

Estimation of the age of bruising

Terence Stephenson, Yvona Bialas

Abstract

Paediatricians are often requested to give an opinion on the age of a non-accidental bruise. In forensic textbooks, the colour changes which a bruise undergoes with time are not based on research in children. The purpose of this study was to document the sequence of colour changes in photographs taken following accidental bruising in children. Fifty accidental bruises of known age in 23 children were photographed by a medical photographer using the same equipment throughout. The photographs were reviewed by a single observer, blind to the true age of the injury, who described the colours present in the bruise. Red colouration was seen in 15 out of 37 bruises which were less than one week old. Yellow colouration was seen in 10 out of 42 bruises over one day old. Aging of bruises from photographs was much less precise than textbooks imply. (*Arch Dis Child* 1996; 74: 53-55)

Keywords: bruising, aging, non-accidental.

In cases of suspected non-accidental injury, paediatricians are often requested to give an opinion on the age of soft tissue injuries, especially if a case comes to court, when several expert witnesses may be called to give their opinion on whether the injuries are consistent with the explanation offered and with the alleged timing of the events. The age of bruises then has to be deduced from photographs of the injuries taken at the time. Published reports on the aging of bruises is confusing. Forensic textbooks which cite the colour changes which a bruise undergoes with time do not appear to be based on research in children and there is no general consensus on the duration of each stage of colour, nor even any agreement on the exact sequence of colour changes¹⁻⁶ (table 1). The purpose of this study was to document the sequence of colour changes in photographs taken after accidental bruising in children.

Methods

White children with accidental bruising from a known timed injury were recruited from the

orthopaedic ward. Children with suspected non-accidental injuries were excluded from the study. Parental consent was obtained for recruitment and the date and time of the injury ascertained. The bruise was then photographed by a single professional medical photographer, using a Nikon F3 single lens reflex camera, with a 105 mm Macro lens, Kodak VPS (160 ASA) film, Metz professional flashgun (to standardise ambient lighting), and a reproducible colour scale included in the field of each photograph. If the child remained in hospital for more than three days, a second set of photographs was taken to offset the fact that most children were admitted and discharged soon after their injury and therefore the sample was biased towards fresher injuries. The photographs were reviewed by one of us (TJS) with personal experience of over 300 cases of non-accidental injury, and this observer was blind to the true age of the injury. The 'blind' observer was asked to record the colours present in the photograph of the injury (described as one or more of red, blue, purple, grey, brown, green, yellow) and to estimate the age of the injury as fresh (48 hours or less), intermediate (between 48 hours and seven days), or old (more than seven days).

The study was approved by the ethics committee of the University Hospital, Nottingham.

Results

We recruited 23 children (13 boys, 10 girls) aged 8 months to 13 years old, with a total of 36 bruises. Twelve were pedestrians or cyclists involved in road traffic accidents and the remaining 11 sustained falls from heights of 0.5 to 2 metres. Of the 36 bruises, 12 involved the upper limb, 12 the lower limb, five the trunk, and seven the face. Ten of these 23 children had a single fracture in addition to the soft tissue injuries but no child had multiple fractures. Ten of the 23 children, with 14 bruises between them, remained as inpatients and were therefore photographed a second time three to nine days later. There were thus 50 photographs of bruises. Six of these children had fractures and four had bruising only. At the time of photography, the actual ages of the bruises varied from 1.5 hours to 14 days (48 hours or less, 34%; 48 hours to seven days, 39%; more than seven days, 27%).

Table 1 Schemes for the aging of bruises (for full references, see end of text)

	Adelson ²	Rentoule and Smith ³	Camps ⁴	Polson and Gee ⁵	Spitz and Fisher ⁶
Initial	Red/blue	Violet	Red	Red, black	Blue/red
1-3 days	Blue/brown	Dark blue	Purple, black	Purple, black	Dark purple
1 week	Yellow/green	Green	Green	Green	Green/yellow
8-10 days		Yellow	Yellow		Brown
2 weeks		Normal	Normal	Yellow	Normal

Department of Child Health, University Hospital, Nottingham NG7 2UH
T Stephenson
Y Bialas

Correspondence to: Dr Stephenson.

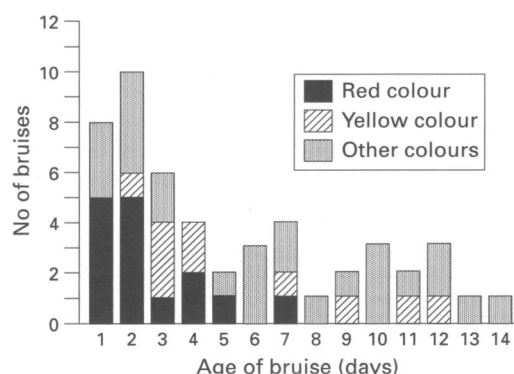
Accepted 5 September 1995

Table 2 Estimation of the age of bruises from photographs: 'Fresh' ≤ 48 hours; 'intermediate' > 48 hours, ≤ 7 days; 'old' > 7 days; 24 correct, 20 wrong

	Estimated fresh	Estimated intermediate	Estimated old
True fresh	7	5	3
True intermediate	0	10	7
True old	0	5	7

The most salient results are shown in the figure and in table 2. Purple, blue, grey, and brown colouration were ascribed to photographs taken from the day of the injury and up to two weeks later. They were therefore not discriminatory in aging the bruises. Purple, grey, and brown were equally likely to be ascribed to injuries less than or more than one week old. Blue colouration was ascribed to five out of the 37 bruises less than one week old and in one bruise more than one week old. Red colouration was ascribed only to photographs of injuries one week old or less, and was described in 15 out of the 37 bruises that were one week old or less (see figure). Yellow colouration was not seen in photographs of injuries less than one day old (but was seen in 10 out of 42 bruises more than one day old, see figure), and green colouration was not ascribed to photographs of injuries less than two days old (but was seen in nine out of 32 bruises more than two days old, data not shown).

The blind observer felt that it was possible to age 44 of the 50 bruises photographed (36 at presentation and 14 on follow up photographs). Six could not be aged because the colour grey was not cited in any of the reference texts. It can be seen from table 2 that the estimate was correct in 24 out of the 44 cases and incorrect in 20. No photograph of an injury older than 48 hours was estimated as being fresh. Apart from this observation, there were errors for all other permutations of aging as shown in table 2. The accuracy of the 'blind' observer's estimates of age of bruising was unrelated to the age of the child (24 correct estimates, median age of child 8 years; 20 incorrect estimates, median age of child 10 years), the presence of a fracture (incorrect in seven out of 17 bruises associated with a fracture, incorrect in 13 out of 27 bruises not associated with a fracture), or to the site of the bruise (incorrect in six out of 16 bruises on the upper limb, nine out of 18 bruises on the lower limb, five out of 10 bruises on the face or trunk).



The height of the bars shows the total number of bruises at each age.

Discussion

A bruise is an escape of blood into the skin, subcutaneous tissue, or both following the rupture of blood vessels, usually capillaries, by the application of blunt force. There may be associated swelling, in which case the injury may be referred to as a haematoma. The appearance of the bruise (and presumably the evolution of the appearance with time) may be influenced by the severity of the blunt force, the vascularity of the underlying tissues, diseases which affect the connective tissues or the ability of the blood to clot, age, possibly sex, and the colour of the skin. Bruising shows more easily the paler the skin. If the skin is loose at the site of injury, as for example around the eye or genitalia, bruising will occur more easily; conversely, if the skin is strongly supported and muscle tone is good, bruising may be minimal. To some extent these factors may be taken into account when an observer ages bruises but often this information will not be apparent from a photograph. For example, the presence of swelling may be very difficult to discern from a photograph.

The extent of a bruise may increase considerably after the injury which caused it, because of continued extravasation of blood and tracking between tissue planes. Gravity may result in a bruise appearing in a place remote from the point of injury, such as may be seen when bruising appears on the outer side of the thigh following a fractured femur or over the lower chest wall following a fractured clavicle.

Petechiae may also arise in children with normal clotting and platelet counts as a result of trauma. Examples are the petechial bruising which occurs as a result of a suction bite (a 'love bite' on the soft tissues of the neck), petechial bruising which may affect the pinna of the ear when it is squeezed or slapped, and petechial bruising on the cheek or around the orbit as a result of a slap mark to the face. There have been no studies of the changes in appearance or colour of petechiae with time.

In reports relating to non-accidental injury, less research has been devoted to soft tissue injuries than to fractures and head injuries.^{7,8} The data from this study suggest that ascribing an age to childhood bruising from colour changes on the basis of photographic evidence is much less precise than forensic textbooks imply. This study shows that several different colours can be present at the same time within one bruise and that bruises can change colour at very different rates, presumably depending on the nature of the injury and the child's response to this injury. At the time of repeat photography in one particular child, the bruise on her leg had turned green/yellow while that on her arm remained blue, although both injuries had occurred during the same accident.

The findings of this study suggest that a red colour is only seen in a photograph of an injury less than a week old, whereas green or yellow hues suggest the injury is at least 24 to 48 hours old. A study in adults showed that photographs of bruises less than 18 hours old never showed a yellow colour. In that study,

the colours red, blue, and purple/black occurred from within one hour of bruising up to 21 days.⁹ Even using the crude categories of 'fresh', 'intermediate', and 'old', aging of injuries from photographs appears to be unreliable, except that an injury over 48 hours old is unlikely to be estimated as fresh from photographs (table 2). Ultraviolet photography can detect bruising which is no longer visible to the naked eye but this technique cannot age these older injuries precisely.¹⁰

This report may be criticised because there was only one 'blind' reviewer and therefore we cannot assess the degree of possible observer variation. It could be alleged that we may have had a vested interest in returning a negative message, or had preconceptions before embarking on the study, thus introducing bias. These issues should be addressed in any subsequent research in this field. Our study may also be criticised because the degree of trauma resulting in a child being admitted to an orthopaedic ward may be more severe than that encountered in children who have been the victims of non-accidental injury or chastisement. It is likely that the duration of bruising is related to the severity of the trauma and perhaps also the proximity of fractures or other injuries. Nevertheless, while this may influence the duration of bruising, the wide variability of colour change found in this study is still likely to apply to a non-accidental injury group rather than the precise colour sequences cited in forensic textbooks.¹⁻⁶ Our study shows that describing shades of flesh

using 'paintbox' colours is extremely difficult. Retrospective opinions on the age of injuries from photographs may be less reliable than a contemporaneous opinion from an experienced paediatrician, particularly since the eye witness may see other clues to age such as abrasions and swelling. Judges and barristers should be made aware of this. Aging of injuries from photographs is imprecise, even in a controlled research setting, but this study draws no conclusions about assessing the age of injuries on clinical examination. This would require a further study in which a 'blind' observer attempted to age the actual injuries at presentation rather than aging photographs of the injury, as was done in this study.

- 1 Wilson EF. Estimation of the age of cutaneous contusions in child abuse. *Pediatrics* 1977; **60**: 750-2.
- 2 Adelson L. *The pathology of homicide*. Springfield: Charles C Thomas, 1974: 382-6.
- 3 Rentoule E, Smith H. *Glaister's medical jurisprudence and toxicology*, 13th Ed. Edinburgh: Churchill Livingstone, 1973: 242-6.
- 4 Camps FE. *Gradwohl's legal medicine*, 3rd Ed. Bristol: John Wright and Son, 1976: 264-7.
- 5 Polson CJ, Gee DJ. *The essentials of forensic medicine*, 4th Ed. Oxford: Pergamon Press, 1984: 97-105.
- 6 Spitz WU, Fisher RS. *Medicolegal investigation of death*, 2nd Ed. Springfield: Charles C Thomas, 1980: 122-5.
- 7 Speight N. ABC of child abuse. Non-accidental injury. *BMJ* 1989; **298**: 879-81.
- 8 Hobbs CJ, Hanks HGI, Wynne JM. *Child abuse and neglect. A clinician's handbook*. Edinburgh: Churchill Livingstone, 1993: 53-4.
- 9 Langlois NEI, Gresham GA. The aging of bruises: a review and study of the colour changes with time. *Forensic Sci Int* 1991; **50**: 227-38.
- 10 Hempling SM. The applications of ultraviolet photography in clinical forensic medicine. *Med Sci Law* 1981; **21**: 215-22.