

Byler-like familial cholestasis in an extended kindred

B Bourke, N Goggin, D Walsh, S Kennedy, K D R Setchell, B Drumm

Abstract
Progressive familial intrahepatic cholestasis (PFIC) occurs in many communities and races. A form of PFIC in five children from two consanguineous marriages in an Irish kindred is described. In addition, a review of clinical information from the records of three deceased members of the kindred strongly implies that they also suffered from PFIC. The children had a history of neonatal diarrhoea, sepsis, and intermittent jaundice that ultimately became permanent. They suffered intractable pruritus and growth retardation. Despite evidence of severe cholestasis, serum γ -glutamyl transferase and cholesterol were normal in these children. Sweat sodium concentration were raised in three children. Liver histology showed severe intrahepatic cholestasis and hepatocellular injury. Urinary bile acid analysis revealed a non-specific pattern consistent with chronic cholestasis. These children suffer from a form of PFIC remarkably similar to that occurring in members of the Byler kindred.

(*Arch Dis Child* 1996;75:223-227)

Keywords: familial cholestasis, Byler disease.

In 1969 Clayton *et al* described seven members of an Amish family descended from Jacob Byler with progressive familial intrahepatic cholestasis (PFIC).¹ Although there have been reports of a similar disease occurring in various individuals and, races^{2-10,11-12} many of these patients differed clinically from the Byler children. Therefore, it is recognised that PFIC comprises a heterogenous group of conditions.¹³ We describe eight affected children from a single kindred with a form of familial intrahepatic cholestasis very similar to that of the original Byler family. This kindred is part of a group of highly intermarried (fig 1) Irish travellers (an indigenous Irish nomadic community). Familial cholestasis affecting eight related children offered a unique opportunity for a detailed clinical and pathological study of the natural history of this rare disease.

Patients

Clinical and biochemical profiles for the five members of the kindred reviewed in this hospital were obtained from other hospital records and appear in tables 1 and 2. Before cholestasis became clinically apparent these children

suffered from episodes of sepsis and severe, protracted diarrhoea. These features continued after cholestasis was established and caused significant morbidity throughout early childhood years.

In three of the children, episodic jaundice appeared within the first two months of life. However, the onset of jaundice was delayed until 6 and 9 months respectively in the other two children.

For each of the children, the established illness was dominated by the complications of chronic cholestasis. Severe, intractable pruritus that was unresponsive to trials of phenobarbitone, rifampicin, ursodeoxycholic acid, or phototherapy was a particularly distressing symptom. Marked hepatosplenomegaly was present in all children. The liver was palpable between 4 and 10 cm below the right costal margin and spleens were palpable up to 4 cm below the left costal margin. In all cases the liver was of very firm consistency. Short stature and failure to thrive were also prominent (table 1).

Recurrent epistaxis was common to all five children. However, haematemesis occurred in only one child. Intellectual development was normal in all of these children.

A number of additional features were also present. Each of the five living children had fine hypopigmented hair. These children also manifested a spectrum of dystrophic nail changes. Mild fingernail pitting, which was evident in the younger children, was superseded by gross dystrophic changes in the older two. Nail scrapings taken from the eldest child grew *Candida inconspicua*.

Results

Varying degrees of conjugated hyperbilirubinaemia and liver enzyme elevation were present (table 2). However, in all of the children, serum albumin and prothrombin time were normal, suggesting hepatic synthetic function was relatively preserved. During intercurrent illness liver enzyme values increased markedly. γ -Glutamyl transferase and cholesterol were normal or near normal in all five children studied. All of the children had markedly raised faecal fat content and severe fat soluble vitamin deficiency.

Abnormal sweat tests were documented in three of these children (table 2). Results of sweat tests performed during infancy were available for four living children (patients 1, 3, 4, and 5) and for two of the children now dead. These sweat tests were all in the normal range during infancy. In view of the abnormal sweat

Department of
 Paediatrics, University
 College Dublin,
 Republic of Ireland

B Bourke
 N Goggin
 D Walsh
 B Drumm

Department of
 Pathology, St Vincent's
 Hospital, Dublin,
 Republic of Ireland
 S Kennedy

Clinical Mass
 Spectrometry Center,
 Children's Hospital
 Medical Center,
 Cincinnati, Ohio, USA
 K D R Setchell

Correspondence to:
 Dr Billy Bourke, Division of
 Gastroenterology, Hospital
 for Sick Children, 555
 University Avenue, Toronto,
 Ontario, Canada M5G 1X8.

Accepted 29 April 1996

Table 1 Clinical findings in (living) members of kindred with Byler disease

Patient No	Age (years)	Onset of jaundice (months)	Height centile	Weight centile	Pruritus (0-4 + *)	Nail dystrophy	Hepatomegaly (cm†)	Haematemesis
1	12	6	< 3	< 3	3-4 +	Severe	6-8	Yes
2	11	< 2	< 3	< 3	2-3 +	Moderate	8-9	No
3	6	< 2	< 3	< 3	3 +	Mild	9	No
4	4	9	< 3	3	3-4 +	Mild	7-8	No
5	4	< 2	< 3	< 3	3 +	Mild	4	No

* Pruritus scoring: 0 = none, 1 + = rubbing or scratching when undistracted, 2 + = scratching without abrasions, 3 + = abrasions evident, 4 + = cutaneous mutilation, haemorrhage, and scarring.

† Measurements indicate liver size below the right costal margin.

Table 2 Biochemical findings in (living) members of kindred with Byler disease

Patient No	Age (years)	AST (IU/l)	ALP (IU/l)	Bilirubin ($\mu\text{mol/l}$)	Cholesterol (mmol/l)	Albumin (g/l)	Prothrombin time (s)	GGT (IU/l)	5'NT (IU/l)	Sweat	
										Sodium (mmol/l)	Chloride (mmol/l)
1	12	45	508	170	3.5	39	15	20	25	50	33
2	11	62	723	86	4.6	40	13	21	35	30	17
3	6	75	908	183	5.9	43	12	22	42	102	79
4	4	56	536	45	4.3	40	12	19	16	88	69
5	4	111	750	172	3.7	42	13	46	33	28	25
Normal values	—	8-40	—	< 17	2.3-5	33-58	10.5-15	< 24	< 12	< 40	< 40

Biochemical parameters refer to values at presentation to this hospital (at age as given). AST = aspartate aminotransferase; ALP = alkaline phosphatase; GGT = γ -glutamyltransferase; 5'NT = 5'-nucleotidase.

tests the four siblings, patients 1, 2, 3, and 4, and their mother were all screened for cystic fibrosis $\Delta F508$ mutation and 10 other mutations common among Irish cystic fibrosis patients including R117H, D1507, G542X, G551D, R560T/R560K, N1303K, W1282X, R553X, 1717-1G \rightarrow A and 621 + 1G \rightarrow T. Each of the children and their mother were negative for all 11 mutations.

Exhaustive investigations were undertaken to rule out other causes of cholestasis. Screening studies for hepatitis A, B, and C were negative. Serum and urinary amino acid chromatography and urinary organic acid profile gave normal results. The serum α_1 -antitrypsin values and phenotype were also normal. Extrahepatic

manifestations of Alagille's syndrome, such as posterior embryotoxin and butterfly vertebrae, were sought but not found. Karyotype was normal in all of the children.

Three other children from this kindred died from sepsis. Two children were aged 4 months and one was 15 months. Clinical information was available for two of these children. The 15 month old child was diagnosed in another hospital with PFIC. She had recurrent diarrhoea and failure to thrive before the onset of jaundice and pruritus at age 7 months. Her disease was clinically and biochemically identical to that of the five living children described above. The 4 month old child suffered with severe diarrhoea and failure to thrive from age 1 month. At the time of death (4 months) he was anicteric but had markedly raised transaminases (alanine aminotransferase = 468 U/l). No clinical notes were available for the third child. However, he was jaundiced at the time of death.

Each of the five living children were followed up at this institution for three years since the initial referral; they were maintained on fat soluble vitamin replacements. The eldest child required intermittent hospitalisations during intercurrent infections, which were commonly accompanied by bouts of watery diarrhoea. Although copious, stool output diminished appropriately during fasting. Invariably, pathogenic organisms were absent from stools during these episodes. Furthermore, immunological investigations performed on a subgroup of these children including immunoglobulin concentrations (patients 1 and 3) and T cell subsets (patient 1) were normal. IgG₁, IgG₂, and IgG₄ subclasses were raised in the one child (patient 3) in whom they were evaluated. Despite the severity of cholestasis during this period there was no clinical or biochemical evidence of disease progression among any of the children.

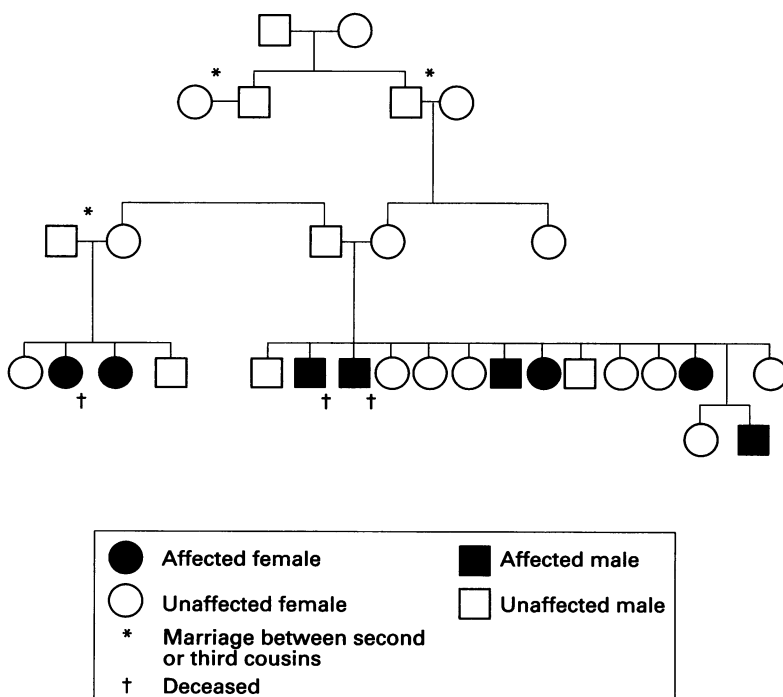


Figure 1 Pedigree of Irish Byler kindred illustrating high degree of intermarriage.

LIVER HISTOLOGY

Liver biopsy specimens were obtained from each of these children. The specimens from the youngest children (patients 3, 4, and 5) showed moderate periportal inflammation and portal expansion. In these specimens there was apparently normal bile duct number and calibre with neocholangiole formation at the periphery of the portal tracts. Changes within the lobular parenchyma included pseudorosette or pseudoacinar formation with bile thrombi and canalicular bile stasis (fig 2A). In the specimens from the older children (patients 1 and 2), pseudoacinar change and cholangiolar bile stasis were equally prominent with giant cell transformation in the children aged 11 and 12 years (fig 2B). Steatosis was not seen. Thin fibrous bands extended out from the portal tracts in these specimens, although bridging fibrosis and regenerative nodules were not present (fig 2C). In specimens from these older children there were inflammatory aggregates within the hepatic parenchyma and occasional acidophil bodies. Hepatocellular architectural changes such as irregular liver cell plates were seen at this stage. An acquired paucity of intralobular bile ducts was also present in these specimens.

URINARY BILE ACID ANALYSIS

Urinary bile acids were analysed for four of the children (patients 1, 2, 3, and 4). Bile acids were extracted, concentrated, and analysed by fast atom bombardment ionisation-mass spectrometry (FAB-MS) and gas chromatography-mass spectrometry (GC-MS).¹⁴⁻¹⁶ The results of FAB-MS and GC-MS analysis revealed similar patterns for each of the four children. All children were capable of synthesising the two primary bile acids. Each had markedly increased total urinary bile acid excretion. Raised excretion of glycine, taurine, and sulphate conjugates of dihydroxy, trihydroxy, and tetrahydroxy cholanoic acids was detected. The pattern of bile acid excretion was consistent with chronic cholestasis rather than an inborn error of bile acid synthesis.

Discussion

Since the report of Clayton *et al* in 1969,¹ the terms PFIC and Byler disease have been used synonymously for this condition. However, it is clear that many cases described subsequently demonstrate considerable clinical, biochemical, and pathological heterogeneity.^{2-4 6 11} Therefore, it is now speculated that PFIC includes a group of conditions of varying aetiologies.¹² In this report we have described a form of PFIC affecting an extended kindred of Irish travellers.

Members of this kindred suffered with a form of PFIC identical in many respects to that of the Byler kindred. Specific features common to this Irish family and the original Byler kindred include early onset of diarrhoea followed by episodic cholestatic jaundice, which ultimately becomes permanent, intractable pruritus, growth, but not mental, retardation, fine blond hair, the complications of fat soluble vitamin deficiency, normal serum

cholesterol, and recessive inheritance pattern.^{1 17} It is also noteworthy that a high degree of intermarriage is common among both the Amish and Irish travelling people. However, some features specific to the children in this report (for example nail dystrophy) suggest that this Irish family may suffer from a unique form of PFIC.

Death in early life is a feature among some children with this condition.^{1 8 17} Three children in this kindred are dead, two in infancy and one at 15 months old. Of the five living children, all spent the greater part of the first year of life in hospital. True Byler disease and Byler-like familial cholestasis associated with low serum γ -glutamyltransferase is associated with a poor prognosis.^{1 18} However, it is noteworthy that survival past infancy in this Irish kindred has been followed by relatively slow disease progression, albeit in the face of severe cholestasis and a high level of morbidity.

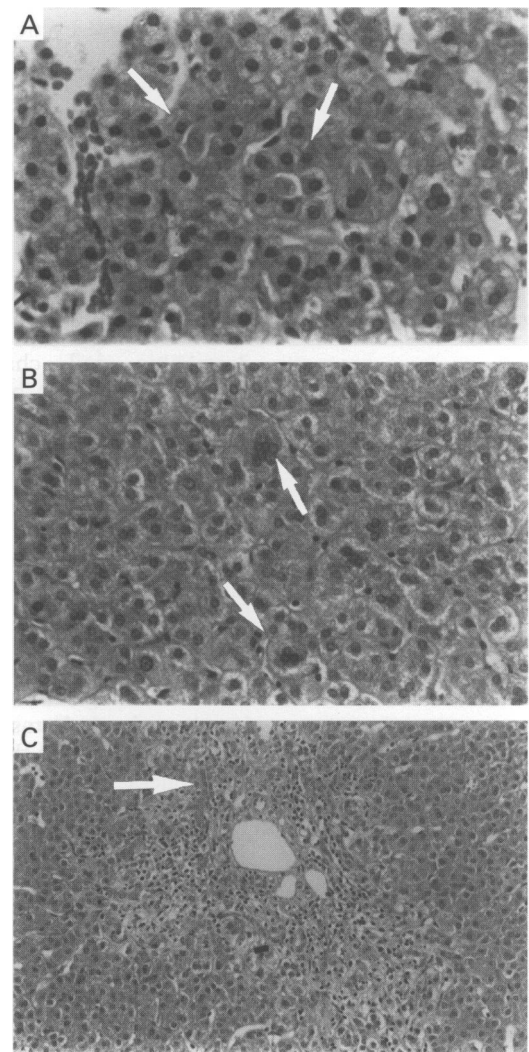


Figure 2 Liver biopsy specimens. (A) Biopsy specimen taken from patient 4 (aged 4 years). Pseudoacinar transformation (arrows) and intracanalicular bile are prominent (magnification $\times 200$). (B) Biopsy specimen taken from patient 1 (aged 12 years); there is hepatocellular disarray with multinucleate hepatocytes scattered throughout the liver parenchyma (arrows) (magnification $\times 200$). (C) Biopsy specimen from patient 1; there is stellate periportal fibrosis and inflammation spilling into the adjacent hepatic parenchyma. Transformation of hepatocytes to neocholangioles can be seen at the edges of the portal tracts (arrows) (magnification $\times 100$).

Recurrent diarrhoea and sepsis were features of this disease in the original Byler kindred. A recent report from Switzerland describes a similar case presenting with idiopathic diarrhoea and recurrent sepsis.⁸ Although we are not told of any relationship between this case and the Byler family, it is of interest that the Byler kindred were of Swiss descent.¹⁷

Sweat electrolytes are reported to be raised in some children with PFIC.^{19, 20} In this study, raised or high normal sweat sodium values were observed in all except one child (patient 5) over 6 months old. Frankly raised sweat sodium was found in three children aged 4, 6, and 12 years. Normal sweat test results were documented elsewhere for five of these children during infancy. This suggests that sweat sodium is normal in early life when diagnostic confusion with cystic fibrosis would be most likely to occur. Conversely raised sweat sodium or chloride may be a useful marker for this condition in later childhood. Despite some phenotypic similarities these children do not appear to have cystic fibrosis as they have no evidence of respiratory disease and do not manifest any of the more common cystic fibrosis mutations found in the Irish population. In addition, the immune reactive trypsinogen value was not depressed in one child (patient 3) in whom it was measured, consistent with intact pancreatic function.

Cell mediated immunity has been documented to be abnormal in patients with PFIC,²¹ which may account for the recurrent episodes of sepsis in these children. Although dystrophic nail changes associated with chronic candidiasis have not previously been reported in PFIC, nail channel osteomyelitis occurred in a very similar case.⁸ Although we failed to observe an abnormality in immunoglobulin concentrations or T cell subsets in members of this family, chronic nail infection offers further evidence for a defect in cell mediated immunity in PFIC. The relevance of the observed increase in IgG subclasses in one of the kindred is as yet uncertain.

In this series the liver disease is characterised at the histological level by a combination of intrahepatic cholestasis and hepatocellular injury consistent with the toxic affect of accumulated bile acids. Giant cell transformation was not remarkable in the biopsy specimens of the original Byler kindred.^{1, 17} However, giant cell transformation has been commented on in other cases of PFIC,²² including a case typical of the original family in other respects.⁸ Pseudoacini or rosettes are a prominent feature of the disease in most reports. Paucity of bile ducts has been a prominent feature in some reports of PFIC.^{3, 22} Ductular proliferation rather than paucity was present in the early infancy biopsy specimens in the original report of this condition.¹ However, ductular paucity (with focal ductular proliferation) was present in a child aged 3.5 with the typical disease.⁸

There is considerable disagreement about the typical pattern of bile acid excretion in PFIC.^{1, 2, 5, 17} However, there is no evidence to implicate an inborn error of bile acid synthesis as a cause of this disease. We found no

evidence to suggest a primary defect in bile acid synthesis in this family. We were also unable to detect a raised cholic acid to chenodeoxycholic acid ratio in urine from this family with PFIC as has been described for other patients with PFIC.⁹ A recent report from France implicates a defect in canalicular secretion of bile acids in the aetiology of PFIC.²³ This assumption was based on the finding of very low concentration of biliary bile acids in the presence of raised serum bile acids coupled with normal serum γ -glutamyltransferase in seven unrelated children with PFIC. Further studies comparing the bile acid profiles of urine, serum, and bile from patients of the original Byler kindred and others displaying a similar disease (such as those described in this report) will help confirm this finding. Such studies would also help to more precisely establish the relationship of Byler disease to other forms of PFIC.

Although not phenotypically identical, this extended non-Amish family suffers from a form of PFIC remarkably similar to that of the Byler kindred. An understanding of these rare diseases may provide insights into the aetiological events underlying more frequently encountered cholestatic conditions such as that associated with cystic fibrosis. Therefore, further investigations are warranted to elucidate the aetiology of these conditions.

We thank Dr J Murphy, Dr M Taylor, and Dr E Naughten for allowing us the opportunity to examine these patients. We are grateful to Dr S McQuaid and Dr D Barton for providing molecular genetic analysis and Dr Bernard Portmann for additional histopathological consultations during the management of these children.

- 1 Clayton RJ, Iber FL, Ruebner BH, McKusick VA. Byler disease. Fatal familial intrahepatic cholestasis in an Amish kindred. *Am J Dis Child* 1969; 117: 112-24.
- 2 Williams CN, Kaye R, Baker L, Hurwitz R, Senior JR. Progressive familial cholestatic cirrhosis and bile acid metabolism. *J Pediatr* 1972; 81: 493-500.
- 3 Ballow M, Margolis CZ, Schachtel B, Hsia YE. Progressive familial intrahepatic cholestasis. *Pediatrics* 1973; 51: 998-1007.
- 4 Odievre M, Gautier M, Hadchouel M, Alagille D. Severe familial intrahepatic cholestasis. *Arch Dis Child* 1973; 48: 806-12.
- 5 De Vos R, De Wolf-Peeters C, Desmet V, Eggermont E, Van Acker K. Progressive intrahepatic cholestasis (Byler's disease): case report. *Gut* 1975; 16: 943-50.
- 6 Jones EA, Rabin L, Buckley CH, Webster GK, Owens D. Progressive intrahepatic cholestasis of infancy and childhood. *Gastroenterology* 1976; 71: 675-82.
- 7 Nakagawa M, Tazawa Y, Kobayashi Y, et al. Familial intrahepatic cholestasis associated with progressive neuromuscular disease and vitamin E deficiency. *J Pediatr Gastroenterol Nutr* 1984; 3: 385-9.
- 8 Winkhofer-Roob BM, Shmerling DH, Soler R, Briner J. Progressive idiopathic cholestasis presenting with profuse watery diarrhoea and recurrent infections (Byler's disease). *Acta Paediatr* 1992; 81: 637-40.
- 9 Whittington PF, Freese DK, Alonso EM, Fishbein MH, Emond JC. Progressive familial intrahepatic cholestasis (Byler's disease). In: Lentze M, Reichen J, eds. *Paediatric cholestasis—novel approaches to treatment*. Dordrecht: Kluwer Academic Publishers; 1992:165-80.
- 10 Gray OP, Saunders RA. Familial intrahepatic cholestatic jaundice in infancy. *Arch Dis Child* 1966; 41: 320-8.
- 11 Dahms BB. Hepatoma in familial cholestatic cirrhosis of childhood. *Arch Pathol Lab Med* 1979; 103: 30-3.
- 12 Riely CA. Familial intrahepatic cholestasis: an overview. In: Walker WA, Durie PR, Hamilton JR, Walker-Smith JA, Watkins JB, eds. *Pediatric gastrointestinal disease*. Vol 2. Philadelphia: BC Decker, 1991:1025-32.
- 13 Whittington PF, Freese DK, Alonso EM, Schwarzenberg SJ, Sharp HL. Clinical and biochemical findings in progressive familial intrahepatic cholestasis. *J Pediatr Gastroenterol Nutr* 1994; 18: 134-41.
- 14 Setchell KDR, Worthington J. A rapid method for the quantitative extraction of bile acids and their conjugates from serum using commercially available reverse phase octadecylsilane bonded silica cartridges. *Clin Chim Acta* 1982; 125: 135-44.

- 15 Sjovall J, Lawson AM, Setchell KDR. Mass spectrometry of bile acids. In: Law JH, Rilling HC, eds. *Methods and enzymology*. Vol 1. London: Academic Press, 1985:63-113.
- 16 Setchell KDR, Matsui A. Serum bile acid analysis: the application of liquid-gel chromatographic techniques and capillary column gas chromatography and mass spectrometry. *Clin Chim Acta* 1983; **127**: 1-17.
- 17 Linarelli LG, Williams CN, Philips MJ. Byler's disease: fatal intrahepatic cholestasis. *J Pediatr* 1972; **81**: 484-92.
- 18 Maggiore G, Bernard O, Riely C, Hadchouel M, Lemonnier A, Alagille D. Normal serum γ -glutamyl-transpeptidase activity identifies groups of infants with idiopathic cholestasis with poor prognosis. *J Pediatr* 1987; **113**: 251-2.
- 19 Hillemeier AC, Hen J, Riely CA, Dolan TF, Gryboski JD. Meconium peritonitis and increasing sweat chloride determinations in a case of familial progressive intrahepatic cholestasis. *Pediatrics* 1982; **69**: 325-7.
- 20 Lloyd-Still JD. Familial cholestatic syndrome with elevated sweat electrolytes. In: Sturgess JM, ed. *Proceedings of the 8th International Congress on Cystic Fibrosis*. Toronto: Imperial Press, 1980:25a.
- 21 Maggiore G, De Giacomo C, Scotta MS, Siena S, Maccario R, Vitiello A. Cell-mediated immunity in children with chronic cholestasis. *J Pediatr Gastroenterol Nutr* 1982; **1**: 385-8.
- 22 Alonso EM, Snover DC, Montag A, Freese DK, Whittington PF. Histologic pathology of the liver in progressive familial intrahepatic cholestasis. *J Pediatr Gastroenterol Nutr* 1994; **18**: 128-33.
- 23 Jacquemin E, Dumont M, Bernard O, Erlinger S, Hadchouel M. Evidence for defective primary bile acid secretion in children with progressive familial intrahepatic cholestasis. *Eur J Pediatr* 1994; **153**: 424-8.