

CONCERNING SURGICAL TREATMENT OF TRAUMATIC INJURY OF THE UPPER DIVISION OF THE BRACHIAL PLEXUS (ERB'S-TYPE)*

ALEXANDER LURJE, M.D.

MOSCOW, U.S.S.R.

FROM THE SURGICAL DIVISION OF BLAUGUSHIN'S HOSPITAL, MOSCOW, U. S. S. R.
DIRECTOR, PROF. F. M. LAMPERT.

IN CASES OF INJURY of the "upper primary fasciculus" of the brachial plexus, (which is formed as a result of confluence of the 5th and 6th cervical roots) the classical method of choice is direct suturing after resection of neuroma and removal of scar tissue. Foerster, Babchin and we observed restoration of the function of *m. deltoideus* and *m. biceps* 6-18 months after operation. Having performed 82 operations upon the brachial plexus we became convinced that in many cases the defect, formed after removal of neuroma and scar tissue, is so great that direct suturing—to unite the divided ends of the upper primary fasciculus (or its elements)—becomes impossible. Recourse to transplants in such cases does not appear to hold much promise. In certain cases it is possible to employ implantation into the peripheral end of the divided upper primary fasciculus of some neighboring nerve which would serve as a neurotizer. Such nerves as *n. phrenicus*, *n. thoracalis longus*, or one of the *nn. thoracales anterior* (a method used by Foerster, and by us) could be used for the purpose.

However, in many cases the damage may be so extensive that the above nerves cannot be employed with any hope for success. Sometimes there is a considerable difference in the dimensions of the neurotizer and of the cut-end of the upper primary fasciculus, so that it becomes doubtful whether the size of the neurotizer would be adequate to assure sufficient supply of growing fibers for the basic pathways of the peripheral end. We have made use of the neurotizers in a series of operations in which the neurotizers were implanted into the peripheral trunk of the plexus after it was isolated in the zone of injury. The remote results of such operations will be described elsewhere.

Our experience in the surgery of large destruction of single trunks of the *plexus brachialis*, led us to the conclusion that certain muscular branches of the plexus (those which could be used without impairing essentially the function of the extremity) could be profitably used as neurotizers for the functionally more important peripheral nerves, which had been traumatically severed. It seemed rational to neurotize the divided nerves as far distally from the zone of injury as possible. This is, of course, to assure optimal conditions of regeneration and, thus, to shorten the period of healing. The execution of the operation distally from the zone of trauma (and scarification) also makes the suturing, *etc.*, technically much easier.

* Translated by S. A. Komarov, M.D., Ph.D.

The operation of neurotization, when indicated by exploration, can be conveniently carried out as the concluding step of the exploratory operation. In many cases, when the exploratory operation, for some reason, has been lengthy, neurotization can be carried out as a separate second-stage. Sometimes a preliminary examination of the scars and a study of the local changes in the zone of trauma permits a purely clinical diagnosis of the impossibility of restoring any function by means of surgery in the traumatized area. In these cases it is advisable to undertake neurotization from an incision made distally from the zone of trauma. While considering such a decision, one must have in mind that very often patients will not consent to undergo a second operation after the first has not brought about any functional improvement.

In traumatic lesions of the upper primary fasciculus (so-called Erb's paralysis), there is a loss of function of *n. suprascapularis*, *n. axillaris* and *n. musculocutaneus*, with atrophy of the corresponding muscles.

As a result of the study of topography on 100 cadavers, we have concluded that the following nerves can be rationally used for neurotization of the above-mentioned nerves: *n. thoracalis longus*, *nn. thoracales anterior rami tricipitis of the n. radialis*, *n. thoracalis dorsalis*, and *n. subscapularis*—providing these nerves contain a sufficient number of the intact fibers. Foerster, and others, have successfully employed *n. thoracalis dorsalis* and *n. subscapularis* in cases of isolated injury of the *n. axillaris*. He also described a successful neurotization of the peripheral end of *n. musculocutaneus* with *nn. thoracales anterior*. Analogous operations are described by Vulpius and Stöffel in their handbook. It should be mentioned that these operations were used separately in cases of isolated injuries of the axillary nerve and *n. musculocutaneus*, where the defect in these nerves after revision of the zone of injury could not be repaired by direct suturing.

N. thoracalis longus is usually formed by the branches from C5, C6, and C7, which emerge from the corresponding roots at the level of the processus transversalis. The roots from C5 and C6 pass through the substance of *m. Scalenus medius*. The most massive trunk from C7 passes laterally on the anterior aspect of the middle scalene muscle. Often, the main trunk of *n. thoracalis longus*, and the structures forming it, remain uninjured when the upper primary fasciculus is completely destroyed, and in such cases this nerve can be advantageously used as a neurotizer.

N. radialis gives off its branches to *m. triceps* rather high, at the level of the tendon of *m. latissimus dorsi*. At this level, or a little lower, *rami tricipitis* can be separated, tested with inductorium and used as neurotizers after having been turned upwards.

For neurotization of the axillary nerve we prefer to use two (from 3 or 4), *rami tricipitis n. radialis*, rather than *n. thoracalis dorsalis* or *n. subscapularis*, for the following reasons: *Nn. subscapulares* receive most of their fibers from the upper primary fasciculus and, therefore, in cases of Erb's paralysis, are mostly degenerated. The use of only two of *rami tricipitis* does not entirely deprive the *m. triceps* of its innervation, while the use of *n. thoracalis dorsalis*

for neurotization would entirely deprive *m. latissimus dorsi* of its nerve supply. The cross-section of two *rami tricipitis* may not be smaller, and sometimes is even larger, than that of *n. thoracalis dorsalis*, which circumstance makes implantation convenient. However, when some difficulties are encountered in the use of *rami tricipitis*, *n. thoracalis dorsalis* can be used for neurotization of *n. axillaris*, especially as it receives its fibers mainly from C7 and C8. *Rami tricipitis* receive their fibers from C7, C8 and T1. *Nn. thoracalis anterior* are formed by the elements of the upper primary fasciculus and by the fibers from C7 and from the lower primary fasciculus as well.

Conclusions as to the functional adequacy and choice of the nerves to be used as neurotizers and as to the degeneration of the recipient nerves are formed from the clinical study of the state of the corresponding muscles, from the results of electrophysiologic examination performed before the operation, and, also, from the results of the stimulation with inductorium and determination of chronicity during the operation.

It should be mentioned, that if some of the fibers of the neurotizer are degenerated (the fibers from the injured plexus which find their way into the neurotizer as a result of exceedingly complex nature of the plexus) then, of course, the process of neurotization of the distal segment of the nerve—whose functional restitution is our aim—would be accomplished only by the intact fibers. In order to assure satisfactory neurotization of the recipient nerve, the intact fibers of the donor nerve should give off a considerable number of collaterals, during the process of regeneration. This is facilitated by a gentle handling, with the use of sharp instruments for cutting the nerve, and the avoidance of any tension. Being distributed evenly on the cross-section of the nerve, these intact fibers will supply the recipient nerve with a sufficient number of regenerating elements, particularly, if the diameter of the nerve donor approaches that of the nerve recipient. Incidentally, such a nerve donor, with only a part of its fibers degenerated, can show a fair functional capacity on being tested electrophysiologically. It should be remembered that the caliber of the nerve recipient, which has already undergone a process of Wallerian degeneration and atrophy, is considerably smaller than that of the corresponding normal nerve. This simplifies coaptation of the epineurium in suturing the nerve donor with nerve recipient. Experimental data of Kilvington, Kennedy, Feiss, Aird and Naffziger indicate that considerably thinner donor nerves, sutured end to end to the thicker recipient nerves, are capable of giving good neurotization of the recipient nerves, with restitution of the function, even if the ratio of the cross-sections is 1 : 2 or 1 : 3.

A case of neurotization with the use of *nn. thoracalis anterior*, *n. thoracalis longus* and *rami tricipitis* of *n. radialis* in Erb's paralysis is presented here.

Case Report: Patient N., female, age 20, was wounded, December 21, 1944, in left side of the neck, by a bomb fragment. She entered the hospital August 6, 1945. On the left side of the neck there is a large scar fixed firmly to the hardened and tender underlying tissues (Fig. 1). Roentgenologic examination reveals deformation of the *processus transversalis* of C7 and a fracture of the first rib at the neck. Physical examination

shows pronounced atrophy of the scapular muscles, deltoid muscle (Fig. 2) and biceps; complete absence of the function in the shoulder joint, except for adduction (after a passive abduction) on account of contraction of *m. pectoralis* and *m. latissimus dorsi*; complete absence of flexion in the elbow joint while extension is adequate; absence of supination; pronation adequate. Movements in the radio-carpal joint and also in the wrist and fingers are well preserved. There is anesthesia in the zone of innervation C5 and C6.

Extensive cicatrization, depth of paralysis and atrophies indicated a considerable destruction of the upper primary fasciculus and possibly also of the roots C5 and C6. These conditions made doubtful the possibility of restitution of the anatomic relations by direct suturing of the injured nerves *in situ*, and of regeneration after the operation. Predicated upon these reasons, and, also, because we did not wish to operate twice (as

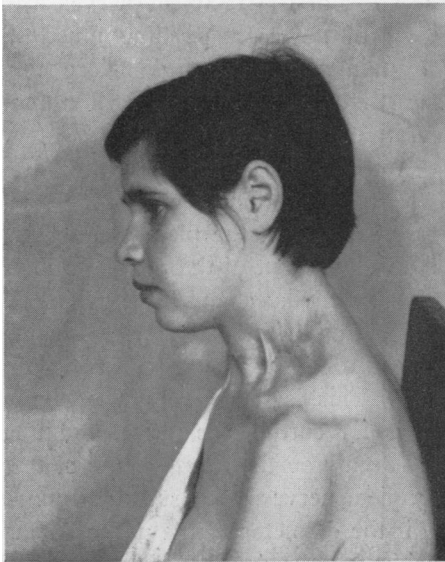


FIG. 1

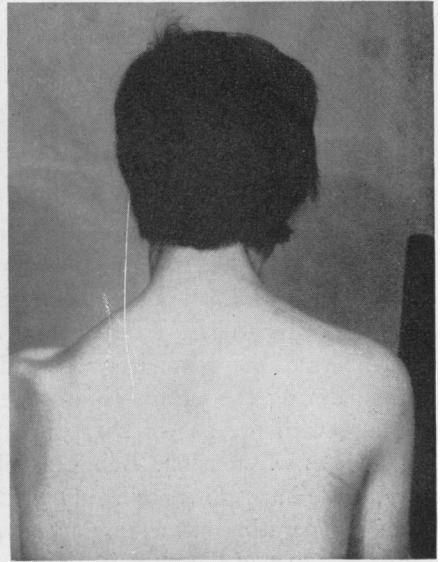


FIG. 2

FIGS. 1 and 2.—Preoperative. Note atrophy about shoulder girdle.

the first operation above the clavicle, in our opinion, would be lengthy and not successful) it was decided to undertake implantation of the sound neurotizers into the peripheral nerves, with the aim not to impair essentially the remaining functions of the limb.

Operation.—August 10, 1945, (Lurje): Incision from the clavicle to the borderline between the upper and middle third of the arm. *M. pectoralis major* was separated from *m. deltoideus* and from the clavicle for 5-cm., and then dissected at its insertion. Next the clavi-pectoral fascia and *m. subclavius* were dissected. In the upper corner of the wound it was not hard to find the suprascapular nerve below the clavicle, while pulling slightly the outer (secondary) fasciculus of the brachial plexus. Stimulation with inductorium revealed complete degeneration of the nerve with absence of any response from the scapular muscles. *N. thoracalis longus* was found below all the trunks of the brachial plexus. Stimulation of *n. thoracalis longus* resulted in the contraction of *m. serratus anterior*. This nerve was divided below the 2nd rib in such a manner that innervation of the upper two digitations of *m. serratus anterior* was preserved; the nerve was then implanted with three fine silk sutures into the peripheral end of *n. suprascapularis* which

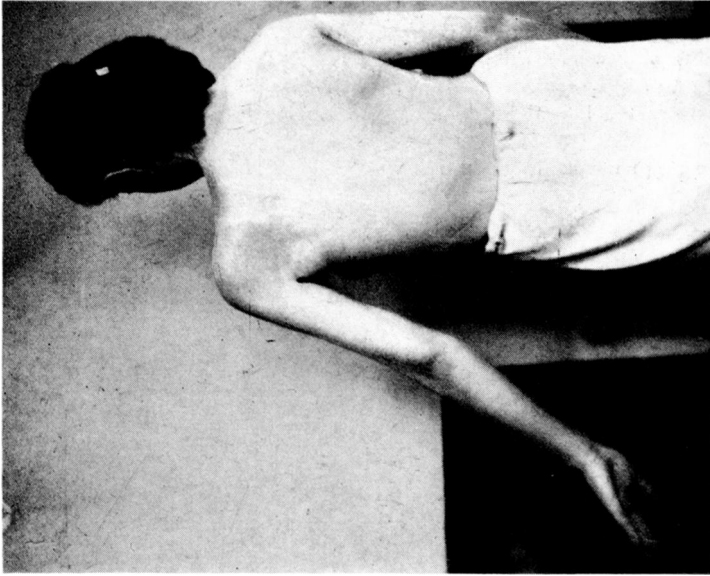


FIG. 4

FIGS. 3 and 4.—Five months postoperative. (See text.)

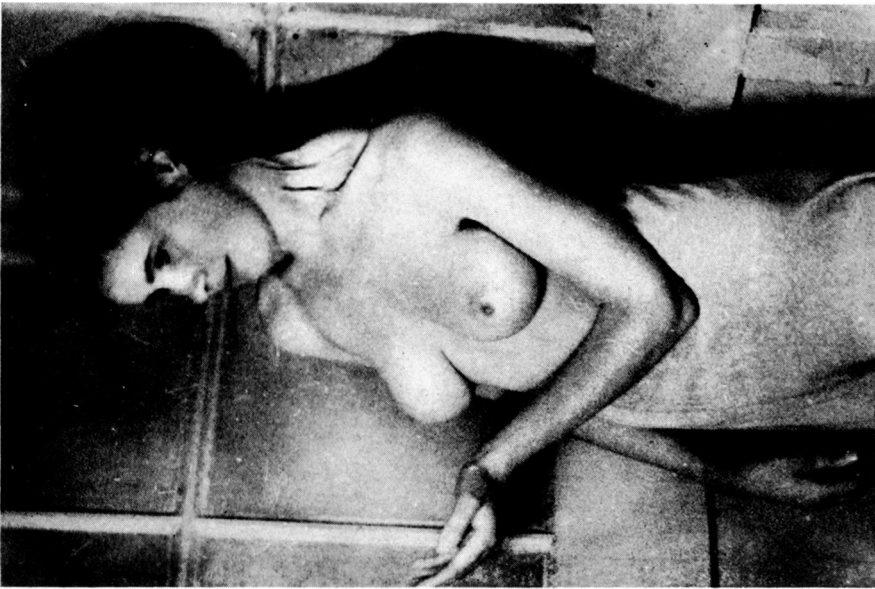

FIG. 3

had been divided below the clavicle. The cross-sections of both nerves were nearly the same, as the suprascapular nerve was degenerated and atrophic. In the middle part of the wound we separated two *nn. thoracalis anterior*. They emerged from the lateral secondary fasciculus of the brachial plexus (derived mainly from C7). After having verified their functional adequacy, we implanted them into the peripheral end of the previously divided (at its origin) *n. musculocutaneus*. The caliber of both *nn. thoracalis anterior* was comparable to that of *n. musculocutaneus*. It was first necessary to isolate *n. musculocutaneus* upwards from the lateral head of the median nerve with the aid of cutting instruments; the nerve was divided high, so that it would be possible to perform implantation while avoiding any tension. Implantation was made with four fine silk sutures.

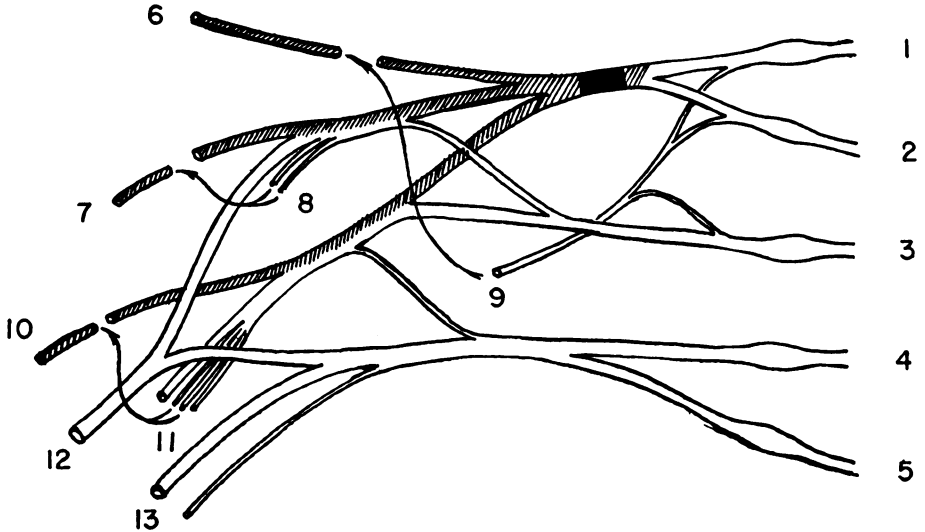


CHART I.—1. 5th cervical n. 2. 6th cervical n. 3. 7th cervical n. 4. 8th cervical n. 5. 1st thoracic n. 6. Suprascapular n. 7. Musculocutaneous n. 8. Anterior thoracic n. 9. Long thoracic n. 10. Axillary n. 11. Triceps rami of radial n. 12. Median n. 13. Ulnar n.

In the lower corner of the wound, we isolated three *rami tricipitis* of *n. radialis*. Two of them were divided and turned upwards and implanted into *n. axillaris*. The latter was cut on the anterior aspect of *m. subscapularis* at its origin from the posterior secondary fasciculus of the brachial plexus and then its peripheral end was turned downwards. The caliber of the nerve donor and the nerve recipient were nearly equal (Chart I).

The wound was closed in the usual way and left with drainage for 24 hours. The postoperative course was uneventful.

Already, after two months, control examination revealed a definite improvement in the functions of *mm. pectoralis* and *m. triceps* (at the time of the operation their innervation was impaired by about two-thirds). At five months, after treatment with massage and faradization, there was some restitution of movements in the elbow joint, contractions of the deltoid muscle also appeared, and atrophy began to diminish (Figs. 3 and 4).

Examination of the patient on October 10, 1946 (14 months after the operation) revealed a disappearance of atrophy of *m. deltoideus* and *m. biceps*, and a diminution of atrophy of the scapular muscles. The patient was able to contract *m. deltoideus* strongly

INJURY OF BRACHIAL PLEXUS

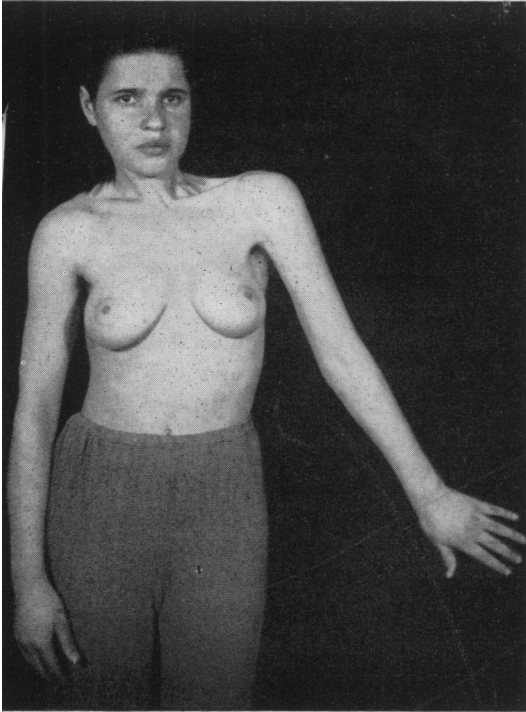


FIG. 5

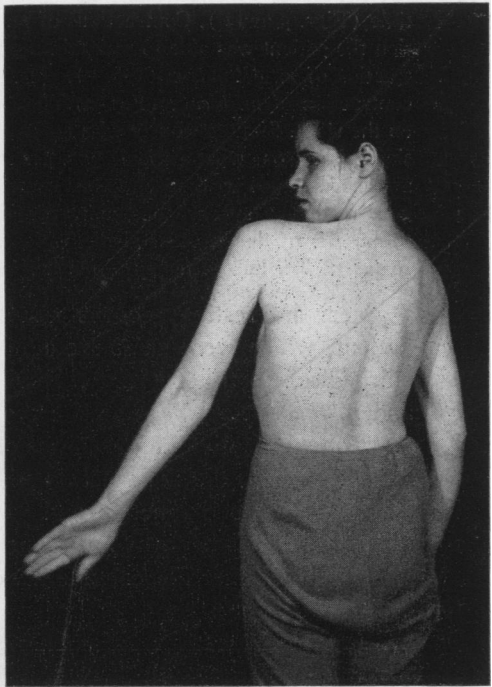


FIG. 6

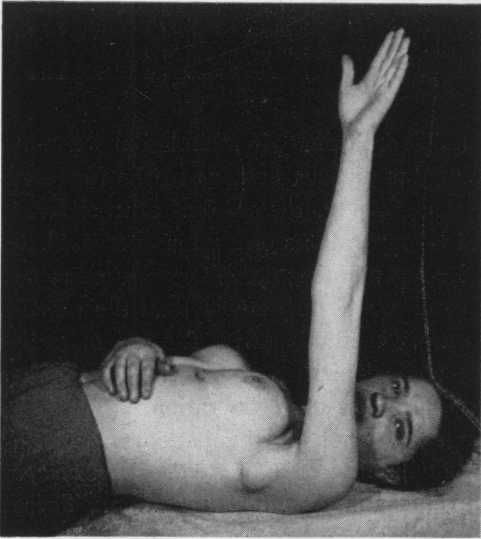


FIG. 7

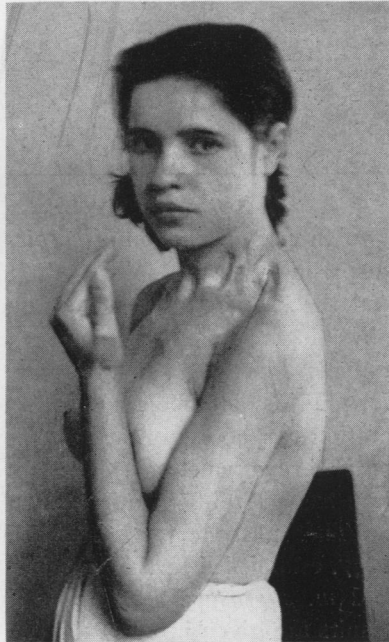


FIG. 8

Figs. 5, 6, 7 and 8.—Fourteen months postoperative. (See text.)

with abduction of the shoulder for 35°, while *m. triceps* contracts maximally at the same time (Figs. 5 and 6). Contractions of *m. supraspinatus* were quite definite. In supine position the patient was able to maintain the limb in the vertical position by virtue of the contraction of *m. deltoideus* (Fig. 7). Flexion in the elbow joint was complete with distinct contraction of *m. biceps* (Fig. 8). The strength of *m. biceps* is below that of the muscle on the right. Simultaneously with contractions of *m. biceps* there are synchronous contractions of the somewhat atrophic *mm. pectoralis*; and, similarly, contractions of *m. deltoideus* are accompanied with synchronous contractions of *m. triceps*. This phenomenon is analogous to that of synchronous contractions of the facial muscles together with contractions of muscles of the shoulder girdle, which can be observed after transplantation of *n. accessorius willisii* into *n. facialis* from half a year to a year after the operation.

Very interesting are the results of the chronaxymetric studies on our patient, which were carried out in the physiologic laboratory of the Neurochirurgical Institute (L. A. Novikova): Before the operation, *n. axillaris* and *n. musculocutaneus* gave a typical reaction of degeneration, and did not react on stimulation at a rheobase of 280v. After the operation, on October 4, 1946, *m. biceps* did not react on stimulation at a rheobase up to 200v, in spite of otherwise good function and occurrence of distinct contractions. *M. deltoideus* on the side of the injury gave chronaxy of 2.8G at a rheobase of 100v, while on the other normal side the chronaxy was 0.24G at a rheobase of 60v.

TABLE I.

April 26, 1947				
Right Arm Normal				Left Arm Operation
G	F		G	F
a < k			a > k	
2.6 mA	3	<i>m. supraspinatus</i>	8.0 mA	6.5
1.0 mA	3.2	<i>m. biceps</i>	4.6 mA	3.8
2.4 mA	3.8	<i>m. deltoideus</i>	5.0 mA	4.2

Absence of reaction of *m. biceps* on electrophysiologic stimulation was not surprising to us, in spite of the fact that this muscle, both as to the function and the shape, was restored much better than *m. deltoideus*. Our electrophysiologic studies on remote results of the operations on various nerves, had convinced us that in almost every case the regenerating nerve becomes passable for physiologic impulses much sooner (and more completely) than the regeneration can be established by the laboratory methods (with the use of ordinary chronaxymeters). Therefore, the clinical picture of functional restoration has a leading role in evaluating the progress of regeneration.

The subsequent electrophysiologic examination of the patient in April, 1947, established further restoration of excitability of *m. deltoideus*, *m. biceps* and *m. supraspinatus* both to the galvanic and faradic stimulation. These results are given in the Table I.

(Examination was carried out on a usual electrodiagnostic apparatus in the Institute of Physiotherapy, Moscow.)

The following observation is also of some interest. *M. serratus anterior sin.* gave before the operation chronaxy of 0.16G at a rheobase of 60v; 14 months after the operation the chronaxy was 0.28G at a rheobase of 65v. Both times only the lower segments of the muscle were studied. We consider that this phenomenon could be explained by the fact that *m. serratus anterior* is sometimes innervated by the intercostal nerves, as our anatomical studies, presently in progress, have shown. Roentgenologic control of the osseous apparatus of the arm—before and after operation—established some diminution in the Sudeck's atrophy of the bones.

On the basis of our results, we feel justified in recommending the use of *n. thoracalis longus*, *nn. thoracalis anterior*, *rami tricipitis* of *n. radialis* (after proper physiologic examination) for neurotization of *n. suprascapularis*, *n. museulocutaneus* and *n. axillaris*. We regard this combined transplantation as a typical one in treatment of Erb's paralysis, in cases where the corrective operation *in situ* above the clavicle cannot be carried out. We believe that, in cases of upper Erb's paralysis, partial loss of the function of *m. pectoralis* and *triceps* following section of two *rami tricipites* and two *nn. thoracales anterior* used for neurotization cannot make the function of the whole limb essentially worse. A part of the innervation of *m. pectoralis* and of *m. triceps* will be preserved, and, with proper exercise, the strength of these muscles can be restored, as we have seen in our patient. It is somewhat harder to evaluate the question of whether sectioning *n. thoracalis longus* is admissible. While performing neurotomy distally from emergence of the fibers to two upper indentations of *m. serratus anterior* we do not entirely deprive this muscle of its innervation. However, instead of *n. thoracalis longus*, *n. thoracalis posterior* can be employed for the purpose. The use of the latter nerve, according to Foerster, is already strongly indicated because exclusion of *m. latissimus dorsi*, as an antagonist, will aid restoration of the function of *m. deltoideus*.

On the basis of our experience with isolated injuries of the supraclavicular nerve, we regard its regeneration as important for the restoration of function of abduction in the shoulder joint and therefore its neurotization as desirable.

In our method of operation three physiologically important nerves: *n. suprascapularis*, *n. axillaris* and *n. musculocutaneus*, obtain fresh neurotizers with a good regenerative potential, and this, as our case well demonstrates, is of great importance for success in restitution of the function. In our opinion, the use of a freshly cut healthy nerve for the purpose of neurotization is a matter of great importance, since regeneration leads immediately to neurotization of the degenerated nerves. It is also important that in the zone of healthy normal tissues outside of the area of trauma, "ideal" conditions will be found for regeneration. Ordinarily, when in the case of gun shot wound, the injured nerve is sutured *in situ*, the regenerative process takes place twice. The first regeneration results in formation of a neuroma; the second regeneration takes place after the severed ends of the nerve are refreshed and sutured together, and only the latter results in neurotization. It is known, that with the passage of time after injury the capacity of axon and its cell to regenerate diminishes

(Foerster, Egorov, Chibumacher, Bondarchuk). Therefore, it is possible, that neurotization with fresh nerves, by our modification of treatment of Erb's paralysis, even when performed a considerable time after injury, will give better results than direct suturing after resection of the neuromas.

SUMMARY

In the Erb type of paralysis, with considerable destruction of the upper primary fasciculus of the brachial plexus, where a corrective operation (restorative) cannot be technically carried out *in situ* with any hope of success, neurotization of the peripheral end of *n. suprascapularis* with *n. thoracalis longus*, of the peripheral end of *n. musculocutaneus* with *n. thoracalis anterior*, and of the distal end of *n. axillaris* with *rami tricipitis* of *n. radialis* was performed. Prior to such an operation it should be established, by clinical and electrophysiologic examination, that nerve donors have sufficient potential capacity as neurotizers, and that nerve recipients are completely degenerated. Electrophysiologic examination should be repeated during the operation, and only after that the corresponding implantations can be performed. Under the above conditions, Erb's paralysis, with extensive trauma, indicates triple neurotization below the clavicle of the degenerated nerves according to the scheme presented, provided the tissues beyond the zone of cicatrization are normal.

REFERENCES

- ¹ Aird, and H. C. Naffziger: Regeneration of Nerves after Anastomosis of Small Proximal to Larger Peripheral Nerves. Arch. of Surg., 1939.
- ² Babchin, I. S.: Operative Treatment of Extensive Injuries of the Plexus Brachialis. Handbook—"Brain Tumors and Problems of Neurosurgery." Part II. Rostov. 1936. (Russian)
- ³ Bondarchuk.: Report at 25th Meeting of Surgeons S. S. S. R. Moscow, October 1946. (Russian)
- ⁴ Egorov, B. G.: Report at the Conference of the Surgeons of the Hospitals RSFSR. January 1946. (Russian)
- ⁵ Feiss, H. O.: On the Fusion of Nerves. Quart. J. Exper. Physiol. 5: 1-30, 1912.
- ⁶ Foerster, O. Burke: Foerster's Handbook of Neurology Erganzungsband, 1929.
- ⁷ Kennedy, R.: Experiments of the Restoration of Paralyzed Muscles by Means of Nerve Anastomosis. II. Anastomosis of the Nerve Supplying Limb Muscles. Phil. Tr. Roy. Soc. London S. B., 205: 27-76, 1914. Abstr. Proc. Roy. Soc. London, S. B., 87: 331-335, 1914.
- ⁸ Kilvington, B.: An Investigation on the Regeneration of Nerves with a View to the Surgical Treatment of Certain Paralyzes. Brit. M. J., 1: 935-940, 1905.
- ⁹ Chibumacher: Report at 25th Meeting of Surgeons S. S. S. R. Moscow, 1946. (Russian)
- ¹⁰ Vulpius, O., and A. Stoffel: Orthopadische Operationslehre 2 Auflage Stuttgart Euke, 1920.

Surgical Division
Blagushin's Hospital
Moscow, U. S. S. R.