

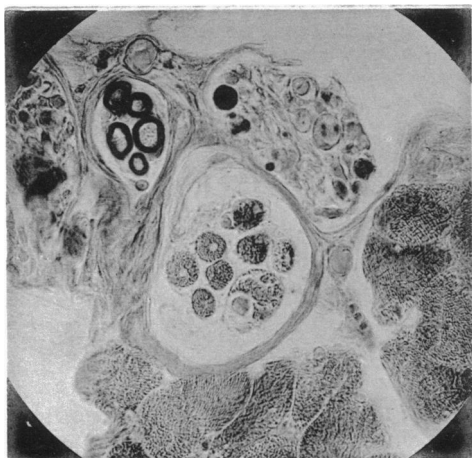Fig. 13.

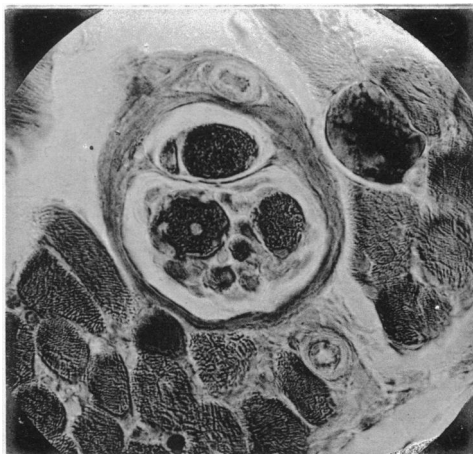


Fig. 14.

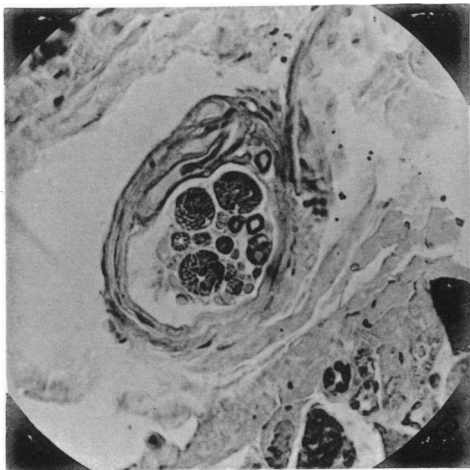


Fig. 15.

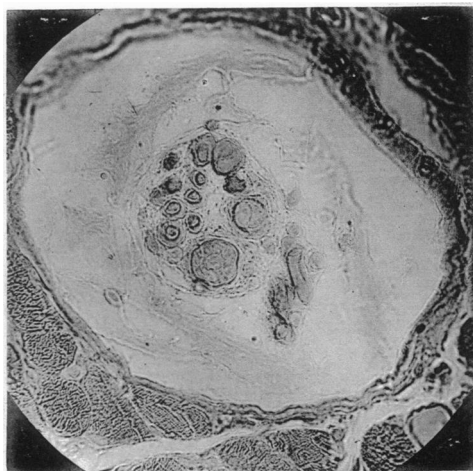


Fig. 16.

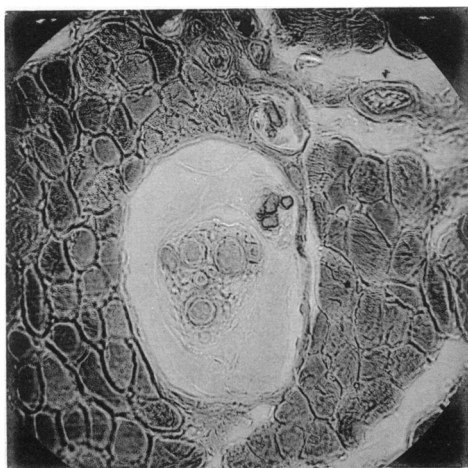


Fig. 17.

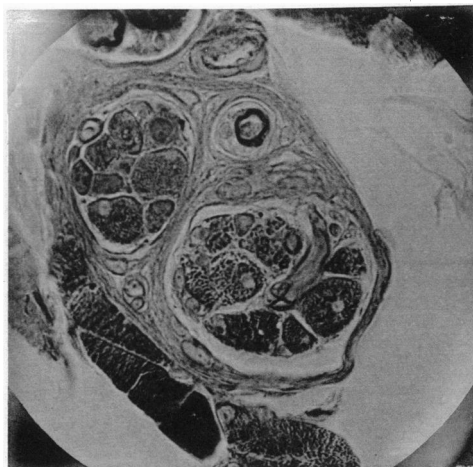


Fig. 18.

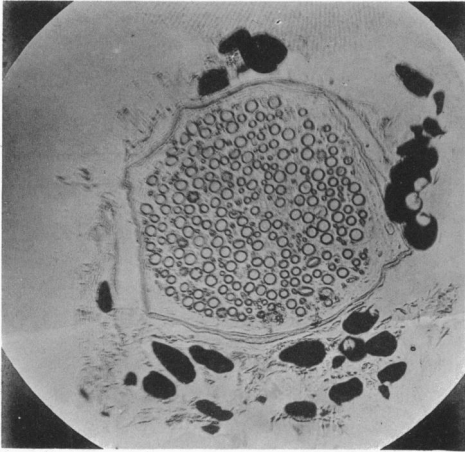


Fig. 7.

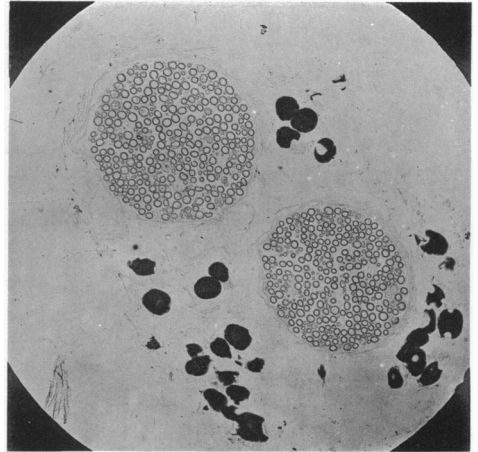


Fig. 10.

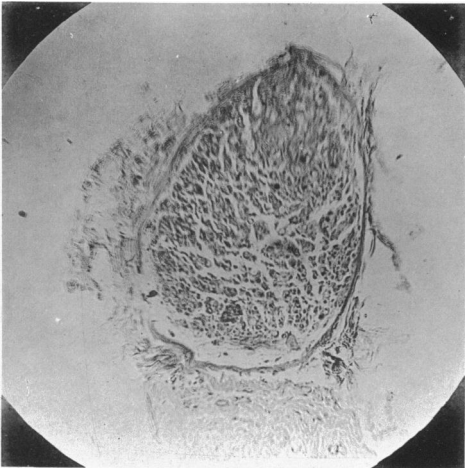


Fig. 8.

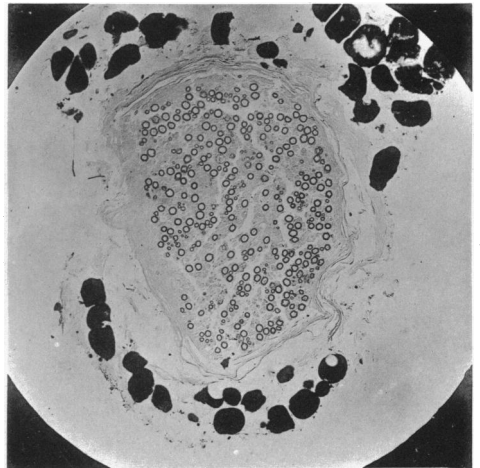


Fig. 11.

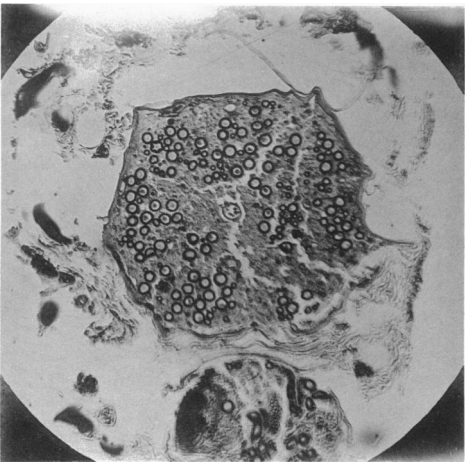


Fig. 9.

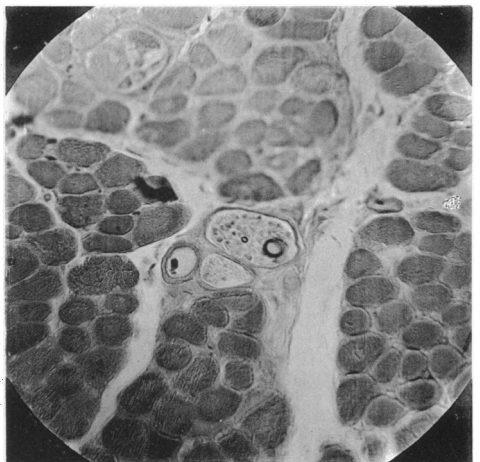


Fig. 12.

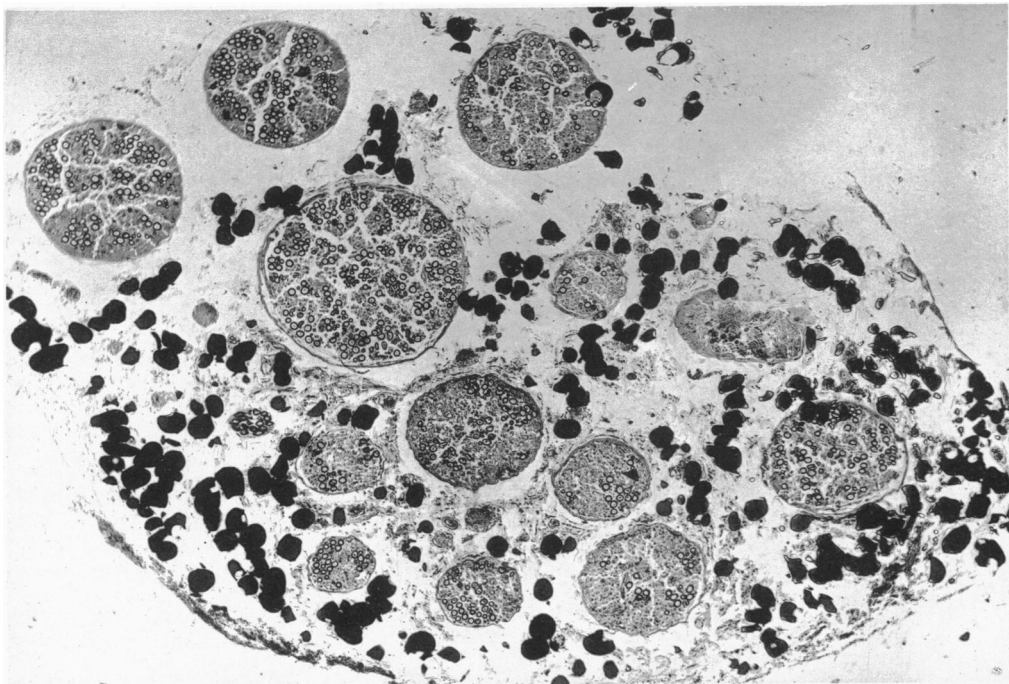


Fig. 1.

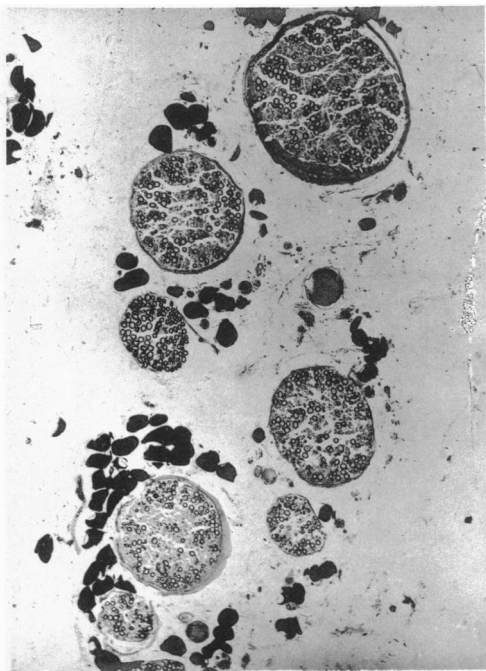

Fig. 2.

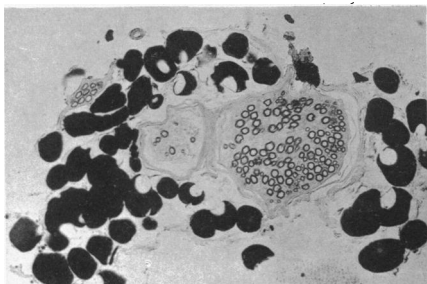


Fig. 3.

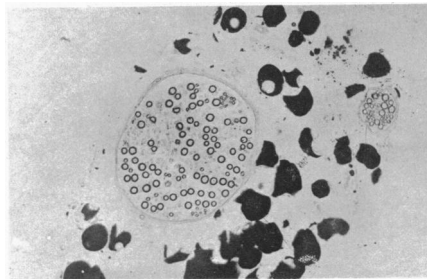


Fig. 4.

Fig. 5.

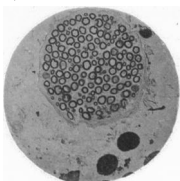
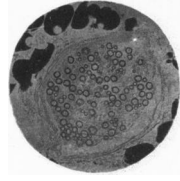


Fig. 6.



ON THE ANATOMICAL CONSTITUTION OF NERVES OF SKELETAL MUSCLES; WITH REMARKS ON RECURRENT FIBRES IN THE VENTRAL SPINAL NERVE-ROOT. BY C. S. SHERRINGTON, M.A., M.D., F.R.S., *Lecturer on Physiology, St Thomas's Hospital, London.* (Plates V. VI. VII.)

- I. Introductory.
- II. Methods employed in the present enquiry.
 1. Comparison of the nerve-fibres in ventral (anterior) spinal roots with the fibres composing the nerves of limb-muscles.
 2. Comparison of the nerve-fibres in dorsal (posterior) spinal roots with the fibres composing some cutaneous and articular nerves.
 3. Removal from peripheral limb-nerves of all fibres arising from the spinal cord, the fibres arising from the spinal root ganglia being left intact.
 - i. Question of the existence in the dorsal (posterior) spinal root of fibres having origin in the spinal cord.
 - ii. Are the myelinate fibres remaining sound in the muscular nerves recurrent and derived from adjacent peripheral nerves?
 - iii. May the myelinate fibres remaining be attributed to regeneration?
 - iv. Are any of the myelinate fibres derived from the sympathetic?
 - v. Are any of them of peripheral origin, i.e. possessed of a peripheral trophic centre (nerve-cell)?
- III. Anatomy of those nerve-fibres to skeletal muscles which spring from cells of the spinal root-ganglia.

1. Number.
 2. Size.
 3. Relative numbers of the different sizes.
 4. Arrangement in the nerve-trunks.
 5. Distribution in the muscles.
 6. The "muscle-spindle."
- IV. Pale fibres in the nerves of skeletal muscles.
 - V. The muscular nerves in an anencephalous amyelous fœtus.
 - VI. Remarks on the physiological condition of the nerves and muscles from which motor nerve-fibres have been removed.
 - VII. Remarks on recurrent fibres and scattered ganglion cells in the ventral (anterior) spinal nerve-roots.
 - VIII. Summary of conclusions.
- Explanation of figures.

I. Introductory.

Anatomical evidence of the existence of afferent fibres¹ in the nerves distributed to skeletal muscles remains but scanty. Some authorities question the validity of the sparse observations which supply it. The actual insufficiency of the observed facts was recently pointed out to me by Dr Waller, who in connection with his own experiments on muscular effort² had lately had the subject under consideration. Still more recently the same point was pressed upon me by laboratory experience of my own, in the course of observations upon the "knee-jerk."

In these latter I succeeded in determining³ that the reflex arc with which the "knee-jerk" is connected possesses *afferent* as well as *efferent* fibres in the nerve of the *vastus medialis*⁴ (*vastus internus*) muscle; and further that the branches given by the sciatic nerve to the hamstring muscles convey from those muscles centripetal impulses which can greatly modify the "jerk"⁵. These nerves *must* therefore contain afferent fibres. The questions toward answering which this Paper is primarily directed are: (i) among the fibres in the nerves of *vastus medialis* and of the

¹ Several of the observations detailed here were summarised in a communication made to the Brit. Med. Assoc., Newcastle, August 1893 (*Brit. Med. Journal*, p. 235, II. 1893).

² *Brain*, 1891, p. 236.

³ *Brit. Med. Journal*. March 12th, 1892. *This Journal*, XIII. p. 666.

⁴ The anatomical nomenclature recommended by the Committee appointed at the instance of the *Anatomische Gesellschaft* is followed in this Paper.

⁵ *Proc. of the Roy. Soc.*, Feb. 9th, 1893.

ham-string muscles which are the afferent? (ii) does the constitution of the nerve of *vastus medialis* differ appreciably from that of the nerves of other divisions of *quadriceps femoris* which are not so essentially connected with the "knee-jerk"?

II. Methods employed in present investigation.

To determine what fibres other than those of the ventral spinal roots enter into the composition of the nerve-trunk supplying a skeletal muscle, e.g. *vastus medialis*, several anatomical methods may be followed. I have relied almost exclusively on four:

1. comparison of the fibres of certain spinal roots with those of the corresponding peripheral nerve-trunks entering the muscle and the skin respectively;
2. the alteration of composition of the nerve-trunks induced by degeneration of spinal roots contributing to it;
3. the examination of the nerve-trunks of muscles where the spinal cord has been arrested early in its development;
4. the search for end-organs within the muscular tissue.

1. *Comparison of the structure of the ventral (motor) roots of the 6th, 7th and 8th post-thoracic spinal nerves of the monkey, and of the 7th, 8th and 9th of the cat with the nerve-trunks of the hamstring and tibialis posticus muscles.*

In the nerve-trunks to these muscles the proportion of smallish fibres, i.e. 2μ — 12μ , to large fibres, i.e. above 18μ , is obviously higher than in the motor roots of the spinal nerves which innervate the muscles. Therefore either (i) some of the large fibres of the roots become smaller as they pass to the nerve-trunk entering the muscle, or (ii) to the fibres contributed by the motor roots a number of other smallish ones are added. Regarding the first possibility the diameter of the motor nerve-fibre has been shown to remain unaltered throughout its course (Schwalbe¹, Kölliker), except where branching occurs. Now Mays² could not find any branching of the nerve-fibres in the macroscopic nerve-trunks in the frog. Myself I have, searching for it in nerve-trunks of the cat and monkey, never seen it, apart from microscopic intra-muscular nerve-twigs, where it is of course of common occurrence. Regarding the

¹ *Ueber die Kaliberverhältnisse der Nervenfasern.* (Leipzig), 1882.

² *Zeits. f. Biologie*, xxxi. p. 365, 1886. By macroscopic nerve-trunks I mean those large enough to be easily dissected by the scalpel in cat and monkey.

second of the above possibilities the smallish fibres in the muscular nerves correspond in size with a large proportion of the fibres in the corresponding dorsal (sensory) roots.

A result of the comparison is therefore the suggestion that of the nerve-trunks supplying these muscles a number of smallish fibres of from 2μ — 12μ are contributed by the sensory spinal roots.

From comparison between other ventral (motor) spinal roots and their muscular branches this result cannot be obtained so readily. The other motor roots in the region contain a far higher proportion of small fibres (Reissner¹, Gaskell², Siemerling³); these Gaskell has shown to enter for the most part the white *rami communicantes* of the sympathetic. It would however be difficult to accurately deduct those entering the sympathetic from the total existing in the motor root; and this deduction would have to be made before comparing the muscular trunks with the roots themselves.

2. *Comparison of the fibres of the internal saphenous nerve, of the cutaneous division of the musculo-cutaneous of the leg, of the external saphenous and of the plantar digital trunks with the fibres of the dorsal (sensory) roots of the 3rd—9th post-thoracic spinal nerves in the monkey and cat.*

In these cutaneous nerves the largest fibres in fresh preparations measure 17μ , in osmic and alcohol preparations 16μ . On the other hand, in the dorsal (sensory) spinal roots both proximal and distal to the root-ganglion exist a large number of fibres of more than 16μ diameter, e.g. many are 20μ and more in osmic and alcohol preparations. These large fibres of the sensory roots must therefore either, (i) become diminished in size before entering the cutaneous trunks above named, or (ii) their largest fibres must be distributed in nerves which are not cutaneous and be destined for structures other than cutaneous. The destinations remaining available for them are chiefly (i) articular and (ii) muscular. As to articular nerves in the first place they are very small, and could not contain all the large fibres of the sensory roots even if they consisted of them entirely; in the second place, I find the nerve to the hip joint (from the obturator) in the cat, and the nerve to the shoulder joint (from circumflex) in the monkey, contain no fibres of more than 14μ .

¹ *Archiv für Anatomie*, 1862, p. 125. Also Luchtmans, *Utrechtsche genootschap*, 1866, p. 69.

² *This Journal*, VII. p. 1, 1886.

³ *Anat. Untersuch. über die menschlichen Rückenmarkswurzeln*, Berlin, 1887.

They resemble in this character small cutaneous nerves. The remaining possibility becomes therefore a strong probability, namely, that the large fibres of the dorsal (sensory) spinal root are mainly distributed to the nerves of the skeletal muscles. Schwalbe (*op. cit.* p. 43) has, however, found that the fibres in the cutaneous nerves that cross the dorsal lymph-sac of the frog do actually diminish measurably in diameter within these nerve-trunks, although they do not branch within them. He remarks the impossibility of sufficiently following the fibres of large mammalian nerve-trunks to permit of the same fact being examined in them. The likelihood remains that something of the same progressive diminution may occur in the sensory fibres of mammalian cutaneous nerves, and in the sensory fibres (if existent) in the nerves of mammalian muscles. This possibility weakens the value of the comparison made. A further method (method 2) had therefore to be resorted to.

3. *Removal from the peripheral limb-nerves of all fibres springing from the spinal cord, the fibres arising from the spinal root-ganglion remaining intact.*

My observations have been on three monkeys and on nineteen cats. For two more cats I have to thank the kindness of Mr Langley and Mr Anderson, who performed the root sections in the course of their experiments upon the abdominal sympathetic. I have to thank Mr W. Legge Symes for assistance in a number of the dissections.

The method of operation I have employed may be briefly given here.

The spinal theca having been freely exposed for a sufficient length in the vertebral canal is opened longitudinally in the middle line. The spinous processes of the vertebræ it is unnecessary to remove, and though in my earlier operations they were removed, in all the later they were left. The cut edge of the dura mater on the side on which the nerve-roots are to be severed is seized with fine forceps: the nerve-roots are then easily found and laid bare. The roots of three to six consecutive post-thoracic nerves are severed with the scissors; both the ventral and the dorsal roots are included in the section, the latter being cut the earlier, and both nearer to the spinal cord than to the spinal ganglion. In the case of almost every nerve-root of the lumbar enlargement the root is long enough to allow a piece of it to be excised, and this was done. The ganglia should not be seen at all during the operation. To ensure complete severance of all the filaments of each ventral (anterior) root it is well to slip a thread under it before cutting it; then when the root has been cut the thread can be lifted away

without hindrance; if some filament has escaped section it is caught, lifted and exposed for cutting by the thread when that is raised. The traumatic disturbance following the operation lasts about five days. On the first day it may be necessary to evacuate the urinary bladder. The time allowed for degeneration has varied between 13 and 190 days.

To obtain from the nerve-trunks transverse sections in which microscopic examination can at once distinguish between all degenerate and all sound fibres, and that at the same time offer little complication from regenerating fibres, the best period of degeneration is from the end of the 4th week to the end of the 6th. The observations of sound fibres scattered among entirely degenerate ones is preferable to that of scattered degenerate among sound. It is so for the reasons, that fibres in advanced degeneration are not always readily distinguishable from connective tissue especially where the connective tissue is laden with myelin *débris*; that *post mortem* and accidental damage incidental to some dissections are liable to make a few of the nerve-fibres appear degenerate in places (the acidity developed in muscles *post mortem* quite rapidly seems to slightly alter the myelinate fibres in the nerve-twigs); that a few small degenerate fibres can be rapidly removed from a nerve-trunk without leaving any anatomical mark recognisable with certainty.

When the animal was finally examined the plan adopted was (i) to stimulate with the faradic current the muscular nerves on the normal and on the operated sides; (ii) to tease out in the fresh condition portions of the various nerves and muscles and examine them with the microscope; (iii) to fix with osmic acid, and with Marchi's reagent, pieces of the nerves and muscles; the fixed preparations were afterwards divided into portions of which some were teased completely, others microtomed into serial sections by the paraffin method. The distal portions of the spinal roots were microscopically examined to ascertain that the severance of them had been complete.

i. *Question of the existence in the dorsal (posterior) spinal root of fibres having origin in the spinal cord.*

At first sight it might appear superfluous for the present purpose to sever the dorsal (posterior) spinal roots as well as the ventral (anterior) and in two early experiments I was content with cutting ventral roots alone. The following considerations subsequently induced me to sever both roots, the dorsal of course well proximal to its ganglion.

1. Vejas¹ and Joseph² assert that after lesion of dorsal (sensory) root proximal to ganglion a number of fibres degenerate on the peri-

¹ *Beit. z. Anat. u. Phys. d. spinal Gangl.*, Munich, 1883.

² *Arch. f. Anat. u. Phys., Phys. Abth.*, p. 296, 1887.

pheral (ganglionic) side of the lesion. Joseph asserts these can be traced through the ganglion and into the peripheral nerve itself. He supplies no description or figure of the fibres. The observation is opposed to the original one by Waller, which was confirmed by Bernard and others, and has been recently again by Kahler¹ and by Singer and Münzer².

2. Ramon y Cajal³, v. Lenhossek⁴, and van Gehuchten⁵ have discovered in the chick that axis-cylinder processes pass from certain cells in the ventral cornu of the cord to emerge with the fibres of the dorsal (sensory) spinal roots. They describe the cells as "motor" and very sparse. No observer has yet found them in the mammalian cord, and Kölliker⁶ has especially sought there for them.

My own observations regarding the existence of such fibres in the roots of the lumbosacral nerves of cat and monkey are as follows:

(1) *Monkey*. Dorsal (posterior) roots of 4th, 5th, 6th, 7th, and 8th post-thoracic nerves severed close to spinal cord. 9 days allowed for degeneration. The portions of the roots attached to the ganglia carefully examined fresh and after osmic fixing. Not a single degenerate fibre detected; small fibres and large appeared, all of them absolutely intact.

(2) *Cat*. Similar experiment, with similar result, on 5th, 6th, 7th, 8th, and 9th post-thoracic nerves.

(3) *Cat*. Both roots of 4th and 5th post-thoracic nerves severed close to ganglion. Twenty-three days allowed for degeneration. In the spinal portions of these roots not a single nerve-fibre of less than 12μ was discoverable in a sound condition; all were obviously degenerate. A small number of large fibres (20μ) were not sufficiently altered to leave it certain whether they were degenerate or sound.

(4) *Cat*. 4th, 5th, 6th, 7th, 8th, and 9th post-thoracic spinal ganglia (right side) excised with adjoining bits of ventral roots. Thirty-three days allowed for degeneration. No motor reactions on applying maximal currents to femoral, obturator or sciatic nerves. The spinal cord ends of each of the six dorsal (posterior) roots was sufficiently long to divide into three pieces; one of these was teased fresh, one after fixation in osmic, the third after osmic fixation was cut into serial sections. The whole thickness of each root was thus examined. No large but a number of small fibres appeared intact.

(5) *Cat*. The 4th, 5th, 6th, 7th, and 8th post-thoracic spinal ganglia of

¹ *Prager medic. Wochenschr.* p. 302, 1884.

² *Denkschr. d. k. Akad. d. Wiss.*, Vienna, LVII. p. 570, fig. 1, 1890.

³ *Anat. Anzeiger*, 1890, p. 112.

⁴ *Anat. Anzeiger*, 1890, p. 360.

⁵ *Anat. Anzeiger*, 1893, p. 215.

⁶ *Handb. d. Gewebelehre.* 1893, vol. II.

the right nerves excised together with the adjoining part of each corresponding ventral (anterior) root. Forty-two days allowed for degeneration. No motor reaction on stimulating anterior crural, obturator or peroneal trunks. Flexion of toes on exciting tibial (internal popliteal) nerve. 9th post-thoracic ventral root on left side gave flexion of digits. Plexus rather post fixed. No large but a number of small fibres appear intact.

In (4) at first sight it seemed that all the fibres were in advanced degeneration, broken down, and overlaid by lines of cells containing granules of fatty and other nature. Further examination revealed great numbers of extremely delicate myelinate fibres varying from 1μ to 3.5μ in diameter. These possessed perfect continuity and were clearly not degenerating. They were scattered throughout the whole thickness of each root. They much resembled young regenerating fibres in:—(a) the excessive thinness of the myelin-sheath, (b) the inconspicuous character of the nodes of Ranvier, (c) the frequency of occurrence in couplets and triplets, (d) the somewhat tortuous course, (e) the appearance of being bedded in or on pale embryonic somewhat flattened "protoplasmic" fibres, such as described by Neumann, and by Howell and Huber, to arise by regeneration in the peripheral end of a severed nerve independently of reunion with the central end. Inasmuch as the spinal ganglia had in this experiment been in each case actually *excised* it is difficult to understand how regeneration of any root-fibres could have occurred, unless as Bowlby has said by autochthonous development. However in the peripheral nerves which were also exhaustively examined I failed to find any regenerating myelinate fibres.

In (5) the portions of dorsal (posterior) roots attached to the cord showed the same condition as in previous experiment, modified in two points only. There were as follows:

(1) At 33rd day, i.e. experiment (4), nine large myelinate fibres (12μ — 20μ) existed in the series of the six roots which were in places so little altered I hesitated as to their being degenerate. These fibres might be the sparse "motor" axis cylinders of Cajal. At 42nd day, i.e. present experiment, all doubt about them was removed. Every fibre of more than 4μ diam. in every root was broken up.

(2) Minute myelinate nerve-fibres of unbroken course were present and seemed more obvious, more numerous and larger than in previous experiment. They amounted probably to several thousands in the five roots. I could not find any measuring a full 4μ .

Those dorsal (posterior) roots with which I here deal conform therefore perfectly with the original observations by Waller,

i.e. no fibres in them pass from the spinal cord outward along the root to or through the spinal ganglion; all pass toward the spinal cord.

I cannot explain the presence of the minute myelinate fibres in the spinal portion of the dorsal (posterior) root five weeks after excision of the ganglion. In the course of the second and third weeks I have not found them. Their existence is beyond question, as also the completeness of excision of the ganglia, which were preserved at the time of operation. I reserve discussion of their origin until a subsequent paper.

After complete section of all the ventral (motor) spinal roots and of the corresponding dorsal (posterior) roots (proximal to spinal ganglia) contributing fibres to the nerve-trunk of a skeletal muscle, a large number of the myelinate fibres in the nerve-trunk still remain intact.

This fact has been ascertained for the following muscles: vastus lateralis, femoralis, vastus medialis, rectus femoris, sartorius, obturator externus, biceps flexor cruris, semitendinosus, semimembranosus, gracilis, pectineus, adductor brevis, tibialis anticus, extensor longus hallucis, extensor longus digitorum pedis, peroneus longus, extensor brevis digitorum pedis, soleus, gastrocnemius, tibialis posticus, flexor longus digitorum pedis, abductor hallucis, the second plantar interosseous muscle, psoas, pyramidalis, obliquus internus abdominis, rector spinæ.

The fibres remaining intact in these nerves arise in cells of the ganglion of the dorsal (sensory) spinal nerve-root.

When all the ventral (motor) roots which can possibly contribute fibres to the nerve-trunk have been severed and allowed to proceed to full degeneration, and when the operation has included section of the dorsal (posterior) roots proximal to their ganglia, there remain, in addition to the above-mentioned source of origin in the spinal ganglion, only three further possible sources for them. These must now be considered.

ii. *The fibres may be recurrent and derived from other peripheral nerves.*

It will be remembered that this supposition has been urged to account for the pair of undegenerate myelinate fibres found by Sachs¹

¹ Reichert u. Du Bois Reymond's Archiv, 1874, p. 645.

in the sartorius muscle after degeneration of the 7th and 8th motor spinal roots: Sachs' experiments do not meet the objection. I have endeavoured to test it as applied to my own experiments by the following means:

Cat. Spinal theca opened and ventral (anterior) roots of 3rd, 4th, 5th, 6th, 7th, and 8th post-thoracic nerves (right) cut. 28 days allowed for degeneration. Many sound myelinate fibres existed in nerve to *tibialis anticus* and *peroneus longus*. But the series of roots cut had been sufficiently extensive to exclude from nerve-trunks near middle of series the possibility of recurrent fibres, e.g. the fibres in nerve to *tibialis anticus* would have to come from 2nd lumbar or 2nd sacral, which is beyond credibility.

Cat. Vertebral canal opened and spinal ganglia with dorsal and ventral roots of 3rd, 4th, 5th, and 6th, post-thoracic nerves (right) excised. 26 days allowed for degeneration. Nerves to *vastus medialis*, *vastus lateralis*, *rectus femoris*, *sartorius*, and *psoas* contained no myelinate fibres. But recurrent fibres from adjacent branches of obturator, sciatic, remained intact (there were more than 300 sound fibres in obturator trunk, and nerve to *tibialis anticus* showed no obvious degeneration).

Cat. Femoral (ant. crural) trunk cut at emergence from *psoas* muscle. Central stump 21 days later showed no degenerate fibres; in peripheral stump and branches to *quadriceps* I could find no myelinate fibres that were sound.

Cat. Sciatic trunk cut above *quadratus femoris*. 21 days allowed for degeneration. No degenerate fibres detected proximal to trauma, no sound fibres detected distal to it. Similar experiment; union prevented by turning cut ends of trunk up and down. 88 days allowed for degeneration. No sound myelinate fibres in distal trunk and branches.

I conclude therefore that from the muscular nerves, the subject of these experiments, recurrent fibres are absent. The nerve-fibres remaining sound in these muscular nerves after degeneration of the ventral (anterior) spinal nerve-roots cannot therefore be recurrent.

iii. *May the fibres be attributed to regeneration?*

This is negatived by several facts. 1. The time allowed in some experiments was too short to permit of myelinate fibres by regeneration. Thirteen and eighteen days after section of the roots, the fibres in the nerves appeared perfect in size and number amid the remaining degenerate ones. 2. Regenerated fibres seen even 74 days after section of anterior crural trunk were strikingly different in number and

appearance from those left after section of the roots proximal to the ganglia.

Experiment. Cat.

Femoral (Anterior crural) trunk severed at Poupart's ligament. Final examination made on 74th day from operation. In the muscular branches of the nerve were a number of thinly myelinate fibres imbedded in fibrillated tissue. The upper nerve to *sartorius* consisted of two bundles; in the larger 156 myelinate-fibres, in the smaller 39. The corresponding nerve on the unoperated side contained 1314 fibres. The similar nerve in an experiment in which 3rd, 4th, 5th, and 6th, post-thoracic roots had been severed proximal to the spinal ganglia for 39 days contained 514 fibres, as against 1183 in the corresponding nerve of the sound side. Moreover the fibres in the nerves 74 days after section of the nerve-trunk measured on an average less than 3μ diam., a great number of them less than 2μ ; the largest fibre discoverable in the nerve to *sartorius* 5.6μ . But of the fibres in the nerve to *sartorius* after section of the spinal roots proximal to ganglia more than a half measured above 8μ . In the nerve to *rectus femoris* the largest regenerating fibre measured 5μ , and in the whole trunk of the regenerating anterior crural the very largest fibre measured only 7.5μ . Further differences between the newly regenerated fibres and the persistent sensory fibres lies in the thin myelin sheath of the former, and in the absence from the smaller of the new fibres of clear nodes of Ranvier; the larger regenerating fibres, e.g. 4μ — 6μ , do however possess distinct, though not well-developed, nodes of Ranvier. When the regenerating trunk is examined in transverse section the fibres in it are seen to be mostly grouped in pairs, triplets, &c., and to be then contained in a common sheath and imbedded in a homogeneous substance. In longitudinal view it is frequent for a pair of fibres each of, e.g. 3μ , to lie imbedded together in a band of homogeneous material about 8μ wide and possessed of a distinct fine sheath. In such fibres I could find no distinct nodes of Ranvier. Further, the course of the fibres at the seat of trauma is tortuous and slightly so in the very regenerating trunks below.

It will be gathered therefore that young regenerating fibres offer many points of difference from the fully-developed fibres of the normal nerves. On the other hand, the fibres found in the muscular nerves after degeneration of the motor spinal roots resemble in every respect the normal fully-developed fibres. They cannot be regarded as attributable to regeneration.

iv. *The fibres under consideration may be derived, at least in part, from the sympathetic system.*

This question is answerable on the following lines.

(1) Nearly a half of the fibres exceed 12μ in diameter, whereas only a few of the very largest myelinate fibres of the sympathetic attain that diameter (Langley¹).

(2) In a cat twelve days after extirpation of the 5th, 6th, 7th, and 8th post-thoracic ganglia of the sympathetic prevertebral chain I have failed to find any degenerate myelinate fibres after examining the following nerves: n. musculo-cutaneus on the dorsum of the foot; 1st and 2nd plantar digitals; nerves to *flexor longus digitorum*, *rectus femoris*, *vastus medialis*, *sartorius*, *psaos magnus*, *gracilis*, *tibialis anticus*.

(3) After extirpation of the spinal ganglia, together with the adjacent portions of the dorsal (sensory) and ventral (motor) spinal roots, no myelinated fibres remain sound in the peripheral nerves of the limb. In these excisions it is important to remember that a few of the cells of the spinal ganglion usually lie outside the naked eye limits of the ganglion even to a millimeter or so beyond (i.e. distal to) the point at which the primary dorsal division of the nerve is given off. If these outlying cells be not included in the ablated portion, a few of the sensory fibres will persist in the nerve-trunks and many of them will be indistinguishable from myelinate fibres of the sympathetic system.

I have already instanced an experiment in which after the 3rd, 4th, 5th, and 6th post-thoracic ganglia and roots were excised no myelinate fibres escaped degeneration in the anterior crural nerve and its branches. Similarly, 21 days after excision of the spinal ganglia and roots of the 5th, 6th, 7th, 8th and 9th post-thoracic nerves I found no fibres undegenerated in the following: n. to *tibialis anticus*, *peroneus longus*, *tibialis posticus*, lateral head of *gastrocnemius*, *biceps flexor cruris*, *semitendinosus*, *semimembranosus*, lower end of *adductor magnus*, n. *saphenus*, *externus*, n. *musculo-cutaneus*.

Again in Monkey.

Macacus rhesus ♂ 2nd, 3rd, 4th, and 5th post-thoracic spinal ganglia and roots of the right side excised. 28 days allowed for degeneration.

Examination proved the plexus to be moderately post-fixed, e.g. the 6th lumbar nerve gave a small twig to the obturator nerve. A few fine myelinate fibres found in the trunks of the 2nd, 3rd, 4th, and 5th lumbar nerves a few millimeters outside their points of emergence from the intervertebral foramina; cf. *infra* p. 224.

In the anterior crural trunk, where it lay embedded in the belly of *psaos* and consisted of the usual three large bundles, there existed not a single myelinate fibre.

¹ *Phil. Trans. Roy. Soc.* Vol. CLXXXIII. B, p. 118, 1892.

In the nerve from the 4th and 5th lumbar trunks to psoas muscle not a single myelinate fibre.

In the nerves to *rectus femoralis*, to *vastus medialis* (internus), to *femoralis*, to *sartorius*, and to *vastus lateralis*, no myelinate fibres.

In the internal saphenous nerve halfway down the thigh, no myelinate fibres.

In the obturator trunk in the pelvis, consisting of 3 large bundles			
in the smallest bundle	15 fibres,	scattered in sclerotic tissue.	}
in the largest	„ 133 fibres,	„ „ „	
in the third	„ 108 fibres,	„ „ „	
In nerve to <i>obturator externus</i> muscle	72 fibres	in sclerotic tissue.	}
In a nerve to <i>adductor magnus</i>	„ 18 fibres	„ „	
„ „ lower end of <i>gracilis</i>	„ 43 fibres	„ „	
„ „ <i>adductor brevis</i>	„	no myelinate fibre.	
„ „ upper part of <i>adductor longus</i>		no myelinate fibre.	

* These fibres traceable to 6th lumbar.

v. *Have any of the myelinate fibres in the limb-nerves a trophic centre somewhere distal to the cells of the spinal root-ganglion?*

This possibility may appear remote. v. Lenhossek and Retzius have however found in the skin of the earthworm sensorial nerve-cells which are believed to be homologues of cells of the spinal root-ganglion of vertebrates. Also Joseph¹ asserts that in the 2nd cervical nerve some fibres of the dorsal (posterior) root have their trophic centre distal to the spinal root-ganglion. The possibility must therefore be considered, and I have examined it as follows.

Cat (A). The spinal ganglia of 5th, 6th, 7th, and 8th post-thoracic nerves of the right side excised together with the adjoining ventral (anterior) roots; 39 days allowed for degeneration. Nerves to *tibialis anticus*, *peroneus longus*, *extensor digitorum longus* examined and not found to contain any sound myelinate-fibres.

Cat (B). The spinal ganglion and adjoining ventral roots of the 4th, 5th, 6th, 7th, 8th, and 9th post-thoracic nerves excised; 30 days allowed for degeneration. Plexus of prefixed type. Nerves to *sartorius*, *adductor magnus*, *gracilis*, *tibialis anticus*, *gastrocnemius*, *tibialis posticus*, and *flexor brevis digitorum* examined; no sound myelinate fibres found in them.

In obturator nerve-trunk just inside pelvis one sound myelinate fibre existed; it lay close under the connective tissue sheath of one of the large nerve-bundles; it was 5 μ diam.

¹ *Archiv f. Anat. u. Phys., Phys. Abth.* p. 296, 1887.

In the segmental nerve-trunks a few millimeters outside the intervertebral foramina some myelinate fibres existed in both the experiments. All these fibres were quite small, the largest measuring 6μ diam. They were very few in number. In 4th lumbar trunk, none. In 5th lumbar (A) two fibres, (B) four fibres. In 6th lumbar (A) three fibres, (B) two fibres. In 7th lumbar (A) eleven fibres, (B) eight fibres. In 8th post-thoracic trunk (A) nine fibres, (B) thirteen fibres. In 9th post-thoracic trunk, three fibres. In the ten nerves, 55 fibres. These fibres had not origin in the straggling ganglion cells lying a little distal to the main ganglion of the root, because those outlying cells had been included in the portion excised. Nearly all the fibres in question lay either in or close beneath the connective tissue of the bundle-sheaths of the nerve-trunks. Their appearance was such as to suggest an origin in the sympathetic. Those in the 6th lumbar cannot have come from any of the five adjacent nerve-roots above and below. They correspond in size with some in the ventral spinal root which do not degenerate peripheral to section of that root. They may be connected with certain of the scattered ganglion-cells within the ventral root, the more probably since a number of those cells like these fibres lie close under the connective tissue sheath of the nerve bundles. Similar fibres, as has been said, were not found in the peripheral nerves in the limb, except for one detected in the sheath of *obturator* trunk.

I conclude therefore that of the myelinate fibres persisting in the peripheral nerves of the limb after section of the ventral (motor) spinal roots none belong to the sympathetic system, and all, both the small and the large, belong to the cells of the spinal ganglia of the sensory roots.

Since the fibres are thus traceable to the spinal root-ganglion I refer to them in future as root-ganglion fibres.

III. Root-ganglion fibres in muscular nerves.

The fibres are myelinate, possess "nodes of Ranvier," &c., and under appropriate treatment show "incisions of Lantermann," "neurokeratin network," &c. The appearance of the individual fibres is quite indistinguishable from that of the myelinate fibres derived from the ventral (anterior) root, with which they are commingled. Some of the fibres of about 6μ — 7μ have a myelin sheath of great relative thickness.

1. Number of the fibres.

The actual number of root-ganglion nerve-fibres in an ordinary

muscular nerve-trunk is considerable. I have in not a few instances counted them, using the same method of counting as for the fibres of the spinal cord¹. Thus:—

A nerve to the upper part of <i>sartorius</i>	514 fibres.
A nerve to <i>vastus medialis</i> (Cat)	364 „
„ „ „ (Cat)	495 „
„ „ „ (Monkey)	274 „
„ <i>vastus lateralis</i> (Cat)	408 „
A division of the anterior crural nerve supplying <i>femoralis</i> , both <i>vasti</i> and a part of lower end of <i>rectus femoris</i>	1638 fibres.
A division of the anterior crural nerve supplying <i>femoralis</i> and both <i>vasti</i>	1282 „
A nerve to the lower part of <i>rectus femoris</i>	188 „
„ middle „ „	149 „
„ upper „ „	109 „
A twig to <i>rectus femoris</i>	90 „
A nerve to <i>tibialis posticus</i> and <i>flexor longus digitorum pedis</i>	589 „
Main branch to the medial head of the <i>gastrocnemius</i>	375 „
„ „ lateral „ „	340 „
Accessory branch	214 „
A nerve to the <i>tibialis anticus</i> and <i>extensor longus digitorum pedis</i>	674 „
The division of the sciatic trunk which supplies <i>biceps flexor cruris</i> , <i>semitendinosus</i> , and <i>semimembranosus</i>	1820 „

For assigning physiological values to the above numbers the following further data are useful. In a small cat the branches to *sartorius* and *quadriceps femoris* contained 2379 afferent fibres and the main cutaneous branch of the same trunk, *i.e.* the n. saphenus internus supplying skin along the inner side of the thigh, leg and foot contained 3710 fibres. The nerve to the hamstring muscles in another small cat contained 1456 afferent fibres, so that the two muscular nerves together contain more afferent fibres than does the long saphenus nerve itself.

To estimate the numerical proportion of afferent fibres to efferent in the muscular nerves, corresponding branches on the operated and unoperated sides have been compared. Thus: in a Cat the hamstring nerve contained

on the unoperated side 4512 fibres

¹ This Journal, xiv. p. 287.

	on the operated side	1820 fibres.
In Cat	the common trunk to <i>vasti and femoralis</i>	
	on the unoperated side	2840 fibres
	on the operated side	1182 fibres.
In Cat	the branch to <i>sartorius</i>	
	on the unoperated side	1183 fibres
	on the operated side	514 fibres.
In Cat	a branch to <i>vastus medialis</i>	
	on the unoperated side	749 fibres
	on the operated side	364 fibres.
In Monkey	the branch to the lateral head of <i>gastrocnemius</i>	
	on the unoperated side	1116 fibres
	on the operated side	554 fibres.

These comparisons between right and left hand nerve-trunks can be more accurately carried out with the larger nerve-trunks to muscles than with the smaller.

An assumption lying at the basis of the comparisons is that the number of fibres in the corresponding nerve-trunks from the two sides of the body is normally equal. Actual observation shows that these are really only so approximately. Thus:

branch from 5th lumbar nerve to the obturator trunk in the Cat, the plexus being of post-fixed arrangement and the relative size of the branch fairly corresponding with the figure given by Langley, fig. 1, Plate XII., this *Journal*, Vol. XII.

	Right side.	Left side.
No. of bundles	1	1
No. of fibres	828	737
Area of cross section	346	339.

Branch from 6th lumbar nerve to the obturator trunk in *Macacus rhesus*, the plexus being moderately post-fixed.

	Right side.	Left side.
No. of bundles	1	1
No. of fibres	174	161.

But for the present purpose it is necessary to be certain that the nerve-trunk selected is actually destined for muscle. In the term "muscle" I here include its connective-tissue accessories of tendon, perimysium, &c. It is necessary therefore to select nerve-trunks which are actually plunging into the fleshy parts of ample muscles. Now, when corresponding nerve-twigs of this kind are taken from the right and left limbs respectively it is found that on microscopic examination

they frequently do not prove so symmetrical as one would wish for carrying out their comparison (cf. figs. 10, 11, plate VI.). Thus :

Branch from anterior crural to upper part of *rectus femoris*.

	Right side.	Left side.
No. of bundles	3	2
No. of fibres	1022	810.

Branch from anterior crural to *vastus medialis*.

	Right side.	Left side.
No. of bundles	2	{1 large 2 small
No. of fibres	666	712
Area of total cross section of the bundles	367	434.

Branch from combined 5th and 6th lumbar nerves to the belly of *psaos magnus*; on both right and left sides the branch contained three nerve-bundles.

		Right side.	Left side.
Bundle <i>a</i> .	No. of fibres	673	768
	Area of cross section	313	357
Bundle <i>β</i> .	No. of fibres	209	173
	Area of cross section	88	60
Bundle <i>γ</i> .	No. of fibres	62	19
	Area of cross section	25	12
Total of fibres		944	960
Total area		426	429

I have endeavoured to overcome this discrepancy, which though sometimes trifling is more frequently wide, by gauging the number of fibres that must originally have been present in a nerve-branch by measurement of its transverse sectional area. In normal muscular nerves the fibres in the nerve-bundles are regularly and compactly arranged (cf. figs. 5, 7, 10, plate VI.). A given considerable area of cross section of nerve-bundle contains, if the same procedure in fixing and dehydration has been used, in the same individual not far from the same absolute number of fibres in corresponding nerves of the right and left sides. The cutaneous nerves contain considerably more fibres per unit of sectional area than do the nerves of muscles. Thus :

in Monkey an area of muscular nerve-bundles measuring 2608 contained 5112 fibres, whereas an area of cutaneous nerve-bundles (cutaneous division of musculo-cutaneous branch of external popliteal) measuring 415 contained 1618 fibres. Again in Cat an area of bundles in the muscular branches from the

anterior crural trunk (especially to *vastus lateralis*) measuring 1225¹ contained 920 fibres, while an area of a cutaneous branch (internal saphenous) from same trunk measuring 1925 contained 3796 fibres.

It is essential therefore that the nerves compared be corresponding nerves, *i.e.* muscular with muscular, cutaneous with cutaneous.

The plan adopted has been to take a small muscular nerve from the undegenerated side, and from the degenerated side the corresponding twig; then in both to count the total number of sound fibres and in both to measure the area of the component bundles. On the supposition that the bundles of the degenerated side were originally packed with fibres to the same degree of closeness as those in the corresponding nerve of the normal side, the sectional area serves as a guide to the number of fibres originally contained.

For the measurement of area the degenerative process should not have been allowed to run more than five weeks lest shrinkage due to sclerosis upset the basis of comparison. It is, however, necessary that at least twenty-six days elapse; otherwise, in any given cross-section of the nerve-bundles, there may occur a certain number of cross-sections of degenerate fibres which, being cut at a point where still tubular, are difficult to distinguish from sections of sound fibres. To measure the area of the nerve-bundles their outline was drawn on squared paper by means of the microstat and squared eyepiece. The system used was Zeiss apoch. obj. 4 mm. ocular 6. The fibres were counted by the same system. Examples:—

Cat.	Normal side.	Side with afferent fibres only.
A nerve to <i>rectus femoris</i>		
area	476	330
fibres	530	149
A nerve to <i>vastus medialis</i>		
area	535	482
fibres	414	164
Nerve to <i>biceps flexor cruris</i>		
area	420	478
fibres	630	322
Main nerve to medial head of <i>gastrocnemius</i>		
area	1063	987
fibres	946	375

¹ The measurements of area quoted from time to time are not indiscriminately comparable one with another. Only those are comparable which were in order to allow of comparison carried out with the *same sheet* of previously tested paper.

A nerve to <i>tibialis posticus</i> and <i>flexor longus digitorum pedis</i>		
area	944	873
fibres	1390	588
Common trunk to hamstring muscles		
area	5750	4306
fibres	4512	1456
Cat xi., a nerve to <i>sartorius</i>		
area	1387	996
fibres	1183	514
A nerve to lower end of <i>rectus femoris</i>		
area	315	382
fibres	244	188
A nerve to <i>femoralis</i>		
area	375	693
fibres	371	354
A nerve to upper end of <i>rectus femoris</i>		
area	400	216
fibres	208	90
A nerve to <i>tibialis anticus</i> and <i>extensor longus digitorum pedis</i>		
area	1315	1096
fibres	1557	675
A nerve to <i>vastus lateralis</i>		
area	1225	945
fibres	920	408

From these measurements it appears that in several examples (nerves to *femoralis*, lower end of *rectus femoris*, to *vastus lateralis*, to *sartorius*) a full numerical half or more of the nerve-fibres remained undegenerate. But taking the whole series together the average proportion of the afferent fibres to the total myelinate fibres in the nerves of the muscles examined proves to be a little less than a half (49%). The proportion of afferent fibres to total myelinate fibres ranges from a little more than a third in some muscular nerves to a full half in others.

2. Size of the fibres.

The afferent fibres in every muscular nerve examined have presented a striking variety of individual size.

From a number of measurements made on specimens fresh and fixed by osmic acid their diameter ranges in each nerve from about 1.8μ up to 18μ — 22μ . In fixed specimens I have never met with instances of

more than $20\cdot5\mu$. Fibres of 20μ are uncommon. Between 2μ and 20μ all intermediate sizes are to be found. In the nerves to the hamstring muscles afferent fibres of 19μ (fixed) are fairly common, whereas in other muscles, e.g. *vasti*, *femorales*, *tibiales*, fibres of 19μ are not so common, fibres of 17μ — 18μ being much more usual.

In the cutaneous nerves I have examined there are no fibres so large as the large afferent from muscles.

Thus:

	Largest fibre.
i. Cutaneous trunks.	
Medial division of <i>n. musculo-cutaneus</i> on <i>dorsum pedis</i> (fresh)	16 μ .
3rd division of <i>n. musculo-cutaneus</i> on <i>dorsum pedis</i> (fresh)	16 μ .
2nd plantar digital nerve (fresh)	16 μ .
a nerve to the pad (fresh)	16 μ .
<i>n. saphenus internus</i> , at top of thigh (osmic)	16 \cdot 5 μ .
<i>n. saphenus externus</i> (osmic)	15 μ .
2nd plantar digital (osmic)	15 μ .
2nd division of <i>n. musculo-cutaneus</i> on <i>dorsum pedis</i> (osmic)	14 \cdot 5 μ .
ii. Muscular trunks with afferent fibres removed.	
n. to <i>vastus medialis</i> and <i>femorales</i> (fresh)	20 μ .
n. to " " " (osmic)	19 μ .
n. to <i>vastus lateralis</i> and <i>femorales</i> (osmic)	19 μ .
n. to <i>biceps flexor cruris</i> (osmic)	20 \cdot 5 μ .
n. to <i>semimembranosus</i> (osmic)	20 μ .
n. to outer head of <i>gastrocnemius</i> (osmic)	19 μ .
n. to <i>flexor brevis digitorum pedis</i> (osmic)	18 \cdot 5 μ .
n. to <i>tibialis anticus</i> (osmic)	18 μ .
2nd plantar digital muscle (osmic)	18 μ .

A cross section of the plantar nerves at the ankle after removal of motor fibres illustrates the relation well. In these nerves smallish nerve-bundles are then seen scarcely or not at all affected by degeneration. These are the bundles which can be traced into the digital collaterals, and are cutaneous. Other bundles including two larger than the rest are heavily degenerated; these are traceable into the trunks or the plantar muscles. Among the relatively few fibres left in these highly degenerated bundles are a number larger (largest 18μ — 19μ) than any among all the very numerous fibres left in the cutaneous

bundles (largest 16μ — 17μ), and in the nerve twigs *inside* the 2nd plantar interosseous muscle were a few fibres of 18μ .

Among the large afferent fibres in the muscular nerves many are therefore larger than any in the cutaneous nerves. But the large afferent nerve-fibres of muscles, although larger than cutaneous fibres, are not the largest fibres in the muscular nerve-trunks in which they lie. Thus in the normal nerve to the *rectus femoris* (Cat) were fibres of 21μ — 22μ , and fibres of 20μ — 21μ were not uncommon, whereas the largest afferent fibre in the corresponding nerve measured 20μ . Again, in the nerve of the hamstring muscles exist a few huge fibres of 27μ — 30μ , *i.e.* of greater diameter than some cells in the spinal ganglion. These very large fibres disappear after section of the motor roots. The largest afferent fibres in a muscle-nerve are therefore not so large as are its largest efferent fibres.

The above facts bear out the suggestions obtained above, (i) that many of the small fibres in the nerves to muscles are afferent, (ii) that many of the large fibres of the sensory spinal roots are distributed *via* muscle-nerves.

Search in the sensory roots of the 5th, 6th, 7th, 8th, and 9th post-thoracic nerves shows a certain number of fibres larger than any I have seen among the afferent of muscle-nerves. Thus :—

	Largest fibre found.
dorsal (sensory) root of 6th post-thoracic (osmic)	23μ — 24μ .
" " 7th " "	24μ .
" " 8th " "	24μ — 25μ .
" " 9th " "	$22\cdot5\mu$.

I cannot explain this discrepancy. The discrepancy is still greater between the fibres of the sensory root of the 7th and those in the external saphenous and the digital nerves, to which—apart from muscles—it is mainly distributed—*i.e.* 24μ in the root, 15μ in the nerves, but this as above stated may be accounted for by the larger fibres being drafted off to muscles; the articular nerves will not account for it (*v. supra*, p. 214). Cf. however reference to Schwalbe, p. 215, *supra*.

The small fibres are not branches from the larger, for there is no evidence (*vide supra*, p. 213) of any branching of myelinate fibres in the nerve-trunks, and further small, medium, and large fibres all coexist at the very origin of the nerve-trunks in the spinal roots.

It is clear from the above that of the root-ganglion fibres in muscular nerves some are 100 times larger than others. Does a difference at all correspondent with this exist between the sizes of the

ganglion cells in the spinal ganglion? The only measurements extant are by Kölliker, who briefly notes that the diameter of some of the cells is thrice that of others. In the spinal ganglia belonging to the sacro-lumbar region my own preparations (Monkey, Cat) exhibit some cells more than five times the diameter of others. Thus:

	cell-body	nucleus	cell-body	nucleus
5th lumbar spinal ganglion	102 μ	25 μ	90 μ	24 μ
	28 μ	12 μ	21 μ	10 μ
6th lumbar	98 μ	23 μ	104 μ	25 μ
	19 μ	11 μ		
7th lumbar	100 μ	25 μ	21 μ	10 μ
	21 μ			
8th post-thoracic	98 μ	24 μ	18 μ	11 μ

The measurements were all from sections equatorial in so far that the nucleolus lay in the section. The largest cells extend through 13—15 sections, while the smallest disappear in three. Although not much stress can be laid on the fact, it is striking how often large and small fibres can be seen in the ganglion running radially toward large and small cells respectively, thus, toward a cell of 73 μ a fibre of 17 μ , and toward a cell of 24 μ lying next to the larger cell a fibre of 6 μ only.

Treating the cells as of spheroidal figure, an example of 100 μ diam. is rather more than 100 times the volume of an example of 20 μ diam. The difference is therefore about the same as that which exists between equal lengths of the smallest and the largest root-ganglion fibres in the muscular nerves.

3. *Relative numbers of the different sizes of fibres.*

The relative numbers of the different sizes of fibres in the bundles of muscular nerve-trunks are exemplified by the following:

Cat. A nerve to *vastus medialis* and *femoralis*.

384 fibres of 12 μ or more.

89 „ 8 μ —12 μ .

167 „ 4 μ —8 μ .

63 „ less than 4 μ .

A twig from the upper nerve to *rectus femoris*.

156 fibres of 12 μ or more.

54 „ 8 μ —12 μ .

69 „ 4 μ —8 μ .

29 „ less than 4 μ .

A twig to the lower end of *rectus femoris*.

78	fibres of 16μ or more.
38	„ $12\mu-16\mu$.
23	„ $8\mu-12\mu$.
40	„ $4\mu-8\mu$.
36	„ less than 4μ .

Two bundles in the branch from the anterior crural trunk to vastus lateralis and femoralis yielded together

202	fibres of 12μ or more.
47	„ $8\mu-12\mu$.
89	„ $4\mu-8\mu$.
33	„ less than 4μ .

Of the 1607 myelinate fibres in these nerves 858 measured 12μ or more. Analysis of nerves to the pretibial group of muscles gave a slightly different set of sizes. Thus :

Two bundles from a nerve to *tibialis anticus*.

	bundle A.	bundle B.
fibres of 12μ or more	148	131
„ $8\mu-12\mu$	64	44
„ $4\mu-8\mu$	67	47
„ less than 4μ	80	48.

In the same cat the corresponding nerves, from which however the ventral-root fibres had been all removed by 5 weeks' degeneration, yielded the following analyses :

A twig to *vastus medialis* and *femoralis*.

146	fibres of 12μ or more (none of more than 18μ existed).
63	„ $8\mu-12\mu$.
82	„ $4\mu-8\mu$.
65	„ less than 4μ .

When calculated from the sectional area and the data from the control nerve there should have been

378	fibres of $12\mu-21\mu$.
86	„ $8\mu-12\mu$.
163	„ $4\mu-8\mu$.
66	„ less than 4μ .

The loss by degeneration had therefore been least in the class of fibres of less than 4μ ; greatest in the class of 12μ or more; the fibres of more than 18μ had been entirely removed. In the fibres of less than 4μ it is not clear that there had been any loss at all; but it must be remembered that in the ventral spinal roots, even in those which do

not give off white *rami communicantes* there exist fibres of less than 4μ . Thus: in the ventral root of the VIIIth lumbar nerve I find fibres of $2-3\mu$, patchily scattered among the large fibres.

A twig to upper part of *rectus femoris* yielded

29 fibres of 12μ or more (none more than 18μ existed).

19 „ $8\mu-12\mu$.

23 „ $4\mu-8\mu$.

18 „ less than 4μ .

A twig to lower part of the same muscle yielded

34 fibres of $16\mu-19\mu$.

22 „ $12\mu-16\mu$.

22 „ $8\mu-12\mu$.

66 „ $4\mu-8\mu$.

34 „ less than 4μ .

Of the total number of fibres in these nerves little more than a third instead of distinctly more than one-half measure above 12μ . Further the absolute number of fibres of less than 4μ is not indubitably diminished per unit of sectional area of nerve-bundle.

Change in a similar sense is obvious from analysis of a twig to *tibialis anticus*.

125 fibres of $12\mu-18\mu$.

76 „ $8\mu-12\mu$.

45 „ $4\mu-8\mu$.

104 „ less than 4μ .

Again, in another Cat

a large bundle in the normal nerve entering *rectus femoris* contained 433 fibres, of which 246 measured above 12μ , while 76 measured less than 4μ ;

a bundle in a nerve to *vastus medialis* contained 394 fibres, of which 227 measured more than 12μ ;

a twig from the nerve to *rectus femoris* of opposite side from which the ventral-root fibres had been removed by degeneration contained the following:

54 fibres of 12μ or more.

25 „ $8\mu-12\mu$.

45 „ $4\mu-8\mu$.

25 „ less than 4μ .

a bundle to *vastus medialis*

68 fibres of 12μ or more.

- 21 fibres of 8μ — 12μ .
- 32 „ 4μ — 8μ .
- 35 „ less than 4μ .

a branch to medial head of gastrocnemius consisting of four bundles (A to D) yielded the following analysis:

	A	B	C	D
fibres of 12μ or more	89	31	46	12
„ 8μ — 12μ	20	7	11	3
„ 4μ — 8μ	45	14	25	6
„ less than 4μ	20	16	24	6

a branch to *tibialis posticus*,

	A	B	C	D
fibres of 12μ or more	99	62	48	19
„ 8μ — 12μ	14	14	36	2
„ 4μ — 8μ	51	31	48	12
„ less than 4μ	44	30	53	15

Confining attention to the extensor group of the knee it will be noted that of 2434 fibres in the normal nerve-bundles 1331 measured more than 12μ in diameter: but in the similar nerves of the side whence ventral-root fibres had been removed, out of 948 fibres only 353 measured above 12μ in diameter.

After removal of all ventral-root fibres by degeneration, the sections prepared from the fleshy parts of muscles with their small intramuscular nerve-bundles, very rarely in my experience exhibit fibres quite as large as the largest afferent fibres seen in the parent nerve-trunks traceable into the muscles by naked eye dissection. Thus:

intramuscular bundle in *sartorius* muscle,

- 15 fibres of 12μ — 15μ .
- 6 „ 8μ — 12μ .
- 13 „ 4μ — 8μ .
- 9 „ less than 4μ .

three intramuscular bundles in *vastus medialis* (A to C),

	A	B	C
fibres of 12μ — 18μ	20	4	21
„ 8μ — 12μ	5	3	7
„ 4μ — 8μ	16	4	18
„ less than 4μ	15	7	13

intramuscular bundle in *tibialis anticus*,

4 fibres of 12μ — 14μ .
 8 „ 4— 12μ .
 5 „ less than 4μ .

On comparing the root-ganglion fibres of muscles with the fibres in the articular twigs from the circumflex trunk to the shoulder joint the fibres in the latter are found to average much the smaller.

Articular nerve to shoulder.

No fibre of 12μ .
 8 fibres of 8μ — 12μ .
 17 „ 7μ .
 96 „ 3μ — 7μ .
 22 „ less than 3μ .

As to the dimensions therefore of the fibres commingled in a muscular nerve, the efferent and the afferent both present individual fibres of strikingly diverse calibre, yet the largest of all are efferent, and the afferent predominate among the smaller. The comparison can be curiously accurately expressed by quoting Henle's statement¹ of the difference between the motor and sensory spinal nerve-roots. "Die Mehrzahl der Röhren in den hinteren Wurzeln feiner ist als in den vorderen; die dicksten Röhren der vorderen Wurzeln stärker sind als die dicksten Röhren der hinteren Wurzeln; die Zahl der feinsten Röhren in den hinteren Wurzeln grösser ist als in den vorderen."

4. *Arrangement in the nerve-trunks.*

The root-ganglion fibres lie scattered fairly regularly throughout the cross-section of the nerve-trunk, and are commingled with the motor fibres, though occasionally partially grouped apart from them. The large, medium and small fibres are admixed without obvious distinction. Occasionally little groups of large fibres or similar of small occur. When side twigs are thrown off from the parent stem large fibres and small together are drafted off into them; the fibres for a branch are usually gathered together and become grouped off from the rest of the parent nerve at some little distance above the point at which the branch actually separates from the trunk. Although in all the examined muscular nerves of macroscopic size the root-ganglion fibres and the motor fibres are commingled, on following the nerves with the microscope, twigs of microscopic size are frequently found consisting of

¹ *Handbuch der Nervenlehre.* Brunswick, 1883.

root-ganglion fibres only. Such twigs contain usually some 10—40 nerve-fibres, but occasionally even 70—80. In these purely afferent twigs the fibres are usually as elsewhere of various sizes. After removal of all motor fibres these twigs stand out in striking contrast against the sensori-motor parent bundles, and against their numerous sister offshoots of sensori-motor quality. Purely motor twigs are in my experience quite infrequent, and very small (*e.g.* 60μ across); they contain after the ventral (anterior) roots have been severed not a single myelinate-fibre.

5. *Distribution in the muscular tissue.*

The root-ganglion fibres in the nerve-trunks to muscles can be followed fully into the muscles. There they course for the most part in small sensori-motor and purely sensory branches. Not infrequently large myelinate root-ganglion fibres can be seen running absolutely singly and apart. When this is the case it is common for the single fibre to be surrounded by a very conspicuous loosely-fitting "sheath of Henle." For the most part the root-ganglion fibres tend to follow aponeuroses and fibrous septa for a considerable distance. They thus come to lie frequently near the surface of or between the divisions of a muscle. I have seen this perhaps especially well in *soleus*, *gastrocnemius*, *vastus medialis*, *femoralis* and *gracilis*.

Some of the afferent fibres while still myelinate divide dichotomously. After losing the myelin sheath some branch and rebranch very freely; the branches are beset with numerous oval nuclei. Others appear not to branch in the same way as this. The existence in muscles of certain nerve-fibres which do not terminate in "end-plates" was first noted by Kölliker. Such fibres have been especially studied in the ventral skin-muscle (*cutaneus pectoris*) of the Frog. The observations concerning them will be found summarised by Kölliker¹ and still more recently by Landauer². Some are supposed to be sensorial, but I do not discuss them here because, until the degeneration test has been applied to them, it is scarcely possible to exclude satisfactorily what may be motorial, *e.g.* Bremer's *enddolden* have proved motorial.

6. *The Muscle-spindle.*

In embryonic muscles occur certain primitive fibres possessed of closely-set and even juxtaposed double, triple or quadruple rows of

¹ *Handb. der Gewebel.* Vol. I. 1889.

² *Sitzungsab. aus Ungarn, Math. naturw. Klasse, 1892.*

nuclei. These fibres were first noted by Weismann (1860), and as he, Kölliker, and subsequently Bremer (1882) and Felix (1888) have shown, produce by longitudinal fission 'daughter-fibres,' thus constituting centres for muscular growth by the addition of new fibres. In adult amphibian muscle Kölliker in like manner discovered (1862, *m. cutaneus pectoris*, Frog) certain circumscribed bundles of fibres closely resembling the "Weismann fibres" of embryonic muscle. These he interpreted as similar centres of growth persisting within the adult and already specialised tissue. He named these bundles in accordance with that view "muscle-buds," *muskel-knospen*. Kühne discovered (1863) similar bundles of fibres in adult mammalian muscle; in attaching significance to them he was more guarded than his predecessor. He designated the bundles simply in virtue of their shape, *muscle-spindles*, "*muskel-spindeln*," the name adopted here as the most suitable of all that have been applied. The name "muskelknospen" in a sense different from Kölliker's has been given by pathologists to the sprouting fibres of muscles undergoing regeneration after injury. The "spindles" have been studied by Golgi (1880); Golgi's definition of them is "bundles of incompletely developed muscle-fibres, surrounded by a special sheath, and to be found in muscles at every period of their growth." He suggests their special connection with the lymphatic system of the muscle. Fränkel has asserted the spindles to be pathological formations, describing them under the name "umschnürten Bündeln." Working upon pathological material Eisenlohr, and Fränkel and Milbacher, also Eichhorst (1888) and Santesson (1890), regard them as foci of inflammatory degeneration. S. Mayer and Babinski (1886) similarly ascribe them to degeneration, although considering them physiological rather than pathological, inasmuch as due to a degeneration of normal occurrence within active muscles. Mays (1885) has discussed the possibility of the spindles being sensorial, but his conclusion is against their being so; *inter alia*, he quotes Kühne to the effect that after section of the motor spinal-roots the nerve-fibres supplied to the spindles degenerate (in Lizard), together with those belonging to the motor end-plates. Kerschner however (1888) on *a priori* grounds has renewed the suggestion. v. Kölliker¹, in the last edition of his *Handbuch*, critically sums up what is now known concerning the 'spindles' (his 'knospen'). With reference to their functional significance he writes "the most contradictory views prevail. Some, as

¹ *Handb. d. Gewebelehre*. Vol. I. 1889. pp. 394—406. Cf. also for references up to this date.

Krause, Felix and myself regard the 'knospen' as stages in the development of the fibres of the muscle; Kerschner declares them to be sensory structures; others again believe them to be pathological." After weighing the evidence Kölliker concludes that "putting all the facts together it cannot be doubted that the 'knospen' are nothing but muscle-fibres in process of longitudinal subdivision."

Since Kölliker's summary further papers have come from Trinchese¹ and from v. Thanhoffer², both upholding Kölliker's growth-centre view. But Mays³ from study of development of motor endings, and Christomanos and Strössner⁴ from the histology of human muscle, have failed to satisfy themselves that production of new muscle-fibres and new nerve-fibres is actually observable in the "spindles." Santesson⁵ still follows the pathological explanation. R. Volkmann⁶ finds that though as he believes the spindles are concerned with the physiological growth of the muscle they have nothing to do with the regeneration of repair from injury. Lastly, important information on the mode of termination of nerve-fibres within the "spindle" has been contributed by Ruffini⁷. Ruffini considers that there are two modes of ending of the nerve-fibres in the spindle neither of which resembles ordinary motor endings. In his second communication (November, 1893) he says, "I cannot to-day say other than I said in my communication already published, namely, that the muscle-spindles may be special nerve-organs entrusted with some peculiar sensorial function; but in saying so I look forward to experiment for the final word upon the matter."

My own experiments have been suitable for examining the effect of degeneration of the motor spinal roots upon the nerve-fibres supplying the muscle-spindles; they demonstrate that the muscle-spindle is supplied with nerve-fibres arising in the cells of the spinal root-ganglion. In muscles from which all motor fibres have been entirely removed by degeneration I have never in a single instance failed to find every spindle met with in the muscle still possessed of perfectly sound myelinate nerve-fibres. These myelinate fibres are traceable from the sen-

¹ *Arch. ital. d. Biologie*, xiv. 221, 1891.

² *Anat. Anzeiger*, vii. 635, 1892.

³ *Zeits. f. Biologie*, xxix. p. 41, 1892.

⁴ *Sitz. d. k. k. Wien. Akad. c. III.* 417, 1891.

⁵ *Verhandl. d. biolog. Vereins in Stockholm*, iii. 3, p. 26.

⁶ *Ziegler's Beiträge*, xii. 320. 1893.

⁷ A. Ruffini. *Rendiconto d. R. Accad. d. Lincei*. Rome, June, 1892. *Arch. ital. d. Biol.* xviii. 106. Also *Anat. Anzeiger*, Nov. 1893, p. 87.

sory roots, and penetrate into the spindles and terminate within them. The muscle-spindle proves therefore to be a sensorial organ as argued by Kerschner and is indicated by the histological analysis of the nerve-ending by Ruffini.

Belonging to that class of end-organs of which the Herbst corpuscle, the Golgi tendon-organ, and the Pacinian corpuscle may serve as types, a feature peculiar to the muscle-spindle is the remarkable bundle of striped muscle-fibres contained within it. I shall here briefly describe the anatomy of the organ on the basis of my own preparations taken from the monkey and the cat.

In *shape* the muscle-spindle is as its name implies fusiform. The long axis of the organ lies parallel to that of the muscle-fibres amid which it is imbedded, or to that of the bundles composing the fibrous septum near which it is often placed; in the second case its long axis may be inclined at an angle with the long axes of the adjacent muscle-fibres. Its own contained muscle-fibres, or as they may be termed¹ the *intrafusul* muscle-fibres, always however run parallel with the long axis of the spindle itself.

In *size* the muscle-spindle presents much variation. It is usually just visible to the naked eye. It is common for a spindle to be compounded out of two conjoined simple spindles. I have met with a triple spindle (*f. brev. hallucis*, monkey). The length of the spindles in my preparations has ranged between .75 mm. and 4 mm. The diameter of the organ where widest is 80μ — 200μ .

A very important part of the muscle-spindle is its *capsule*. This is composed of concentrically superposed membranous lamellæ, in most places not more than 6—8 in series. The lamellæ consist of fibrous tissue in flattened bundles, more or less fused together; the fibres are circularly arranged almost accurately in the plane of the short axis of the spindle. Between the capsule and the axial contents of the spindle intervenes a distinct space, which toward and at the poles of the spindle is a narrowish cleft, *e.g.* 5μ — 15μ across, but in the middle or *equatorial* region is much wider, *e.g.* 40μ — 60μ across. This space, which completely surrounds the axial contents of the spindle, may be called the *periaxial space*. It is a lymph space, and exhibits in hardened specimens proteid precipitate and occasional lymphocytes, but never blood corpuscles. I have succeeded in injecting it by injecting the lymphatics of the leg. It is bridged across and partially subdivided in many points by extremely tenuous membranes and filaments. These

¹ From *fusus* a spindle, as extramural from *murus*.

septa, as also the membranes of the capsule proper, are studded with sparse oval nuclei like those upon the coats of a Pacinian corpuscle. The open work of delicate septa webbing across the *periaxial lymph space* fuses on one side with the inner face of the inmost sheet of the corpuscle proper, on the other with a thin more or less perfect layer of connective tissue which immediately invests the axial core of the spindle. This investment I would term the *axial sheath*. It is fairly well shown in figs. 16 and 17, Plate VII. It is richly nucleate and supports as well as invests the neuro-muscular contents of the organ. In a compound spindle each intrafusal muscle-bundle retains its own axial sheath, even where the capsules of the component spindles are completely merged one in another.

The capsule proper is fairly sharply delimitable upon its inner side by the *periaxial lymph space*, and in great measure is separated outside from the surrounding *perimysium internum* of the muscle, except at certain definite places. At each pole it is perfectly continuous with perimysium and often with commencing tendon-bundles. At places where a nerve enters it is continuous with perineurium. In and on the capsule small blood vessels are numerous; one of these usually runs in the superficial part of the capsule for some distance along the length of the spindle; from its sides diverge capillaries taking a more or less spiral course within the capsule.

An essential component of the muscle-spindle is the bundle of muscle-fibres within it. This *intrafusal muscle-bundle* passes along the approximate axis of the spindle, entering at or commencing at one end and usually becoming tendinous as it reaches the opposite extremity. Sometimes it issues from the spindle before becoming tendinous. The intrafusal muscle-bundle consists of 2—12 primitive fibres; in a compound spindle there may be more than twenty, but these are nowhere perfectly merged into a single bundle. To facilitate description it is necessary to distinguish between the end portions and the intermediate region of the spindle, and between the end at which the muscle-bundle enters and that at which it often terminates in tendon. I shall call these portions of the spindle the *equatorial region* and the *distal* and *proximal polar regions*, the last-named being that at which the intrafusal muscle-bundle enters or begins.

In the extreme proximal end of the *proximal polar region* two or three primitive muscle-fibres, of the "red" (Ranvier) "trübe," "protoplasma-reich" (Grützner, Knoll) kind, become invested in common by a sheath of perimysium internum, somewhat thicker and more definite

than their neighbours. They thus form an "umschnürten Bündel" and in this region may be said to be entering the spindle. As they penetrate further into the organ they tend to split lengthwise, so that one parent fibre becomes cleft into perhaps three daughter fibres. Accompanying this cleavage there is in my specimens no obvious change in size of the total cross section, that is, the daughter fibres combined offer about the same area as the single parent fibre. The daughter fibres are, however, very commonly circular in cross section, whereas the parent fibres resemble ordinary muscular fibres in being variously polygonal. In the intrafusal fibres it is common for nuclei to lie imbedded in the thickness of the fibre, often quite centrally. It is also common for only the marginal sheet of the substance of the intrafusal fibre to be striate or fibrillate, the appearance produced in cross section resembling somewhat that given by the Purkinje cardiac muscle-fibres, or by the myoblasts described by J. Schaffer. Some of the intrafusal fibres are devoid of sarcolemma. Except that the nuclei in the intrafusal fibres become more frequent as the equatorial region is approached, the fibres without presenting further change than the above pass usually through somewhat more than the whole proximal third of the spindle.

In the *equatorial region* the intrafusal muscle-fibre often becomes somewhat smaller in diameter and is nearly always circular in section. Its surface zone soon gets thickly encrusted with or almost completely occupied by a sheet of nuclei. Whether these nuclei are strictly part of the muscle-fibre proper is not clear to me. The nuclei are spherical or slightly oval, are clear, and measure about 6μ diameter. Cross-sections reveal beneath the nuclear sheet a thin tubular layer which is fibrillated. This tubular layer itself invests a central core (4μ — 5μ) of hyaline substance, which runs rodlike along the axis of the intrafusal fibre in this region (Fig. 16). The cross-section of the fibre thus often displays a nearly complete zone of four to six nuclei around a hyaline centre. The striation is obscured by the nuclei clothing the face of the attenuated fibre, but where seen in the adjoining regions the striation is very marked, and coarser than in the ordinary muscle-fibres outside the spindle.

More than 400μ of the length of the intrafusal muscle-fibre may in the equatorial region be thus beset with groups of nuclei. The appearance so given makes the fibre closely resemble the Weismann fibre of embryonic muscle. This resemblance is doubtless the cause of the confusion existing between the sensorial spindle-organ and the em-

bryonic centres for reproduction of muscle-fibres. One important anatomical point of difference should assist to distinguish between the two. In the embryonic muscle-centres for production of new fibres nuclear mitosis must be a striking feature¹. On the other hand in those muscle-spindles which I have examined for mitosis I have failed to find nuclei other than in a resting condition. In all my preparations treated for studying karyomitosis the closely set nuclei of the equatorial region show no signs of reproduction but are typically resting nuclei. While insisting on the sensorial nature of the muscle-spindles I would therefore also urge that I find no evidence in favour of their being considered, in the adult muscle at least, as centres of growth or of production of new muscular fibres.

The *equatorial region* usually occupies somewhat less than one-third of the entire length of the spindle (Fig. 16, Plate VII.). On emerging from this region the intrafusal fibres quickly regain the character they possess in the proximal polar region. The number of nuclei in them becomes less as the distal pole of the spindle is approached. Toward the farthest end of the distal polar region the muscle-fibres often merge in tendon bundles; not all the fibres become tendinous at the same point, and the tendon filaments of some are relatively very long, *e.g.* 500μ — 600μ . The tendons finally combine with the fibrous tissue of the capsule near or at the distant apex of the spindle. It is sometimes difficult to distinguish a cross section through the extreme distal polar region of a muscle-spindle from a cross section through a Golgi tendon-organ. If myelinate nerve-fibres lie with the tendon-bundles inside the corpuscular sheath the organ usually proves to be a Golgi tendon-organ; in the muscle-spindle it is with the muscular not with the tendinous portion of the axial core that myelinate fibres become juxtaposed, and as the nerve-fibres enter by the proximal polar or equatorial regions rather than by the distal polar they are not usually seen in cross-sections through the tendinous end of the spindle.

The diameter of the intrafusal muscle-fibres ranges between 6μ and 28μ so far as I have seen. The intrafusal bundle is not itself spindle-shaped; it hardly alters in diameter throughout its extent, though perhaps usually slightly more slender in the equatorial region than elsewhere. The bundle like its component fibres is rounded, not angular in section; its diameter in the equatorial region may be only one-sixth that of the spindle itself, *e.g.* 32μ out of 190μ . The bundle frequently is placed excentrically in the spindle. The eccentric position

¹ Cf. Felix, *Anat. Anzeiger*, 1888. *Zeits. f. wiss. Zool.* 1889.

is due to asymmetry of the capsule which bulges here on this aspect, there on that. In longitudinal sections the bundle is always found to pass quite in a straight line between its ends in the spindle.

The spinal-ganglion nerve-fibres which supply the muscle-spindles are large and myelinate, varying in diameter from 7μ to 18μ . They are not distributed singly one to each spindle. On an average 3—4 independent nerve-fibres enter each spindle, in the case of compound spindles 5—7 fibres. This gives an average of about three intrafusal muscle-fibres to each individual myelinate root-ganglion fibre attaining a muscle-spindle. The separate nerve-fibres may approach the spindle by different nerve-twigs and enter it at widely distant points. Many of the large spinal-ganglion fibres distributed to muscles course singly (*vide supra*, p. 237), enveloped in a thick loosely-fitting sheath of Henle (*e.g.* a sheath of 35μ containing a fibre of 8μ) girt from place to place with annular and spiral elastic fibres. Almost all, if not all, these solitary nerve-fibres, that by the above characters are readily recognisable even in normal muscle without the analytical help of degeneration, are destined for "muscle-spindles." Their highly developed sheath of Henle becomes continuous chiefly with the layers of the capsule of the spindle, but partly in most cases also with the *axial sheath* of the core of the spindle, being in part retained as the nerve-fibre gradually traverses the periaxial lymph-space to reach the intrafusal muscle. But besides isolated nerve-fibres attaining the spindles, not infrequent are small nerve twigs consisting of 3—6 large spinal-ganglion fibres all bound for one and the same muscle-spindle and entering it at one point, or two closely adjacent points. These twigs are pure spindle-nerves. Such spindle-nerves form one class of the purely afferent intramuscular nerve-trunks above described. One such is figured in Fig. 13, Plate VII.

The nerve-fibres enter the spindle from the side, not from the end; they most commonly enter not far from the junction of equatorial with polar, especially proximal polar, region. A single fibre entering the capsule sometimes winds between its coats for some distance, lying as it were partitioned off from the rest of the organ. The nerve-fibre does not on reaching the spindle lose the myelin-sheath; it retains it long after piercing the capsule, and even after attaining to the intrafusal muscle-fibres beyond the periaxial lymph-space. The nerve-fibre never in my experience loses the myelin-sheath before it has completely penetrated the periaxial lymph-space. Carrying with them

a sleeve as it were of investing membrane which, like the periaxial sheath is very delicate and richly studded with oval nuclei, the nerve-fibres plunge in various directions within the spindle, diverging one from another and traversing considerable lengths of the organ. I have seen spinal-ganglion fibres branch both when close outside and when quite within the thickness of the capsule. The branching is usually by dichotomous division at a node of Ranvier, and the angle of divergence of the two branches is usually quite small. While approaching the spindle the length of the sheath segments (internodes) of the spinal-ganglion fibre is from 600μ — 900μ ; at a variable distance within the spindle, the segments (internodes) become suddenly much shorter, 80μ — 130μ . At the same time dichotomous subdivision becomes more frequent, the myelin-sheath becomes less thick, and the diameter of the axis cylinder considerably greater, *e.g.* 14μ instead of 9μ . A parent-fibre of 12μ diam. will thus give rise to two thin myelinate fibres, each of 13μ — 17μ . These large, closely-jointed, thinly-myelinate fibres run along and within the intrafusal muscle-bundle, especially in the equatorial and immediately adjacent regions. In longitudinal view they exhibit a serpentine course and in fixed specimens indent the margins of the intrafusal muscle-fibres. They are wrapt in extremely delicate nucleated sheaths continuous with the nucleated axial-sheath of the spindle core. Some of the nerve-fibres are in hardened specimens somewhat flattened against the muscle-fibres; perhaps these may be the ribbon-fibres described by Ruffini. The nerve-fibres devoid of myelin clasp the muscle-fibres in the equatorial region by wide, flattened expansions; these expansions are set more or less obliquely across the fibre. I take these to be the annulo-spinal terminations described by Ruffini, and pointed out by him to differ widely from ordinary motorial nerve endings. In my preparations one sensory nerve-fibre may be in this manner connected with more than one fibre of the intrafusal muscle.

Is the intrafusal muscle like the rest of the muscle connected directly with the motor nerve? In attempting to answer this question anatomically I have been unable by the gold method (Ranvier's, Fischer's) to satisfy myself of the existence of motorial end-plates on the intrafusal muscle-fibres. I do not however on the strength of not finding them venture to deny their possible existence in some form or other. To the physiological side of the question I obtained a more definite reply in the following way. From the sciatic nerve of the cat a short piece beneath the gluteus muscle was excised. The end of

the central stump was at the time of operation stitched upward to defeat reunion. A period of 150 days was allowed to elapse for degeneration. No union of the divided nerve took place and the muscles supplied by it remained completely paralysed. The muscle-fibres (in gastrocnemius and in the plantar muscles) were then examined. It was sought to ascertain whether the muscle-fibres inside the spindles and outside the spindles had suffered from the degeneration in a similar or dissimilar manner. The ordinary primitive fibres composing the muscle were with scarcely an exception found altered almost beyond recognition. The alteration offered the well-known characters, which may be shortly enumerated thus: (1) the muscle-fibres had from a diameter of $15\ \mu$ – $40\ \mu$ dwindled to $4\ \mu$ – $10\ \mu$; (2) their longitudinal fibrillation and their cross striping had altogether disappeared; (3) the hyaline masses representing the fibres were dotted with minute granules, many of them blackening with osmic acid; (4) the continuity of most of the fibres was interrupted at short distances. Between the shrunken fibre-bundles intervened large clefts, containing fat droplets free or within cells. The blood vessels even to the minutest capillaries were remarkably engorged. As to the condition of the muscle-spindles of course all nerve-fibres had absolutely disappeared. In the periaxial space of the spindles lay fat either in cells or free: I have never seen fat in the muscle-spindles under normal circumstances. The muscular fibres in the spindles were not obviously altered from their normal; they measured $8\ \mu$ – $25\ \mu$ in diameter, were well striated and fibrillated, and were not fatty. In all the spindles met with, this was the condition; I cannot assert that every fibre in every spindle had remained unaffected by degeneration but all the evidence I found was to that effect. The intrafusal fibres, originally the slenderest in the muscle, were become, owing to atrophy of the rest, the stoutest fibres present. The relation that holds between the ordinary muscular fibres and the motor-nerve does not therefore hold between the intrafusal muscle-fibres and the motor-nerve. Nor does the spinal ganglion take for the intrafusal muscle the place taken for the ordinary muscle-fibres by the ventral horn of the cord. The intrafusal muscle-fibres seem in regard to their nutrition to be largely independent both of the afferent and the efferent nerves of the muscle—if one may judge by absence of obvious degeneration in them for five months after total enervation.

Most of the spindles lie absolutely imbedded in the fleshy parts of the muscles; many abut upon intramuscular septa or are in the

immediate vicinity of aponeuroses. In these situations it is not rare to find two or even three spindles almost touching one another. The arrangement recalls one common with the Pacinian corpuscles in the pelvic septa, but I have never seen a nerve-fibre traverse one muscle-spindle to reach a second, as is not unusual with Pacinian bodies. Sometimes a Golgi tendon-organ comes by one of its ends in contiguity with a muscle-spindle. My preparations prove that the myelinate nerve-fibres supplied to the Golgi tendon-organs are like those of the muscle-spindles all derived from the cells of the spinal root-ganglion. They also show that neither the muscle-spindles nor the tendon-organs receive any myelinated fibres from the sympathetic system, for after extirpation of the spinal ganglion together with section of the ventral (motor) spinal nerve-root all myelinate nerve-fibres to the muscle-spindles and Golgi tendon-organs degenerate and disappear. The capsule of the organs does not in seven or even twenty weeks suffer any obvious alteration, although in that time the nerve-fibres are completely broken up and removed. The number of nuclei in the Henle sheath and between the intrafusal fibres and in the *axial-sheath* appears to be considerably increased and the capillary vessels of the spindle are abnormally evident.

I judge the number of spindle-organs in the limb muscles I have examined to be sufficient to account for nearly if not quite two-thirds of all the afferent nerve-fibres demonstrated to exist in the nerve-trunks of those muscles. The muscle-spindles appear able to account only for the larger-sized nerve-fibres, namely those of 7μ or more. It was shown above that about two-thirds of all the afferent fibres measure above 7μ diameter. Of these I imagine that considerably more than a half may be apportioned to the muscle-spindles, the majority of the rest belonging probably to Golgi's tendon-organs. I have not observed any of the quite small afferent nerve-fibres entering a muscle-spindle; although the larger afferent nerve-fibre has the muscle-spindle for its terminal organ the small afferent fibres must therefore possess some other kind of ending.

Judging from my preparations I imagine the spindle-organs to be relatively more numerous in the intrinsic plantar muscles than in the large muscles of the thigh, though they are plentiful in both situations. In *vastus medialis* (internus) a large aponeurosis belongs to the distal fleshy portion of the muscle. Under this aponeurosis the spindle-organs are numerous; if the aponeurosis be

thoroughly separated however carefully I have always found the 'knee-jerk' irrevocably lost from the muscle.

In the eye-muscles of the cat and monkey I have at present been unable to find any muscle-spindles of the usual type, though in the tendons of these muscles tendon-organs exist. Nor have I as yet found muscle-spindles in the intrinsic muscles of the tongue. To these points I hope to return in a subsequent paper upon the muscular and nerve-fibres of these muscles themselves.

I have entered here into the structure of these sensorial organs demonstrable in voluntary muscles, largely because a physiological inference clearly arises in the course of study of them, namely, that the stimulus to which these organs are specially adapted is mechanical in quality. In a previous paper¹ I have given evidence that (1) to stretch a passive muscle causing lengthening and increased longitudinal strain in it is a remarkably efficient means of obtaining a discharge of impulses along its afferent nerves: also (2) that contraction of the muscle brought about by electrical excitation of its motor nerve-fibres only, even when the muscle lies cut loose from its attachments and free to change its shape without further load than a fraction of its own weight, can also cause a discharge of centripetal impulses. The muscle-spindle, supplied as above shown with special afferent nerve-fibres, does from its structure help to a conception of how both modes of excitation may mechanically affect the endings of the sensory nerves connected with the muscles.

IV. Pale fibres of the nerves of skeletal muscles.

Besides myelinate fibres there are in the nerves of skeletal muscles a number of pale fibres. They are however hardly so numerous as in the small cutaneous nerves. In cross sections of the plantar and dorsal digital nerves of the foot the pale fibres can be found forming strands 15μ — 25μ across islanded amid the mass of myelinate fibres. Collections such as these are quite infrequent in the muscular nerves of corresponding size. I have especially examined the pale fibres in the twigs from the nerve-trunks to *vastus medialis*, *flexor longus digitorum* and *tibialis anticus*.

I have above given evidence that after extirpation of the lower lumbar prevertebral ganglia of the sympathetic no myelinate fibres are found degenerate in the muscular or cutaneous nerves of the lower

¹ *Proc. Roy. Soc.* Feb. 9th, 1893.

limb. Also that after excision of the spinal ganglia and motor roots of the post-thoracic nerves from the 3rd to the 9th inclusive no myelinate fibres remain sound in the nerves of the limb. It follows therefore that in the muscular and other nerves of the limb none of the fibres derived from the sympathetic are myelinate. All the sympathetic fibres in the muscular and other nerves of the limb are therefore included in the pale fibres.

Not a few of the non-medullated fibres are larger than the smallest medullated; they measure (in fresh preparations) up to 5μ diameter. They are here as elsewhere richly nucleate (sheath-nuclei), 8—10 nuclei per 100μ of length. They frequently branch, the branches being always so far as I have seen distinctly smaller than the parent fibre. The branching appears to be always by dichotomy.

From the foregoing observations I conclude that in the lower limb and adjacent region all nerves of macroscopical size are as regards their myelinate fibres (1) mixed sensori-motor, or (2) purely sensory; none purely motor. Some of the minute nerve-twigs within the skeletal muscles are however purely motor, but even there by far the greater number of the nerve-twigs are mixed, *i.e.* sensori-motor.

V. The muscular nerves in an amyelous fœtus.

From further observations I would extend the same conclusions regarding root-ganglion nerve-fibres and striated muscle to all the spinal nerve-pairs. These observations are as follows.

In cases of extreme *spina bifida* there may occur partial or complete absence of spinal cord or *amyelia*; the development of the spinal cord has presumably been so early arrested that at birth no vestige of it is discoverable or exists. Some of the neurological features of such a deformity have been described by Leonava¹. In the instance examined by him no spinal cord could be found, but there existed nine pairs of spinal ganglia. From the five lowest of them descended trunks which formed a *n. cruralis*, and distributed themselves in a sacral plexus. The upper four gave nerves to intercostal spaces. The muscles of the lower limb were developed, and nerve-twigs were seen to enter them. Leonava remarks concerning the latter, "possibly it is a question here of sensory muscle-nerves²." I find in the Museum of St Thomas's Hospital a fœtus preserved on account of presenting an extreme degree of spina

¹ *Neurologisches Centralblatt*, p. 218, 1893.

² "Möglicherweise handelt es sich hier um sensible Muskelnerven," *loc. cit.* p. 225.

bifida. I have by the kind permission of our Curator, Mr Shattock, examined it carefully. The following is the condition existing.

Fœtus, of the 7th—8th month: body-length 31 centimeters. The left lateral half only has been preserved but the plane of section is such as to include the true medium plane in the preserved specimen. The specimen has been preserved in spirit and has been in the Museum for upwards of eight years.

The bones, skin and muscles of the face and limbs, the ribs and intercostal muscles, and the skin of the chest and abdomen are well developed. The layer of subcutaneous fat is very thick. Examined in the muscles of the limbs, thorax and face the microscopic appearance of the muscular fibres is normal. The eyeball and external ear are normal in appearance, but there is no forehead, and no cranial vault. The contents of the orbit have been considerably damaged apparently before the specimen was preserved. Of the cranium only the basis cranii, and of the foramen magnum only the anterior wall exist. The number of vertebral bodies is normal throughout the cervical thoracic lumbar and sacral regions. The arches of the vertebræ with the muscles and skin that should cover them are all completely wanting, so that the vertebral canal lies widely open along its whole length. The skin of the back stops short in the neighbourhood of the open canal and thins away toward the unclosed canal, finally ending short of it in a free edge.

Brain and spinal cord are completely wanting. The spinal dura mater instead of forming a tubular sac is unclosed behind and forms a shallow gutter, along the middle of which extends a thin irregular membrane which apparently represents the spinal cord. A similar but thicker membrane represents the brain. On raising the lateral edge of the dura mater a complete series of well-developed spinal-ganglia are seen, which contain well-formed ganglion cells and myelinate nerve-fibres. From the central end of each ganglion passes a well-developed compact bundle of nerve-fibres, the size of which is proportionate to that of the ganglion. Each compact bundle pierces the dura mater almost immediately, and then spreads into a long fan-shaped leash of filaments, which in the case of the lumbar sacral and thoracic nerves all turn upward and lie traceable for long distances upon the fibrous membrane which stretches along the mid-floor of the neural canal. Thus in the case of the 1st sacral nerve I was able without dissection to trace one of these dorsal (sensory) root filaments as high as the 5th thoracic level. By dissection they could not be traced much higher than by mere inspection. I could trace none of them up to the top of the cervical region. I looked very carefully for evidence of any of the filaments of these roots running downward as well as upward, since Cajal and others have abundantly proved the bifurcation of the posterior root-fibres into ascending and descending stems. I could find no trace of any descending filaments. On the other hand of the dorsal

(sensory) roots of the nerves of the brachial region the filaments descend in large leashes. Thus I easily traced filaments of the 6th cervical root as low as the 5th thoracic vertebra. From these roots it was not easy to find any that ascended, they were so fine and few.

From the distal end of each ganglion passes outwards a spinal nerve, which receives no ventral (motor) root. No trace of any ventral (motor) spinal roots exists either outside or inside the dura mater. The only nerve-bundles discoverable inside (*i.e.* on the dorsal side of) the dura mater are those of the above described dorsal (sensory) root filaments. The dura mater itself is nowhere perforated except by the row of foramina in it through which the dorsal (sensory) roots run.

The spinal nerves thus formed exclusively by the dorsal (sensory) roots proceed in the brachial and lumbo-sacral regions to make limb plexuses which differ in no particular of arrangement from the normal, except that some of the branches of the plexus appear disproportionately small. No named branches are absent from either of the limb plexuses.

In the whole of the anterior and posterior limbs the usual muscular branches are all obvious to ordinary dissection and show myelinate nerve-fibres when examined microscopically. In the intercostal spaces and in the abdomen nerves can be readily followed into the intercostal and abdominal muscles. The phrenic nerve is traceable from the diaphragm up through the thorax and neck to two filaments of origin, of which the larger comes from the 4th cervical ganglion, the smaller from the 5th ganglion. Among the muscular nerves traced may be specially mentioned the suprascapular, the posterior interosseous of the forearm, the nerves to *serratus anticus* (*serratus magnus*), *pronator quadratus*, the obturator trunk and its divisions and the nerve to *obturator internus*: the usual large nerve to *psaos* is traceable to the 3rd and 4th lumbar ganglia. The only remark to be made as to the appearance of these and all the muscular nerves is that they seem somewhat disproportionately thin, but not very obviously so.

I am unable to find the 11th, 12th or 13th cranial nerves but the condition of preservation of the orbit is bad. The optic nerve, the 5th cranial, the auditory, the glossopharyngeal, and vagus are all easily found. The auditory nerve before it enters the petrous bone has a well-marked ganglion upon it. The vagus is a very large trunk and gives off exactly its usual branches, including recurrent laryngeal, cardiac and pulmonary. The hypoglossal trunk reaches the tongue and gives off a large leash of lingual twigs as well as its usual branches to *styloglossus*, *hyoglossus*, *geniohyoideus*, *geniohyoglossus*, and *thyrohyoideus*. It gives off *n. descendens noni* as usual. Tracing the normal-looking nerve-trunk backwards however it seems to be almost exclusively formed by a branch from the 2nd cervical ganglion and another from the vagus below the vagus ganglion. I say almost, because a filament of it seems

traceable to the base of the skull posterior to the vagus exit and I then lose it. The accessory portion of the spinal accessory exists; of the spinal portion inside the dura mater I can find no evidence.

The prevertebral ganglia of the sympathetic, the cervical sympathetic trunk with its ganglia, the splanchnic trunks, &c. all exist and are normal in appearance.

I do not enumerate the list of sensory nerve trunks to the various muscles of the limb, &c. all demonstrable in this fœtus. It is sufficient to make the general statement that no muscular nerve in the limbs, trunk or neck was found wanting, although there existed not a single motor (ventral) spinal nerve-root in any segment. In view of present knowledge of the growth of the peripheral nervous system this must mean that all and each of the muscles of the limbs, trunk and neck receive abundance of myelinate fibres from the sensory root-ganglia.

An instructive feature in the specimen is that, just as in Leonava's, the striated muscles and their fibres revealed no obvious departure from the normal although the anterior cornual cells of the cord were non-existent. It is usual to suppose that the anterior cornual cells have a trophic influence on the fibres of their striate muscles. There is the well-known fact that destruction of the ventral cornual cells does after birth rapidly bring in train degeneration of the fibres of skeletal muscles. The "trophic" influence of the cells must therefore lie still in abeyance during the period of foetal life. Perhaps the muscular degeneration of later periods is more rightly apprehended as a result of forced inactivity in paralysed muscles accustomed to be active, and not strictly of loss of a pure trophic influence exerted upon them by nerve-cells.

The specimen further demonstrates that the tissue of the *neural crest*, and that laid down for the sympathetic ganglia, are each capable of progressing to full development altogether independently of, and in spite of, actual destruction of their parent tissue of the *medullary canal*.

VI. Remarks on the physiological condition of the nerves and muscles, the ventral-root fibres being degenerated.

The muscles become extremely wasted. Thus: forty-two days after section of the ventral roots (and dorsal roots proximal to ganglia) of 6th, 7th, 8th, and 9th post-thoracic nerves of Cat, *gastrocnemius* and *soleus* weighed hardly more than one-half their weight on the normal

side. The muscles retained their faradic contractility, and in none of the similar experiments have I ever found the faradic contractility wanting. Moreover the muscles have never exhibited marked fatty degeneration: although the eye-muscles 30 days after section of the 111rd cranial were markedly fattily degenerated. Onset of rigor mortis is delayed in the muscles.

On applying fairly strong (easily perceptible by tongue) faradic currents to the nerves of the muscles no reply was detected in them, although on the normal side strong contraction was produced by currents not perceptible to the tongue. On applying very strong currents (unbearable or hardly bearable by tongue) especially of fairly rapid repetition, *e.g.* 50 per sec., a peculiar contraction of the muscles was elicited. The most striking instance of this kind was obtainable quite constantly from the sciatic nerve. This trunk, as it issues from pelvis in Cat and Monkey, consists of three large nerves, the peroneal, the tibial, and the division to the hamstring muscles. Excitation of the peroneal high up under *quadratus femoris* gives slow, feeble, but steady dorso-flexion of ankle and sometimes extension of toes; the movement may continue 5" after cessation of the application of the current, and then the joints slowly return to their previous position. The steadiness of the movement is maintained under slow rates of interruption of current which give clonus in the sound limb. Similar excitation of the tibial nerve under *quadratus femoris* gives similar slow feeble plantar flexion of ankle and sometimes of digits, persisting a short time after withdrawal of current, and slowly subsiding. Crushing the nerves by ligation a couple of centimeters peripheral to point of application of electrodes stops the phenomenon. Regarding escape of current, the point of application of the electrodes is 200 mm. and more from the point at which the nerves excited enter the muscles involved. The phenomenon is not obtained after excision of the ganglia as well as section of the ventral roots. It is tempting to relate it to the intrafusal muscle-fibres. The phenomenon has nothing to do with regeneration of fibres in the peripheral nerves because it is elicitable where no regenerate fibres are detectable, and the contraction obtained through even a few regenerate fibres is far more brisk, and strikingly different in character. It appears related to the "pseudo-motor reaction" described by Heidenhain in the case of the tongue muscles after section of hypoglossal nerve.

The two questions put at outset of this Paper are therefore answered thus: (1) among the fibres in the nerves of *vastus medialis* and the

hamstring muscles from a third to a half are afferent, and these are fibres varying from 2μ — 20μ diam., (2) although *vastus medialis* is so peculiarly related to the "knee-jerk," and has in its nerve-trunk both the afferent and efferent fibres for the spinal arc with which the "jerk" is closely bound, the anatomical constitution of its nerve does not appreciably differ from that of the other divisions of *quadriceps femoris* not similarly related to the "jerk."

VII. **Remarks on recurrent fibres and scattered ganglion cells in the ventral (anterior) spinal nerve-root.**

After section of the ventral (motor) root a few nerve-fibres degenerate on the cord side of the section, and not quite all fibres degenerate on the peripheral side of the section. The fibres which do not conform with the rest of the ventral root must afford the basis of the well-known recurrent sensibility of the motor root, traced by Bernard and Schiff to the dorsal (posterior) root. Joseph however found no recurrent fibres in the root of the 2nd cervical nerve. In my preparations I have had opportunity to study the anatomy of the recurrent bundle in the lumbo-sacral of Monkey and Cat. In most of the lumbo-sacral roots I have however found it a very obvious though somewhat scattered collection of fibres. In one instance I found none in the root of the 6th lumbar nerve. Many of the recurrent fibres are traceable as the excitation experiments had indicated from the sensory root. They emerge from it near the distal end of the ganglion. The fibres range between 2μ and 19μ diameter. The majority are detached from the sensory root as a compact bundle, and remain little scattered for some distance within the motor root. The bundle consists of 5—40 fibres. I have not seen more. Besides the bundle there exist a few scattered fibres for the most part small. I am not sure that these are derived from the (posterior) root. The number of recurrent fibres appears roughly proportionate to the size of the root, a large root contains more than a small, *e.g.* 16 recurrent fibres in the 9th sub-thoracic root, 38 in the 8th root.

As first pointed out by Schäfer a certain number of ganglion cells exist in the ventral (motor) roots of the lumbar region of the Cat. I find such also in the Monkey. Cells exist similarly in the root of the 11th cranial (Rosenthal, Reissner). I find that some of Schäfer's cells lie in close proximity to the recurrent fibres, and I have specimens in which such cells lie actually in the recurrent bundle. The cells are for the most part arranged in short rows so that in serial sections four

or five crop up one after another at the same point in succeeding sections. The cells resemble closely the smaller cells of the spinal ganglion, they range in size from 30μ — 46μ . It is natural to connect the presence of the fibres with the cells; but in many cases the cells are situate quite distant from the recurrent fibres, and I have failed in many trials to trace a myelinate fibre distinctly to and from a cell by following the series of sections. In one instance I found the recurrent fibres in the 5th lumbar root extremely few, only six fibres. The ganglion cells were also few, but I counted eight of them, *i.e.* more cells than fibres. It is possible that some of the cells are sympathetic, and many of them lie close under the connective tissue-sheath of the nerve root. Reissner has suggested that the cells in the *motor oculi* root are sympathetic. It is not always easy to distinguish sympathetic cells from those belonging to the spinal ganglion, *e.g.* the cells of the biliary ganglion closely resemble those of spinal ganglia. I am inclined to connect some of the smaller and more scattered of the recurrent fibres with the few small fibres found undegenerate in, or close beneath, the sheath of the segmental nerves after section of both spinal roots distal to the spinal ganglion. Those fibres it appears probable are of sympathetic origin.

VIII. Summary of Conclusions.

Some conclusions from the above observations may be summarised thus:

1. In a muscular nerve-trunk from one-third to one-half of the myelinate fibres are from cells of the spinal root-ganglion.
2. These fibres range in size (in fresh preparations) from 1.5μ to 20μ diam.
3. The largest of them are not the largest fibres in the muscular nerve-trunk; the largest in the nerve-trunk come from the ventral (motor) spinal root.
4. The largest root-ganglion fibres in the muscular nerve are larger than any fibres in the cutaneous nerves of the limb and than any in the articular nerves examined.
5. The smallest myelinate fibres in the muscular nerve are for the most part, perhaps entirely, root-ganglion fibres.
6. Macroscopic nerve-trunks are as regards their myelinate fibres in no case purely motor, all are sensori-motor or purely sensory. Such nerves as phrenic, hypoglossal, recurrent laryngeal, posterior interosseous contain abundance of fibres from sensory ganglia.

7. For the root-ganglion fibres in the muscles a special end-organ exists, this is the so-called "muscle-spindle" (Kühne).

8. The muscle-spindles lie numerous imbedded in the muscular tissue, and are especially frequent in the neighbourhood of aponeuroses, tendinous intersections and tendons.

9. The majority, perhaps all, the larger root-ganglion fibres in the muscular nerves terminate in "muscle-spindles"; the small nerve-fibres do not appear to end in spindle-organs; some seem to terminate after branching in free fibrils.

10. After section of the nerve supplying the muscle the muscle-fibres inside the spindles do not degenerate like the fibres composing the rest of the muscle.

11. The skeletal muscles and their primitive fibres can attain a very complete structural development in absence of the spinal cord and its roots.

12. The peripheral limb-nerves contain no myelinate fibres derived from the sympathetic system; but they contain large numbers of pale fibres; all their sympathetic fibres must therefore be among these.

13. In the lumbo-sacral region there exist recurrent fibres in the ventral spinal root as shown in other regions by Waller, Schiff, etc.

14. Schäfer's ganglion cells in the ventral spinal root, although many of them lie in proximity to the recurrent sensory bundle in the root, do not for the most part appear to be connected with those fibres.

15. In the lumbo-sacral nerves near their commencement exist a few minute and scattered myelinate fibres which do not degenerate after section of the nerves at their origin; the fibres appear related to the sheaths of the nerve-trunk, and may be "sympathetic."

16. All the fibres of the dorsal (posterior) spinal roots of the sacro-lumbar nerves remain sound (apart from traumatic degeneration for a few millimeters) on the distal (ganglionic) side of a section carried out between the ganglion and the cord; all on the spinal side degenerate.

17. Four to seven weeks after excision of the spinal root ganglia large numbers of minute myelinate nerve-fibres (less than 4μ) exist in the proximal (spinal) end of the dorsal (posterior) spinal root; these fibres resemble regenerate fibres.

PLATES V. VI. VII.

Fig. 1. Spinal root-ganglion fibres in a large branch of the hamstring nerve to the medial hamstring muscles (Monkey). Fifty-two days degenera-

tion allowed after section of the 5th, 6th, 7th, 8th and 9th post-thoracic ventral and dorsal spinal roots, the latter cut proximal to their ganglia.

Fig. 2. Spinal root-ganglion fibres in a branch to *tibialis posticus* and *flexor digitorum longus* (Cat), 6th, 7th, 8th and 9th post-thoracic ventral and dorsal spinal roots severed, the latter proximal to ganglia. Forty-nine days degeneration allowed.

Fig. 3. Spinal root ganglion fibres in a branch from hamstring nerve to *biceps femoris*; fifty-eight days after section of 6th, 7th, 8th and 9th post-thoracic ventral and dorsal spinal roots, the latter proximal to ganglia. A small nerve-twig to left hand consists only of large root-ganglion fibres.

Fig. 4. Twig from "knee-jerk" nerve (*vastus medialis*). All except root-ganglion fibres removed by forty-two days degeneration. A smaller twig shows very little sclerosis and contains large and small myelinate fibres.

Fig. 5. Twig to *femoralis*, normal (Monkey).

Fig. 6. Corresponding opposite nerve from same monkey; spinal root-ganglion fibres alone left. 3rd, 4th, 5th and 6th post-thoracic ventral and dorsal spinal roots cut, the latter proximal to ganglia. Fifty-four days degeneration allowed.

Fig. 7. Twig to *seminembranosus*, normal (Cat).

Fig. 8. Corresponding from opposite side, on which the 6th, 7th, 8th and 9th post-thoracic spinal ganglia and ventral roots had been excised thirty-four days. No myelinate fibres left.

Fig. 9. Corresponding twig from another cat of about the same size as preceding, in which 6th, 7th, 8th and 9th post-thoracic ventral and dorsal spinal roots had been cut, the latter proximal to ganglia. Thirty-four days degeneration allowed.

Fig. 10. Nerve to *vastus medialis* and adjoining part of *femoralis* (Monkey). Knee-jerk nerve. Normal.

Fig. 11. Corresponding nerve of opposite side, the 3rd, 4th, 5th and 6th post-thoracic ventral and dorsal spinal roots having been cut, the latter proximal to ganglion. Thirty-five days degeneration allowed.

Fig. 12. *Flexor digitorum brevis* muscle (Cat); root-ganglion fibres only remaining. 6th, 7th, 8th, and 9th post-thoracic ventral and dorsal spinal roots severed, the latter proximal to ganglia. Thirty-five days allowed for degeneration. Small intra-muscular nerve-twigs in cross section; from the smaller of these (purely motor) all myelinate fibres have disappeared, from the larger all but two (one 16μ , one 2μ). Near the smaller twig a small artery. Further to the right and above is the commencement of a "muscle-spindle;" into the capsule of this the large fibre seen in middle of figure was traceable in the series of sections made.

Fig. 13. *Gracilis* muscle, Monkey; root-ganglion fibres only remaining. Muscle-spindle containing eight muscle-fibres: near it a "spindle nerve"

containing five large myelinate fibres; also a motor nerve from which all myelinate fibres have disappeared. The *periaxial space* is well seen.

Fig. 14. *Adductor hallucis* muscle (Monkey). 6th, 7th, 8th and 9th post-thoracic ventral and dorsal spinal roots severed, the latter proximal to ganglia. Fifty days degeneration allowed. A compound "muscle-spindle" in cross section near one of its poles. Three large muscle-fibres and five small inside the spindle. A large thinly myelinate nerve-fibre is seen cut twice, obliquely, in the capsule of the organ.

Fig. 15. *Vastus medialis* muscle (Cat). 4th, 5th, 6th and 7th post-thoracic ventral and dorsal spinal roots severed, the latter proximal to ganglia. Sixty days degeneration allowed. Muscle-spindle through its *proximal polar region* containing three large and six small muscle fibres. A large root-ganglion fibre lies in the outer part of the capsule of the organ, a smaller myelinate fibre lies close to the muscle-fibres in the core of the organ.

Fig. 16. *Biceps femoris* (Cat). 6th, 7th, 8th and 9th post-thoracic ventral and dorsal spinal roots cut, latter proximal to ganglion. 106 days degeneration allowed. A "muscle-spindle" in cross section through its *equatorial region*. Three thinly myelinate nerve-fibres obliquely cut in the periaxial space. Nine muscle-fibres and two non-myelinate terminal nerve-fibres seen in core. The delicate tissue in the *periaxial lymph space* is visible.

Fig. 17. *Semimembranosus* muscle (Monkey). 6th, 7th, 8th and 9th post-thoracic ventral and dorsal spinal roots severed, latter proximal to ganglia. Fifty days degeneration allowed. A "muscle-spindle" in cross section through the equatorial region. Two myelinate fibres cut obliquely in the thickness of the capsule of the spindle; three cut fairly transversely just within the periaxial lymph-space. Six muscle-fibres and two non-myelinate nerve-fibres cut transversely within the core of the organ.

Fig. 18. Interosseous plantar muscle (Cat). Compound "muscle-spindle" in distal polar region not far from junction with equatorial region. One division of the spindle contains eight muscle-fibres, the other nine muscle-fibres. In the smaller division a myelinate fibre is seen in transverse section, in the larger a myelinate fibre curves across from the centre to the periphery of the intrafusal bundle. At one side of the spindle lies a large solitary "spindle" nerve-fibre enclosed in a well-developed loosely-fitting sheath of Henle.

For much assistance in the preparation of the microphotograms I have to thank the kindness of Mr A. F. Stanley Kent.