

- Rolles, C. J., Anderson, C. M., and McNeish, A. S. (1975a). Confirming persistence of gluten-intolerance in children diagnosed as having coeliac disease in infancy: usefulness of one-hour blood-xylose test. *Archives of Disease in Childhood*, **50**, 259–263.
- Rolles, C. J., Kendall, M. J., Nutter, S., and Anderson, C. M. (1975b). Reappraisal of the xylose test. *Archives of Disease in Childhood*, **50**, 748.
- Rolles, C. J., and McNeish, A. S. (1976). Standardised approach to gluten challenge in diagnosing childhood coeliac disease. *British Medical Journal*, **1**, 1309–1311.
- Schaad, U., Gaze, N., Hadorn, B., Pedrinis, E., Cottier, H., Lorenz, E., and Colombo, J. P. (1975). Der Blutxylosetest im Kindesalter: Korrelation des 1-Stunden-Blutxylosewertes mit der Anzahl intraepithelial gelegener Lymphocyten in der Dünndarmschleimhaut bei der Zöliakie. *Helvetica Paediatrica Acta*, **30**, 331–341.
- Schaad, U., Hadorn, B., and Gaze, H. (1977). Intraepithelial lymphocytes and one-hour blood-xylose in children with untreated coeliac disease. *Lancet*, **1**, 1264–1265.
- Sladen, G. E., and Kumar, P. J. (1973). Is the xylose test still a worth-while investigation? *British Medical Journal*, **3**, 223–226.

U. SCHAAD, H. GAZE, and B. HADORN

Gastrointestinal Unit, Department of Paediatrics, University of Berne, and Hôpital des Cadolles, Neuchâtel, Switzerland.

Correspondence to Dr U. Schaad, Department of Paediatrics, University of Berne, Inselspital, 3010 Berne, Switzerland.

Persistent neonatal hypoglycaemia due to glucagon deficiency

Glucagon deficiency as a possible cause of persistent neonatal hypoglycaemia has been discussed before (Wagner *et al.*, 1969; Gotlin and Silver, 1970; Zuppinger, 1975). Vidnes (1976) recently described a case of persistent hereditary neonatal hypoglycaemia due to glucagon deficiency; therapy with zinc-protamine-glucagon resulted in dramatic improvement. This was the first case in a child where glucagon deficiency was verified by glucagon determination. We here describe a further case of a newborn infant with persistent neonatal hypoglycaemia due to glucagon deficiency and treated by zinc-protamine-glucagon.

Case report

A boy was born after a normal pregnancy in August 1975 as the third child of healthy unrelated parents. He has 2 healthy siblings. No family history of infant deaths from hypoglycaemia was known. Birthweight was 3.7 kg. The child was breast fed, and the first day passed uneventfully. In the evening

of the second day he became drowsy and failed to suck. Next morning he was apathetic, breathed irregularly, and rolled his eyes. At admission to a local hospital blood glucose was low (0.9 mmol/l; 16 mg/100 ml) with a metabolic acidosis (pH 7.22, base excess -5.5 mmol/l (-5.5 mEq/l)). Treatment was started with infusion of glucose 10%; after 2 and 4 hours respectively the blood glucose value was 1.6 and 0.5 mmol/l (28.8, 9 mg/100 ml). Apart from the infusion therapy, which was continued, he received feeds of humanised milk, and prednisone was started. The first day after admission several convulsions were noted, but within a few days the clinical condition improved. During the next few weeks several attempts were made to reduce the frequency of oral feedings below 8 times per day, but each time the blood glucose level decreased and his condition deteriorated.

At the age of 3 weeks he was referred to the University Hospital. We found an alert but sweaty and restless baby with a length of 56.5 cm and a weight of 4250 g. The liver was palpable 1 cm below the costal margin. Blood was analysed for cortisol, insulin, thyroxine, growth hormone, lactate, pyruvate, and alanine levels. After 2 hours of fasting the levels of β -hydroxybutyrate and acetoacetate were respectively 37 and 15 μ mol/l (0.39, 0.15 mg/100 ml). Reducing substances in the urine were absent. Vanillylmandelic acid excretion was 4.5 nmol in 24 hours. No abnormal organic acids in the urine were detected by gas chromatography. Under a regimen of 12 oral feeds of humanised milk per day, blood glucose varied between 1.8 and 3.0 mmol/l (32, 54 mg/100 ml). A glucose tolerance test showed a high peak value after 45 minutes and rapid decrease to values below normal. Insulin regulation during the test was normal (Zuppinger, 1975; Fig. 1). A glucagon tolerance test showed a normal glucose mobilisation, followed by rapid decrease to values below normal: again insulin regulation was intact (Zuppinger, 1975; Fig. 2).

In the light of a possible glucagon deficiency we started treatment with zinc-protamine-glucagon IM at a dose of 2 mg, with 8 feeds per day. For 8–10 hours after the injection the blood glucose level remained above 3 mmol/l (54 mg/100 ml). When given twice daily, the effect lasted for 24 hours.

The clinical condition improved, and the frequency of feeds could be lowered to 6 times per day. In the next few months we had to increase the dosage of glucagon gradually, and stable glucose values could then be maintained. With a regimen of 6 feeds per day and two daily doses of 3.5 mg glucagon IM symptomatic hypoglycaemia did not occur. The patient was discharged in December 1975. After some months the parents discontinued the glucagon

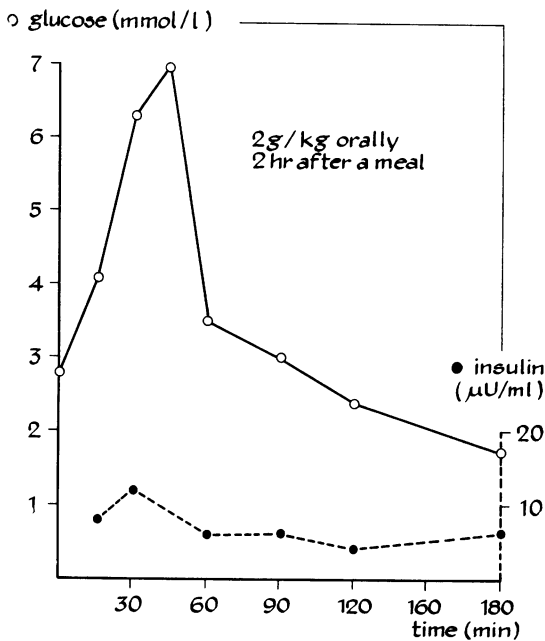


Fig. 1 Glucose tolerance test. See Table for conversion factor for glucose.

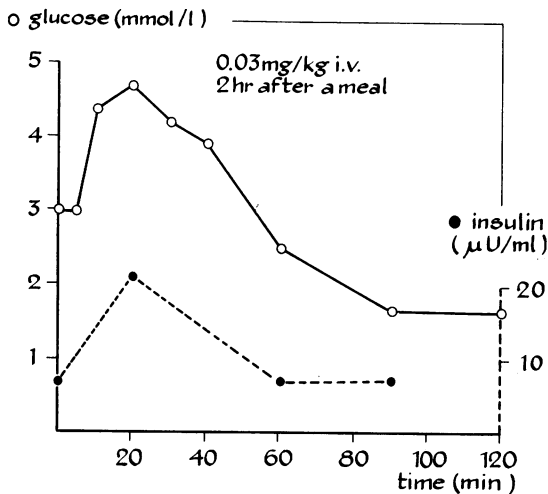


Fig. 2 Glucagon tolerance test.

injections, which resulted in a relapse, and therapy was resumed immediately.

In May 1976, he was readmitted for review. Glucagon was stopped and a regimen of 12 feeds per day started. After 5 days a glucose tolerance test showed much the same result as before. Fasting

glucagon and insulin values were determined on four occasions starting 10 days after glucagon therapy had stopped. Glucagon was estimated by the method of Aguilar-Parada *et al.* (1969); antibody 30K was used. Insulin values (Table) varied between 6 and 15 $\mu\text{U/ml}$, while glucagon values were below 10 ng/l .

Table Glucagon and insulin determinations

	Glucagon* (ng/l)	Insulin ($\mu\text{U/ml}$)	Glucose (mmol/l)
Patient (aged 9 m)	10	9	2.6
	10	15	3.4
	10	7	3
	10	6	2.8
4 control infants, fasted 4–10 h	105; 155;		5.9; 4.2; 4.6; 4.7
	145; 145		

*Precision of the assay ± 5 ng/l .

Conversion: SI to traditional units—Glucose: 1 $\text{mmol/l} \approx 18$ mg/100 ml .

Glucagon therapy was resumed and feedings reduced to 6 per day. On neurological examination no specific signs were noted, but the level of motor development was only 4 months at the age of 9 months. Electroencephalogram and echoencephalogram were normal. At the age of 16 months motor development was 11 months.

Discussion

Persistent neonatal hypoglycaemia is rare and has been classified by Cornblath and Schwartz (1976) into four groups. In the first group the hypoglycaemia is due to hormone deficiency (congenital hypopituitarism, or insufficiency of growth hormone, adrenal hormone, or thyroid hormone); in the second group to hyperinsulinism; in the third group to hereditary defects in carbohydrate metabolism; and in the fourth group to hereditary defects in amino acid metabolism.

The commoner hormone deficiencies were excluded in our patient by the appropriate tests. Hyperinsulinism was absent. Absence of hepatomegaly and the good glucose response to injection of glucose eliminate glycogen storage disease type 1 and glycogen synthetase deficiency as possible causes of the hypoglycaemia. Normal blood lactate levels and normal serum alanine levels argue against deficiency of one of the gluconeogenic key enzymes. Normal blood levels of amino acids and organic acids exclude hereditary defects in amino acid metabolism. The low levels of glucagon in plasma, and the restoration of almost normal blood glucose levels by long-acting glucagon, support a diagnosis of congenital glucagon deficiency.

There have been several reports of α -cell deficiency and neonatal hypoglycaemia but without

measurements of plasma glucagon (McQuarrie *et al.*, 1950; Wagner *et al.*, 1969; Gotlin and Silver, 1970). In Vidnes's (1976) case of persistent neonatal hypoglycaemia due to glucagon deficiency, verified by measuring plasma, treatment with zinc-protamine-glucagon was successful: after 2 months the dosage of glucagon had to be gradually increased as in our case, probably because of antibody production.

Neonatal hypoglycaemia due to glucagon deficiency may be extremely dangerous for the neonate. During glucose need it is glucagon, through a mechanism that remains to be elucidated, that converts the liver to a 'ketogenic mode' and thereby maintains a level of hepatic ketone production necessary to meet cerebral fuel needs (Unger and Orci, 1976). The ketones are an important alternate substrate for the neonatal brain. Ketogenesis in our patient was not adequately studied because the fasting period was limited.

Summary

In a newborn baby, suffering from persistent severe hypoglycaemia with convulsions glucagon deficiency was shown. Treatment with zinc-protamine-glucagon injection twice daily resulted in normal blood glucose levels. Motor development is delayed.

We thank Mr J. B. C. van Veen (Novo Industries AS, Amsterdam) for the zinc-protamine-glucagon preparation, and Dr T. J. Benraad (Department of Medical Biology) for insulin and growth hormone measurements.

References

- Aguilar-Parada, E., Eisentraut, A. M., and Unger, R. H. (1969). Effects of starvation on plasma pancreatic glucagon in normal man. *Diabetes*, **18**, 717-723.
- Cornblath, M., and Schwartz, R. (1976). *Disorders of Carbohydrate Metabolism in Infancy*. Saunders, Philadelphia.
- Gotlin, R. W., and Silver, H. K. (1970). Neonatal hypoglycaemia, hyperinsulinism and absence of pancreatic alpha cells. *Lancet*, **1**, 1346.
- McQuarrie, I., Bell, E. T., Zimmerman, B., and Wright, W. S. (1950). Deficiency of alpha cells of pancreas as possible etiologic factor in familial hypoglycemia. (Abst.) *Federation Proceedings*, **9**, 337.
- Unger, R. H., and Orci, L. (1976). Physiology and pathophysiology of glucagon. *Physiological Reviews*, **56**, 778-826.
- Vidnes, J. (1976). Persistent hereditary neonatal hypoglycaemia caused by glucagon deficiency. (Abst.) *Pediatric Research*, **10**, 881.
- Wagner, T., Spranger, J., and Brunck, H. J. (1969). Kongenitaler alpha-Zellmangel als Ursache einer chronischen infantilen Hypoglykämie? *Monatsschrift für Kinderheilkunde*, **117**, 236-238.
- Zuppinger, K. A. (1975). *Hypoglycemia in Childhood. Evaluation of Diagnostic Procedures*. Monographs in Paediatrics, 4, Karger, Basel.

L. A. KOLLÉE, L. A. MONNENS, V. CEJKA, and R. H. WILMS

Department of Paediatrics, University of Nijmegen, and Department of Clinical Endocrinology, University of Amsterdam, The Netherlands.

Correspondence to Dr L. A. Kollée, Department of Paediatrics, University of Nijmegen, Geert Groteplein Zuid 20, Nijmegen, The Netherlands.

Pulmonary interstitial emphysema requiring lobectomy

Complication of assisted ventilation

Ventilatory techniques for treating newborn infants with hyaline membrane disease (HMD) have led to improvement in prognosis (Rawlings *et al.*, 1971), although their use involves potential hazards (Reynolds, 1975). We describe an infant with HMD treated with intermittent positive pressure ventilation (IPPV) who developed localised pulmonary interstitial emphysema which progressed to produce tension and to require lobectomy.

Case report

This male infant was the product of the mother's first pregnancy, this being complicated by diabetes. Labour began spontaneously at 36 weeks' gestation and after 11 hours the infant was delivered with the assistance of forceps. Apgar score was 5 at 1 minute and apart from intranasal oxygen, no resuscitation was required. The birthweight was 3040 g and no malformations were detected. Soon after delivery expiratory grunt, tachypnoea, rib retraction, and cyanosis developed, and chest x-ray showed a reticulogranular pattern consistent with HMD.

At 3 hours arterial oxygen tension (P_{aO_2}) was only 67 mmHg (8.9 kPa) breathing 100% oxygen. Nasal continuous positive airways pressure was begun. At 5 hours, due to continued deterioration, an endotracheal tube was passed and IPPV started, using a Loosco Amsterdam Infant Ventilator. Inspired pressure was 20-25 cm H₂O with a positive end expiratory pressure of 5 cm H₂O and the inspired oxygen concentration (F_{IO_2}) was 1.0. On this regimen the infant improved and F_{IO_2} was gradually reduced to 0.6.