

## References

- Allen, M., Diamond, L. K., and Howell, D. A. (1960). Anaphylactoid purpura in children (Schönlein-Henoch syndrome); review with a follow-up of the renal complications. *American Journal of Diseases of Children*, **99**, 833-854.
- Cream, J. J., Gumpell, J. M., and Peachey, R. D. G. (1970). Schönlein-Henoch purpura in the adult; a study of 77 adults with anaphylactoid or Schönlein-Henoch purpura. *Quarterly Journal of Medicine*, **39**, 461-484.
- Fitzsimmons, J. S. (1968). Uncommon complication of anaphylactoid purpura. *British Medical Journal*, **4**, 431-432.
- Gardner, D. (1948). The Schönlein-Henoch syndrome (anaphylactoid purpura). *Quarterly Journal of Medicine*, **17**, 95-122.
- Imai, T., and Matsumoto, S. (1970). Anaphylactoid purpura with cardiac involvement. *Archives of Disease in Childhood*, **45**, 727-729.
- Jacome, A. F. (1967). Pulmonary hemorrhage and death complicating anaphylactoid purpura. *Southern Medical Journal*, **60**, 1003-1004.
- Lewis, I. D., and Philpott, M. G. (1956). Neurological complications in the Schönlein-Henoch syndrome. *Archives of Disease in Childhood*, **31**, 369-371.
- Silber, D. L. (1972). Henoch-Schönlein syndrome. *Pediatric Clinics of North America*, **19**, 1061-1070.

J. A. McV. GARNER

Royal Alexandra Hospital, Marine Drive, Rhyl, Clwyd, North Wales.

## 13q- syndrome

### Family study

Clinical syndromes due to duplication or deletion of part of a chromosome are much less commonly observed than those due to trisomy or monosomy. De Grouchy (1976) gives an incidence of 0.11 per 1000 live births for recognized deletion syndromes as compared with 1.29 for the trisomies. The trisomies are due to anomalous separation of parental chromosomes during gametogenesis and neither the sibs of affected individuals nor the parents show abnormalities in the chromosomes of blood lymphocytes or extragonadal tissues. Duplications or deletions, however, are often the result of translocations which commonly exist in a balanced form in one of the parents and may well affect any sibs. Cytogenetic investigation of the family is therefore important in such circumstances and this need is not perhaps sufficiently appreciated in clinical practice.

We report the clinical and cytogenetic findings in the family of an infant who presented with anomalies due to partial deletion of a number 13 chromosome—anomalies which together form a recognizable clinical syndrome.

### Case report

A girl weighing 1.96 kg was born 3 weeks after term in the 37-year-old mother's tenth pregnancy. Apart from unstable lie resulting in breech delivery, pregnancy was normal. Clinical examination confirmed that the child was mature and therefore small-for-dates. The head circumference was 31 cm and the length 40 cm. The following features were noted soon after birth: a triangular-shaped skull with frontal bossing, low-set ears, broad nasal bridge, bilateral ptosis, and choroidal colobomata. The neck was short with markedly redundant skin folds. The labia minora were rudimentary. The thumbs were small and both they and the fifth fingers were proximally placed. There was partial fusion of the fourth and fifth toes on both feet, and the feet were held in correctable equinovarus position. Within the first week intermittent cyanosis and a cardiac murmur were noted. Chest x-ray and electrocardiogram showed no specific abnormality, but investigation of the congenital heart disease was not pursued further. Hypotonia and poor feeding continued throughout life and there was no apparent visual awareness. The child died at the age of 7 months of bronchopneumonia.

Both parents and all 7 older sibs were examined and were well and physically normal. 2 of the mother's previous pregnancies ended in stillbirth. The first baby was stillborn at term; he weighed 4.14 kg and at necropsy a normal physical appearance was noted. The sixth pregnancy ended at 24 weeks with the spontaneous delivery of a stillborn female infant weighing 0.54 kg; gross appearance was normal, but necropsy was not performed.

### Necropsy findings

**Brain.** There was failure of perforation of the cribriform plates of the ethmoid bones of the skull. The brain showed two cerebral hemispheres in which there were identifiable hippocampal formations, but was externally abnormal as both olfactory bulbs and tracts were missing. Slicing the brain showed the following abnormalities: the corpus callosum was reduced in thickness and showed marked thinning at its rostral end. This structure was also reduced in length and the splenium was not well developed. There was some dilatation of both lateral ventricles and of the third ventricle. The caudate nuclei were not well developed structures and were represented by bands of grey matter bounding each lateral ventricle. The fornix, which had developed bilaterally, remained widely separated with formation of two

septa instead of a normal septum lucidum. This allowed the third ventricle to extend up to the corpus callosum.

*Lungs* showed extensive bronchopneumonia. The *cardiovascular abnormality* was a preductal coarctation of the aorta with a small persistent left-sided superior vena cava. The ductus arteriosus had closed. The heart was normally situated. The *uterus* was absent and only the fimbrial ends of the fallopian tubes had formed. The ovaries were narrow but histologically normal. The *thymus* was hypoplastic. The *mesentery* was unattached and there was a Meckel's diverticulum.

**Cytogenetics.** Lymphocyte preparations (with Giemsa banding) showed the following karyotypes.

Mother	37 yrs	46XX, t(13q- 3q+)
Father	29 yrs	46XY
Patient	2 w	46, XX, 13q-
Sibs		
Female	13 yrs	46XX, t(13q- 3q+)
Male	12 "	46XY, t(13q- 3q+)
Male	11 "	46XY
Male	9 "	46XY
Male	5 "	46XY, t(13q- 3q+)
Female	3 "	46XX, t(13q- 3q+)
Female	2 "	46XX

The mother and 4 sibs have a balanced translocation from the long arm of a no. 13 chromosome to the long arm of a no. 3 chromosome, with no appreciable loss of chromosomal material. The patient shows a similar deletion from the long arm of a no. 13 and no abnormality of the no. 3. In both the patient and the affected relatives the break point on the no. 13 chromosome appears to be immediately proximal to the distal dark band at the negative band q22. The deleted segment (3 1-3) includes the whole of the distal dark band (Paris Conference, 1972).

### Discussion

The most commonly recognized clinical syndrome associated with abnormality of chromosome 13 is Patau's syndrome (trisomy 13). Deletion syndromes, with or without ring chromosome formation, are also well recognized (Allderdice *et al.*, 1969; Grace *et al.*, 1971; McCandless and Walker, 1976), however, and attempts have been made since the introduction of chromosome banding techniques to correlate specific clinical features with the bands on the deleted part of the chromosome (Lewandowski and Yunis, 1975).

Table *Clinical features of the 13q- syndrome*

Performance:	Psychomotor retardation*
Growth:	Low birthweight* (often small-for-dates)
Craniofacial:	Microcephaly*, trigonocephaly* Broad, prominent nasal bridge* Epicanthic folds* Ptosis*, microphthalmia Colobomata*, retinoblastoma Protruding maxilla and upper incisors, micrognathia
Neck:	Large, prominent low-set ears*
Cardiac:	Short, with redundant skin folds*
Skeletal:	Congenital heart disease* Focal lumbar agenesis Hip dislocation
Extremities:	Hypoplastic* or absent thumbs Foot deformities* (often talipes equinovarus)
Perineum:	Imperforate anus Hypospadias, perineal fistula Undescended testes; bifid scrotum

\*Features noted in the case described.

The child we describe shows many of the characteristic features of the 13q- syndrome, which are listed in the Table. Now described in over 50 cases, the 13q- syndrome may be suspected clinically on the basis of physical appearance; however, chromosomal studies with banding techniques are necessary to confirm the diagnosis and to specify the exact nature of the deletion. When family studies are undertaken after diagnosis of a deletion or duplication syndrome, balanced translocations in phenotypically normal family members may well be found (Stoll and Halb, 1974; Schwanitz *et al.*, 1975). The family described here illustrates this well. Since the children of a person with a balanced translocation would theoretically be at equal risk of four possibilities, namely normality, balanced translocation, duplication, and deletion, the importance of thorough family studies is clear. Of the 7 living children in this family, 3 are normal and 4 carry the balanced translocation. The karyotypes of the 2 children who died perinatally are unknown, but as they were phenotypically normal it is unlikely that either a deletion or duplication was present. It seems possible, therefore, that deletion or duplication may adversely affect the viability of the conceptus in early pregnancy. Nonetheless, both deletions and duplications have been described in families with this type of balanced translocation (Stoll and Halb, 1974; Schwanitz *et al.*, 1975). Thorough cytogenetic studies, followed by appropriate genetic counselling with reference to the possibility of amniocentesis and selective abortion, are mandatory when such a family is discovered.

### Summary

A patient is described who had a deletion involving the long arm of chromosome number 13. The mother

and 4 of 7 living sibs showed a balanced translocation from the long arm of a number 13 chromosome to the long arm of a number 3 chromosome. We stress the importance of investigating the families of children with chromosomal defects.

#### References

- Allderdice, P. W., Davis, J. G., Miller, O. J., Klinger, H. P., Warburton, D., Miller, D. A., Allen, F. H., Jr., Abrams, C. A. L., and McGilvray, E. (1969). The 13q-deletion syndrome. *American Journal of Human Genetics*, **21**, 499-512.
- De Grouchy, J. (1976). Human chromosomes and their anomalies. *Aspects of Genetics in Paediatrics*, p. 5. Report of the Third Unigate Paediatric Workshop. Ed. by D. Barltrop. Fellowship of Postgraduate Medicine, London.
- Grace, E., Drennan, J., Colver, D., and Gordon, R. R. (1971). The 13q-deletion syndrome. *Journal of Medical Genetics*, **8**, 351-357.
- Lewandowski, E. C., Jr., and Yunis, J. J. (1975). New chromosomal syndromes. *American Journal of Diseases of Children*, **129**, 515-529.
- McCandless, A., and Walker, S. (1976). D<sub>13</sub> ring chromosome syndrome. *Archives of Disease in Childhood*, **51**, 449-453.
- Paris Conference (1972). Standardization in human cytogenetics. *Birth Defects: Original Article Series*, **8**, No. 7. The National Foundation, March of Dimes.
- Stoll, C., and Halb, A. (1974). Trisomie 13 partielle par translocation 46XX, t(3: 13) (p26: q21) maternelle. *Pédiatrie*, **29**, 725-729.
- Schwanitz, G., Reither, G., Grosse, G., Hägele, Ch., Grosse, K.-P., and Gutfried, U. (1975). Partial monosomy 13 as a result of a balanced translocation 3/13 pat. *Humangenetik*, **28**, 93-96.

A. CARMICHAEL, D. P. ADDY, W. R. SHORTLAND-WEBB, A. H. CAMERON, and ISLAY C. S. DAVIES  
*Departments of Paediatrics and Pathology, Dudley Road Hospital, and Department of Cytogenetics, Children's Hospital, Birmingham.*

Correspondence to Dr. D. P. Addy, Department of Paediatrics, Dudley Road Hospital, Dudley Road, Birmingham B18 7QH.

## Failure to thrive at the breast: an old problem revisited

In recent years there has rightly been considerable effort to persuade British mothers to breast feed (Department of Health and Social Security, 1974; Sloper *et al.*, 1975). Although not totally successful, there are now more mothers attempting breast feeding than for some considerable time.

Breast feeding is not without its complications, however. One well-known problem is underfeeding. Typically these infants are restless, cry excessively, and fail to gain weight adequately (James, 1956; Shanks, 1973). However, there is another presentation of underfeeding which, although well recog-

nized by earlier paediatricians, may be less appreciated by the present generation of doctors and nurses. This is the breast-fed infant who fails to thrive without complaint. We have already drawn attention to the problem in a report of extremely poor weight gain in such an infant (Davies and Evans, 1977). We here describe a further 4 infants who as well as showing poor weight gain, also show varying degrees of retardation of gain in length and head growth.

#### Case reports

Four infants were born at term after uncomplicated pregnancies and deliveries. They were of appropriate size for gestation and had no neonatal problems. Each infant was entirely breast fed. There were no early problems with breast engorgement or sore nipples. The mothers of 3 infants had previously successfully breast fed at least one infant and they were all intelligent women from good social backgrounds.

The infants were between 8 and 12 weeks old. 3 were seen at a hospital 'well baby' clinic, and the fourth was an outpatient referral. All looked emaciated. As well as showing very poor weight gain they also showed growth failure of length and head circumference to a varying extent (Fig.). The mothers

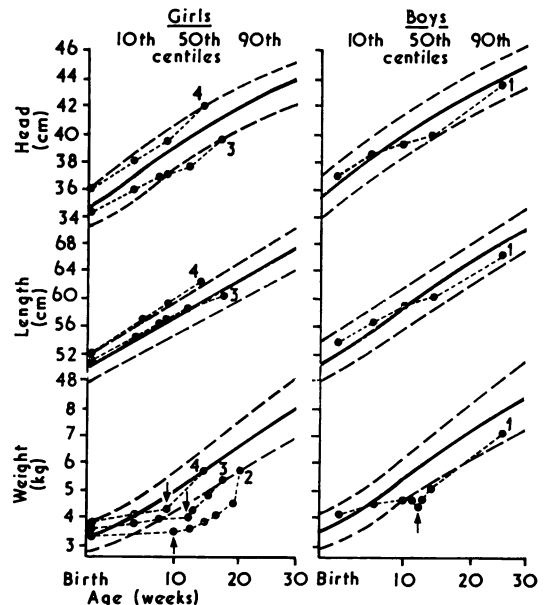


Fig. Growth patterns of the 4 infants. The 10th, 50th, and 90th centiles are from the data of Gairdner and Pearson (1971). The arrows indicate the start of bottle feeds in Cases 1, 2, and 3, and the start of 3-hourly breast feeds in Case 4.