

Concurrence of Graves's disease and Hashimoto's thyroiditis

TAMOTU SATO, IKURO TAKATA, TOKUO TAKETANI, KOHKI SAIDA, AND HIRONORI NAKAJIMA

From the Department of Paediatrics, School of Medicine, Kanazawa University, Takaramachi 13-1, Kanazawa, 920 Japan

SUMMARY Early histological changes in the thyroid gland were examined in 30 patients with juvenile thyrotoxicosis, by means of needle biopsy. Based on the degree of lymphocytic infiltration and degenerative changes in follicular epithelium, results were classified into four groups. *A*: hyperplastic changes without cellular infiltration (6 patients, 20%); *B*: hyperplastic changes with areas of focal thyroiditis <30% of specimen (10 patients, 33%); *C*: those with 30 to 60% areas of thyroiditis (10 patients, 33%); *D*: almost diffuse thyroiditis (4 patients, 13%). Moderate to severe lymphocytic thyroiditis was frequently present in the early stage of hyperplastic thyroid glands.

The clinical significance of the 4 histological groups was evaluated. Neither clinical signs nor routine laboratory tests could differentiate these groups except group *D*, in which thyrotoxic signs were mild and transient. However, serum antithyroid antibodies tended to increase in accordance with severity of thyroiditis. The rate of remission was high in groups *C* and *D*, whereas relapse was frequent in group *A*. These results suggest that Graves's disease and chronic lymphocytic thyroiditis are closely related in the early stage of thyrotoxicosis in children, and that the clinical course may be considerably altered by the degree of associated thyroiditis.

Varying degrees of lymphocytic infiltration have been reported to coexist in approximately 20% of thyroid glands of thyrotoxic children (McClintock *et al.*, 1956; Saxena *et al.*, 1964), but little has been reported of the significance of the cell infiltration in the hyperplastic thyroid. In adults with Graves's disease the significance of concomitant thyroiditis has been difficult to interpret because most of the specimens were obtained surgically after several years of antithyroid medication, while there are few reports of the early histological picture of untreated thyrotoxicosis in children. The association of thyrotoxicosis and autoimmune thyroiditis has been reported by several authors (Doniach and Hudson, 1959; Doniach *et al.*, 1960; Buchanan *et al.*, 1961; Fatourechi *et al.*, 1971; Gavras and Thomson, 1972; Nakajima *et al.*, 1975), but it remains uncertain whether this is an incidental association of two different diseases or a varied manifestation of a single entity. The incidence of the association of Hashimoto's thyroiditis in juvenile thyrotoxicosis is not established. Recently a number of common immunological features between Graves's disease and Hashi-

moto's thyroiditis have been reported (Volpé *et al.*, 1972, 1974), so we have therefore attempted to elucidate the early histological changes of juvenile thyrotoxicosis, and the incidence and the degree of associated thyroiditis, with a view to re-evaluating the clinical significance of lymphocytic infiltration in hyperplastic thyroid tissue.

Patients and methods

Thirty patients with juvenile thyrotoxicosis, aged 6-18 years, were studied. Thyrotoxicosis was diagnosed by the presence of typical clinical signs and goitre with raised serum thyroxine (T4-I) and triiodothyronine (T3). In most of the patients histological specimens were obtained before treatment by needle biopsy with Franklin-Silverman's needle from both lobes of the thyroid gland. But in patients with florid toxic symptoms the biopsy was taken after one month of propylthiouracil (PTU) administration. 2 patients who had been thyrotoxic in the past and were euthyroid or hypothyroid without treatment at the time of biopsy were also included in the study.

Thyroid histology was examined by the pathologist after staining with haematoxylin-eosin, and the

degree of thyroiditis classified according to the scheme of Woolner *et al.* (1959). Grade of goitre was expressed by the criteria of Shichijo (1958) (details in Table 1). Serum T4, T3, and thyrotrophin concen-

Table 1 *Clinical manifestations of the patients*

| | Group | | | |
|---------------------------|-------|------|------|------|
| | A | B | C | D |
| No. of patients | 6 | 10 | 10 | 4 |
| Age (average) (years) | 12.6 | 11.8 | 12.6 | 13.2 |
| Sex (male:female) | 0:6 | 2:8 | 1:9 | 0:4 |
| Goitre, grade* | | | | |
| 2.5 | 3 | 3 | 3 | 2 |
| 3 | 2 | 6 | 7 | 2 |
| 4 | 1 | 1 | 0 | 0 |
| increased consistency | 3 | 9 | 10 | 4 |
| Prominence of eyes | 4 | 7 | 4 | 0 |
| Palpitation, tachycardia | 6 | 10 | 9 | 2 |
| Restlessness, tremor | 4 | 5 | 5 | 1 |
| Perspiration, weight loss | 4 | 7 | 9 | 1 |

*2.5 = the thyroid gland is just visible with the head in normal position and obviously visible with the head drawn backward; 3 = the gland is obviously visible with the head in normal position; 4 = the gland bulges forward giving the appearance of a tumour (Shichijo, 1958).

trations were measured by the column T4 method and radioimmunoassay respectively. Thyrotrophin-releasing hormone (TRH) stimulation test was performed before and one year or more after PTU treatment by intravenous injection of a single bolus of synthetic TRH (10 µg/kg), and blood samples were obtained at 0 and 30 minutes. T3 suppression test was performed before and 7 days after administration of 75 µg/day T3, by estimation of 24-hour ¹³¹I uptake. 50% or more of suppression from the previous uptake was considered to be positive. Serum antithyroglobulin antibody, antimicrosomal antibody, and anti-DNA antibody titres were determined by haemagglutination of tanned sheep red cells coated with corresponding antigen (THA, MCHA, and DNA test kit, Fujizoki, Tokyo). Statistical analysis was carried out by Student's *t* test.

Results

According to the degree of lymphocytic infiltration and degenerative changes in follicular epithelium of biopsy specimens, the patients were divided into four groups. *A*: hyperplastic thyroid without cellular infiltration; *B*: hyperplastic epithelial changes with focal aggregates of lymphocytes < 30% area of specimen; *C*: hyperplastic epithelium with 30–60% of area containing lymphocytic infiltration and atrophic follicles replaced by fibrous tissues; *D*: almost diffuse thyroiditis with minimal or no epithelial hyperplasia. The typical histological picture of each group is illustrated in Figs. 1–4, and the number of patients in

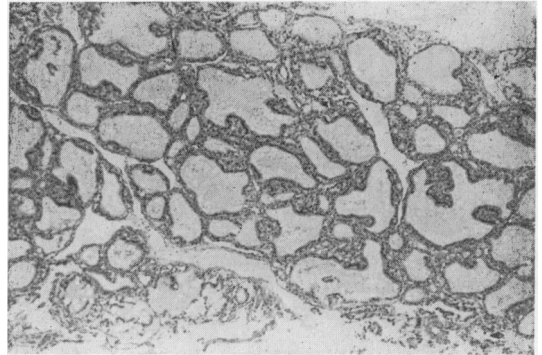


Fig. 1 *Group A. Tall columnar epithelial cells thrown into papillary folds and vacuolated colloid adjacent to the hyperplastic epithelia. No cell infiltration in this field. (H & E. × 20.)*

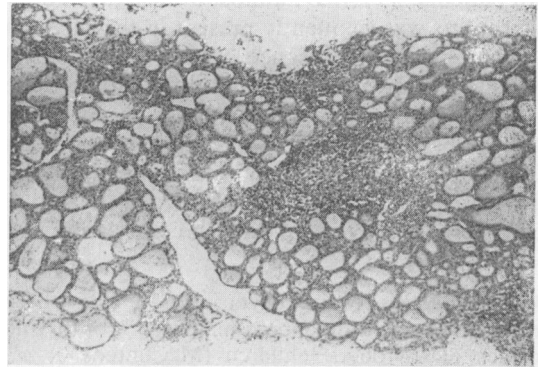


Fig. 2 *Group B. Scattered areas of interfollicular aggregates of lymphoid cells. Follicular epithelia are tall, forming microfollicles with scanty colloid. (H & E. × 20.)*

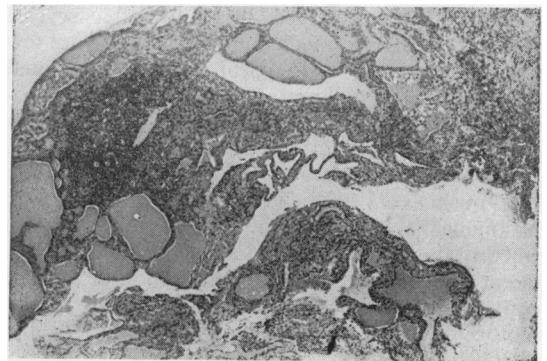


Fig. 3 *Group C. Over half the field is replaced by areas of cell infiltration and interstitial fibrosis. Remaining follicles are hyperplastic. (H & E. × 20.)*

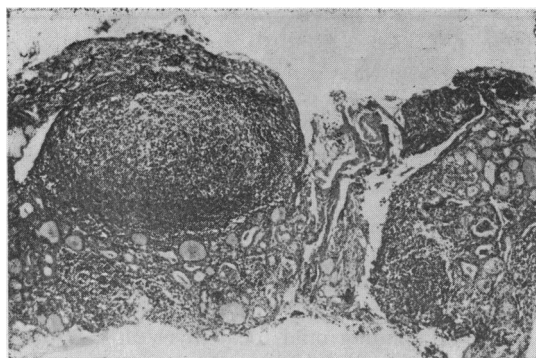


Fig. 4 Group D. Extensive destruction of follicles with massive cell infiltration forming lymphoid follicle. (The patient is now functionally euthyroid.) (H & E. $\times 25$.)

each group is listed in Table 2. Pure epithelial hyperplasia was noted only in 20% of the patients, and others were associated with varying degrees of thyroiditis. Although there was sharp contrast between the histological changes of groups A and D, groups B and C being intermediate, differences appeared quantitative rather than qualitative, with a progressive change from primary hyperplasia to diffuse thyroiditis.

Based on this histological classification, the clinical signs (Table 1), the laboratory data, and the clinical course of each group were evaluated. No striking difference in these parameters was noted

Table 2 Histological classification of the patients

| Group | Histological diagnosis | No. of patients (%) |
|-------|---|---------------------|
| A | Hyperplastic thyroid | 6 (20) |
| B | Hyperplastic thyroid with focal thyroiditis | 10 (33) |
| C | Chronic thyroiditis with hyperplastic epithelium | 10 (33) |
| D | Focal thyroiditis with varied epithelial changes, Almost diffuse thyroiditis | 1 } 3 } (13) |

Table 3 Laboratory data before treatment

| Group | No. of patients | T4-I ($\mu\text{g}/100\text{ml}$) (mean \pm SD) | T3 (ng/ml) (mean \pm SD) | ^{131}I uptake % (24 h) (mean \pm SD) | T3 suppression (no. positive) |
|--------------|-----------------|---|----------------------------------|--|----------------------------------|
| A | 6 | 11.0 \pm 1.7 | 5.80 \pm 1.6 | 54.8 \pm 15.4 | 0/3 (0%) |
| B | 10 | 11.1 \pm 2.8 | 5.55 \pm 2.0 | 71.6 \pm 21.6 | 1/6 (16.6%) |
| C | 10 | 11.4 \pm 2.5 | 4.79 \pm 1.74 | 65.2 \pm 15.0 | 1/8 (12.5%) |
| D | 2 | 8.6 \pm 0.6* | 2.65 \pm 0.15* | 1.6 (n=1)† | Not tested |
| | 2 | 10.3 \pm 0.2‡ | | 71.6 \pm 7.0 | |
| Normal range | | 3.5-6.6 | 1.0-2.0 | 10.0-40.0 | |

Group D vs A, B, or C: * P < 0.05, † P < 0.01. Values between other groups are not significant.
 ‡Protein-bound iodine (normal range 4.0-8.0 $\mu\text{g}/100\text{ ml}$)
 Conversion: Traditional units to SI—T4: 1 $\mu\text{g}/100\text{ ml}$ \approx 12.87 nmol/l. T3: 1 ng/ml \approx 1.536 nmol/l.

between the groups except D, in which clinical signs were milder and transient. Thus the serum T4-I and T3 levels (Table 3) were lower in group D than in the other groups, and 3 of 4 patients in group D showed spontaneous decrease in thyroid hormone levels without treatment. However, in the other groups, serum T4-I and T3 concentrations, ^{131}I uptake and T3 suppression test did not differ significantly, and the time required for normalization of serum T3 level with PTU treatment was also similar (Table 4). Although all of group C were histologically diagnosed as chronic thyroiditis with hyperplastic epithelium (Table 2), neither clinical signs nor laboratory tests could differentiate this group from the patients of groups A and B. Therefore, on a clinical basis, all the patients except those of group D could reasonably be diagnosed as juvenile thyrotoxicosis.

Most of the patients in group A were negative for THA, MCHA, and DNA, whereas these titres were apparently higher in the patients of groups B, C, and D (Fig. 5). Significant difference was observed between the mean MCHA titre of groups A and B and that of group C vs B (P < 0.05 and P < 0.01 respectively). It appeared that these serum antibody levels approximately paralleled the severity of associated thyroiditis. Furthermore, the clinical course of the patients differed considerably between the groups. Recovery of TSH responsiveness to TRH during therapy was more frequent in groups C and D. After reducing the PTU dose (150 mg/day), relapse occurred more often in group A than in the others. In contrast, the period of remission without PTU continued longer than one year in all of group D and in 2 of 5 patients in group C, but in none of groups A and B (Table 4). Overt hypothyroidism developed in one group D patient and she received L-T4 replacement.

Discussion

McClintock *et al.* (1956) reported slight to marked lymphoid cell infiltration in 10 of 45 (22%) hyper-

Table 4 Clinical course of the patients

| Group | Months required for normalization of T3 | Suppressed TSH after TRH* | Rate of remission† | Rate of relapse‡ |
|-------|---|---------------------------|--------------------|------------------|
| A | 3.3±2.2 | 2/4 (50%) | 0/4 (0%) | 4/4 (100%) |
| B | 4.1±3.7 | 6/9 (66%) | 0/9 (0%) | 3/9 (33%) |
| C | 3.6±3.1 | 2/7 (29%) | 2/5 (40%) | 1/5 (20%) |
| D | 1.3±0.4§ | 0/3 (0%) | 3/3 (100%) | 0/3 (0%) |

*TRH (thyrotrophin (TSH)—releasing hormone) test was done after year or more of PTU treatment.

†No. of patients in remission for 1 year or more after stopping treatment.

‡No. of patients relapsing after reducing PTU dose from 200–300 mg/day to 100–150 mg/day, or stopping treatment after 1 year's duration.

§3 of 4 patients in group D attained euthyroid state without treatment.

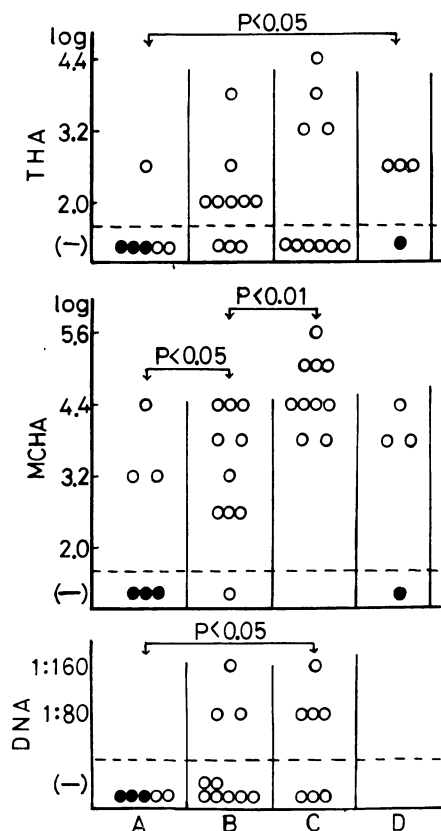


Fig. 5 Serum antithyroglobulin (THA), antimicrosomal (MCHA), and anti-DNA antibody titres in the patients in groups A–D. ● = patients in whom all of these antibodies were negative, or ○ = positive. With increasing degree of thyroiditis, these antibody titres tend to rise.

plastic thyroid glands in children. Saxena *et al.* (1964) also found moderate to marked lymphocytic infiltration in 15 of 52 patients (29%) with juvenile thyrotoxicosis. Our study showed a much higher prevalence of lymphocytic aggregation in the early stage of hyperplastic thyroid glands in children. 33% of the patients clinically diagnosed as Graves's disease

showed definite histological features of chronic thyroiditis, involving half the area of thyroid tissue obtained. Including mild focal thyroiditis, 80% of the patients examined showed a slight to severe degree of lymphocyte aggregation. Neither clinical signs nor routine laboratory tests could differentiate these patients except group D, but raised THA and/or MCHA titre or a positive test for DNA antibody in serum were found when thyroiditis was intense.

The patients of group D cannot be regarded as Graves's disease, but rather as chronic thyroiditis with transient hyperthyroidism. Nevertheless, the existence of this form of hyperthyroidism seems to be of importance from the aetiological and practical points of view. We have concluded that the association of autoimmune thyroiditis and thyrotoxicosis is a common occurrence in the early stage of juvenile thyrotoxicosis, and that the infiltrating lymphocytes may play an important role in causing stimulation or degeneration of thyroid epithelium.

Recent investigations indicate that these cells are involved in the production of long-acting thyroid stimulator (Miyai *et al.*, 1967; Wall *et al.*, 1973), LATS-protector (Shishiba *et al.*, 1973), human thyroid stimulator (Onaya *et al.*, 1973), and thyroid-stimulating immunoglobulin (Knox *et al.*, 1976), all of which could cause thyroid hyperplasia. In addition, there has been abundant evidence for the role of cell-mediated immunity against thyroid antigens in Graves's disease and orbital antigens in patients with exophthalmos (Volpé *et al.*, 1974). Cellular immune responses with cytotoxicity could gradually work to destroy thyroid epithelial cells and produce spontaneous or post-therapy hypothyroidism. DeGroot (1970) speculates that Graves's disease may be a condition representing a semistable balance between stimulating, blocking, and cell-lethal immune responses. Our observations are consistent with this balance theory for the development of Graves's disease and Hashimoto's thyroiditis.

From a practical point of view, the degree of co-existing thyroiditis appears to exert a decided influence on the clinical course of thyrotoxicosis. Whitesell and Black (1949) showed a positive correlation between (a) the extent of lymphocytic and fibro-

tic replacements in hyperplastic thyroid gland and (b) the incidence of postoperative myxoedema, and a definite increase in the incidence of exophthalmos with an increasing degree of these replacements. This is in accordance with our results. The incidence of remission was positively related to the degree of thyroiditis, whereas the relapse rate was inversely related.

In summary, the early histological changes of the thyroid gland in juvenile thyrotoxicosis suggest that a close aetiological relationship exists between Graves's disease and Hashimoto's thyroiditis.

We are grateful to Professor Fujitsugu Matsubara for histological examination of the biopsied specimens.

References

- Buchanan, W. W., Alexander, W. D., Crooks, J., Koutras, D. A., Wayne, E. J., Anderson, J. R., and Goudie, R. B. (1961). Association of thyrotoxicosis and autoimmune thyroiditis. *British Medical Journal*, **1**, 843-847.
- DeGroot, L. J. (1970). Current concepts in management of thyroid disease. *Medical Clinics of North America*, **54**, 117-130.
- Doniach, D., and Hudson, R. V. (1959). Thyrotoxicosis merging into Hashimoto's disease. *Proceedings of the Royal Society of Medicine*, **52**, 178-179.
- Doniach, D., Hudson, R. V., and Roitt, I. M. (1960). Human autoimmune thyroiditis; clinical studies. *British Medical Journal*, **1**, 365-373.
- Fatourech, V., McConahey, W. M., and Woolner, L. B. (1971). Hyperthyroidism associated with histologic Hashimoto's thyroiditis. *Mayo Clinic Proceedings*, **46**, 682-689.
- Gavras, I., and Thomson, J. A. (1972). Late thyrotoxicosis complicating autoimmune thyroiditis. *Acta Endocrinologica*, **69**, 41-46.
- Knox, A. J. S., von Westarp, C., Row, V. V., and Volpé, R. (1976). Thyroid antigen stimulates lymphocytes from patients with Graves' disease to produce thyroid-stimulating immunoglobulin (TSI). *Journal of Clinical Endocrinology and Metabolism*, **43**, 330-337.
- McClintock, J. C., Frawley, T. F., and Holden, J. H. P. (1956). Hyperthyroidism in children: observations in 50 treated cases, including an evaluation of endocrine factors. *Journal of Clinical Endocrinology and Metabolism*, **16**, 62-85.
- Miyai, K., Fukuchi, M., Kumahara, Y., and Abe, H. (1967). LATS production by lymphocyte culture in patients with Graves' disease. *Journal of Clinical Endocrinology and Metabolism*, **27**, 855-860.
- Nakajima, H., Sato, T., Inoue, M., Sano, M., Taketani, T., Takata, I., Suzuki, Y., Kawashima, H., Okuda, N., and Matsubara, F. (1975). Four cases of Hashitoxicosis in childhood. (In Japanese.) *Clinical Endrinology (Tokyo)*, **23**, 557-560.
- Onaya, T., Kotani, M., Yamada, T., and Ochi, Y. (1973). New *in vitro* tests to detect the thyroid stimulator in sera from hyperthyroid patients by measuring colloid droplet formation and cyclic AMP in human thyroid slices. *Journal of Clinical Endocrinology and Metabolism*, **36**, 859-866.
- Saxena, K. M., Crawford, J. D., and Talbot, N. B. (1964). Childhood thyrotoxicosis; a long-term perspective. *British Medical Journal*, **2**, 1153-1158.
- Shichijo, K. (1958). Clinical study of thyroid gland. (In Japanese.) *Journal of the Japanese Society of Internal Medicine*, **46**, 1229-1246.
- Shishiba, Y., Shimizu, T., Yoshimura, S., and Shizume, K. (1973). Direct evidence for human thyroidal stimulation by LATS-protector. *Journal of Clinical Endocrinology and Metabolism*, **36**, 517-521.
- Volpé, R., Edmons, M., Lamki, L., Clarke, P. V., and Row, V. V. (1972). The pathogenesis of Graves' disease; a disorder of delayed hypersensitivity? *Mayo Clinic Proceedings*, **47**, 824-834.
- Volpé, R., Farid, N. R., von Westarp, C., and Row, V. V. (1974). The pathogenesis of Graves' disease and Hashimoto's thyroiditis. *Clinical Endocrinology*, **3**, 239-261.
- Wall, J. R., Good, B. F., Forbes, I. J., and Hetzel, B. S. (1973). Demonstration of the production of the long acting thyroid stimulator (LATS) by peripheral lymphocytes cultured *in vitro*. *Clinical and Experimental Immunology*, **14**, 555-561.
- Whitesell, F. B., and Black, B. M. (1949). Statistical study of clinical significance of lymphocytic and fibrocytic replacements in hyperplastic thyroid gland. *Journal of Clinical Endocrinology and Metabolism*, **9**, 1202-1215.
- Woolner, L. B., McConahey, W. M., and Behars, O. H. (1959). Struma lymphomatosa (Hashimoto's thyroiditis) and related thyroidal disorders. *Journal of Clinical Endocrinology and Metabolism*, **19**, 53-83.

Correspondence to Dr. Tamotu Sato, Department of Paediatrics, School of Medicine, Kanazawa University, Takaramachi 13-1, Kanazawa 920, Japan.