

Rifamycin in neonatal flavobacteria meningitis

E. L. LEE, M. J. ROBINSON, M. L. THONG, AND S. D. PUTHUCHEARY

From the Departments of Paediatrics and Microbiology, University of Malaya, Kuala Lumpur, Malaysia

Lee, E. L., Robinson, M. J., Thong, M. L., and Puthuchear, S. D. (1976). *Archives of Disease in Childhood*, 51, 209. **Rifamycin in neonatal flavobacteria meningitis.** Three newborn infants with meningitis due to *Flavobacterium meningosepticum* were treated with rifamycin administered parenterally and directly into the cerebral ventricles. Antibiotic concentrations of blood and cerebrospinal fluid (CSF) were monitored during treatment. There was rapid sterilization of the CSF after this antibiotic. Jaundice was the only toxicity noted. All 3 infants developed hydrocephalus and are shunt dependent. Two of them are otherwise free of neurological complications and are developing normally. Rifamycin is a safe and effective antibiotic in this form of neonatal meningitis.

Bacterial meningitis acquired in the newborn period still carries a high mortality risk. The prognosis is especially grave if the causative organisms belong to certain Gram-negative species, namely *Klebsiella*, *Pseudomonas*, *Proteus*, and the 'water bugs' (McCracken, 1972; George, Cochrane, and Wheeler, 1961). This latter group of bacteria includes *Flavobacteria*, *Mimae*, *Xanthomonas*, *Achromobacter*, *Chromobacterium*, *Aerobacter*, *Serratia*, and *Erwinia*. They have simple growth requirements, abound in water, and infect newborn infants through contamination of the environment (Macpherson, 1958; Sever, 1959). Several epidemic outbreaks of meningitis in newborn nurseries caused by these organisms have been documented (Foley *et al.*, 1961; Plotkin and McKitrick, 1966; Rance *et al.*, 1962). Antimicrobial agents used in the treatment of this form of meningitis include erythromycin, chloramphenicol, vancomycin, and novobiocin (George *et al.*, 1961; Hawley and Gump, 1973; Sindhu, 1971). In the few infants who survive, the bacteriological response to these antibiotics has often been so delayed that host immune mechanisms probably play the major role in the eradication of these organisms (George *et al.*, 1961).

We report 3 neonates with meningitis, caused by *Flavobacterium meningosepticum* in whom the infection was rapidly controlled by the use of rifamycin. Rifamycin is derived from *Streptomyces mediterranei*. It is extensively used in the treatment of tuberculosis and other bacterial infections in adults.

However, there are few reports of its use in the treatment of Gram-negative infection in the newborn (Naveh and Friedman, 1973). We administered this antibiotic parenterally to our patients and directly into the cerebral ventricles through a Rickham ventriculostomy reservoir. Antibiotic levels in blood and cerebrospinal fluid (CSF) were measured. On the basis of our experience dosage recommendations are presented.

Materials and methods

The clinical profile and laboratory data of the 3 neonates are presented in Table I. The diagnosis was confirmed by culture of the organisms from the ventricular fluid in all 3 patients. Ampicillin and gentamicin were administered initially for 2-5 days, subsequently being replaced by rifamycin once sensitivity results were known. Case 1 additionally received parenteral erythromycin for one week. Rifamycin was given intramuscularly or intravenously over $\frac{1}{2}$ hour, at a dose of 20 mg/kg 12-hourly. Once the diagnosis of ventriculitis was confirmed, a Rickham reservoir was inserted and 2-5 mg rifamycin diluted in 2 ml normal saline was instilled into the ventricles each day. A pneumoencephalogram was performed routinely to check the site of the ventricular catheter, assess ventricular size, and ensure that the ventricles were freely communicating.

Susceptibility studies. The minimum inhibitory concentrations (MIC) of rifamycin for the isolated pathogens were determined by tube dilution method in nutrient broth (pH 7.3). The inoculum used was 10^3 organisms per tube. Readings were made after 18 hours of incubation at 37°C. Subcultures were made on blood agar for measurements of minimal bactericidal concentrations.

TABLE I

Clinical and laboratory findings of 3 newborn infants with flavobacteria meningitis

	Case 1	Case 2	Case 3
<i>Clinical picture</i>			
Age of onset	21 d	1 d	7 d
Sex	Female	Male	Male
Weight	2750 g	3200 g	1990 g
Head circumference	35 cm	36 cm	36 cm
Symptoms and signs	Hydrocephalus, opisthotonus, depressed respiration, generalized tremors, and convulsions	Fever, bulging fontanelle, convulsions	Fever, hydrocephalus, jitteriness
<i>CSF findings</i>			
WBC ($10^3/\text{mm}^3$)	400	433	625
Polymorphonuclear lymphocytes (%)	60	82	61
Lymphocytes (%)	40	18	39
Sugar (mg/100 ml)	60	20	10
Protein (mg/100 ml)	600	220	730
Smear for organisms	Gram-negative bacilli	Gram-negative bacilli,	Gram-negative bacilli,
Culture	<i>Fl. meningosepticum</i> type C	<i>Fl. meningosepticum</i> type C	<i>Fl. meningosepticum</i> type F
<i>Antibiogram</i>			
Sensitive to	Rifamycin, erythromycin	Rifamycin, novobiocin	Rifamycin, chloramphenicol, novobiocin
Resistant to	Ampicillin, gentamicin, chloramphenicol, kanamycin, cephaloridine	Ampicillin, gentamicin, erythromycin, chloramphenicol, kanamycin, cephaloridine	Ampicillin, gentamicin, kanamycin, cephaloridine, erythromycin
MIC of rifamycin	1.25 $\mu\text{g}/\text{ml}$	0.625 $\mu\text{g}/\text{ml}$	1.25 $\mu\text{g}/\text{ml}$
MBC of rifamycin	10 $\mu\text{g}/\text{ml}$	1.25 $\mu\text{g}/\text{ml}$	5.0 $\mu\text{g}/\text{ml}$
Frontal cerebral mantle at ventriculography	13 mm	24 mm	14 mm

Rifamycin assay. Plastic plates containing 100 ml of nutrient agar seeded with 10^7 assay organisms were freshly prepared on day of use. Wells of 7.5 mm diameter were made and filled with standard antibiotic solutions and test samples in a sequential fashion with 3-5 replications of each sample. After overnight incubation at room temperature (28°C), zone sizes were read with a caliper, to the nearest 0.1 mm. A standard curve was prepared for each plate on semilogarithmic paper and concentrations of test samples read off the linear scale (Bennett *et al.*, 1966).

A strain of *Staphylococcus pyogenes* was used to assay low concentrations while a strain of *Fl. meningosepticum* was used for high concentrations. Antibiotic standards were prepared in normal human serum for serum assay or in phosphate buffered saline for CSF assay.

Results

Serum rifamycin levels. Serum level-time curves for the 3 infants are shown in Fig. 1. Peak serum rifamycin concentrations were observed 1 to 2 hours after the intramuscular dose, with a mean value of 14.1 $\mu\text{g}/\text{ml}$. The zero time levels represented values 12 hours after the previous dose. The mean rifamycin activity at this stage was 0.65 $\mu\text{g}/\text{ml}$.

CSF rifamycin levels. The corresponding concentrations of rifamycin in the CSF in Cases 1

and 2 after an intramuscular injection are shown in Fig. 2. These values were recorded during meningeal inflammation as judged by CSF white cell count and protein content. All levels fell

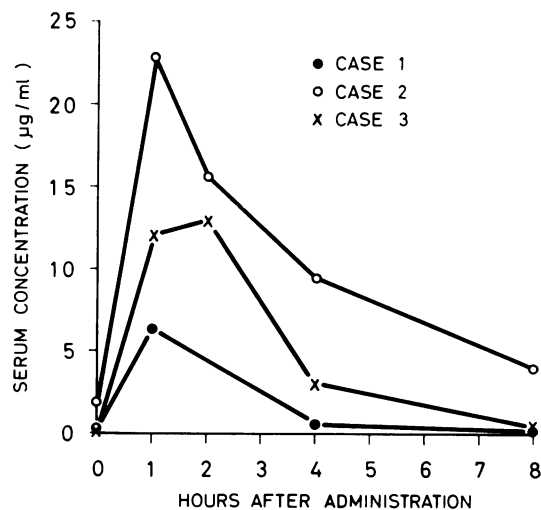


Fig. 1.—Levels of rifamycin in serum of 3 infants after intramuscular dose of 20 mg/kg.

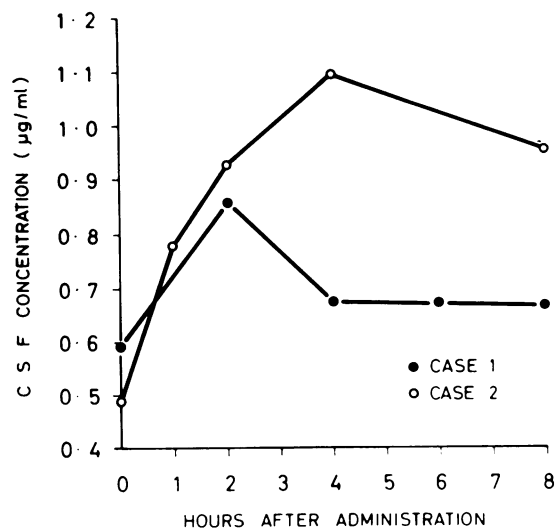


FIG. 2.—Concentration of rifamycin in CSF of Cases 1 and 2 after intramuscular dose of 20 mg/kg.

below the minimal bactericidal concentrations for the infecting organisms. Serial CSF levels monitored 24 hours after daily intraventricular administration of 2 or 5 mg rifamycin ranged from 3 to 94 µg/ml (Fig. 3). At the time of study the ventricular size was assessed by measurement of the head circumference and thickness of the frontal cerebral mantle. These dimensions are included in Table I. Though an identical dose of rifamycin (2 mg) was administered intrareservoir in 2 infants with greatly differing ventricular volume, daily CSF antibiotic concentrations were only marginally higher in the baby (Case 2) without significant ventricular dilatation. There was no evidence of drug accumulation within the CSF with the doses used.

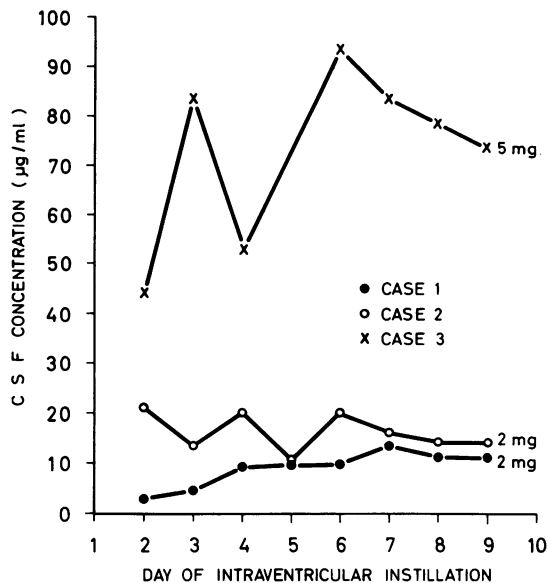


FIG. 3.—Concentration of rifamycin in CSF 24 hours after intraventricular dose. Number after curve represents the daily dose administered.

Bacteriological response. The response of the 3 patients to antimicrobial therapy is summarized in Table II. Bacteriological sterilization of the CSF was rapid. Case 2 had prolonged intraventricular rifamycin therapy because of persistent pleocytosis in the CSF despite repeated negative cultures. When the Rickham reservoir was removed at 3 months of age there was bacterial colonization at the catheter tip. The MIC of rifamycin remained at 0.625 µg/ml at this stage.

Rifamycin toxicity. Jaundice was observed in 2 babies soon after starting treatment with rifamycin.

TABLE II

Response to treatment and sequelae of the 3 infants after rifamycin therapy

Case	Antibiotics administered	Duration of systemic antibiotics (w)	Duration of intraventricular antibiotics	Period taken for sterilization of CSF	Sequelae
1	Rifamycin	6	10 d	2 d	Hydrocephalus—shunted
	Erythromycin	1	nil	—	Mild spasticity, developmental delay
2	Rifamycin	14	10 w	5 d	Hydrocephalus—shunted, normal at 9 months
3	Rifamycin	4	10 d	2 d	Hydrocephalus—shunted, normal at 6 months

cin. Bilirubin was mainly conjugated with a maximal recorded level of 10.3 mg/100 ml (total). It persisted for 4–8 weeks and regressed spontaneously despite continuation of the drug. Full blood counts, blood urea, electrolytes, serum transaminases, and alkaline phosphatase levels were determined weekly. All levels were normal and they did not alter significantly during therapy.

Response to therapy. All 3 infants developed hydrocephalus requiring shunts. Cases 2 and 3 are developing normally and only Case 1 was left with a significant neurological defect when last followed up at 9 months of age. Her developmental age was assessed as 6 months, and increased tone and reflexes were noted in all 4 limbs.

Discussion

Most paediatricians have experienced enormous difficulty in sterilizing the CSF of neonates with meningitis caused by 'water bugs' (George *et al.*, 1961; Foley *et al.*, 1961; Sindhu, 1971). Factors contributing to the high fatality in this illness include delay in diagnosis, and delay in the accurate identification of the organism. Furthermore, these organisms have an unusual pattern of antibiotic sensitivity, being generally resistant to the conventional chemotherapeutic agents used in the treatment of neonatal meningitis, i.e. ampicillin, gentamicin, kanamycin, and chloramphenicol (Altmann and Bogokovsky, 1971). Thus, by the time treatment with appropriate antibiotics is started, severe neurological damage has usually occurred. Even after the administration of suitable antibiotics the response is often unsatisfactory largely because of poor penetration into the CSF, together with the rapid development of resistance (George *et al.*, 1961).

Studies in this hospital have shown that all 21 isolates of *Flavobacteria* cultured from neonates are sensitive to rifamycin—the MIC ranging from 0.625–3.1 µg/ml. Of the 20 antimicrobial agents tested *in vitro* against this organism by Altmann and Bogokovsky (1971), rifampicin was judged to be the most efficient. There are very few accounts of the use of this antibiotic in the treatment of neonatal bacterial infections, and we have not encountered any report of its use in meningitis. This prompted us to monitor blood and CSF levels of rifamycin in our patients. The wide variation in serum antibiotic levels in these infants is probably related to uncertain rates of absorption and excretion of drugs in the neonatal period. We found that, even in the presence of high serum levels and meningeal inflammation, rifamycin does not cross

the blood-brain barrier in sufficient concentration for the effective treatment of neonatal meningitis. D'Oliveira (1972) similarly recorded CSF rifampin* levels between 0.041–1.37 µg/ml with the use of the drug in meningeal tuberculosis. Only in Case 2 in our series did the CSF antibiotic levels exceed the MIC for the organism when rifamycin was given intramuscularly. Lorber, Kalhan, and Mahgreffe (1970), however, advised that since the most important factor in the prognosis of neonatal meningitis is the level of the antibiotic in the CSF, this level must exceed the MIC for the pathogen by 50-fold to be effective. This concentration can be adequately reached without causing systemic toxicity by direct intraventricular instillation of the drug. In our patients the high CSF rifamycin levels obtained by this method resulted in prompt sterilization of their ventricles. There was no evidence of cerebral irritability or convulsions during the course of intraventricular therapy.

If during the course of treatment CSF leucocytosis persists despite adequate antibiotic concentration, and if repeated attempts to culture the organism fail, colonization within the reservoir should be suspected. This occurred in Case 2. The delay in removal of the ventriculostomy catheter after its colonization by the bacteria probably led to progressive hydrocephalus in this infant.

In our experience, rifamycin is a safe and effective antibiotic in the treatment of certain varieties of Gram-negative meningitis. The occurrence of jaundice alone during drug therapy is not a contraindication for its continued use. Because of the risk of potential hepatic toxicity, however, liver function tests should be monitored during treatment (Radner, 1973). The cases selected for treatment should of course be determined by results of culture and sensitivity testing. Rifamycin discs are now used routinely in the University Hospital when testing organisms isolated from spinal fluid of neonates. We recommend treatment at first with rifamycin parenterally in a dosage of 40 mg/kg per day in two equal doses. In addition, daily intrathecal or preferably intraventricular instillation of the drug in a dosage of 2–5 mg/day is an essential complement to systemic therapy. Further study is required before we can confidently recommend the duration of intraventricular and parenteral therapy—we have probably erred on the side of caution in this respect.

We are grateful to Dr. R. E. Weaver, Center for Disease Control, Atlanta, Georgia, U.S.A., for confirming the identity and serotyping the isolated organisms.

* Semisynthetic oral analogue of rifampicin.

REFERENCES

- Altmann, G., and Bogokovsky, B. (1971). In-vitro sensitivity of *Flavobacterium meningosepticum* to antimicrobial agents. *Journal of Medical Microbiology*, **4**, 296.
- Bennett, J. V., Brodie, J. L., Benner, E. J., and Kirby, W. M. M. (1966). Simplified accurate method for antibiotic assay of clinical specimens. *Applied Microbiology*, **14**, 170.
- D'Oliveira, J. J. G. (1972). Cerebrospinal fluid concentrations of rifampin in meningeal tuberculosis. *American Review of Respiratory Disease*, **106**, 432.
- Foley, J. F., Gravelle, C. R., Englehard, W. E., and Chin, T. D. Y. (1961). *Achromobacter* septicemia; fatalities in prematures. *American Journal of Diseases of Children*, **101**, 279.
- George, R. M., Cochran, C. P., and Wheeler, W. E. (1961). Epidemic meningitis of the newborn caused by *Flavobacteria*. II. Clinical manifestations and treatment. *American Journal of Diseases of Children*, **101**, 296.
- Hawley, H. B., and Gump, D. W. (1973). Vancomycin therapy of bacterial meningitis. *American Journal of Diseases of Children*, **126**, 261.
- Lorber, J., Kalhan, S. C., and Mahgreffe, B. (1970). Treatment of ventriculitis with gentamicin and cloxacillin in infants born with spina bifida. *Archives of Disease in Childhood*, **45**, 178.
- Macpherson, C. R. (1958). Oxygen therapy—an unsuspected source of hospital infections? *Journal of the American Medical Association*, **167**, 1083.
- McCracken, G. H. (1972). The rate of bacteriologic response to antimicrobial therapy in neonatal meningitis. *American Journal of Diseases of Children*, **123**, 547.
- Naveh, Y., and Friedman, A. (1973). Rifampicin therapy in Gram-negative bacteraemia in infancy. *Archives of Disease in Childhood*, **48**, 967.
- Plotkin, S. A., and McKittrick, J. C. (1966). Nosocomial meningitis of the newborn caused by a *Flavobacterium*. *Journal of the American Medical Association*, **198**, 662.
- Radner, D. B. (1973). Toxicologic and pharmacologic aspects of rifampin. *Chest*, **64**, 213.
- Rance, C. P., Roy, T. E., Donohue, W. L., Sepp, A., Elder, R., and Finlayson, M. (1962). An epidemic of septicemia with meningitis and hemorrhagic encephalitis in premature infants. *Journal of Pediatrics*, **61**, 24.
- Sever, J. L. (1959). Possible role of humidifying equipment in spread of infections from the newborn nursery. *Pediatrics*, **24**, 50.
- Sindhu, S. S. (1971). *Achromobacter* meningitis in the newborn. *Journal of the Singapore Paediatric Society*, **13**, 31.

Correspondence to Dr. E. L. Lee, Department of Paediatrics, University of Malaya, Kuala Lumpur, West Malaysia.

The following articles will appear in future issues of this journal:

- Cord γ glutamyl transpeptidase activity and neonatal jaundice. *D. C. Davidson, W. B. McIntosh, and J. A. Ford.*
- Evidence of duration and type of illness in children found unexpectedly dead. *C. Sinclair-Smith, F. Dinsdale, and J. Emery.*
- Rapid assessment of gestational age at birth. *J. M. Parkin, E. N. Hey, and J. S. Clowes.*
- Respiratory complications in long-term survivors of oesophageal atresia. *N. E. Dudley and P. D. Phelan.*
- Serum creatine phosphokinase in normal newborns. *N. Gilboa and J. R. Swanson.*
- Annotation:* Screening for Duchenne muscular dystrophy. *V. Dubowitz.*
- Thyrotoxicosis in a neonate of a mother with no history of thyroid disease. *D. S. K. Brookfield, A. E. McCandless, and C. S. Smith*
- Neonatal brain growth during prolonged intravenous feeding. *R. S. Trompeter, J. Dobbins, A. Aynsley-Green, and J. D. Baum.*