

Menkes's steely hair syndrome

E. MAY WHEELER and P. F. ROBERTS

From the Departments of Paediatrics and Histopathology, United Norwich Hospitals, Norwich

Wheeler, E. M., and Roberts, P. F. (1976). *Archives of Disease in Childhood*, **51**, 269. **Menkes's steely hair syndrome.** Three unrelated cases of Menkes's syndrome are described. In addition to the typical features these cases all showed abnormalities of the urinary tract characterized by hydronephrosis, hydroureter, and bladder diverticula. There was no organic obstruction in the urinary tract and the changes are presumed to be due to disturbed innervation. The 3 patients showed no overall clinical response to parenteral copper therapy administered for periods of 1 to 8 months. Necropsy studies showed structural changes in veins as well as arteries together with aneurysm formation in both, and one case showed a polypoid lesion in the stomach.

Since the first description of the steely-hair syndrome (Menkes *et al.*, 1962), consisting of male infants with characteristic facies, hair resembling steel-wool in texture, hypothermia, convulsions, severe mental retardation, and low serum copper and caeruloplasmin levels, many new cases have been described. The discovery of the disturbance in copper metabolism (Danks *et al.*, 1972a, b) was an important step in the understanding of the evolution of the disease and led to the treatment by parenteral copper therapy (Danks *et al.*, 1972b, 1973; Walker-Smith *et al.*, 1973; Bucknall, Haslam, and Holtzman, 1973; Dekaban and Steusing, 1974). Unfortunately, in these cases the infants had severe neurological damage before copper therapy was begun and no improvement was obtained. Recently an infant has been treated from the age of 28 days and has so far shown a favourable response (Grover and Scrutton, 1975).

Three unrelated cases of Menkes's syndrome seen at one hospital in Norfolk showing several new clinical and pathological features are reported, and their response to parenteral copper therapy is described.

Case reports

Case 1. The first child of unrelated parents. Birthweight was 2.42 kg at 39 weeks' gestation. During the first 2 weeks of life he had a persistently low temperature of 36 °C. At 11 days of age he was found to have a urinary tract infection. In spite of treatment

with ampicillin he gained weight very slowly and was restless. At 9 weeks he was a thin, wriggling baby who did not smile or pay attention to his mother. His weight, length, and head circumference were well below the 10th centile. Scalp hair was scanty and crinkled, resembling his mother's hair. His facies were characteristic of Menkes's syndrome and he had a persistent erythematous rash on the head, neck, and trunk. Hb 11.9 g/dl; white blood count, electrolytes, liver, and thyroid function tests were normal; blood urea 41–74 mg/100 ml; creatinine clearance 25 ml/min per 1.73 m² (normal for age). An intravenous urogram showed that the left kidney was grossly hydronephrotic but with good function. There was obstruction at the pelviureteric junction. The right kidney was normal. A micturating cystogram showed bilateral ureteric reflux and a trabeculated bladder.

Over the next few months the child remained in a state of constant activity with athetoid movements of limbs but there were no major convulsions. Physically and mentally he made no progress and at 4 months developed intractable diarrhoea. At 5 months the serum copper level was found to be <5 µg/100 ml; no caeruloplasmin was detected. Treatment with copper-EDTA by intramuscular injection had no beneficial effect on the neurological state though serum copper and caeruloplasmin rose to normal levels. He died at 6 months weighing 2.92 kg.

Case 2. A boy was born at 38 weeks' gestation by caesarean section for fetal distress; weight 3.3 kg. He was the only child of unrelated healthy parents. In the neonatal period he had a wrinkled, flabby skin, abnormal facies, and bilateral talipes. He smiled at 6 weeks but at 8 weeks had prolonged twitching of face and arms. Examination at this stage showed scanty, steely hair on the scalp and curly eyelashes. Microscopical examina-

tion of the scalp hair showed pili torti. The hands had a single palmar crease and the skin was overgrowing the nail folds. There was an umbilical hernia, bilateral undescended testes, and a marked, persistent napkin rash. Neurological examination showed hypotonia, poor head control, and frequent fits. The child had several episodes of hypothermia. Hb 10 g/dl; white blood count, platelets, electrolytes, and serum calcium were normal; blood urea 74 mg/100 ml, serum iron 42 μ g/100 ml, serum folate 2.3 ng/ml, serum copper 4 μ g/100 ml. No caeruloplasmin was detected. Urine was sterile. Urinary amino acid chromatography was normal. Skull x-rays showed a few wormian bones. The long bones were normal at 2 months of age but later became osteoporotic.

Treatment with anticonvulsants failed to control the fits. At 11 weeks of age he was given intramuscular copper-EDTA 1 mg daily for a week. Serum copper then rose to 47 μ g/100 ml and caeruloplasmin to 43 mg/100 ml. Further courses of EDTA were necessary to maintain the serum copper levels at the lower end of the normal range (Table). In spite of this treatment there was minimal improvement in the control of fits, feeding ability, and temperature regulation. Neurological examination showed no improvement. Tendon reflexes disappeared and marked muscle wasting developed. At 7 months of age he had a large palpable bladder, dribbled urine, and had a urinary tract infection. An intravenous urogram and expression cystogram showed normal kidneys and ureters, but there was massive bladder enlargement with two diverticula. Over the next few months 2 large cysts grew from his gums causing feeding difficulties (Fig 1). Soft cystic swellings appeared in the neck. He died aged 11 months from bronchopneumonia.

Necropsy. External examination showed a male infant with blonde steely hair and blue eyes. There was narrowing of the skull with occipitofrontal elongation. There was a small umbilical hernia and the testes were undescended. In the cranial cavity the dura and leptomeninges were markedly thickened by fibrous tissue with extensive deposits of underlying gelatinous mucoid material. The brain weighed 520 g and showed

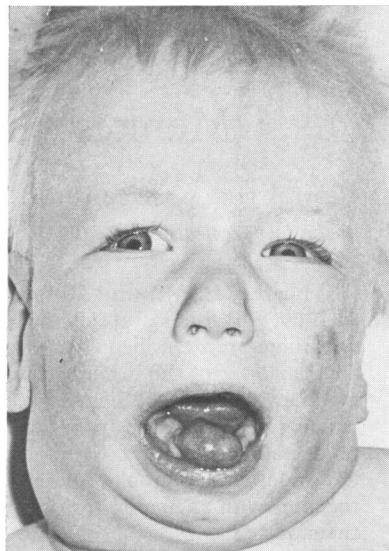


FIG. 1.—Case 2. Lobulated epulis of lower jaw. Hair now blond and straight after 5 months of copper therapy.

atrophy of the white matter and dilatation of the ventricular system. There was also atrophy of the cerebellum (Fig. 2). In the mouth there was a pedunculated epulis on the left upper jaw and generalized gingival hyperplasia. In the neck there was a 1 cm aneurysm of the left external jugular vein just below the carotid bifurcation. There was a smaller aneurysm on the right external jugular vein. The right external carotid artery showed aneurysmal dilatation above the bifurcation measuring 1.5 cm in diameter.

The lungs showed bilateral bronchopneumonic consolidation. There was an emphysematous bulla at the apex of the left upper lobe and partial fissuring of both lower lobes. The thymus was reduced in size. The heart was normal. There was some thickening of the thoracic abdominal aorta. The stomach was dilated and the pyloric canal was occluded by polypoid,

TABLE

Case 2. Response to copper therapy.

Age	Serum copper (μ g/100 ml) (normal range 60–12)	Serum caeruloplasmin (mg/100 ml) (normal range 20–44)	Treatment (copper-EDTA)
8 w	4	nil	—
11 w	—	—	1 mg \times 7
13 w	47	4.3	—
15 w	63	11.7	1 mg \times 7
17 w	37	5.1	1 mg \times 7
5 m	35	—	1 mg \times 10
6 m	73	10.2	2 mg weekly
7 m	65	10.2	1 mg \times 7
7½ m	107	13.5	2 mg weekly
9 m	60	13.7	—

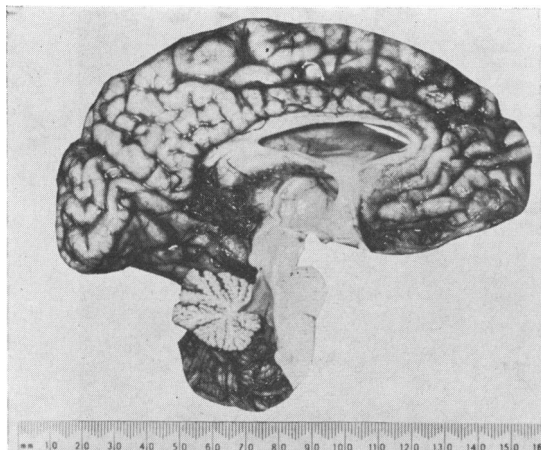


FIG. 2.—Case 2. Sagittal section through brain.

mucosal tumour 1 cm in diameter, which had partly prolapsed into the first part of the duodenum. The remainder of the intestines was normal. The liver, spleen, and pancreas were normal. Both kidneys weighed 25 g and showed no evidence of scarring. The ureters were normal. The bladder was markedly distended and completely filled the abdominal cavity. There were several large diverticula in the bladder wall with areas of petechial haemorrhage in the mucosa. The ureteric orifices appeared normal. The urethra was removed intact and opened with scissors and no obstruction was found. Apart from a generalized increase in subcutaneous fat and associated muscle wasting, no other abnormality was found.

Microscopical examination. The changes in the brain were typical of Menkes's disease and have been described before. The bladder diverticula were covered by a thin attenuated layer of smooth muscle, with areas of mucosal ulceration. The antral polyp consisted of hyperplastic pyloric mucosa lying on a thickened muscularis mucosae continuous with the normal adjacent muscularis. The appearances were consistent with repeated prolapse of redundant antral mucosa to produce a polypoid lesion. The duodenal mucosa appeared normal. Sections of the carotid artery aneurysm showed subintimal oedema and marked widening of the media with extensive loss of elastin (Fig 3). The remaining elastic fibres showed curling and fragmentation. The jugular vein aneurysm similarly showed subintimal oedema and loss of the elastin in the media (Fig 4). There was no inflammatory cell infiltration.

Case 3. A male was born at term weighing 2.66 kg. Initially he was hypotonic and required tube feeding for 3 weeks. At that time his unusual facies, low set ears, and soft occipital bones were noted. At 7 weeks convulsions began which were not controlled by phenobarbitone. He had scanty, steely hair, and eyelashes,

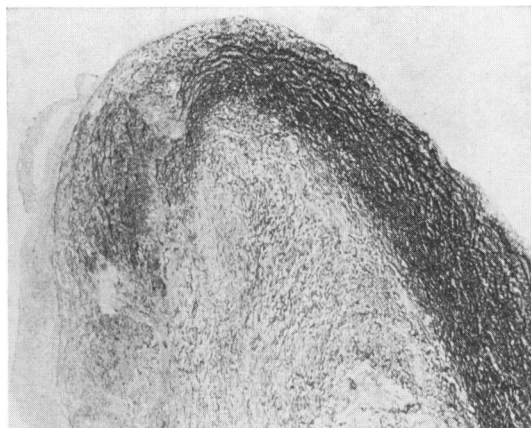


FIG. 3.—Case 2. Normal vessel wall on right and aneurysmal wall on left showing loss of elastin in the media and subintimal oedema. (Elastin stain $\times 25$.)

with pili torti, dolichocephaly, deeply wrinkled forehead, and loose folds of skin on the dorsum of the hands with the nail folds overgrowing the nails. Episodes of hypothermia occurred, with a temperature of 33.9 °C on one occasion. Diagnosis of Menkes's syndrome was confirmed by the following investigations: plasma copper 3.8 $\mu\text{g}/100$ ml, red cell copper 73 $\mu\text{g}/100$ ml. Plasma caeruloplasmin not detectable; plasma zinc 58 $\mu\text{g}/100$ ml. Skull x-rays showed multiple wormian bones in the occipital region. A skeletal survey at the age of 3 months showed metaphyseal spurs at the lower ends of the femora. Other investigations: Hb 9.1 g/dl; normal film and WBC; blood urea 45 mg/100 ml, blood sugar 73 mg/100 ml; serum calcium normal; serum folate 3.6 mg/100 ml, serum iron 15 $\mu\text{g}/100$ ml. Initial bacteriological examination of urine was normal, and amino acid chromatogram was also normal. At 4 months recurrent urinary tract infections began and an intravenous urogram showed that both kidneys were slightly enlarged. The bladder was markedly sacculated. A cystogram showed a large bladder diverticulum lying posteriorly with no ureteric reflex.

At 4 months of age he was treated with intramuscular copper-EDTA, which seemed to reduce the number of fits and his appetite improved. Episodes of hypothermia still occurred. He remained on anticonvulsant therapy. Normal plasma levels of copper, zinc, and caeruloplasmin were maintained by weekly copper injections but there was no further neurological development. At 9 months he was extremely hypotonic, had no head control, and did not smile or pay attention to his mother. He died aged 10 months after an episode of profound hypothermia (29 °C) unresponsive to slow re-warming.

Necropsy. External examination showed the features of Menkes's disease. In the cranial cavity the meninges were thickened and there was associated cerebral atrophy

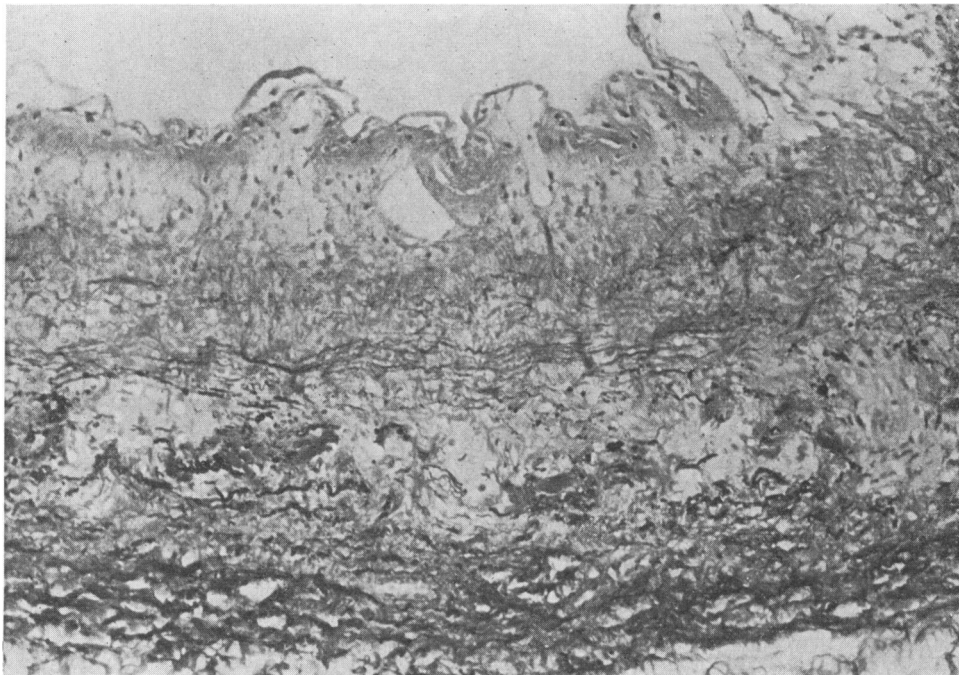


FIG. 4.—Case 2. Wall of jugular vein aneurysm. (Elastin stain $\times 90$.)

(brain weight 380 g) with diffuse micropolygyria. The lungs were acutely haemorrhagic and there were pleural effusions. The thymus was normal. The heart showed dilatation of the left ventricle but the coronary vessels were normal. There was thickening of the aorta and its branches but the endothelial surface appeared to be intact. The stomach was normal. The small bowel was dilated and in the colon there were punctate haemorrhagic lesions in the mucosa. Fresh blood was present in the rectum. Liver, gallbladder, and spleen were normal. The kidneys were normal and the ureters were not dilated. The bladder was markedly dilated and filled with urine and there was marked trabeculation of the wall with several small diverticula. The other organs were normal.

Microscopical examination. The brain showed the changes previously described in Menkes's disease. In the colon there were foci of superficial mucosal necrosis with focal haemorrhage associated with sludging of blood in the mesenteric vein tributaries. The appearances were probably due to hypothermia. The aorta showed subintimal fibrosis and widening of the media due to deposition of basophilic ground substance between elastic fibres (Fig. 5).

Discussion

There have been a number of published reports of patients with Menkes's syndrome from the USA

and Australia but none from Britain. The 3 cases reported here were seen at one hospital in the course of one year. The families were not inter-related and the parents lived in different parts of Norfolk.

Urological abnormalities have not been reported before. Urinary and blood urea are usually normal. Post-mortem reports in 12 previous cases (Menkes *et al.*, 1962; Aguilar *et al.*, 1966; Walker-Smith *et al.*, 1973; Danks *et al.*, 1972a) recorded no renal changes except for one child with terminal pyelonephritis. In our Case 1 there was ureteric reflux and hydronephrosis, in addition to a trabeculated bladder. In the other 2 cases the trabeculaed bladder contained diverticula suggesting bladder neck or urethral obstruction. No organic obstruction was found at post-mortem examination and a neurogenic bladder appears to be the likely cause, in view of the severe neurological defects.

All these infants received treatment with intramuscular copper-EDTA and the extremely low levels of serum copper and caeruloplasmin rose to normal or near normal levels. Doses of 170 $\mu\text{g}/\text{kg}$ daily for 7 days obtained a rapid biochemical response within 2 weeks. Further courses were necessary, and 250 $\mu\text{g}/\text{kg}$ given weekly proved to be safe and satisfactory in maintaining the serum copper levels. The use of an intramuscular preparation,




FIG. 5.—Case 3. Intima and part of media of abdominal aorta. (H. and E. $\times 60$.)

which could be given by a nurse at home, greatly reduced the length of hospital admissions. Grover and Scrutton (1975) when treating a 4-week-old baby with intravenous copper sulphate found lower doses, such as 10 $\mu\text{g}/\text{kg}$ per day, ineffective and increased the dosage to 550–850 $\mu\text{g}/\text{kg}$ weekly in divided doses. Dekaban and Steusing (1974) used intravenous copper sulphate infusions 200–300 $\mu\text{g}/\text{kg}$ twice weekly to raise serum copper level and then used subcutaneous copper sulphate in saline infusions for maintenance. When the defect in copper absorption by the intestinal mucosa was shown by Danks *et al.* (1972b) it was hoped that parenteral copper would benefit these children. Results have been very disappointing as assessed by failure of neurological development and post-mortem findings of gross cerebral degeneration, even in the baby treated from the age of 11 weeks until death at 11 months (Case 2).

The necropsy findings show several features of interest. Changes in the brain have been well described in previous reports though micropolygyria has not been associated with this syndrome. The marked trabeculation of the bladder and dilatation with diverticula has not been reported before in association with Menkes's syndrome. Since no organic obstruction could be found in the lower urinary tract, it is probable that there is disturbed innervation of the bladder neck. The arterial changes in the second patient were severe with the development of aneurysm formation. In contrast to previous reports (Danks *et al.*, 1972a, b) there were

extensive changes in the elastic tissue of the media. In addition, the abnormal histological changes in the veins leading to varix formation has been described for the first time. The duodenal and jejunal mucosa in Case 2 showed no abnormality of the villous architecture. Special stains for copper failed to show evidence of excess copper deposition in the absorptive cells of the duodenum or jejunum. This finding is at variance with the presence of raised levels of copper in the duodenal mucosa of other cases using atomic absorption spectrophotometry (Danks *et al.*, 1973). In view of the discovery of high copper levels in the kidney, spleen, and pancreas of a fetus with Menkes's syndrome (Horn *et al.*, 1975) these tissues were examined from Cases 2 and 3. Using the rubeanic acid method, no excess could be shown. It is possible that the histological technique is insufficiently sensitive.

The underlying defect in Menkes's syndrome awaits clarification. In addition to the transport defect in the intestinal mucosa, Danks *et al.* (1972b) postulated a defect in placental transfer of copper to the fetus resulting in low levels at birth. This agrees with our observation of these 3 babies who had abnormal facies or hypothermia in the first week of life. However, Horn *et al.*, (1975) in Denmark have shown high levels of copper in the placenta, kidney, spleen, and pancreas of a male fetus with Menkes's syndrome, while the hepatic concentration was low. There does not appear to be a defect in the ability of the liver to store copper

given parenterally (Grover and Scrutton, 1975) and caeruloplasmin is rapidly formed after the administration of parenteral copper. It thus appears that *in utero* certain tissues have an abnormal affinity for maternal copper, causing a deficiency in the fetal and neonatal liver, skin, and brain. After birth the failure of copper transport through the intestinal mucosal cells, leading to an accumulation of copper in those cells and the conservation of normal copper levels in the erythrocytes, even when serum levels are very low, support this hypothesis. More detailed investigations are required of the biochemistry of absorption and transport of copper and the serum concentrations of caeruloplasmin, caeruloplasmin-copper, total copper, and noncaeruloplasmin-copper (Scheinberg and Sternlieb, 1975).

We thank Dr. Delves of the Institute of Child Health, London for measurement of the copper levels and Drs. Quinton, R. D. Jones, and E. H. Back, who were responsible for the care of these patients.

REFERENCES

- Aguilar, M. J., Chadwick, D. L., Okuyama, K., and Kamoshita, S. (1966). Kinky-hair disease. *Journal of Neuropathology and Experimental Neurology*, **25**, 507.
- Bucknall, W. E., Haslam, R. H. A., and Holtzman, B. A. (1973). Kinky-hair syndrome: response to copper therapy. *Pediatrics*, **52**, 653.
- Danks, D. M., Campbell, P. E., Stevens, B. J., Mayne, V., and Cartwright, E. (1972a). Menkes's kinky-hair syndrome. *Pediatrics*, **50**, 188.
- Danks, D. M., Stevens, B. J., Campbell, P. E., Gillespie, J. M., Walker-Smith, J., Blomfield, J., and Turner, B. (1972b). Menkes' kinky-hair syndrome. *Lancet*, **1**, 1100.
- Danks, D. M., Cartwright, E., Stevens, B. J., and Townley, R. R. W. (1973). Menkes' kinky-hair disease—further definition of the defect in copper transport. *Science*, **179**, 1140.
- Dekaban, A. S., and Steusing, J. K. (1974). Menkes' kinky-hair disease treated with subcutaneous copper sulphate. *Lancet*, **2**, 1523.
- Grover, W. D., and Scrutton, M. C. (1975). Copper infusion therapy in trichopoliodystrophy. *Journal of Pediatrics*, **86**, 216.
- Horn, N., Mikkelsen, M., Heydorn, K., Damsgaard, E., and Tygstrup, I. (1975). Copper and steely hair. *Lancet*, **1**, 1236.
- Menkes, J. H., Alter, M., Steigleder, G. K., Weakley, D. R., and Sung, J. H. (1962). A sex-linked recessive disorder with retardation of growth, peculiar hair, and focal cerebral and cerebellar degeneration. *Pediatrics*, **29**, 764.
- Scheinberg, I. H., and Sternlieb, I. (1975). Steely-hair syndrome and copper. *New England Journal of Medicine*, **292**, 1192.
- Walker-Smith, J. A., Turner, B., Bloomfield, J., and Wise, G. (1973). Therapeutic implications of copper deficiency in Menkes' steely-hair syndrome. *Archives of Disease in Childhood*, **48**, 958.

Correspondence to Dr. P. F. Roberts, Norfolk and Norwich Hospital, Norwich NR1 3SR.

Addendum

We are now treating another baby with Menkes's syndrome, the sib of the first patient, who was diagnosed in the neonatal period.