

Dermatomyositis in childhood

Review of eight cases

K. M. GOEL and R. A. SHANKS

From Royal Hospital for Sick Children, Glasgow

Goel, K. M., and Shanks, R. A. (1976). *Archives of Disease in Childhood*, **51**, 501. **Dermatomyositis in childhood: review of eight cases.** Eight cases of dermatomyositis in children admitted to Scottish hospitals between 1962 and 1972 have been reviewed. 6 of the 8 were currently in complete remission. In the other 2 cases the disease remained active in 1 and 1 had died of cardiac failure 6 years after the onset of disease. 5 had developed extensive soft tissue calcification for which 2 were treated with ethanehydroxydiphosphonate, one showing definite improvement and the other no change. All had been treated with corticosteroids and two in addition had had cytotoxic agents (methotrexate or cyclophosphamide). The overall prognosis had probably been improved by the use of corticosteroids but not by the cytotoxic drugs. Only one of the patients was incapacitated by residual contractures or calcinosis.

Dermatomyositis is a rare connective tissue disorder affecting both children and adults, and is now thought to be primarily a diffuse angiopathy that affects not only the muscles and skin but also the gastrointestinal tract, adipose tissue, and nervous system (Banker and Victor, 1966). Some clinicopathological features tend to distinguish the childhood from the adult form—early muscle weakness, extensive and early calcinosis, and vasculitis (Dubowitz, 1969). The age at onset of dermatomyositis in childhood varies from infancy to adolescence. For the most part the disease is characterized by an insidious onset but it may be acute and fulminating (Hanson and Kornreich, 1967).

The most common presenting symptoms are muscular weakness, stiffness, easy fatigability, and a skin rash. There may be a violaceous colour of the eyelids and some dilatation of the capillaries over the malar bones, eyelids, knuckles, various pressure points, and dorsa of the hands. Serum enzymes are usually raised and the electromyogram (EMG) is often abnormal showing a myopathic or mixed myopathic/neuropathic pattern. Muscle and skin biopsy have been variously reported as helpful and unhelpful, possibly depending on the site chosen. In a patchy disorder a near normal piece of tissue may be obtained and in an older lesion the later

changes may obscure the initial specific abnormality. In childhood, vasculitis is said to predominate with muscle changes mainly secondary to vascular occlusion (Dubowitz and Brooke, 1973; Boyle and Buchanan, 1973).

This paper describes the clinical course of 8 children with dermatomyositis and illustrates the diagnostic and therapeutic problems.

Patients and methods

From data provided by the Research and Intelligence Unit of the Scottish Home and Health Department, Edinburgh, we found 8 cases of dermatomyositis in childhood admitted to children's hospitals or paediatric units in Scotland during the years 1962–72, 2 of them (Cases 1 and 8) being under our own care. There were 5 girls and 3 boys. The age at onset of the disease ranged from 28 months to 11 years with a mean of 5 years. The period of observation ranged from 2 to 13 years. All the children had been examined clinically, biochemically, radiologically, and histologically in the units concerned but biopsy reports were available only in 7. The main features are summarized in Tables I and II.

Case reports

Case 1. An 11-year-old boy presented in 1962 with a 5-month history of erythematous rash over the extensor surface of both elbows and of the thighs and buttocks and puffy eyelids. There were discrete red areas on his hands. He had painful joints and was unable to walk

TABLE
Clinical features and current status of

Case no.	Sex	Age at onset (yr)	Duration of follow-up (yr)	Initial prednisolone dosage	Duration of initial dosage
1	M	11	13	40 mg/day	1 week
2	M	2½	12	40 mg/day	1 week
3	F	10	7	ACTH 10-20 IU 4 days/week	2 years
4	F	7½	6	60 mg/day	1 week
5	M	5½	6	60 mg/day	5 days
6	F	4	4	60 mg/day	2 weeks
7	F	8	4	60 mg/day	4 weeks
8	F	2½	2	60 mg/day	2 weeks

TABLE
Summary of laboratory findings in

Investigation	Case 1	Case 2	Case 3	Case 4
Hb (g/dl)	12	13.9	11.8	14
ESR (mm in 1 hr)	8	50	20	15
WBC (mm ³)	4700	5600	5500	6000
ECG	Partial RBBB	N	N	N
SGOT (IU/l)	200	NT	126	163
SGPT (IU/l)	180	39	235	NT
CPK (IU/l)	NT	NT	174	420
Soft tissue calcification	Extensive (2 yrs later)	Extensive (1 yr later)	Extensive (4 yrs later)	None
Skin and muscle biopsy	Active myositis with inflammatory cells (mainly mononuclear) between muscle bundles tending to sheath small venules, early degeneration of muscle fibres and overlying skin tissue and subcutaneous fat showed patchy lymphocyte aggregates around some venules. Muscular arterioles not involved.	Details not available	No histological abnormality	Small areas of degeneration of muscle fibres with lymphocytic infiltration. At one or two places fibres were irregular in size and had lost striations

N, no abnormality detected. NT, not tested. In all cases urea and electrolytes, total protein, and electrophoresis were normal and antinuclear factor and LE cell phenomenon were negative.

well. He was treated with prednisolone for 21 months and responded satisfactorily. Extensive soft-tissue calcification developed 2 years after the onset of disease (Fig. 1). Three calcified nodules, two around the right

elbow the other on the left elbow, were excised with small ellipses of skin. He has remained in complete remission over the past 11 years. He is married, works as a window cleaner, and has a family of four children.

I
8 cases of childhood dermatomyositis

Maintenance prednisolone dosage	Duration of maintenance dosage (yr)	Current status	Comments
10 mg/day	1½	Complete remission	Married, has family, and works regularly as window cleaner
Synacthen gel 1 mg/week	2	Complete remission	Bilateral equinovarus deformity, multiple contractures
5 mg/day	5	Complete remission	Multiple contractures
2.5 mg/day	1	Complete remission	No deformity
5-15 mg/day	5½	Died after 6 years	Developed congestive cardiac failure
7.5 mg/day	1½	Complete remission	No deformity
1.25 mg/day	9 months	Complete remission	No deformity
20 mg/day	2	Still active	No deformity

II
8 cases of childhood dermatomyositis

Case 5	Case 6	Case 7	Case 8
14	12	11.8	12
14	8	20	17
7000	7100	5500	5500
Left ventricular damage	Sinus tachycardia	N	N
120	195	580	49.5
80	154	96	NT
NT	42.7	224	88
Extensive (4 yrs later)	None	None	Extensive (2 yrs later)
No histological abnormality	Small collections of chronic inflammatory cells in lower dermis and sub-cutaneous fat but no frank arteritis. Muscle sections showed active phagocytosis of degenerating muscle fibres and variations in fibre diameter affecting nearly all muscle bundles	Some inflammatory cells present in dermis. Vasculitis not seen. No evidence of muscle fibre degeneration or atrophy. Two small foci of lymphocytes but widespread inflammatory change absent	Medium-sized blood vessels and bands of connective tissue in chronic inflammatory state. Cellular exudate mainly lymphocytic but a few plasma cells. Patches of muscle fibres close to inflammatory tissue showed loss of central structure. No type specific atrophy of muscle fibres.

Case 2. A 2½-year-old boy was admitted to hospital in April 1963 with a 4-week history of low back pain and progressive stiffness in the lower limbs. He had an erythematous rash of the upper eyelids,

cheeks, and a palmar erythema with reddening of the nailbeds and dorsa of the distal phalanges. He had a painful left knee and pain in the hip joints, cervical spine, and temporomandibular joints. A diagnosis of

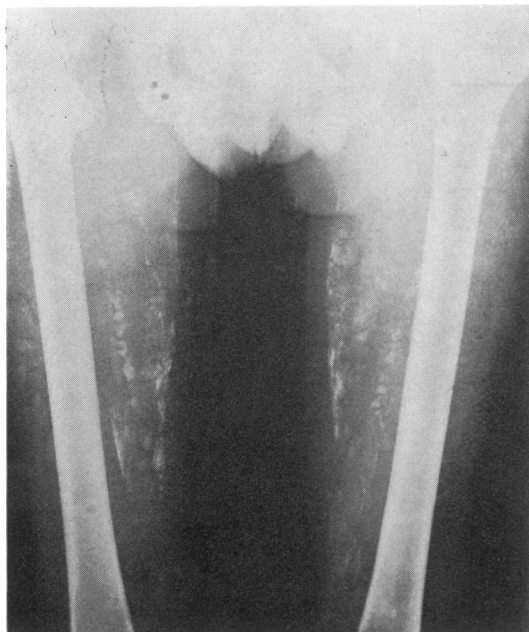

FIG. 1.—Case 1. Extensive subcutaneous calcification 2 years after onset of disease.

Still's disease was made but his facial rash later suggested dermatomyositis. He developed subcutaneous calcification and was given ethanehydroxydiphosphonate (EHDP) 10 mg/kg per day. Radiological examination showed a significant diminution in ectopic calcification after 2 years of EHDP therapy. He was treated with prednisolone 40 mg/day with rapid improvement within a week. This was followed by Synacthen (tetracosactrin) gel 1 mg weekly intramuscularly for 2 years. He has flexion contractures of both hips and both knees and bilateral equinus deformity for which bilateral achilles tenotomy was carried out with good effect. He is unable to stand unaided and can only move around the house on a tricycle. Otherwise his disease has been inactive for the past 10 years.

Case 3. A 10-year-old girl was admitted in October, 1967 with a history of swollen ankles, elbows, and wrists. One month later she developed subcutaneous nodules and a violaceous rash over her face. At this stage a diagnosis of juvenile dermatomyositis was made and she was given a prolonged course of corticosteroids. She improved gradually, her pain and muscle weakness largely subsided, but the stiffness persisted. Four years later she developed heavy soft-tissue calcification lying posterior to the lower end of both humeri and both olecranon processes and posterior to the upper half of both ulnae (Fig. 2). She was given a course of diphosphonates (EHDP) 10 mg/kg per day which had no effect on the ectopic calcification. She is currently in remis-

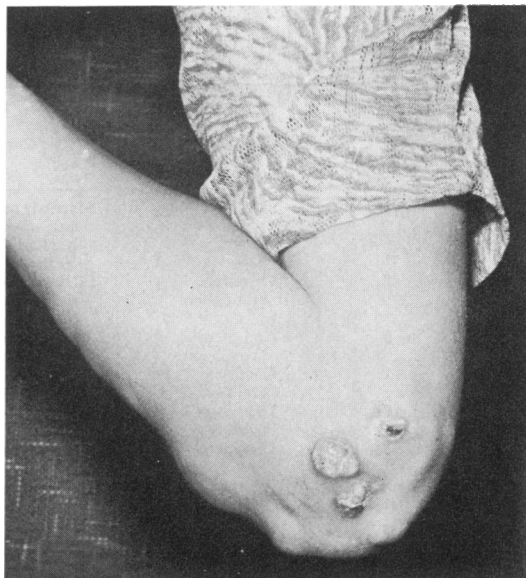


FIG. 2.—Case 3.—Calcinotic nodules in skin and subcutaneous tissues with extrusion of calcified debris.

sion and has contractures of several joints but is only minimally incapacitated.

Case 4. A 7½-year-old girl presented in August 1969 with a 4-week history of weakness of the legs. She had heliotrope discoloration of her eyelids, puffiness of the hands, and slight erythema just proximal to the nail beds and over the interphalangeal joints. There was pronounced impairment of muscle power affecting the whole body but especially the proximal parts of the limbs and the flexors of the thighs. She was treated with corticosteroids for one year and showed a gradual improvement. She has been off corticosteroids for 5 years and her disease at present is inactive. She has no residual deformity.

Case 5. A 5½-year-old boy presented in October 1967 with a history of generalized stiffness and pain in the limbs for 2 months. He had a violaceous facial rash. The elbows showed a scaling erythema and induration of the extensor aspects. There was no other detectable abnormality. A prolonged course of prednisolone was given. Initially his symptoms improved but later his condition deteriorated. He was unable to lift his feet up and could only reach his mouth to eat by leaning his elbows on the table. He was started on methotrexate 5 mg intravenously at monthly intervals (for 3 months), which had no beneficial effect. His joints later became very stiff and fairly immobile. His condition suddenly deteriorated and he died of congestive cardiac failure 6 years after the onset of disease. Necropsy was not performed.

Case 6. A 4-year-old girl presented in April 1971 with increasing difficulty in walking, particularly on going upstairs. She often fell and had to be carried upstairs. For 9 months she had had a rash on her eyelids. She also had redness of her knees and knuckles which was attributed to frequent falls. She had no difficulty in supporting her head or in eating. She had a striking violaceous rash on her eyelids. Her muscles were very wasted and fibrotic on palpation, particularly the proximal muscles in the upper limbs and all lower limb muscles. Other systems showed no significant abnormality. She was treated with prednisolone 60 mg/day for two weeks followed by 7.5 mg/day for 1½ years. Two months later her parents noticed that she was 'getting about a lot better.' She had no muscular pains and her skin rash had become less striking. On review 4 months later she was able to walk upstairs without holding on and she was able to get up from the floor without support. Apart from slight violaceous tinges to her eyelids her skin was completely clear. Her corticosteroids were completely withdrawn after 1½ years. She has been off steroids for 2 years and has had no recurrence of her skin lesions or muscular weakness.

Case 7. An 8-year-old girl presented in 1971 with a rash on her face, neck, and back and weakness of the proximal muscles of her lower limbs. She was unable to stand unsupported. She had no other abnormality. She was treated with prednisolone 60 mg/day for 4 weeks followed by 1.25 mg/day for 9 months. Four weeks after the start of steroid therapy she was able to do everything for herself and had no difficulty in going up or down stairs. She made a slow and steady recovery and corticosteroids were stopped after 10 months. That was 3 years ago and there has been no recurrence of the skin rash, muscle weakness, or pain although there is still a violaceous tinge to her eyelids.

Case 8. A 28-month-old girl presented in 1972 with a 2-3 months' history of being unable to climb stairs and of often falling down. She could not get up from the lying or sitting position by herself. She became very stiff, especially in the morning, and seemed unable to bend. She had had a dry skin for a long time but an erythematous rash on her face, axillae, and back had been noticeable on and off over the whole period of her illness. There was weakness predominantly of the proximal muscle and considerable weakness of neck flexors so that her head lagged when coming up to the sitting position. She had a waddling gait and tended to slip through one's fingers when held under the armpits. Her skin showed several abnormalities including a fleeting erythema and an 'eczematous' dry rash on face, upper trunk, and axillae in which grey-yellow, punched-out ulcers appeared later. She was treated with prednisolone 60 mg/day for 2 weeks followed by 20 mg/day, on which she marginally improved. Since she had been on corticosteroids for 2 years cyclophosphamide 50-100 mg weekly was tried for 3 months, with little beneficial effect. At present her disease is active. Increasing subcutaneous calcification is being treated with diphosphonate.

Discussion

Although dermatomyositis was first described in 1863, its course is so variable as to be difficult to predict. In children the clinical pattern tends to run more true to type than in adults, in whom vascular lesions have been less characteristic of the pathological findings (Banker and Victor, 1966). In this series the combination of muscle weakness and a characteristic rash was common to all cases, so that there was little diagnostic difficulty. Nevertheless, Cases 2 and 8 were thought initially to be juvenile rheumatoid arthritis, but the diagnosis became clear after the pathognomonic facial rash of dermatomyositis had been recognized. The diagnosis is therefore essentially a clinical one as muscle changes seen on biopsy may vary from the florid to the insignificant or completely normal (Boyle and Buchanan, 1971; Dubowitz and Brooke, 1973). Biopsy of skin and muscle showed the characteristic vasculitis with accompanying degeneration of muscle fibres in only two children (Cases 1 and 8). In Cases 4, 6, and 7 there was apparently no evidence of vasculitis but only degeneration of muscle fibres, and Cases 3 and 5 showed no histological abnormality at all. Thus an apparently normal looking muscle on biopsy or an absence of vasculitis does not exclude a clinical diagnosis of dermatomyositis. Serum enzyme levels (SGOT, SGPT, CPK) were raised in all 8 patients but the erythrocyte sedimentation rate was unhelpful. Tests for the LE cell phenomenon and antinuclear factor were negative in all cases.

Children seem more apt to develop calcinosis than adults (Banker and Victor, 1966), and 5 of our 8 children (Cases 1, 2, 3, 5, and 8) developed extensive subcutaneous calcification, one year (Case 2), two years (Cases 1 and 8), and four years (Cases 3 and 5), respectively after the onset of disease. Cases 1 and 3 had nodules which extruded calcified debris which was removed surgically (Fig. 2). The management of calcinosis in general is difficult and chelating agents have given disappointing results (Hill and Wood, 1970). However, Cases 2, 3, and 8 were treated with diphosphonates (EHDP) 10 mg/kg per day. Case 2 showed a definite radiological improvement in the calcified deposits but Case 3 had no change in the ectopic calcification. Case 8 has only recently begun treatment. Cook, Rosen, and Banker (1963) reported calcium deposits in 60% of children who survived and who were followed up for more than 2 years. The appearance of calcification in dermatomyositis seems to constitute an important prognostic sign of survival (Muller, Winkelmann, and Brunsting, 1959).

Of the many therapeutic measures employed at

one time or another for juvenile dermatomyositis corticosteroids have received the most attention. Additional measures are physiotherapy, orthopaedic procedures, and nursing care to try to prevent contractures. All 8 children in this series were treated initially with large doses of corticosteroids—prednisolone 40–60 mg/day (Cases 1, 2, 4, 5, 6, 7, and 8) or ACTH 10–20 IU on alternate days (Case 3). The prednisolone dosage was reduced after 1–2 weeks and maintenance therapy continued on a long-term basis ranging from 9 months to 5 years in doses of the order of 1.25 to 20 mg prednisolone per day or Synacthen gel 1 mg/week. The response to steroids was slow but steady, and improvement in most of the children was characterized by subsidence of skin lesions, diminution of muscle pain and tenderness, and increase in muscle strength. Steroids were discontinued after 10 months (Case 7), one year (Case 4), 18 months (Case 6), and two years (Cases 1, 2, and 8).

Cases 3 and 5 needed maintenance steroid therapy for 7 and 6 years, respectively, to suppress their disease. Whenever steroids were stopped signs of relapse appeared. The activity of the disease was judged by raised serum enzyme (SGOT, SGPT, CPK) levels, and these seen to be a useful guide to the adjustment of steroid dosage. In addition, 2 of the children (Cases 5 and 8) were given cytotoxic therapy with methotrexate or cyclophosphamide for 3 months, without benefit.

Ansell, Hamilton, and Bywaters (1971) reported that the overall prognosis in dermatomyositis had been improved by the introduction of cytotoxic drugs. Malaviya, Many, and Schwartz (1968) treated 4 patients with intravenous methotrexate. The clinical and laboratory responses were satisfactory, but they suggested that treatment should be evaluated in other patients. Some believe that corticosteroids offer no more than symptomatic relief, while others emphasize their value (Bitnum, *et al.*, 1964; Hill and Wood, 1970; Ansell *et al.*, 1973; Dubowitz and Brooke, 1973). Our own experience supports the latter view.

Various workers have emphasized a high mortality in juvenile dermatomyositis. It seems from several reports that most fatalities occur within two years of onset (Sheard, 1951; Wedgwood, Cook, and Cohen, 1953; Everett and Curtis, 1957; Cook *et al.*, 1963). Perforation of the gastrointestinal tract was the immediate cause of death in 7 of 8 cases reviewed by Banker and Victor (1966). Other causes of death are palatorespiratory insufficiency or cardiac failure.

Case 5 of the present series died 6 years after the onset of disease. The terminal phase of illness was

complicated by cardiac failure. In six (Cases 1, 2, 3, 4, 6 and 7) the disease has been in complete remission over the past 11, 10, 7, 5, 3, and 3 years respectively. These 6 children, while showing residual evidence of the disease (calcinosis, minor contractures, or minimal skin changes) are able to lead normal lives. Case 2, however, had surgical intervention for contractures but he is still fairly restricted in physical activity. This suggests that once the disease becomes inactive over a period of several years subsequent exacerbations are uncommon. The disease in Case 8, being refractory to steroids, continues to be active over the past 2 years. Possibly it may become inactive in due course. Furthermore, in view of the extensive soft tissue calcification in this patient, the chances of survival are probably good, although the quality of life cannot be predicted. Only one other patient (Case 2) in this series is seriously incapacitated by residual contractures or calcinosis, or both.

We thank the Research and Intelligence Unit, Scottish Home and Health Department, Edinburgh, for the details of these patients, and our colleagues for allowing us to study patients under their care.

REFERENCES

- Ansell, B. M., Hamilton, E., and Bywaters, E. G. (1973). Course and prognosis in juvenile dermatomyositis. *II International Congress on Muscle Disease*, pt. II. Ed. by B. A. Kakulas. International Congress Series, no. 295. Excerpta Medica, Amsterdam.
- Banker, B. Q., and Victor, M. (1966). Dermatomyositis (systemic angiopathy) of childhood. *Medicine*, **45**, 261.
- Bitnum, S., Daeschner, C. W., Travis, L. B., Dodge, W. F., and Hopps, H. C. (1964). Dermatomyositis. *Journal of Pediatrics*, **64**, 101.
- Boyle, J. A., and Buchanan, W. W. (1971). *Clinical Rheumatology*, p. 507. Blackwell Scientific Publications, Oxford and Edinburgh.
- Cook, C. D., Rosen, F. S., and Banker, B. Q. (1963). Dermatomyositis and focal scleroderma. *Pediatric Clinics of North America*, **10**, 979.
- Dubowitz, V. (1969). Muscle disorders in childhood. *British Journal of Hospital Medicine*, **2**, 1627.
- Dubowitz, V., and Brooke, M. H. (1973). *Muscle Biopsy: A Modern Approach*, p. 319. Saunders, Philadelphia.
- Everett, M. A., and Curtis, A. C. (1957). Dermatomyositis. A review of nineteen cases in adolescents and children. *Archives of Internal Medicine*, **100**, 70.
- Hanson, V., and Kornreich, H. (1967). Systemic rheumatic disorders (Collagen disease) in childhood: lupus erythematosus, anaphylactoid purpura, dermatomyositis and scleroderma. *Bulletin on Rheumatic Diseases*, **17**, 441.
- Hill, R. H., and Wood, W. S. (1970). Juvenile dermatomyositis. *Canadian Medical Association Journal*, **103**, 1152.
- Malaviya, A. N., Many, A., and Schwartz, R. S. (1968). Treatment of dermatomyositis with methotrexate. *Lancet*, **2**, 485.
- Muller, S. A., Winkelmann, R. K., and Brunsting, L. A. (1969). Calcinosis in dermatomyositis. *Archives of Dermatology*, **79**, 669.
- Sheard, C. (1951). Dermatomyositis. *Archives of Internal Medicine*, **88**, 640.
- Wedgwood, R. J. P., Cook, C. D., and Cohen, J. (1953). Dermatomyositis. *Journal of Pediatrics*, **12**, 447.

Correspondence to Dr. K. M. Goel, Royal Hospital for Sick Children, Yorkhill, Glasgow, G3 8SJ.