

Nifedipine in hypertensive emergencies

O BERTEL, D CONEN, E W RADÜ, J MÜLLER, C LANG, U C DUBACH

Abstract

The effects and safety of using oral nifedipine 10-20 mg as acute antihypertensive treatment were studied in a single-blind placebo-controlled study of 25 consecutive patients with very high blood pressure requiring emergency reduction. In addition the effect of this treatment on cerebral blood flow was investigated using xenon-133 in 10 patients randomly allocated to receive oral nifedipine or intravenous clonidine. Whereas placebo did not alter the blood pressure, oral nifedipine significantly reduced the systolic and diastolic blood pressures in all 25 patients (from $221 \pm 22/126 \pm 14$ mm Hg to $152 \pm 20/89 \pm 12$ mm Hg after 30 minutes, $p < 0.001$). Heart rate increased from 74 ± 11 to 84 ± 11 beats/minute ($p < 0.01$); this effect was inversely related to age ($r = -0.65$, $p < 0.01$). The falls in systolic and diastolic blood pressures were closely related to the blood pressures before treatment ($r = 0.67$, $p < 0.001$ for systolic, and $r = -0.58$, $p < 0.01$ for diastolic values). No serious unwanted effects were observed. Measurement of cerebral blood flow after nifedipine showed an increase in flow in four out of five patients. Clonidine, by contrast, reduced cerebral blood flow in all patients by up to 28%.

Nifedipine is a simple, effective, and safe alternative drug for managing hypertensive emergencies, especially when continuous monitoring of the patient cannot be guaranteed.

Introduction

Acute treatment of hypertensive emergencies carries risks¹⁻⁴ despite the variety of drugs currently used. A rapid fall in blood pressure in patients with severe hypertension may result in permanent ischaemic damage due to disturbance of the autoregulation of cerebral blood flow. Serious and sometimes fatal complications of treatment in hypertensive crises have been reported for nearly all drugs, such as sodium nitroprusside,⁵ diazoxide,³ methyl dopa,² hydralazine,² and ganglionic blocking agents.¹ Thus continuous monitoring is mandatory to prevent hypotensive episodes. Such monitoring is not available in general practice and seldom in emergency rooms. Therefore, restricting acute treatment of high blood pressure has been suggested.¹ In this study we provide evidence that oral nifedipine may be a safe and effective method of controlling blood pressure in hypertensive emergencies without reducing cerebral blood flow.

Patients and methods

Thirty successive patients aged from 37 to 80 with very high blood pressure requiring emergency reduction from the outpatient depart-

ment and the emergency room of the medical department were entered in the study. All patients had a mean blood pressure higher than 130 mm Hg; they were considered to require emergency reduction because of various associated factors—namely, hypertensive encephalopathy (six patients), intracranial haematoma (three), fundal haemorrhages (three), unstable angina (three), diabetic retinopathy (three), use of oral anticoagulants (three), severe headache as chief complaint (three), severe bleeding (two), dissecting aneurysm of the aorta (two), and severe congestive heart failure (two). Use of oral anticoagulants (phenprocoumon) in three patients with mean blood pressures of 146, 152, and 154 mm Hg was included in our list of indications because of the especially high risk of intracranial haemorrhages in these patients.

Hypertension was of renovascular origin in three patients as established by angiography; three patients had diabetic nephropathy and one a pheochromocytoma. In two patients the high blood pressures were classified retrospectively as neurogenic: one, with hypertension of recent onset, had a glioblastoma multiforme while the other, with well-controlled essential hypertension, was admitted because of an intracerebral haematoma and a blood pressure of 230/122 mm Hg. In 21 patients the final diagnosis was essential hypertension.

Nineteen of the 30 patients had been treated previously with a combination of up to four different drugs. If facilities for measurement of cerebral blood flow were available patients were randomised, after giving informed consent, to treatment with oral nifedipine ($n = 25$) or intravenous clonidine ($n = 5$). The starting doses of 10 mg nifedipine and 75 μ g clonidine were doubled after 30 minutes if the mean blood pressure was still above 130 mm Hg. Before treatment and after mean blood pressures lower than 130 mm Hg had been reached cerebral blood flow was measured. In the 20 patients in whom cerebral blood flow could not be measured treatment with nifedipine 10-20 mg by mouth was begun either after a placebo period of one hour or immediately if the placebo period was omitted for ethical reasons.

Heart rate and blood pressure were measured by a trained nurse every five minutes during the first 30 minutes after treatment and then every 15 minutes, a London School of Hygiene random zero sphygmomanometer being used.

Cerebral blood flow was studied under standardised conditions using a Novo Cerebrograph. Xenon-133 (15 mCi) dissolved in 5 ml sodium chloride was given intravenously and regional xenon wash-out curves measured by eight detectors placed over each hemisphere. The values for global and regional cerebral blood flow were calculated using a standard computer program.⁶ End-tidal carbon dioxide pressure was monitored during all procedures and remained constant in nine of the 10 patients; in one patient values of cerebral blood flow were corrected for an increase in carbon dioxide pressure in the second flow study (4%/1 mm Hg change in pressure).

Statistical methods—Analysis of variance was used for blood pressures before and after treatment, and Student's *t* test to compare changes in cerebral blood flow after treatment. Correlations were calculated according to the least squares method. Results are given as mean \pm 1 SD.

Results

Effect of oral nifedipine on blood pressure and heart rate—In all 25 patients treated with oral nifedipine systolic and diastolic blood pressures decreased significantly (fig 1). The effect was first observed after 10 minutes, was maximal after 30-40 minutes, and lasted for at least 90 minutes. The absolute fall in blood pressure was not uniform but was directly correlated with the pretreatment systolic ($r = -0.67$, $p < 0.001$) and diastolic blood pressures ($r = -0.58$, $p < 0.01$; fig 2) but not with age. Only one patient, who was receiving a rigorous diuretic regimen, exhibited a fall in the systolic blood pressure to 95 mm Hg, but he was asymptomatic even in the upright position. Heart rate increased significantly after nifedipine from 74 ± 11 to 84 ± 11 beats/minute ($p < 0.01$). This rise was correlated with the age of the patients: younger patients showed a higher increase than older patients ($r = -0.65$, $p < 0.01$).

Medizinische Universitäts-Poliklinik, Department of Internal Medicine and Department of Neurology, University Hospital, CH-4031 Basle, Switzerland

O BERTEL, MD
D CONEN, MD
E W RADÜ, MD
J MÜLLER, MD
C LANG, MD
U C DUBACH, MD

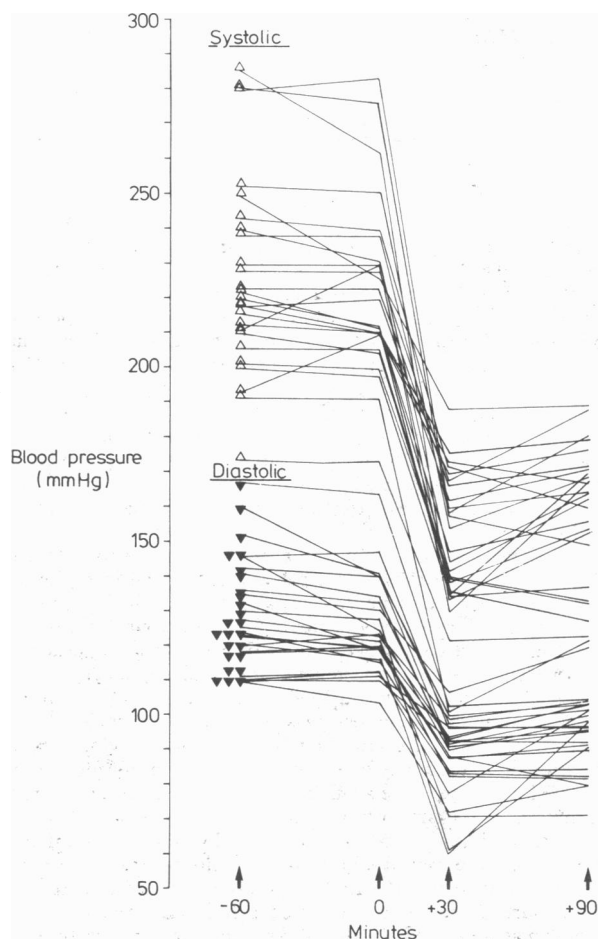


FIG 1—Effect of 10–20 mg nifedipine by mouth in hypertensive emergencies ($n=25$).

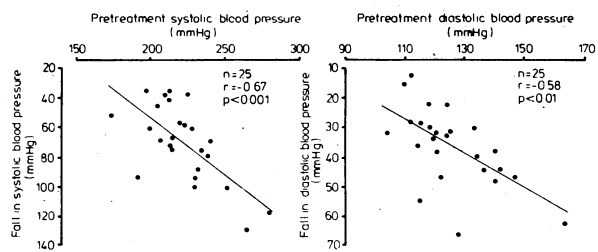


FIG 2—Fall in systolic and diastolic blood pressures after oral nifedipine related to pretreatment pressures.

Effect of nifedipine and clonidine on cerebral blood flow—Before treatment global cerebral blood flow was normal in all 10 patients tested. Oral nifedipine and intravenous clonidine were equally effective in lowering blood pressure (fig 3). Significantly different changes in cerebral blood flow, however, were observed between the patients treated with nifedipine and those treated with clonidine: whereas clonidine reduced cerebral blood flow in all patients by up to 28% (-8 ± 6 ml/100 g/min), four of the patients treated with nifedipine showed an increase in flow while the remaining one showed a slight decrease ($+4 \pm 5$ ml/100 g/min, $p < 0.01$).

Adverse effects—No serious adverse effects were observed. Three patients had flush-like symptoms after nifedipine, one patient complained of a dry mouth after clonidine, and one patient exhibited sinus bradycardia after 225 μ g clonidine (52 beats/minute).

Discussion

Nifedipine was effective and did not cause any serious side effects in all 25 patients studied. Since the fall in blood pressure

was closely related to the pretreatment pressure the effect of nifedipine seems to be predictable, so we consider that continuous monitoring of the patient is not necessary after nifedipine has been given. Thus treatment with oral nifedipine offers an advantage when compared with the usual regimens for hypertensive emergencies.

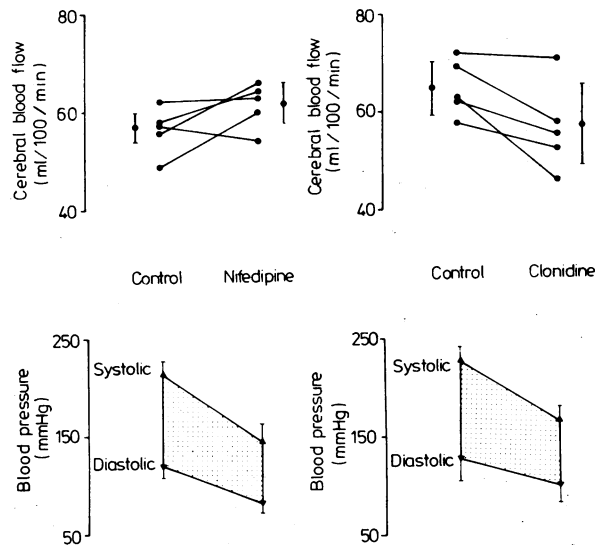


FIG 3—Effect of oral nifedipine and intravenous clonidine on blood pressure and cerebral blood flow in 10 patients.

An even more important difference from other drugs emerged from the studies of cerebral blood flow comparing the effects of nifedipine and clonidine. After clonidine had been taken the fall in blood pressure resulted in diminished blood flow, which might be a serious threat to high-risk patients. This effect is most probably related to the fall in cardiac output and to the slight concomitant rise in peripheral resistance.⁷ By contrast, nifedipine predominantly lowers peripheral vascular resistance by blocking calcium exchange and cardiac output remains constant or even increases as a result of a reduction in afterload.⁸ The peripheral vasodilating effect of nifedipine is not uniform like that of other vasodilating agents, which may induce a “steal effect,” but depends on the blood pressure before treatment. In addition, recent animal experiments have shown that cardiac and cerebral regional flow increase selectively after vasodilatation with nifedipine.⁹ The absence of any effects of nifedipine on blood pressure in healthy subjects as well as the vasodilating effects in patients with Raynaud’s phenomenon may also be interpreted as a selective action of nifedipine in blood vessels with abnormally raised tone.

The slight age-dependent increase in heart rate may be best explained by a higher beta-adrenergic responsiveness to sympathetic stimulation in younger people.¹⁰ All reported effects of nifedipine in hypertensive patients accord well with our findings: Guazzi *et al*¹¹ found the drug to be extremely effective in three patients with seriously raised blood pressures, and treatment of hypertensive patients in an emergency room was successful in nearly all cases without any adverse effects.¹² Despite the increasing frequency with which nifedipine is prescribed in patients with coronary heart disease only one report has claimed a possible relation between nifedipine treatment and transient cerebral ischaemia.¹³ In this report, however, blood-pressure values were not given and there was no clear-cut relation between the ischaemic episodes and nifedipine treatment. We conclude, therefore, that oral nifedipine should be regarded as an effective and safe alternative treatment in hypertensive emergencies, especially if intensive patient care cannot be guaranteed.

References

- ¹ Anonymous. Dangerous antihypertensive treatment. (Editorial.) *Br Med J* 1979;ii:228-9.
- ² Ledingham JGG, Rajagopalan B. Cerebral complications in the treatment of accelerated hypertension. *Q J Med* 1979;48:25-41.
- ³ Kumar GK, Dastoor FC, Robayo JR, Razzaque MA. Side effects of diazoxide. *JAMA* 1976;235:275-6.
- ⁴ Graham DI. Ischaemic brain damage of cerebral perfusion failure type after treatment of severe hypertension. *Br Med J* 1975;ii:739.
- ⁵ Merrifield AJ, Blundell MD. Toxicity of sodium nitroprusside. *Br J Anaesth* 1974;46:324.
- ⁶ Meyer JS, Ishihara N, Deshmukh VD, et al. Improved method for non-invasive measurement of regional cerebral blood flow by ¹³³xenon inhalation. Part I. Description of method and normal values obtained in healthy volunteers. *Stroke* 1978;9:195-205.
- ⁷ Lowenstein J. Clonidine. *Ann Intern Med* 1980;92:74-7.
- ⁸ Stone PH, Antman EM, Muller JE, Braunwald E. Calcium channel blocking agents in the treatment of cardiovascular disorders. Part II. Hemodynamic effects and clinical applications. *Ann Intern Med* 1980;93:886-904.
- ⁹ Aboul-Khair M, Wicker P, Tarazi RC. Differences between the effects of hydralazine and a calcium antagonist (BAYe5009) on cerebral, renal and coronary blood flow. *Clinical Research* 1981;29:704A.
- ¹⁰ Bertel O, Bühler FR, Kiowski W, Lütold B. Decreased beta-adreno-receptor responsiveness as related to age, blood pressure, and plasma catecholamines in patients with essential hypertension. *Hypertension* 1980;2:130-8.
- ¹¹ Guazzi M, Olivari MT, Polese A, Fiorentini C, Magrini F, Moruzzi P. Nifedipine, a new antihypertensive with rapid action. *Clin Pharmacol Ther* 1977;22:528-32.
- ¹² Beer N, Gallegos I, Cohen A, Klein N, Sonnenblick E, Frishman W. Efficacy of sublingual nifedipine in the acute treatment of systemic hypertension. *Chest* 1981;79:571-4.
- ¹³ Nobile-Orazio E, Sterzi R. Cerebral ischaemia after nifedipine treatment. *Br Med J* 1981;283:948.

(Accepted 13 October 1982)

SHORT REPORTS

A new danger associated with airgun pellet injuries

The removal of airgun pellets from patients is a common problem in accident and emergency departments. Locating the pellet can be difficult, even with radiographic control. We report a case in which a new type of pellet was encountered, part of which was radiolucent. This type of pellet could lead to difficulties in localisation and removal.

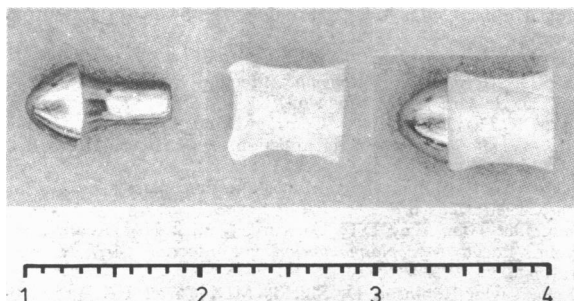
Case report

A 17 year old boy attended the accident and emergency department having been shot in the right side of the neck by an air rifle two hours previously. The pellet had not passed through clothing. On examination there was an entry wound of 5×5 mm on the skin overlying the right sternomastoid muscle, 6 cm above the clavicle. A small lump was palpable 5 cm posterior to the entry wound. Radiographs in two planes showed the pellet 5 cm posterior to the entry wound and 1 cm in depth.

A small incision was made over the pellet under image-intensifier control and the pellet removed from the superficial fibres of the trapezius. The wound was sutured. At this stage there was no evidence of further radio-opaque foreign bodies. The entry wound was explored and a small polyethylene cylinder, part of the original missile, removed from a depth of 1 cm. The entry wound was not sutured.

Comment

In this case the pellet was of two parts, a stainless steel head, and a polyethylene sleeve fitting over the tail (figure). On entry into soft



Hunting pellet from airgun showing stainless steel head and polyethylene sleeve: (left) components (right) assembled.

tissue the sleeve had become detached from the head and had been left in the track of the missile, some distance from where the metallic head had come to rest. The danger with this pellet is that it splits into two components in the body and one of the components is radiolucent, making localisation by x ray examination impossible.

This type of hunting pellet (manufactured by Prometheus, Milbro) is designed for "exceptional penetration."¹ It has been on the market for 18 months, and we are told by the manufacturers that they have recently stopped marketing the pellet for a trial period of one year as they are concerned with its potential danger. The pellets, however, are likely to be on the market for some time until stocks have been used up.

The presence of this type of pellet is shown by its profile on radiographs: a rounded head with a narrow tail. Radiographs of all pellets in soft tissues should show the profile adequately, and if this type of profile is seen the presence of the polyethylene cylinder in the track of the missile should be suspected.

¹ Tasker DG. The air rifle: a dangerous weapon. *Br Med J* 1981;283:57.

(Accepted 9 September 1982)

Accident and Emergency Department, Royal West Sussex Hospital, Chichester, West Sussex PO19 4SE

DAVID CAIN, BM, FRCS, senior registrar
R F WEEKS, MB, CHB, consultant

Severe metabolic acidosis after ingestion of butanone

Misuse of organic solvents is an increasing problem.¹ We report a case of self-poisoning by ingestion of butanone, an organic solvent found in some household and commercial glues.

Case report

A 47 year old housewife born in south India was brought to the casualty department having been found deeply unconscious by her husband. The only relevant history was that she had developed chickenpox one week previously. On examination she was deeply unconscious and unresponsive to painful stimuli. She was hyperventilating, and her breath smelt of a popular glue. Peripheral circulation appeared normal, but blood pressure was 95/70 mm Hg and pulse 120 beats/min. A chickenpox rash was evident with related scratch marks. Blood-gas analysis shortly after her arrival showed oxygen pressure 11.3 kPa (85 mm Hg), carbon dioxide pressure 3.2 kPa (24 mm Hg), bicarbonate concentration 8.5 mmol(mEq)/l, anion gap 30.3 mmol(mEq)/l, and pH 7.19. Plasma electrolyte concentrations were sodium 138 mmol(mEq)/l, potassium 3.8 mmol(mEq)/l, and chloride 103 mmol(mEq)/l; urea concentration was 6.1 mmol/l (37 mg/100 ml), blood glucose concentration 15.7 mmol/l (283 mg/100 ml), haemoglobin concentration 13.4 g/dl, and white cell count $15.5 \times 10^9/l$. A plasma screen for salicylates and paracetamol yielded negative results.

She was given a slow infusion of 150 mmol (12.6 g) 8.4% sodium bicarbonate, after which there was obvious clinical improvement: the hyperventilation became less pronounced, blood pressure rose, and pulse rate slowed. Blood-gas tensions improved correspondingly: oxygen pressure was 10.4