

Vitamin B₁₂ deficiency in chronic gastritis

I. J. WOOD¹, M. RALSTON¹, B. UNGAR, AND D. C. COWLING

From the Clinical Pathology Department of the Royal Melbourne Hospital, and the Clinical Research Unit of the Royal Melbourne Hospital and the Walter and Eliza Hall Institute of Medical Research, Melbourne, Victoria, Australia

EDITORIAL SYNOPSIS This study covers a group of elderly persons who suffer from chronic atrophic gastritis and resulting vitamin B₁₂ deficiency. Increasing weakness, loss of memory, and mental depression were common symptoms and flatulent dyspepsia was sometimes a troublesome recurring complaint. These symptoms were improved by treatment with vitamin B₁₂. Even if untreated, persons in this group rarely develop severe pernicious anaemia.

The introduction of the flexible suction tube for gastric biopsy by members of our Unit (Wood, Doig, Motteram, and Hughes, 1949a) and its extension for jejunal biopsy by Shiner (1956) has enabled us to study chronic gastritis with special reference to the part it may play in causing vitamin B₁₂ deficiency. The clinical manifestations of chronic gastritis have been described elsewhere (Joske, Finckh, and Wood, 1955; Wood and Taft, 1958; Wood, Cowling, Ungar, and Gray, 1960).

The introduction of methods for serum vitamin B₁₂ assay (Ross, 1952) and later the Schilling test for vitamin B₁₂ absorption (Schilling, 1953) provided additional knowledge of established pernicious anaemia. Subsequently Mollin and Ross (1953 and 1954), Spray and Witts (1958), and Siurala, Erämaa, and Nyberg (1960) described the slow fall in the serum vitamin B₁₂ level and its varying effects on the health of the patient.

Gastric biopsy has enabled us to make a conclusive diagnosis of chronic atrophic gastritis and to study a group of cases for a period extending up to 14 years. In 1955 the case of a man aged 65 years, suffering from chronic dyspepsia, achlorhydria, and gastric atrophy was reported: five years later he developed overt pernicious anaemia and subacute combined degeneration of the cord (Robertson, Wood, and Joske, 1955).

A study of 30 patients with chronic atrophic gastritis is now reported, with special reference to the clinical state, serum vitamin B₁₂ levels, Schilling tests, and examination of the blood and central

nervous system. A preliminary study of some of these patients was reported by Wood *et al.* in 1960, but Schilling tests were not performed as this test necessitates the giving of a large dose of vitamin B₁₂, thus interfering with the continuing study.

SELECTION OF PATIENTS

Those selected in the series were patients with achlorhydria or hypochlorhydria in whom gastric biopsy revealed moderate to severe gastritis, with partial to complete atrophy of the acid- and pepsinogen-secreting cells and varying degrees of cellular infiltration, predominantly by plasma cells and lymphocytes.

In keeping with previous experience (Joske *et al.*, 1955; Wood and Taft, 1958; Wood *et al.*, 1960) the majority of patients suffered flatulent dyspepsia, but often this in itself was not of sufficient severity to bring them to our Unit. Thus many initially sought treatment for other ailments.

Patients were excluded from the series if they were suffering from gastric or duodenal ulcer or cancer, a previous gastric operation, or chronic alcoholism with hepatic cirrhosis (Cowling and Mackay, 1959).

METHODS

The method for serum vitamin B₁₂ assay was that of Ross (1952) using *Euglena gracilis* Z stain and the medium of Hutner, Bach, and Ross (1956). The absorption and excretion test was that of Schilling (1953) with minor modifications (Ungar and Cowling, 1962).

In the standard test meal 0.9 mg. of histamine acid phosphate was followed by gastric aspiration for 90 minutes. In the majority of patients with low serum vitamin B₁₂ levels the maximum response test meal of Kay (1953) was used.

¹Working with the aid of a grant from the National Health and Medical Research Council of Australia

Patients were considered to have 'achlorhydria' when the acidity of the gastric contents, as titrated against N/10 sodium hydroxide using Töpfer's reagent, was of pH greater than 3.5 in all samples.

All patients were subjected to gastric biopsy with the flexible suction tube described by Wood *et al.* (1949a). Small bowel biopsies were performed by a modification of the Shiner tube (Shiner, 1956) to render it more flexible (Ralston, Wood, and Hughes, 1960) or by the Crosby capsule (Crosby and Kugler, 1957).

The erythrocyte count was performed with the E.E.L. electronic cell counter and the haemoglobin by a colorimeter using oxyhaemoglobin.

The autoimmune complement-fixation test and the tanned red cell haemagglutination test were performed as described by Mackay and Wood (1962) and Irvine, Davies, Delamore, and Williams (1962).

RESULTS

In the group of 30 cases of chronic atrophic gastritis there were nine men and 21 women. The mean age when the diagnosis was first established by gastric biopsy was 56 years (range 38 to 69 years). The mean duration of the study which followed was nine years (range two to 14 years). Serial studies of the

vitamin B₁₂ level in the serum were made for a mean period of four years (range one to five years).

All of the 30 cases had achlorhydria to standard histamine stimulation on occasion: 21 had it throughout and, of the remainder, six had it at the end of the study. On no occasion was a level above 25 units obtained. All of the seven cases with serum vitamin B₁₂ levels less than 100 µµg. per ml. had achlorhydria to maximum histamine stimulation (Kay, 1953).

Gastric biopsy was performed on all of the 30 patients, 28 being tested on two or more occasions, particularly at the beginning and end of the study (Table I). In 17 the atrophy of acid and pepsinogen-secreting cells was severe and in 13 it was moderate. In eight the atrophy became more pronounced during the study, in 19 it was unchanged, and in one it was less pronounced (Figs. 1 to 4). Intestinal metaplasia was often present when the atrophy was pronounced.

The cellular infiltration of the tunica propria was profuse in six cases and moderately intense in 14: over the years it became more pronounced in six, it was unchanged in 14, and was less in eight. It consisted mostly of plasma cells and lymphocytes.

TABLE I
FINDINGS IN THE 30 PATIENTS WITH GASTRITIS

Case No.	Lowest B ₁₂ Level (µµg.)	Final Examination		
		Gastric Biopsy	R.B.C. (million per c.mm.)	Lesions of Central Nervous System
1	20	Atrophic gastritis	4.5	Normal
2	40	Atrophic gastritis	3.1	Minor subacute combined degeneration of the cord
3	40	Atrophic gastritis	4.3	Peripheral neuritis
4	50	Atrophic gastritis	4.5	Subacute combined degeneration of the cord
5	56	Gastric atrophy	4.5	Minor subacute combined degeneration of the cord
6	80	Atrophic gastritis	5.1	Normal
7	90	Atrophic gastritis	3.5	Normal
8	100	Atrophic gastritis	4.3	Normal
9	100	Atrophic gastritis	4.4	Normal
10	100	Atrophic gastritis	4.0	Normal
11	100	Atrophic gastritis	3.9	Normal
12	110	Atrophic gastritis	3.9	Normal
13	114	Atrophic gastritis	3.6	Normal
14	130	Gastric atrophy	4.9	Normal
15	130	Atrophic gastritis	5.2	Normal
16	140	Atrophic gastritis	4.0	Normal
17	140	Atrophic gastritis	4.0	Minor subacute combined degeneration of the cord
18	140	Atrophic gastritis	3.7	Normal
19	150	Atrophic gastritis	4.5	Minor subacute combined degeneration of the cord
20	160	Atrophic gastritis	4.7	Peripheral neuritis
21	170	Atrophic gastritis	4.5	Normal
22	170	Atrophic gastritis	3.9	Normal
23	180	Gastric atrophy	4.0	Normal
24	180	Atrophic gastritis	4.2	Normal
25	180	Atrophic gastritis	4.4	Normal
26	210	Gastric atrophy	4.5	Peripheral neuritis
27	210	Atrophic gastritis	4.3	Normal
28	240	Atrophic gastritis	4.5	Normal
29	240	Atrophic gastritis	4.5	Normal
30	270	Atrophic gastritis	4.9	Peripheral neuritis

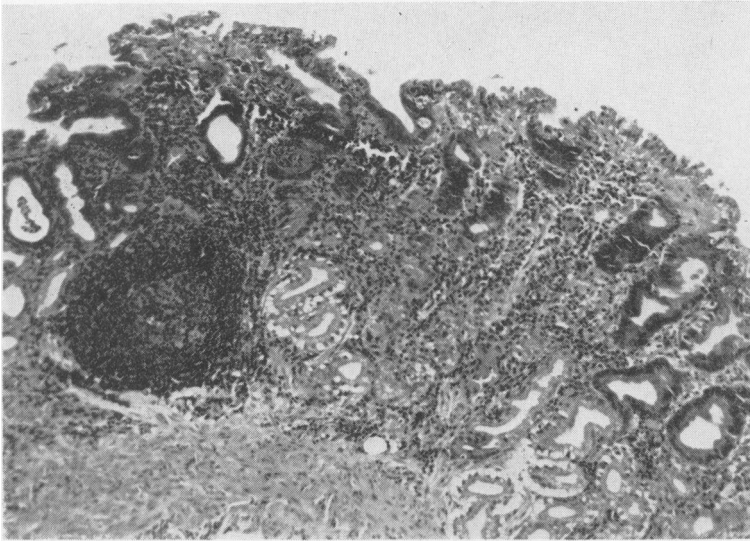


FIG. 1. Case 3. Woman aged 58. Gastric biopsy by suction tube in 1949 showing atrophic gastritis, there being moderate atrophy of the acid- and pepsinogen-secreting cells and intense cellular infiltration of the tunica propria (higher magnification: plasma cells and lymphocytes). There is one large lymph follicle with a germinal centre. Haematoxylin and eosin $\times 100$.

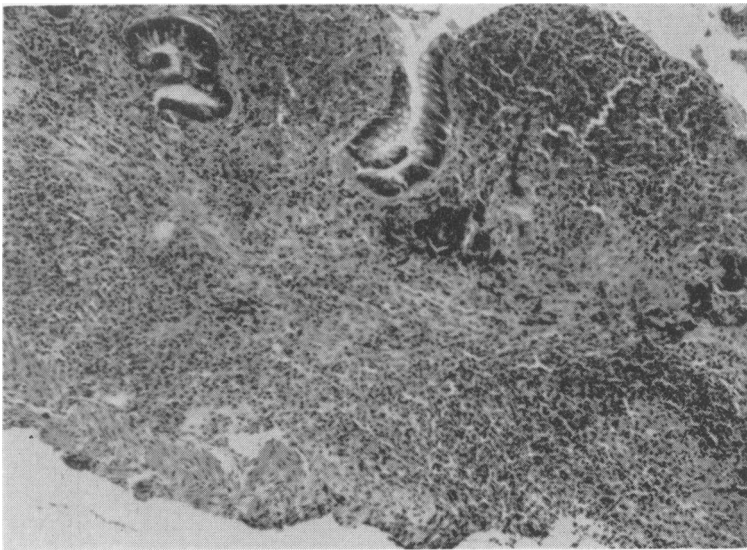


FIG. 2. Case 3 (same as Fig. 1). Gastric biopsy 13 years later showing gross atrophy and persisting cellular infiltration (plasma cells and lymphocytes). There were achlorhydria, serum level of vitamin B₁₂ reduced to 40 $\mu\mu\text{g}$., and an abnormal Schilling test, restored to normal by the addition of intrinsic factor. Haematoxylin and eosin $\times 100$.

Polymorphonuclear cells were relatively sparse. In the normal gastric mucosa small lymphoid follicles are present in the depth of the tunica propria, just above the muscularis mucosae. In the present series the lymph follicles were often enlarged and at these sites the gastric glands were either absent or atrophic.

In four patients (cases 5, 14, 23, and 26) gastric atrophy (Motteram, 1951) was present at the end of the study, their lowest levels of serum vitamin B₁₂ being 56, 130, 180, and 210 $\mu\mu\text{g}$. per ml.

The lowest serum vitamin B₁₂ levels and the range

in the 30 patients are shown in Figure 5. It will be noted that in seven cases the lowest level was in the 'overt' or 'latent' pernicious anaemia range of less than 100 $\mu\mu\text{g}$. per ml. (Wood *et al.*, 1960), in 18 patients it was in the 'pre-pernicious anaemia' range of 100 to 200 $\mu\mu\text{g}$. per ml., and in five patients it was in the normal range (200 to 700 $\mu\mu\text{g}$. per ml. in this laboratory).

The levels fluctuated from month to month, but in the majority of patients there was a downward trend. This pattern is shown in Figure 6, which

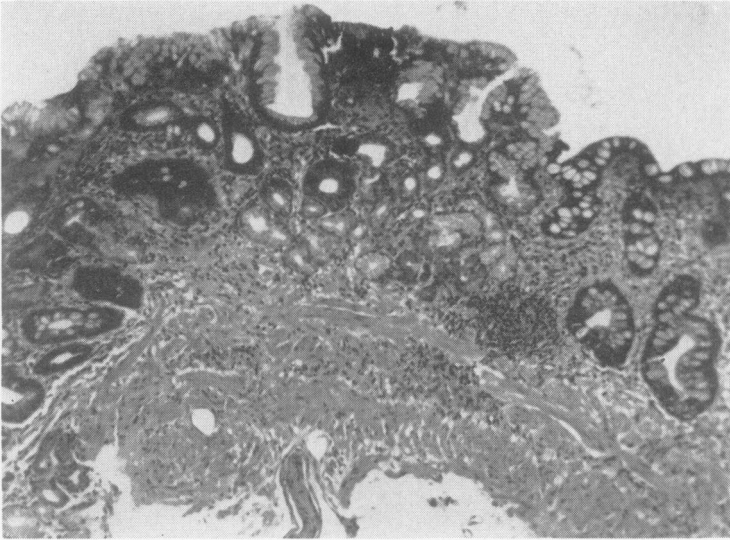


FIG. 3. Case 4. Woman aged 50 with achlorhydria, serum vitamin B₁₂ reduced to 50 $\mu\mu\text{g.}$, abnormal Schilling test, high titre of antibodies to gastric mucosa (16) and thyroid (5,120) and excess lymphoid accumulation in thyroid biopsy, and minor subacute combined degeneration of the spinal cord. Gastric biopsy shows goblet cells, gross atrophy, and moderate cellular infiltration (lymphocytes and plasma cells). Haematoxylin and eosin $\times 90$.

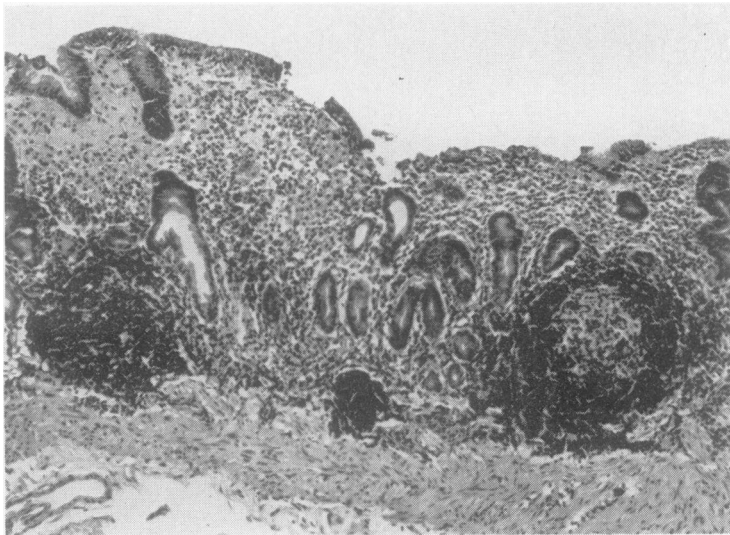


FIG. 4. Case 25. Woman aged 42 with chronic hepatitis and chronic glossitis responding to corticosteroids, and minor reduction of serum vitamin B₁₂ level to 180 $\mu\mu\text{g.}$ Gastric biopsy shows gross atrophy and pronounced cellular infiltration (lymphocytes and plasma cells) with two enlarged lymph follicles, one having a germinal centre. Haematoxylin and eosin $\times 110$.

records the progressive levels in six patients with serum vitamin B₁₂ levels in the pernicious anaemia range.

All patients had severe or moderate gastric atrophy, but the degree of atrophy did not correlate with the serum vitamin B₁₂ levels. Those with severe gastric atrophy had a mean serum vitamin B₁₂ level of 136 $\mu\mu\text{g.}$ per ml. and those with moderate atrophy 135 $\mu\mu\text{g.}$ per ml.

The results of the Schilling test, performed without the addition of intrinsic factor, are also shown in

Figure 5. It will be noted that the percentage of absorption and excretion of labelled vitamin B₁₂ was in the pernicious anaemia range of under 10% in six of the seven patients whose serum vitamin B₁₂ level fell within the pernicious anaemia range (under 100 $\mu\mu\text{g.}$ per ml.), in only two of the 17 patients within the pre-pernicious anaemia range (100 to 200 $\mu\mu\text{g.}$ per ml.), and in one of the four patients within the normal range (over 200 $\mu\mu\text{g.}$ per ml.).

In nine of the patients in whom the Schilling test showed impaired absorption of vitamin B₁₂ the

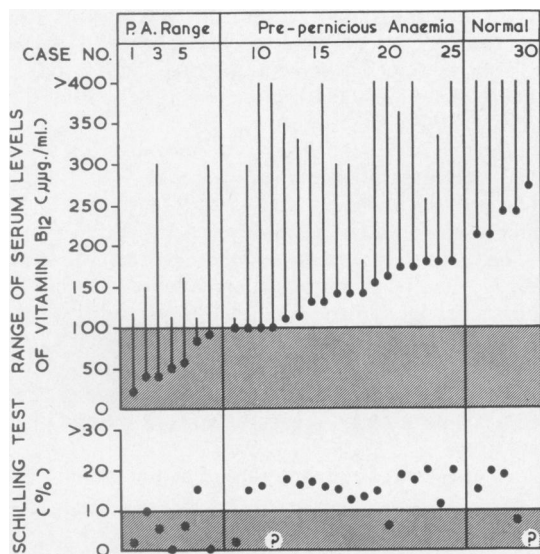


FIG. 5. The lowest level and range of serum vitamin B₁₂ in 30 patients with chronic atrophic gastritis: seven were in the pernicious anaemia range, 18 in the pre-pernicious anaemia range, and five in the normal range. The corresponding results of Schilling tests (without intrinsic factor) are shown in the lower panel: impaired absorption was shown in six of the seven patients whose serum vitamin B₁₂ level was in the pernicious anaemia range.

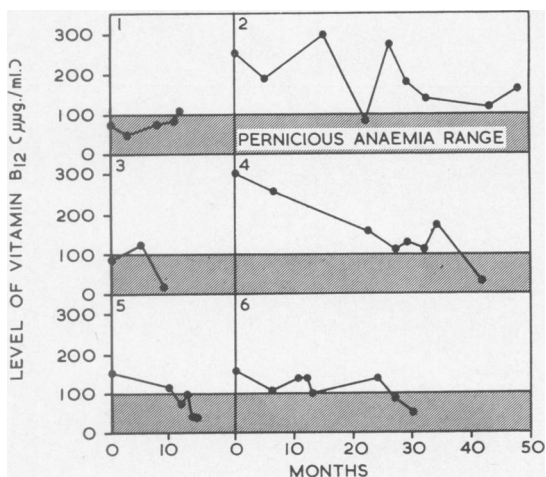


FIG. 6. Serial serum vitamin B₁₂ levels in cases 1, 2, 3, 4, 5, and 7 (panels 3, 5, 4, 1, 6 and 2 respectively). All had low levels, one or more being in the pernicious anaemia range (hatched).

test was repeated with the addition of intrinsic factor to determine whether the low level was due to deficient intrinsic factor being produced by the stomach. The results (Fig. 7) show that in eight of the nine patients tested the addition of intrinsic factor produced a rise to the normal range. The remaining patient (case 4), shown in panel 1 of Figure 6, had achlorhydria to maximum stimulation, severe atrophic gastritis to biopsy, and biopsy of the upper jejunum and lower small bowel revealed well-formed villi without excess lymphoid infiltration. However, she suffered occasional attacks of diarrhoea and fat absorption was moderately impaired over a three-day period.

SYMPTOMS OF B₁₂ DEFICIENCY The 30 patients were elderly and the majority did not complain of major distressing or debilitating symptoms which could definitely be attributed to vitamin B₁₂ deficiency. However, increasing weakness, loss of memory, and mental depression were frequently recorded, together with the flatulent dyspepsia which is a feature of chronic gastritis. Five patients had paraesthesiae in the hands and feet.

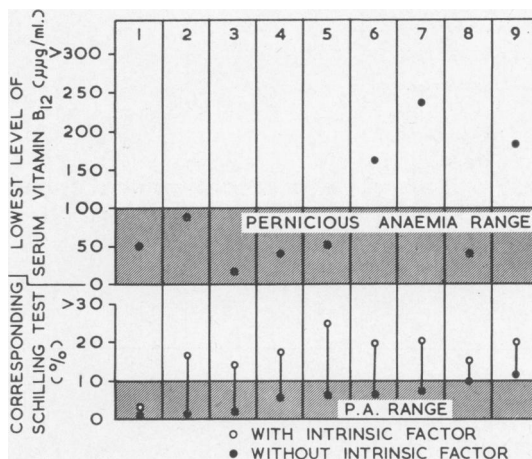


FIG. 7. The results of Schilling tests performed without and with the addition of intrinsic factor in cases 1, 2, 3, 4, 5, 7, 20, 24, and 29 (panels 3, 8, 4, 1, 5, 2, 6, 9, and 7 respectively). There was evidence of deficiency of intrinsic factor except in case 4 (panel 1), a patient who also had intestinal malabsorption.

SYMPTOMS OF GASTRITIS AND ASSOCIATED DISEASES Of the 30 patients, 13 first reported because of dyspepsia, having periodic attacks varying from mild to moderate epigastric discomfort with flatulence to pain of moderate severity. Fifteen had associated diseases: five of these could possibly be related to an autoimmune disease process, there being three cases

of rheumatoid arthritis, one (case 25) of severe chronic ulcerative glossitis and low-grade chronic hepatitis (L.E. cell test negative) responding to steroid therapy, and two of thyroiditis proven by biopsy and with a high serum titre of thyroid antibodies toward red cell haemagglutination. The remaining 10 patients included one with thyrotoxicosis (test negative), one with primary hypertension, six with chronic cholelithiasis (one also with coronary sclerosis and angina pectoris), one with coronary sclerosis, and one with arteriosclerosis and subarachnoid haemorrhage.

BLOOD EXAMINATION The details of the peripheral blood examination are summarized in Table II which shows the case distribution for the blood counts at the end of the study, no vitamin B₁₂ having been administered.

Erythrocyte count At the end of the study seven of the 30 patients had a count below 4,000,000 (Table I). During the study three had a fall of 1,000,000 to 2,000,000 and none had a rise exceeding 1,000,000.

Haemoglobin At the end of the study six patients had a haemoglobin level in the range 9 to 12 g.%. During the study six had a fall of 2 to 4 g.%, and none had a rise of more than 2 g.%.

The mean corpuscular volume At the end of the study the mean corpuscular volume was in the normal range (76 to 96 c μ in this laboratory) in 12 patients, in the range 100 to 110 c μ in 14, and greater than 110 c μ in two.

Leucocyte count There was a leucopenia of 2,000 to 4,000 per c.mm. in seven patients at the end of the study.

At the end of the study none of the patients had

TABLE II

CASE DISTRIBUTION BY BLOOD EXAMINATION AT END OF STUDY				
Erythrocytes per c.mm.	Range Distribution	Over 4.5 million per c.mm. 6 cases	4.4-5 million per c.mm. 17 cases	3.4 million per c.mm. 7 cases
Haemoglobin (g.%)	Range Distribution	Over 14.0 g.% 12 cases	12-14 g.% 12 cases	9-12 g.% 6 cases
Mean corpuscular volume (c μ)	Range Distribution	80-100 c μ 12 cases	100-110 c μ 14 cases	> 110 c μ 2 cases
Leucocytes per c.mm.	Range Distribution	2-4,000 7 cases	5-10,000 23 cases	> 10,000 0 cases

TABLE III

FINDINGS IN SEVEN PATIENTS WITH SERUM VITAMIN B₁₂ LEVELS WITHIN THE PERNICIOUS ANAEMIA RANGE

Case No.	Serum B ₁₂ Range (μ g.)	Schilling		R.B.C. (g.%)	Hb (c μ)	M.C.V. (c μ)	Leucocytes per c.mm.	Film	Bone Marrow	Gastric Biopsy		Nervous System Examination	
		- Intrinsic Factor	+ Intrinsic Factor							Atrophy	Lymphocyte Infiltration	Peripheral Neuritis	Subacute Combined Degeneration of the Cord
1 F 68	20-120	2.3	14.2	4.5	14.6	98	8,000	Slight anisocytosis	Not examined	++	++	Nil	Nil
2 F 67	40-149	10.0	18.8	3.1	11.6	96	6,000	Moderate macrocytosis	Macro-normoblasts	++	+++	++	+
3 F 58	40-300	5.4	17.5	4.3	14.0	101	6,000	Normal	Normal	+++	+++	++	0
4 F 60	50-114	0.5	3.1	4.5	14.0	100	9,000	Normal	Macro-normoblasts	+++	++	+	+
5 M 67	56-162	6.2	24.0	4.5	14.0	95	9,000	Slight macrocytosis	Normal	+++	+	++	+
6 M 56	80-110	14.3	—	5.1	14.6	92	6,000	Normal	Not examined	++	+++	0	0
7 F 55	90-300	1.0	16.5	3.5	12.5	126	4,000	Slight macrocytosis and anisocytosis	Normal	+++	+++	0	0

severe anaemia. However, a few had a minor degree of macrocytic anaemia.

The findings in the peripheral blood and bone marrow in seven patients who had low levels of serum vitamin B₁₂ and an impaired Schilling test are shown in Table III. It reveals moderate anaemia in two patients, one having macrocytosis. Three others had minor macrocytosis. In none of the seven patients tested did the bone marrow show florid megaloblastosis.

THE CENTRAL NERVOUS SYSTEM No patient had florid subacute combined degeneration of the spinal cord. However, five (three with serum vitamin B₁₂ levels in the pernicious anaemia group and two in the pre-pernicious anaemia group) had changes indicative of peripheral neuritis and a minor degree of subacute combined degeneration of the cord. Three had reduced knee and ankle reflexes and impairment of vibration and pain sensation, with pronounced paraesthesiae in one: two had absent ankle reflexes, impaired vibration sense, and moderate paraesthesiae. Minor degrees of paraesthesiae, impairment of the deep reflexes, and impaired sensation were frequently encountered. No patient had abnormal plantar reflexes. The mental changes were those frequently seen with advancing age, but were possibly due in part to vitamin B₁₂ deficiency.

THE TONGUE Two patients had pronounced atrophy, one also having recurrent ulceration. In three there was moderate atrophy, especially in the lateral aspects. A minor degree of atrophy was frequently encountered.

DIET A dietary history, with special reference to the vitamin B₁₂ intake, was obtained in 24 of the patients. The normal range of daily intake as determined by Darby, Bridgforth, Le Brocquy, Clark, de Oliveira, Kevany, McGanity, and Perez (1958) was adopted for study. In 23 patients the history was considered to be reliable: in the remaining patient there was collateral evidence of inadequate vitamin B₁₂ intake and general malnutrition and the tests revealed a serum vitamin B₁₂ level of 140 and a normal Schilling test (12.9%). An analysis of the 'reliable' dietary histories indicated that the daily intake of vitamin B₁₂ was at a high level of the normal range (greater than 20 $\mu\mu\text{g}$. per ml. per day) in three patients, at an intermediate level of the normal range (10 to 20 $\mu\mu\text{g}$. per ml. per day) in 14, and at a low level of the normal range (6 to 10 $\mu\mu\text{g}$. per ml. per day) in five: in none was it less than 6.0 $\mu\mu\text{g}$. per ml. per day, a deficiency which could produce vitamin B₁₂ deficiency *per se*.

The general nutrition was considered to be adequate in 21 patients and poor in three.

FAMILY HISTORY A comprehensive family study was not made. However, all patients were questioned regarding the health of their near relatives. Two stated that their mothers had contracted pernicious anaemia when over 70 years of age, but the records were not available. One woman (case 7) aged 66, with pronounced gastritis, had a sister aged 72 who suffered from flatulent dyspepsia and examination revealed achlorhydria, moderate atrophic gastritis on biopsy, serum vitamin B₁₂ level of 300 $\mu\mu\text{g}$. per ml., and a normal Schilling test of 15.0% and no anaemia.

AUTOIMMUNE COMPLEMENT-FIXATION TEST WITH GASTRIC MUCOSA, LIVER AND KIDNEY ANTIGENS, AND THE TANNED RED CELL HAEMAGGLUTINATION TEST WITH THYROID ANTIGEN The autoimmune complement-fixation test with gastric mucosa antigen was performed by Dr. Ian Mackay on the serum of 28 patients: six gave a significantly positive titre (16 or >16). None gave a positive reaction with liver or kidney. In two patients the tanned red cell haemagglutination test with thyroid antigen was positive in high titre (15,360 and 5,120) and in five cases in moderately high titre (640, 640, 640, 480, and 160). Thyroid biopsy performed in three of these patients revealed moderate lymphoid accumulations in excess of normal in two with titres of 5,120 and 640 (Williams and Doniach, 1962).

DISCUSSION

In 1870 Fenwick described the gastric atrophy of pernicious anaemia and in 1929 Castle, Townsend, Heath, and Strauss discovered the intrinsic factor deficiency which resulted from this atrophy and caused pernicious anaemia by reducing the absorption of 'extrinsic factor', later defined as vitamin B₁₂. It remained for investigators to discover the causes of the gastric atrophy and intrinsic factor deficiency.

The development of new methods and their application to patients with suspected or proven B₁₂ deficiency have indicated several groups of patients in whom vitamin B₁₂ deficiency may be attributed to impaired secretion of intrinsic factor.

Classical pernicious anaemia occurs most frequently in middle-aged or elderly subjects who become progressively paler but suffer minimal discomfort apart from ill-defined weakness. The disease may be recognized finally by the above criteria alone or by the patient reporting because of an acute associated disease such as trauma, infection, or bleeding. At this stage the anaemia may be severe

and this will greatly worsen any associated disease. Moreover crippling subacute combined degeneration of the cord may be close at hand.

There are three other groups of patients with pernicious anaemia or pre-pernicious anaemia due to reduced or absent secretion of intrinsic factor. Although they have a different method of presentation, they may well be closely linked with the classical group discussed above.

First there is a rare juvenile group in whom a genetic abnormality causes depleted production of intrinsic factor and resulting megaloblastic anaemia in the absence of gastric atrophy (Reisner, Wolff, McKay, and Doyle, 1951; Mollin, Baker, and Doniach, 1955; Harris-Jones, Swan, and Tudhope, 1957; Clement, Nichol, and Welch, 1961).

Secondly there is a group of subjects, of widely varying ages, in whom there is a strong genetic background of pernicious anaemia (Askey, 1940). The members of this group, which was identified by family studies, have achlorhydria, atrophy of the gastric mucosa, and latent or overt pernicious anaemia (Callender and Denborough, 1957; Callender and Spray, 1962).

Finally there is the third group described in this paper: a group of elderly subjects, mostly women, who may have chronic flatulent dyspepsia or epigastric pain, and experience, perhaps prematurely, the decline of advancing years, particularly muscular weakness, loss of energy, loss of memory, mental depression, and paraesthesiae—tingling, numbness in the limbs, and occasional aches. The cerebral manifestations of vitamin B₁₂ deficiency have been well described by Holmes (1956).

For the purposes of the present study 30 patients were selected as fulfilling the following criteria: A histamine test meal showed achlorhydria or hypochlorhydria; gastric biopsy showed moderate to severe gastric atrophy with varying degrees of cellular infiltration, particularly with plasma cells and lymphocytes; none were suffering from overt pernicious anaemia, peptic ulcer, cancer, or alcoholism with liver disease; finally none had been subjected to an operation of the stomach.

There were seven females to one male, a ratio similar to that found in cases of chronic gastritis described by Doig and Wood (1952). These authors also found that the average age of onset of symptoms of chronic gastritis was 44 years: the average age at the beginning of the present study was 56 years. The present study continued for a mean period of nine years, serum vitamin B₁₂ levels being observed for a mean period of four years. The finding of histamine-fast achlorhydria throughout in 21 patients, at the end of the study in six, and hypochlorhydria in the remainder indicated complete or partial atrophy of

the secreting cells of the gastric mucosa (Wood, Doig, Motteram, Weiden, and Moore, 1949b; Joske *et al.*, 1955). Indeed gastric biopsy revealed atrophy of the acid- and pepsinogen-secreting cells: in the majority this was pronounced. The individual variation in the atrophy over the years was not considerable, but there was a trend towards increasing atrophy, particularly in eight patients.

There was variation from year to year in the cellular infiltration with plasma cells and lymphocytes, half the patients maintaining considerable infiltration throughout. In time those showing increasing atrophy and diminishing cellular infiltration would fall into the group of 'gastric atrophy' as defined by Motterham (1951), complete or near complete atrophy of the secreting cells with minimal cell infiltration and intestinal metaplasia of the epithelium. It was of interest that gastric atrophy was present at the end of this study in four patients. Gastric atrophy is seen in the majority of patients with classical overt pernicious anaemia (Doig and Wood, 1950; Motterham, 1951; Joske *et al.*, 1955; Wood and Taft, 1958).

All the patients had moderate to pronounced atrophy of the acid- and pepsinogen-secreting cells in the gastric mucosa: however, those with pronounced atrophy did not have significantly lower levels of serum vitamin B₁₂ than those with less atrophy.

The study of the serum levels of vitamin B₁₂ in the 30 patients showed fluctuations with a downward trend over the years which could be attributed to a progressive fall in the intrinsic factor secretion, impaired absorption of vitamin B₁₂, and a gradual depletion of the stores of vitamin B₁₂ in the liver.

The artificial removal of the source of the intrinsic factor by total gastrectomy has revealed that the mechanism for storing vitamin B₁₂ in the liver is efficient and this delays the appearance of pernicious anaemia for two to five years (Deller and Witts, 1962; Ungar and Cowling, 1962). If the depletion of intrinsic factor production be slow and incomplete, then the development of pre-pernicious anaemia, latent pernicious anaemia, and overt pernicious anaemia could be expected to be slow. Indeed it would appear that most persons suffering from chronic atrophic gastritis, with reduced production of intrinsic factor, retain stores of vitamin B₁₂ adequate for the term of their natural life; they do not develop overt pernicious anaemia, for the serum vitamin B₁₂ level remains in the normal range or falls no further than the pre-pernicious anaemia range. In this regard it is of interest that abnormal Schilling tests were obtained in two patients whose vitamin B₁₂ levels remained in the pre-pernicious anaemia range and in one in the normal range.

In the present study seven patients had vitamin B₁₂ levels in the pernicious anaemia range, 18 in the pre-pernicious anaemia range, and five in the normal range. Although none of the seven in the pernicious anaemia range developed florid pernicious anaemia or subacute combined degeneration of the cord, five had findings indicative of vitamin B₁₂ deficiency, including mild macrocytic anaemia, macronormoblasts in the bone marrow, and paraesthesiae or other changes in the central nervous system probably due to vitamin B₁₂ deficiency.

The reason why pronounced vitamin B₁₂ deficiency may be present for many months without overt changes in the peripheral blood or frank megaloblastic changes in the bone marrow has been ascribed to adequate folic acid intake or lack of some precipitating factor (Mollin and Ross, 1953 and 1954; Harrison, Booth, and Mollin, 1956; Callender and Spray, 1962).

Since Reizenstein (1959) found that the calculated biliary excretion of the radioactive label of cobalt-labelled (Co⁵⁶ or Co⁵⁸) vitamin B₁₂ in human subjects was greater than the daily faecal excretion, he postulated the existence of an enterohepatic circulation of vitamin B₁₂. Thus reabsorption in the intestine of vitamin B₁₂ from the bile could partly account for the apparently prolonged storage of vitamin B₁₂ in the liver. The intestinal reabsorption of biliary vitamin B₁₂ in gastrectomized rats is dependent on intrinsic factor (Gräsbeck, Runeberg, and Simons, 1959), so that interruption of the enterohepatic circulation of vitamin B₁₂ might aggravate vitamin B₁₂ deficiency in patients in whom production of intrinsic factor is impaired. This possibility was not investigated in the present study.

That this vitamin B₁₂ deficiency was due, at least in part, to depleted production of intrinsic factor was shown by the Schilling tests. The test was abnormal in six of the seven patients with serum vitamin B₁₂ levels in the pernicious anaemia range, in two of the 17 with levels in the pre-pernicious anaemia range, and in one of four with levels in the normal range. Moreover, when the Schilling test was repeated with intrinsic factor in nine patients who had abnormal Schilling tests without intrinsic factor, there was a rise to the normal range in eight, thus showing that deficient secretion of intrinsic factor was the cause, at least in part, of the vitamin B₁₂ deficiency. The remaining patient gave evidence of intestinal malabsorption.

It may well be that diet plays a part in this group (Deller, Germar, and Witts, 1961): minor degrees of deficient secretion of intrinsic factor may require a vitamin B₁₂ intake in the food well above the low level of the normal range quoted by Darby and his

colleagues (1958). A dietary history, considered to be reliable, was obtained in 23 of the patients, and the intake of vitamin B₁₂ was assessed as being within the normal limits in all. However, in five patients it was estimated as being in the range 6 to 10 μg . per ml., a low level in the normal range. Two of these patients had levels of serum vitamin B₁₂ in the pernicious anaemia range.

Genetic factors as a cause of gastritis were not explored by family studies. However, family histories were obtained from all patients and these did not provide good evidence for a genetic factor: two stated that there had been possible pernicious anaemia in an elderly parent and one had a sister with proven chronic gastritis, but no pernicious anaemia.

The cause of the atrophic gastritis is unknown. However it is of interest that, of the 30 patients studied, five suffered from a disease which could possibly be caused by an autoimmune process: two had chronic thyroiditis shown by biopsy and high titre of thyroid antibodies; one had a moderately high titre of thyroid antibodies but normal thyroid biopsy, low-grade hepatitis, and chronic ulcerative glossitis responding to steroid therapy but not to vitamin B₁₂ therapy; and three had rheumatoid arthritis.

In view of the recent finding by Irvine *et al.* (1962) and by Taylor, Roitt, Doniach, Couchman, and Shapland (1962) that in cases of classical pernicious anaemia there is a high percentage with high antibody titre to gastric mucosa determined by the autoimmune complement-fixation test and to thyroid by the tanned red cell haemagglutination test, it is of interest that Dr. Ian Mackay of our Unit found that six of our patients (28 tested) had antibodies to gastric mucosa, seven had antibodies to thyroid, and none had antibodies to liver or kidney.

These findings and those of Irvine and his colleagues (1962) call for a wider investigation of the part which may be played by autoimmune disease in the production of atrophic gastritis. Dr. Mackay reports his methods and findings on page 23.

The present study supports the view previously held by the authors (Wood *et al.*, 1960) and by others (Siurala *et al.*, 1960) that there is a group of elderly subjects who should be considered to be possible candidates for minor vitamin B₁₂ deficiency but who rarely develop classical pernicious anaemia. The members of this group are elderly and women predominate. Many have suffered from flatulent dyspepsia for many years and then, after the age of 50, they may experience minor symptoms of vitamin B₁₂ deficiency, particularly minor macrocytic anaemia, paraesthesiae, and mental and physical weakness. A poor diet and a strong family history of

pernicious anaemia are not necessary accompaniments. Autoimmune disease of the gastric mucosa is a possible cause in some and may be associated with similar lesions elsewhere in the body.

When a patient is suspected of being in this elderly group with pre-pernicious anaemia or latent pernicious anaemia, a serum vitamin B₁₂ assay is the most informative test. However, the present biological assay is difficult to perform, time consuming, and expensive. It remains for investigators to provide a less elaborate method of assay, readily available to physicians. This would ensure more efficient diagnosis and more rational therapy. Perhaps some of the mental and physical burdens of advancing age would be removed, much to the delight of the patient.

SUMMARY

Twenty-one women and nine men (mean age 56 years) with chronic atrophic gastritis on gastric biopsy and depleted acid secretion were studied over a mean period of nine years, with special reference to the progress of the gastritis, serum vitamin B₁₂ levels, and abnormalities in the blood and nervous system.

Serial gastric biopsies showed that the atrophy of acid and pepsinogen-secreting cells remained unchanged or increased, and infiltration of the tunica propria with plasma cells and lymphocytes persisted.

The serum vitamin B₁₂ levels fluctuated, but in the majority there was a downward trend. Analysis of the lowest levels showed that seven patients were in the 'pernicious anaemia' range, 18 in the 'pre-pernicious anaemia' range, and five in the normal range. The Schilling test proved varying degrees of impaired absorption of vitamin B₁₂, particularly in the first group.

There were varying changes in the central nervous system which were difficult to separate from the aging process. No patient developed severe subacute combined degeneration of the spinal cord.

No patient developed classical pernicious anaemia as shown by peripheral blood and bone marrow examinations. Minor degrees of anaemia and macrocytosis were encountered.

Serological tests showed antibodies to gastric mucosa in six patients and to thyroid in seven.

The study emphasizes that there is a group of elderly persons who suffer chronic atrophic gastritis and resulting vitamin B₁₂ deficiency. This causes distressing symptoms which could be relieved by treatment with vitamin B₁₂. Even if untreated, persons in this group rarely develop severe pernicious anaemia or subacute combined degeneration of the cord.

Our sincere thanks are due to Dr. S. Weiden for the biochemical tests, Dr. Ian Mackay for the serological studies, Sister I. Langford for her skill with the patients, Mrs. A. Krupinska for the vitamin B₁₂ estimations, and Miss G. Jessep for the nutrition survey. We are deeply grateful for the help given by Dr. E. G. Robertson and other members of the medical staff of the Royal Melbourne Hospital. Mr. E. Matthaei of the University of Melbourne prepared the photomicrographs.

REFERENCES

- Askey, J. M. (1940). Prevention of pernicious anemia: recognition of the latent stage in relatives. *Ann. intern. Med.*, **14**, 593-607.
- Callender, S. T., and Denborough, M. A. (1957). A family study of pernicious anaemia. *Brit. J. Haemat.*, **3**, 88-106.
- , and Spray, G. H. (1962). Latent pernicious anaemia. *Ibid.*, **8**, 230-240.
- Castle, W. B., Townsend, W. C., Heath, C. W., and Strauss, M. B. (1929). Observations on the etiological relationship of achylia gastrica to pernicious anemia. Part 1. *Amer. J. med. Sci.*, **178**, 748-764.
- Clement, D. H., Nichol, C. A., and Welch, A. D. (1961). A case of juvenile pernicious anemia: study of the effects of folic acid and vitamin B₁₂. *Blood*, **17**, 618-631.
- Cowling, D. C., and Mackay, I. R. (1959). Serum vitamin B₁₂ levels in liver disease. *Med. J. Aust.*, **2**, 558-562.
- Crosby, W. H., and Kugler, H. W. (1957). Intraluminal biopsy of the small intestine. *Amer. J. dig. Dis.*, **2**, 236-241.
- Darby, W. J., Bridgforth, E. B., Le Brocqy, J., Clark, S. L., Jr., de Oliveira, J. D., Kevany, J., McGanity, W. J., and Perez, C. (1958). Vitamin B₁₂ requirement of adult man. *Amer. J. Med.*, **25**, 726-732.
- Deller, D. J., Germar, H., and Witts, L. J. (1961). Effect of food on absorption of radioactive vitamin B₁₂. *Lancet*, **1**, 574-577.
- , and Witts, L. J. (1962). Changes in the blood after partial gastrectomy with special reference to vitamin B₁₂. Part 1. *Quart. J. Med.*, **31**, 71-78.
- Doig, R. K., and Wood, I. J. (1950). Gastric biopsy in pernicious anaemia. *Med. J. Aust.*, **2**, 565-568.
- , — (1952). Gastritis: a study of 112 cases diagnosed by gastric biopsy. *Ibid.*, **1**, 593-600.
- Fenwick, S. (1870). On atrophy of the stomach. *Lancet*, **2**, 78-80.
- Gräsbeck, R., Runeberg, L., and Simons, K. (1959). Intrinsic factor and radiovitamin B₁₂ excretion in rats. *Acta physiol. scand.*, **47**, 370-374.
- Harris-Jones, J. N., Swan, H. T., and Tudhope, G. R. (1957). Pernicious anemia without gastric atrophy and in the presence of free hydrochloric acid; report of a case. *Blood*, **12**, 461-468.
- Harrison, R. J., Booth, C. C., and Mollin, D. L. (1956). Vitamin B₁₂ deficiency due to defective diet. *Lancet*, **1**, 727-728.
- Holmes, J. M. (1956). Cerebral manifestations of Vitamin B₁₂ deficiency. *Brit. med. J.*, **2**, 1394-1398.
- Hutner, S. H., Bach, M. K., and Ross, G. I. M. (1956). A sugar-containing basal medium for vitamin B₁₂-assay with *Euglena*: application to body fluids. *J. Protozool.*, **3**, 101-112.
- Irvine, W. J., Davies, S. H., Delamore, I. W., and Williams, A. W. (1962). Immunological relationship between pernicious anaemia and thyroid disease. *Brit. med. J.*, **2**, 454-456.
- Joske, R. A., Finckh, E. S., and Wood, I. J. (1955). Gastric biopsy: a study of 1,000 consecutive successful gastric biopsies. *Quart. J. Med.*, **24**, 269-294.
- Kay, A. W. (1953). Effect of large doses of histamine on gastric secretion of HCl: an augmented histamine test. *Brit. med. J.*, **2**, 77-80.
- Mackay, I. R. (1964). Autoimmune serological studies in chronic gastritis and pernicious anaemia. *Gut*, **5**, 23.
- , and Wood, I. J. (1962). Lupoid hepatitis: a comparison of 22 cases with other types of chronic liver disease. *Quart. J. Med.*, **31**, 485-507.
- Mollin, D. L., Baker, S. J., and Doniach, I. (1955). Addisonian pernicious anaemia without gastric atrophy in a young man. *Brit. J. Haemat.*, **1**, 278-290.
- , and Ross, G. I. M. (1953). Serum vitamin B₁₂ concentrations in patients with megaloblastic anaemia after treatment with vitamin B₁₂, folic acid, or folinic acid. *Brit. med. J.*, **2**, 640-645.

- Mollin, D. L., and Ross, G. I. M. (1954). Vitamin B₁₂ deficiency in the megaloblastic anaemias. *Proc. roy. Soc. Med.*, **47**, 428-431.
- Motteram, R. (1951). A biopsy study of chronic gastritis and gastric atrophy. *J. Path. Bact.*, **63**, 389-394.
- Ralston, M., Wood, I. J., and Hughes, A. (1960). Small-bowel biopsy with the suction biopsy tube. *Aust. Ann. Med.*, **9**, 103-110.
- Reisner, E. H., Jr., Wolf, J. A., McKay, R. J., Jr., and Doyle, E. F. (1951). Juvenile pernicious anemia. *Pediatrics*, **8**, 88-106.
- Reizenstein, P. G. (1959). Excretion, enterohepatic circulation, and retention of radiovitamin B₁₂ in pernicious anemia and in controls. *Proc. Soc. exp. Biol. (N.Y.)*, **101**, 703-707.
- Robertson, E. G., Wood, I. J., and Joske, R. A. (1955). Gastric atrophy with subsequent pernicious anaemia and pronounced subacute combined degeneration of the cord. *Lancet*, **2**, 69-71.
- Ross, G. I. M. (1952). Vitamin B₁₂ assay in body fluids using *Euglena gracilis*. *J. clin. Path.*, **5**, 250-256.
- Schilling, R. F. (1953). Intrinsic factor studies. II. The effect of gastric juice on the urinary excretion of radioactivity after the oral administration of radioactive vitamin B₁₂. *J. Lab. clin. Med.*, **42**, 860-866.
- Shiner, M. (1956). Jejunal-biopsy tube. *Lancet*, **1**, 85.
- Siurala, M., Erämaa, E., and Nyberg, W. (1960). Pernicious anemia and atrophic gastritis. *Acta. med. scand.*, **166**, 213-223.
- Spray, G. H., and Witts, L. J. (1958). Results of three years' experience with microbiological assay of vitamin B₁₂ in serum. *Brit. med. J.*, **1**, 295-298.
- Taylor, K. B., Roitt, I. M., Doniach, D., Couchman, K. G., and Shapland, C. (1962). Autoimmune phenomena in pernicious anaemia; gastric antibodies. *Ibid.*, **2**, 1347-1352.
- Ungar, B., and Cowling, D. C. (1962). Vitamin B₁₂ studies after gastrectomy. *Med. J. Aust.*, **2**, 861-867.
- Williams, E. D., and Doniach, I. (1962). The post-mortem incidence of focal thyroiditis. *J. Path. Bact.*, **83**, 255-264.
- Wood, I. J., Doig, R. K., Motteram, R., and Hughes, A. (1949a). Gastric biopsy: report on 55 biopsies using a new flexible gastric biopsy tube. *Lancet*, **1**, 18-21.
- , —, —, Weiden, S., and Moore, A. (1949b). The relationship between the secretions of the gastric mucosa and its morphology as shown by biopsy specimens. *Gastroenterology*, **12**, 949-958.
- , and Taft, L. I. (1958). *Diffuse Lesions of the Stomach*. Arnold, London.
- , Cowling, D. C., Ungar, B., and Gray, A. (1960). Serum vitamin B₁₂ levels in chronic atrophic gastritis. *Aust. Ann. Med.*, **9**, 309-317.