

Effect of vagotomy upon the small intestine¹

J. BEJAR, S. A. BROITMAN, AND N. ZAMCHECK

From the Gastrointestinal Research Laboratory, Mallory Institute of Pathology Foundation, the Second and Fourth (Harvard) Medical Services, Boston City Hospital, the Department of Medicine, Harvard Medical School, and the Departments of Microbiology and Pathology, Boston University School of Medicine, Boston, Mass., U.S.A.

Abdominal vagotomy with various drainage procedures, widely used in the surgical treatment of peptic ulcer, may be followed by weight loss, intermittent diarrhoea, and steatorrhoea (Butler and Eastham, 1965; Everson, Hutchings, Eisen, and Witanowski, 1957; Golding, Mendoza, Aiello, Fierst, Salomon, and Enquist, 1965; Tucker, Barnett, and Goodrich, 1964). Following section of the vagus nerve in the dog, steatorrhoea and histological and enzymatic abnormalities of the small intestinal mucosa were observed (Ballinger, Iida, Aponte, Wirts, and Goldstein, 1964). In man, barium meal studies revealed dilatation, delayed motility, and flocculation in the small intestine (Isaac, Ottoman, and Weinberg, 1950). Although gallbladder functions have been studied in post-

vagotomy diarrhoea in man (Rudick and Hutchison, 1965), the role of the small intestine in the development of these complications has not been elucidated. Accordingly, the effects of abdominal vagotomy upon the villus architecture and mitotic activity of the crypts of the small intestinal mucosa were studied and correlated with xylose and fat absorption.

MATERIALS AND METHODS

Six patients with duodenal or marginal ulcers were studied. All underwent bilateral vagotomy and subsequently had some diarrhoea and weight loss (Table I). Five patients with gastric ulcer without diarrhoea served as controls. Biopsies were obtained with the Carey capsule (positioned at the jejunum under fluoroscopic control) preoperatively (six patients), three weeks postoperatively (six patients), and six weeks postoperatively (four patients). The tissue was examined in the fresh state under the dissecting microscope and sections stained with haematoxylin and eosin and alcian blue-P.A.S. The

¹This investigation was supported by grants from the National Institute of Arthritis and Metabolic Diseases (T1 AM-5320), the National Cancer Institute (CA-02090 and CA-04486), and the National Institute of General Medical Sciences (GM-09628), National Institutes of Health, Bethesda, Maryland.

TABLE I

CLINICAL DATA IN SIX PATIENTS BEFORE AND AFTER VAGOTOMY

Patient No.	Preoperative Diagnosis	Sex	Age	Operative Procedure	Postoperative Course During First Six Weeks
1	Duodenal ulcer and gastro-enterostomy	M	41	Abdominal vagotomy	Epigastric fullness, watery diarrhoea, weight loss (10 lb.)
2	Marginal ulcer and gastro-duodenostomy	F	38	Thoracic vagotomy	Epigastric fullness, watery diarrhoea, weight loss (5 lb.)
3	Duodenal ulcer	M	53	Abdominal vagotomy and pyloroplasty	Epigastric fullness, watery diarrhoea, weight loss (8 lb.)
4	Duodenal ulcer	M	62	Abdominal vagotomy and partial (50%) gastrectomy	Epigastric fullness, steatorrhoea (14 g.), weight loss (16 lb.)
5	Duodenal ulcer	M	42	Abdominal vagotomy and antrectomy	Epigastric fullness, watery diarrhoea, weight loss (8 lb.)
6	Duodenal ulcer	M	58	Abdominal vagotomy and partial (50%) gastrectomy	Epigastric fullness, watery diarrhoea, weight loss (15 lb.)

following morphological findings were evaluated: architecture, height, and invaginations of villi; depths of crypts; integrity of the brush border; height, appearance, and nuclear polarity of epithelial cells; and a quantitative estimate of the villus/crypt ratio was obtained by relating the length of the villus tip with the depth of five consecutive crypts. The mitotic index was estimated by counting the number of metaphase mitotic figures per 1,000 cells in consecutive crypts (Creamer, 1962). The 25 g. oral d-xylose test absorption study was performed. Urine and blood pentose were assayed by the method of Roe and Rice (1948). In three patients ingesting a 100 g. fat diet, 72-hour stool fat studies were done (Wolochow, Broitman, Williams, and Zamcheck, 1965).

RESULTS

MORPHOLOGICAL FINDINGS The appearance of all biopsy specimens in the fresh state seen under the dissecting microscope was normal before and after vagotomy. The dissecting microscopic appearance of the biopsies obtained from one patient (case 5) and representative of the others is shown in Figures 1, 2, and 3. Representative light micrographs are shown in Figures 4a and 4b. Specimens revealed finger-like with occasional leaf-like villi. In the four patients without previous surgery, the preoperative microscopic sections revealed normal villus architecture, and columnar cells with polarized nuclei and an intact brush border. There was a minimal infiltrate of round cells in the lamina propria. In two patients with marginal ulcer there was a moderate increase of eosinophils and round cells. Specimens obtained from five patients, three and six weeks postoperatively, were unchanged from the preoperative biopsies. One patient (case 4) who had a partial gastrectomy with vagotomy showed no change at three weeks postoperatively, but at six weeks a moderate infiltrate of round cells in the lamina propria was observed. The villus architecture and mucosa were unchanged.

VILLUS/CRYPT RATIO AND MITOTIC INDEX The villus/crypt ratio (Table II) and crypt cell mitoses per 1,000 crypt cells did not show significant differences before and after vagotomy.

The xylose absorption test was normal in four patients before and after bilateral vagotomy (Table III). Another patient with a previous gastroduodenostomy experienced severe diarrhoea following ingestion of xylose and had a low five-hour urinary xylose output (1.0 g.). In a repeat test the xylose solution was ingested over a one-hour period. Abdominal pain and diarrhoea were minimized and the five-hour urinary xylose output was normal (7.5 g.). Only one of the six patients exhibited a low urinary xylose output (1.4 g./5 hr. at three weeks

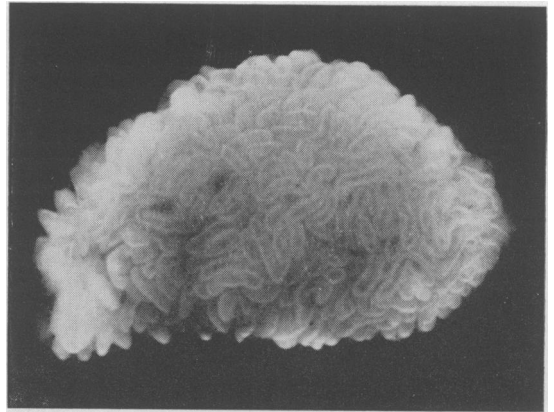


FIG. 1. Appearance of the jejunal biopsy under the dissecting microscope in case 5 before vagotomy revealing finger-like and leaf-like villi ($\times 20$).

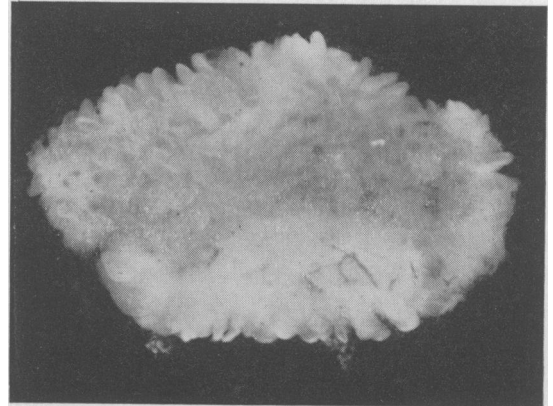


FIG. 2. Appearance of the jejunal biopsy under the dissecting microscope in case 5, three weeks after vagotomy, revealing finger-like and leaf-like villi ($\times 20$).

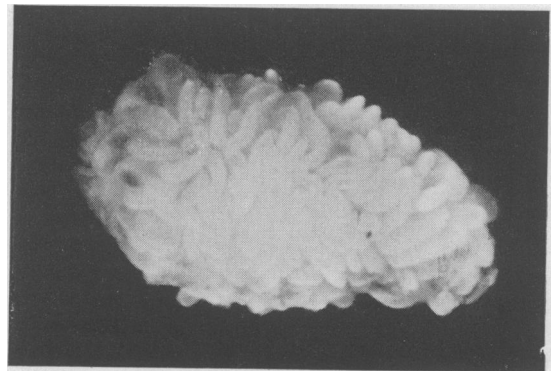


FIG. 3. Appearance of the jejunal biopsy under the dissecting microscope in case 5, six weeks after vagotomy, revealing finger-like and leaf-like villi ($\times 20$).

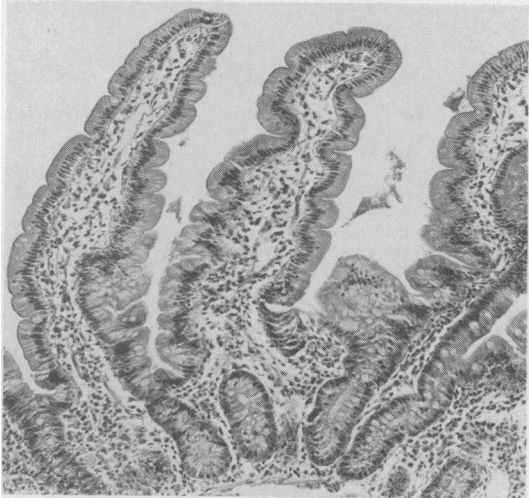
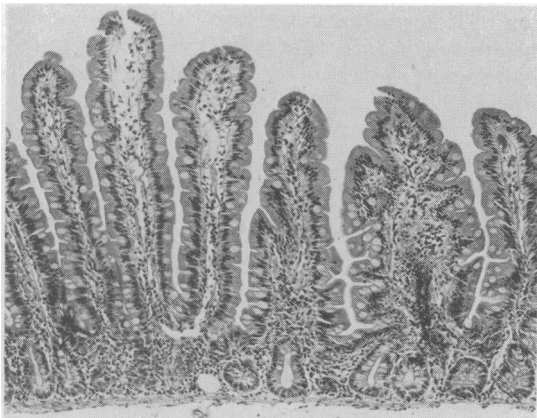


FIG. 4a. Histological section of the jejunal mucosa in case 6 (top) before abdominal vagotomy revealing finger-like villi with minimal infiltrate in the lamina propria ($\times 100$) and (bottom) after vagotomy ($\times 200$).

TABLE III

ORAL XYLOSE TEST
BEFORE AND AFTER VAGOTOMY

Patient No.	Preoperative Five-hour Urine (g.)	Postoperative (Three Weeks) Five-hour Urine (g.)	Postoperative (Six Weeks) Five-hour Urine (g.)
1	3.4	4.5	3.4
2	1.0	6.6	—
	7.5 ¹		
3	5.0	5.4	—
4	4.3	1.4	2.9
5	4.1	6.0	4.0
6	7.2	5.5	—

Mean \pm S.D.

Normal values 5.7 ± 1.5

¹Repeat test — xylose administered over one-hr. period.

and 2.9 g./5 hr. at six weeks postoperatively) which was coupled with steatorrhoea (14 g./24 hr.).

DISCUSSION

It is clear that monosaccharide malabsorption (as assessed by the oral D-xylose test) is not a tenable explanation for postvagotomy diarrhoea since normal values were obtained in all patients except one, who had previously undergone a partial gastrectomy. In this case, the diarrhoea and malabsorption have been ascribed to rapid gastric emptying, decreased absorbing surface, and rapid gastrointestinal transit (Benson, Culver, Ragland, Jones, Drummy, and Bougas, 1957).

It is clear from the present study that vagotomy alone had no significant effect on intestinal morphology as observed by light microscopy; postvagotomy diarrhoea observed in these patients could not be explained on morphological grounds.

The morphology of the small intestinal mucosa was not affected by bilateral vagotomy three and

TABLE II

SMALL BOWEL BIOPSY STUDIES IN SIX PATIENTS BEFORE AND AFTER VAGOTOMY

Patient No.	Villus Crypt Ratio			Mitoses 100 Crypt Cells		
	Before Vagotomy	After Vagotomy		Before Vagotomy	After Vagotomy	
		Three Weeks	Six Weeks		Three Weeks	Six Weeks
1	2.3:1.0	3.0:1.0	2.8:1.0	2.0	1.7	1.7
2	2.4:1.0	2.6:1.0	3.2:1.0	1.5	1.8	1.8
3	2.0:1.0	2.8:1.0		1.6	1.1	
4	2.0:1.0	2.3:1.0	2.0:1.0	1.0	2.0	1.1
5	3.6:1.0	2.0:1.0	3.0:1.0	1.5	1.4	1.6
6	3.7:1.0	4.1:1.0		2.1	1.5	
Mean \pm SD	2.6 \pm 0.7:1	2.8 \pm 0.7:1	2.8 \pm 0.4:1	1.6 \pm 0.4	1.6 \pm 0.2	1.6 \pm 0.3
5 Controls	Mean \pm SD	2.9 \pm 0.5:1		1.7 \pm 0.2		
	Range	2.3:1 — 4.0:1		1.4 — 2.0		

six weeks postoperatively. The moderate increase in infiltrate of round cells in the lamina propria noted in two patients with previous gastric surgery is consistent with jejunal histology observed in patients with partial gastrectomy (Baird and Dodge, 1957; Madanagopalan, Shiner, and Rowe, 1965; Scott, Williams, and Clark, 1964). It was of interest to observe an increase in the infiltrate of round cells in the lamina propria in one patient as early as six weeks following partial gastrectomy and vagotomy.

This study in man differs from observations made in the dog after extrinsic denervation or abdominal vagotomy. Ballinger, Christy, and Ashby (1962) observed protracted diarrhoea, weight loss, decreased fat absorption, alterations in the radiological appearance of the small intestine, and the full-thickness biopsies revealed villus atrophy following complete extrinsic denervation of the canine small intestine. Complete healing with restoration of normal villi was not evident until six months later. Ballinger *et al.* (1964) observed in dogs fat malabsorption, reduced enzymatic activity, and atrophy of the small intestinal mucosa after abdominal vagotomy. The histological changes appeared at the ninth day and were maximal at three weeks after vagotomy. At 21 weeks a return to normal mucosa with normal absorption was noted. It is not clear why the small intestinal mucosa of man responds to abdominal vagotomy differently.

The influence of the autonomic nervous system upon the cell turnover of crypts and maturation process of villous epithelial cells has not been adequately studied in man or in animals. Dupont, Biggers, and Sprinz (1965) observed that the jejunal epithelial cell renewal in the mouse was markedly reduced by immunosympathectomy with damage of the ganglionic cells and postganglionic fibres, indicating a direct interplay between the renewal of mucosal epithelial cells in the jejunum and the sympathetic nervous system. In the present study the mitotic activity of the crypt cells was not significantly altered following bilateral vagotomy, suggesting that the section of the parasympathetic preganglionic fibres has no apparent influence upon the epithelial cell turnover of the small intestinal mucosa in man.

SUMMARY

Vagotomy alone is not associated with malabsorp-

tion of either carbohydrates or fat. In man, unlike the dog and mouse, renewal of the mucosal epithelium does not appear to be directly influenced by the preganglionic parasympathetic nervous system. Postvagotomy diarrhoea in the patients studied was self-limiting within six weeks and was not associated with morphological changes in the small bowel as seen by light microscopy.

The authors are grateful for the assistance of Drs. Melvin P. Osborne, Frank Cagoliano, John Mahan, and Rudolph Vollman of the Fifth Surgical (Harvard) Service, Boston City Hospital, Boston, Mass.

REFERENCES

- Baird, I. Mc. L., and Dodge, O. G. (1957). Jejunal biopsy after partial gastrectomy. *Quart. J. Med.*, **26**, 393-400.
- Ballinger, W. F., II, Iida, J., Aponte, G. E., Wirts, C. W., and Goldstein, F. (1964). Structure and function of the canine small intestine following total abdominal vagotomy. *Surg. Gynec. Obstet.*, **118**, 1305-1311.
- , Christy, M. G., and Ashby, W. B. (1962). Autotransplantation of the small intestine; the effects of denervation. *Surgery*, **52**, 151-164.
- Benson, J. A., Jr., Culver, P. J., Ragland, S., Jones, C. M., Drumme, G. D., and Bougas, E. (1957). The D-xylose absorption test in malabsorption syndromes. *New Engl. J. Med.*, **256**, 335-339.
- Butler, T. J., and Eastham, R. D. (1965). Absorption studies after gastrojejunostomy with and without vagotomy. *Gut*, **6**, 69-72.
- Creamer, B. (1962). Dynamics of the mucosa of the small intestine in idiopathic steatorrhea. *Ibid.*, **3**, 295-300.
- Dupont, J. R., Biggers, D. C., and Sprinz, H. (1965). Intestinal renewal and immunosympathectomy. *Arch. Path.*, **80**, 357-362.
- Everson, T. C., Hutchings V. Z., Eisen, J., and Witanowski, M. F. (1957). A comparative evaluation of changes in weight after partial gastrectomy and after vagotomy with gastroenterostomy. *Ann. Surg.*, **145**, 223-229.
- Golding, M. R., Mendoza, M., Aiello, R. G., Fierst, S. M., Salomon, N. A., and Enquist, I. F. (1965). Effect of vagotomy and pyloroplasty on intestinal absorption. *Amer. J. Surg.*, **109**, 21-25.
- Isaac, F., Ottoman, R. E., and Weinberg, J. A. (1950). Roentgen studies of the upper gastrointestinal tract in vagotomy. *Amer. J. Roentgenol.*, **63**, 66-75.
- Madanagopalan, N., Shiner, M., and Rowe, B. (1965). Measurements of small intestinal mucosa obtained by peroral biopsy. *Amer. J. Med.*, **38**, 42-53.
- Roe, J. H., and Rice, E. W. (1948). A photometric method for the determination of free pentoses in animal tissues. *J. Biol. Chem.*, **173**, 507-512.
- Rudick, J., and Hutchison, J. S. F. (1965). Evaluation of vagotomy and biliary function by combined oral cholecystography and intravenous cholangiography. *Ann. Surg.*, **162**, 234-240.
- Scott, G. B., Williams, M. J., and Clark, C. G. (1964). Comparison of jejunal mucosa in post-gastrectomy states, idiopathic steatorrhea, and controls using the dissecting microscope and conventional histological methods. *Gut*, **5**, 553-562.
- Tucker, F. H., Barnett, W. O., and Goodrich, J. (1964). The influence of various degrees of vagotomy upon fat, carbohydrate, and protein absorption following pyloroplasty. *Surg. Gynec. Obstet.*, **118**, 1281-1285.
- Wolochow, D. A., Broitman, S. A., Williams, L. A., and Zamcheck, N. (1965). A rapid method for quantitative determination of fecal fat based on the principle of electrical capacitance. *J. Lab. clin. Med.*, **65**, 334-341.