

Postmortem survey of diverticular disease of the colon

L. E. HUGHES

From the Department of Surgery, University of Queensland, and the Princess Alexandra Hospital, Brisbane

Part I Diverticulosis and diverticulitis

Diverticular disease of the colon is a common cause of morbidity among many western races, and, being especially a disease of the elderly, is becoming a problem of increasing magnitude.

Abdominal symptoms are common in this age group, and in the absence of evidence of other disease, the finding of diverticula on x-ray examination is prone to lead to a diagnosis of 'diverticulitis'. The frequency with which such an association is a chance one, without causal relationship, would depend on the incidence of diverticulosis in the normal population.

It is probable that the present safety of colonic surgery is the major reason for a tendency to treat diverticular disease by resection at an early stage, for there has been little work reported on the natural history of the disease when treated conservatively to prove that routine surgical excision is justified. The work which has been reported suggests that the disease is not as inexorable in its progress to serious complications as much surgical literature implies (Bolt and Hughes, 1966; Horner, 1958).

Detailed studies of the pathology of diverticular disease are also surprisingly few, considering its importance as a cause of morbidity, while very little indeed is known of its aetiology. Deficiencies in knowledge of aetiology and basic pathology make rational treatment difficult. This, together with the tendency to frequent diagnosis and radical therapy, may readily lead to overtreatment.

This work has been carried out to determine the incidence of diverticula and associated pathology in Queensland, to attempt to assess the relationship of diverticula to symptoms, and to seek any evidence which may throw light on the aetiology of this condition.

MATERIALS AND METHODS

Colons were studied from 200 unselected necropsies at the Princess Alexandra Hospital, Brisbane, in two series

each of 100 consecutive colons, the first taken during winter and the second during summer. The colons in this series were fixed in the undistended state, and all personally examined 24 to 48 hours after fixation. The mesentery and associated fat was dissected from the left colon, and the bowel carefully examined from internal and external aspects for the presence of diverticula. In this way small diverticula 2 to 3 mm in diameter were readily found. The colon and pericolonic tissues were carefully examined for signs of recent or old infection, and sections were taken from such areas for histological study.

Among details routinely recorded during necropsies at this hospital are the presence or absence of gallstones, an assessment of the degree of atheroma of the aorta, and the thickness of the subcutaneous fat at the umbilicus. These details were taken from the postmortem records for correlation with the presence of diverticula. The clinical records of all patients were studied to determine the cause of death and the presence of coexistent disease, including hypertension, and the presence of bowel symptoms at the time of admission or as recorded in the past history.

INCIDENCE AND RESULTS

INCIDENCE OF DIVERTICULA IN THE COLON Diverticula were found in 90 of the 200 colons (Table I).

TABLE I
INCIDENCE OF DIVERTICULA OF COLON RELATED TO AGE AND SEX¹

Age Group	No. in Group	Diverticula (%)		
		Males	Females	Total
10-30	4	0	0	0
31-50	23	12	6	9
51-70	72	33	41	36
71+	101	60	54	56
Over 50	173	48	47	48
All ages	200	45	40	43

¹Solitary caecal diverticula excluded.

In five of these the caecum alone was involved. As this may be a distinct condition, these have been

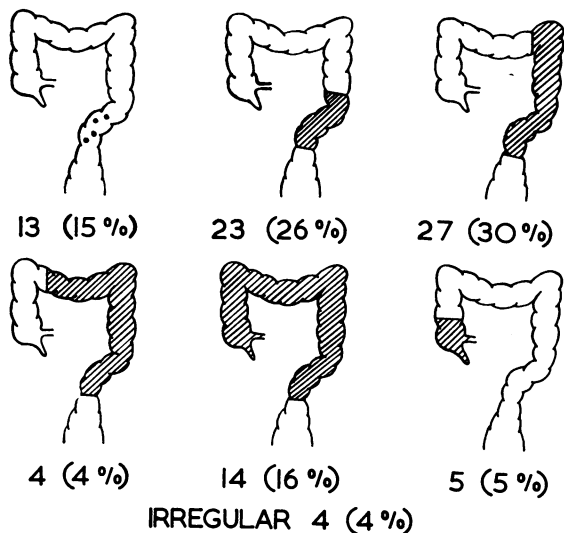


FIG. 1. Incidence of diverticula at necropsy. In 200 cases diverticula were present in 90.

excluded to give an overall incidence of 43% of colonic diverticula. Little difference was found in incidence between the two sexes.

The distribution of diverticula throughout the length of the colon is shown in Figure 1. Early diverticular disease, a group arbitrarily formed of those in whom less than five diverticula were present in the sigmoid colon, was found in 6.5% of the series or in 14% of those with diverticula. As in most reported series the sigmoid colon was involved in almost all cases (99%), there being only one case with diverticula elsewhere where the sigmoid colon was not affected, diverticula localized to the caecum being excluded. In this case there were two isolated diverticula, one each at the splenic and hepatic flexures. The remaining three cases, classified as 'irregular', showed diverticula of the right colon associated with sigmoid diverticula, the intervening bowel being unaffected.

The distribution of diverticula around the circumference of the bowel, in particular in the sigmoid colon, did not differ from that reported by other workers (Slack, 1962; Watt and Marcus, 1964).

CAECAI DIVERTICULA Diverticula involved the caecum in 24 cases. In 14 the caecum was involved in continuity with extensive diverticulosis of the rest of the colon.

In the other 10 cases, the caecum was involved more or less discontinuously, and the details of this group are set out in Table II. Five of the 10 cases were primary caecal diverticula in that they were not associated with other diverticula, and a further two cases were accompanied by early sigmoid diverticular disease only. It is probable that these two patients also are cases of true 'solitary' diverticula and have subsequently developed sigmoid diverticular disease; both were aged less than 65 years. The three cases associated with more extensive left-sided diverticular disease might be merely an extension of the general process, or might also be primary caecal disease with coincident but unrelated left-sided diverticular disease. The incidence of solitary caecal diverticula in this series, therefore, lies between 2.5 and 5% and is probably about 3.5%. Histologically all the diverticula were thin-walled, 'false' diverticula (Fig. 2). No example of the 'congenital' diverticulum containing all muscle coats in its wall was seen. In two cases more than one diverticulum was present in the caecum (Fig. 3). The diverticula varied from a few millimetres to 15 mm in diameter, and were randomly distributed around the caecum, occurring on both mesenteric and peritoneal aspects.

AGE The relationship between age and the extent of the disease is shown in Table III, where the median age of patients in each group is given. Cases of total colonic involvement occur at a later

TABLE II
CAECAI DIVERTICULA¹

Case	Age (yr)	Caecal Diverticula	Distance from Ileo-caecal Valve (cm)	Other Diverticula	Muscle Change in Sigmoid Colon
1	76	1	10	Left colon	Present
2	68	1	5	Nil	—
3	99	1	16	Nil	—
4	49	3	2.5	Sigmoid	Present
5	49	2	3,8	Nil	—
6	79	1	8	Left colon	Present
7	62	1	8	Sigmoid	—
8	70	1	8	Left colon	—
9	57	1	7.5	Nil	Present
10	64	1	15	Nil	Present

¹Excluding caecal involvement in continuity with diffuse colonic diverticula.

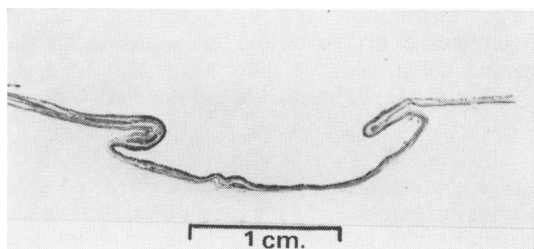


FIG. 2. Section of a large solitary diverticulum of the caecum of the 'false' type. (Scale: 1 division = 1 mm.)

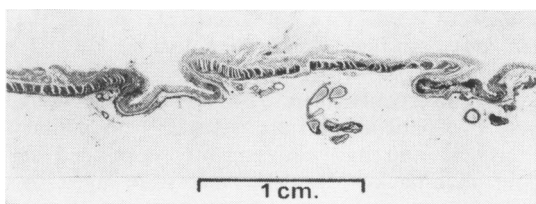


FIG. 3. A section of caecum showing two 'solitary' caecal diverticula. (Scale: 1 division = 1 mm.)

age than lesser degrees of affection. In fact no case of total colonic involvement was seen in this series under the age of 70 years, although caecal involvement in association with diverticula of the distal left colon was seen three times in patients under this age. Involvement of the caecum alone occurred in an earlier age group, as is typically found in clinical diverticulitis of this region.

TABLE III

DISTRIBUTION OF DIVERTICULA OF THE COLON RELATED TO AGE

Extent of Diverticula	No. in Group	Median Age of Patients
Sigmoid (less than five diverticula)	13	73
Sigmoid (more than five diverticula)	23	70
Left colon	35	74
Total colon	14	82
Caecum only	5	57

MORBID ANATOMY OF DIVERTICULOSIS OF THE COLON

The general pathological features of colonic diverticula have already been extensively described, but certain points warrant consideration in relation to this study. Diverticula varied in size from minute protrusions 1 to 2 mm in diameter to faecolith-containing diverticula as large as 7 cm in diameter. Diverticula in the sigmoid colon were frequently narrow-necked, as the result of muscular spasm

or thickening, whereas diverticula proximal to the sigmoid colon usually had wide necks. The combination of a wide neck and soft or liquid faeces probably accounts for the rarity of inflammatory disease proximal to the sigmoid. However, the converse is not always true. Some colons had large diverticula containing faecoliths which had obviously been *in situ* for a very long time yet showed no microscopic evidence of inflammation.

Jejunal diverticula of the typical multiple, mesenteric type are occasionally associated—perhaps by chance—with colonic diverticula. Ileal diverticula have been reported much less commonly. In two cases in this series, small (5 mm) false diverticula were situated just proximal to the ileo-caecal valve (no jejunal diverticula were present). The first case was noted towards the end of the series and until this time the small bowel had not been examined, so the incidence of terminal ileal diverticula associated with colonic diverticula could not be assessed. Spriggs and Marxer (1925), from their radiological studies, described these diverticula of the terminal ileum in association with colonic diverticula. Chronic periileal inflammatory disease is occasionally seen in this region and these diverticula may be a causative factor in this lesion.

EARLY DIVERTICULA A particular study was made of the histological findings in cases of very small and early diverticula. At this stage, when the diverticula are less than 2 mm in diameter, the diverticula move very easily in and out of the bowel through well demarcated defects in the muscle. Sections

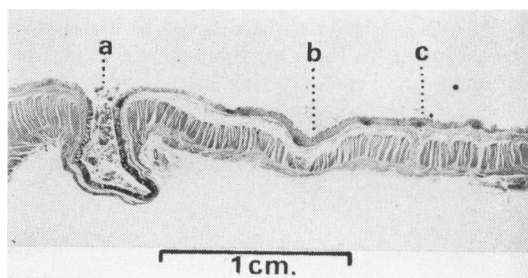


FIG. 4. Section of the sigmoid colon containing early diverticula: a, site of diverticulum through distinct defect in circular muscle; b, site of diverticulum showing an area of 'pressure atrophy' (mm scale); c, defect in circular muscle filled by loose connective tissue: potential defect for diverticular formation.

through this region have shown two appearances: (1) a clear-cut defect in the muscle filled by loose fibrous tissue (Fig. 4), usually containing a vessel of moderate size and representing a defect at the site

TABLE IV

INCIDENCE OF DIVERTICULA RELATED TO TOTAL LENGTH OF COLON¹
 Length of Colon (ft. in.)

	3	3 6	4	4 6	5	5 6	6
Number of cases	2	12	54	60	22	15	22
Diverticula present	50%	33%	28%	48%	41%	54%	45%

¹Thirteen colons excluded, due to length outside above limits, previous colectomy, or disorganization from carcinomatosis.

of penetration of the muscle wall by a small artery; (2) an area with an appearance of pressure atrophy (Fig. 4) with no evidence of an associated blood vessel.

RELATIONSHIP BETWEEN DIVERTICULOSIS AND ANATOMICAL AND PATHOLOGICAL CONDITIONS

LENGTH OF COLON The total length of the colon was measured in all cases and the relationship between length and diverticulosis is set out in Table IV. There is no correlation between these two factors.

OBESITY The subcutaneous fat at the umbilicus was measured routinely as an index of obesity. Patients dying of terminal carcinoma were excluded. A thickness of 20 mm was accepted from experience as being a reasonable dividing line between the obese and the lean. Forty-six per cent of 87 lean patients had diverticula, while the corresponding figure for the obese group was 49% of 86 patients.

GALLSTONES The incidence of gallstones in relation to the presence of diverticulosis was studied, and it was found that diverticula were present in 44% of patients with gallstones, as compared with an incidence of 46% among the 138 patients without gallstones. Of the 62 patients classified as having gallstones, stones were found at necropsy in 51, and the gall bladder had been removed in 11.

ATHEROMA OF THE ABDOMINAL AORTA AND HYPERTENSION An attempt was made to determine any association between diverticular disease and generalized vascular disease. It was not possible to assess the blood supply to the sigmoid colon because the inferior mesenteric artery was not available for examination. Instead two indirect indices were used, atheroma of the aorta and hypertensive vascular disease. The relationship between the incidence of diverticulosis and hypertension was studied by dividing the patients into three groups according to diastolic pressure: less than 100 mm, 100-120 mm, and greater than 120 mm of mercury. Patients whose condition at admission was likely to have

altered the blood pressure, as for example patients with myocardial infarction, were excluded. The incidence of diverticulosis in three groups was 44 out of 97 (45%), 17/38 (45%), and 12/32 (38%) respectively. These differences are not statistically significant. The degree of atheroma of the aorta was assessed subjectively by the pathologist who performed the necropsy, so that classification is subject to some degree of observer error. Atheroma of the aorta was assessed in four degrees, and a relationship with diverticulosis is shown in Table V.

TABLE V

DIVERTICULA OF THE COLON RELATED TO ATHEROMA OF THE ABDOMINAL AORTA

Degree of atheroma	0	+	++	+++
Number of cases	18	63	53	66
Percentage with diverticula	17	36	53	56

A distinct trend of an increasing incidence of diverticulosis with increasing atheroma of the aorta is seen ($\chi^2 = 38.67$ for linear trend in proportions, $P = < 0.001$). However, this figure must be considered with due regard to the possible observer error mentioned above and the relationship is complicated by the fact that atheroma of the aorta in this series also increased with age. It was not possible to determine the significance of the association with atheroma, for this may have reflected merely the increasing incidence of both conditions with age.

DIVERTICULITIS A careful search for macroscopic evidence of recent or old inflammation was made in all cases. In 10 cases, a localized area of thickening and fibrosis was present in the colon. In all cases, the changes were associated with the presence of diverticular disease and with muscle thickening of the sigmoid colon. The actual area of inflammatory fibrosis was in the sigmoid colon in nine cases and in the transverse colon in the remaining one. In this case a subhepatic pericolic abscess had formed which eventually caused the patient's death. None of the patients with diverticula of the caecum showed any evidence of inflammation in this region.

Three patients were males and seven females and

the median age of the group was 75 years. Diverticula were confined to the sigmoid colon in one case, but extended proximal to the sigmoid colon in the other nine cases. In six of the cases definite histological confirmation was obtained and some fibrosis of the mesentery was present in the other four. There was remarkably little correlation between the finding of pathological evidence of inflammatory disease and a history of relevant symptoms before death. Six of these patients denied abdominal symptoms or previous episodes of bowel disease; four patients gave a history of diverticular disease; in two, diverticulitis had been the cause of death; and one patient had been treated for acute diverticulitis 12 months earlier and had suffered mild bowel symptoms since that occasion. The remaining patient had never suffered any bowel symptoms, but 12 months before death a barium enema done during investigation of an upper abdominal mass (liver) showed complete obstruction of the rectosigmoid junction due to diverticular disease. Two cases particularly illustrate this lack of correlation between pathological findings and clinical symptoms.

A patient not included in the group of 10 discussed above had been admitted to hospital with attacks of 'acute diverticulitis' 10 months and one month before death but at necropsy no macroscopic or microscopic evidence of inflammation could be found.

A 61-year-old woman was in hospital for the

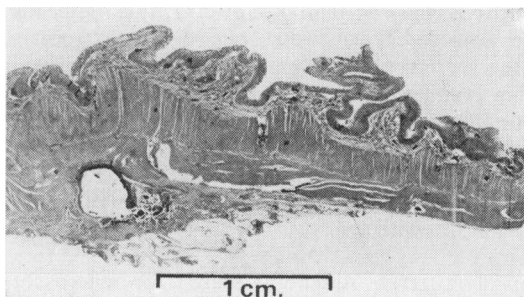


FIG. 5. Section of sigmoid colon showing a pericolic abscess. No bowel symptoms before death (mm scale).

last few months of her life and complained of no bowel symptoms whatsoever. At necropsy an area of fibrosis was obvious in the sigmoid mesentery, and section showed a pericolic abscess (Fig. 5) and other areas of acute inflammation.

SYMPTOMS OF BOWEL DISEASE Patients were questioned on admission for their terminal illness about the presence of bowel symptoms. The presence or absence of bowel symptoms was specifically recorded in 149 cases. The remaining 51 were mainly unable to give a history for such reasons as admission for a cerebrovascular accident, gross senility, and being moribund on admission. The presence of symptoms related to the colon is set out in Table VI. The group

TABLE VI

BOWEL SYMPTOMS IN 200 CASES COMING TO NECROPSY

No specific bowel symptoms	127
Mild recurrent symptoms	15
Clinical diverticulitis	4
Ulcerative colitis	2
Carcinoma	1
Unable to give an adequate history	51

of 'mild recurrent symptoms' consisted mainly of intermittent pain in the left iliac fossa and irregularity of bowel habit. Constipation as an isolated longstanding symptom was ignored. The relationship of symptoms to the presence of diverticula and muscle thickening (Hughes, 1968a and b) is set out in Table VII.

DISCUSSION

INCIDENCE OF DIVERTICULA The quoted incidence of diverticulosis varies widely with different sources. There is a definite racial variation, the condition being rare in many underdeveloped countries, and virtually unknown as a cause of inflammatory disease. Here the main protective factor appears to be a high-residue diet, although genetic differences and the lack of certain stresses of civilization may play a part. Even in countries as close to each other as Finland and Sweden the incidence varies considerably, Swedes suffering from this condition three times as commonly as do the Finns (Kohler, 1963).

TABLE VII

RELATIONSHIP OF BOWEL SYMPTOMS TO DIVERTICULAR DISEASE

Symptom	No. of Cases	Diverticula Present	Muscle Thickening Present	Inflammatory Disease Present
Mild recurrent bowel symptoms	15	7 (47%)	4 (27%)	0
Those of clinical diverticulitis	4	4 (100%)	3 (75%)	3
All patients	200	90 (45%)	73 (36%)	10

In Anglo-Saxon countries, the incidence of diverticulosis is usually quoted as being in the region of 5% to 10% of adults submitted to barium enema. From time to time higher figures have been quoted, but these have not been given the emphasis they should deserve from the fact that high incidences are more likely to be closer to the truth than low ones. Barium studies are not altogether satisfactory, as diverticula frequently fail to fill on a barium enema, presumably from obstruction of the necks as a result of spasm. Follow-through studies are more reliable, but still underestimate the incidence because small diverticula do not retain their contents for long periods. With the exception of a recent careful study on normal subjects by Manousos, Truelove, and Lumsden (1967) where the incidence found was 7.6% under the age of 60 years and 35% above this age, radiological series preselect those patients with bowel symptoms and are therefore unreliable guides to the incidence among the general population.

As diverticulitis is a relatively rare cause of death (500 cases a year in Great Britain) and diverticular disease has not been shown to be associated with any common cause of admission to hospital or death other than diverticulitis, studies on consecutive necropsies should give the most accurate results. Such studies should be prospective, for careful examination is needed to detect early diverticula or those obscured by mesenteric fat. Large retrospective series nearly always underestimate the incidence for this reason, and Dearlove (1954), examining the case records of 7,000 Australian necropsies, found an incidence ranging from nil at 40 years of age to 7% at 70 years compared with figures of 9% and 56% in this series. The high incidence of diverticula reported in this series is neither unique nor a recent finding. For instance, Mourgues (1913) found diverticula in 30% of 100 consecutive necropsies on aged subjects, and Bumm (1933) found an incidence of 33% in 920 necropsies in cases over the age of 50. However, in a more recent necropsy series, Slack (1962) found diverticula in only 18% of a consecutive series of 141 necropsies in London. As diverticula were completely confined to the sigmoid colon in 88% of Slack's cases, compared with 41% in this series, it is interesting to speculate that his series may have been from a population with an unusually low incidence of diverticula for a western country.

CAECAI DIVERTICULA The incidence of caecal involvement of 12% of all patients and 25% of patients with colonic diverticula is higher than in most other series, though not many accurate studies have been undertaken. Ochsner and Bagen

(1935) found diverticula of the right colon in only 2% of 151 cases of diverticulosis, and Williams (1960) found caecal involvement in only 14 of 290 barium enemata showing colonic diverticulosis. It is obvious from this study that caecal diverticula will be frequently found if looked for carefully. It seems likely that the five cases of caecal diverticula associated with left-sided diverticula and a long unaffected area of colon in between were primary caecal diverticula with unrelated involvement of the sigmoid, although it is possible that the distensibility of the caecum from back pressure makes this site particularly prone to develop diverticula from the excessive muscular activity of the sigmoid known to be associated with the development of diverticula in this site.

If approximately 3.5% of the population have caecal diverticula, the development of diverticulitis must be a complication in relatively few of them, for clinical caecal diverticulitis is a rare condition. None of the 24 cases presented here gave a history of an inflammatory mass in the caecum, and no case showed any evidence of old fibrosis.

It is interesting that no case of caecal diverticulum had muscle in its wall apart from the muscularis mucosa. Most textbooks state that caecal diverticula are congenital with all muscular coats in their walls. When quoted references are consulted, they frequently state that microscopic examination showed all muscle coats to be present, but I have not so far been able to find a histological picture of this state. Williams (1960) reported 10 cases of acute diverticulitis of the caecum and ascending colon, and all of these were of the pulsion type. It may be that the 'congenital' caecal diverticulum is largely a pathological myth. Edwards (1954) has pointed out that hypertrophy of the muscularis mucosa has previously resulted in jejunal diverticula being considered to be congenital.

AETIOLOGY OF DIVERTICULA Seventy years of speculation on the aetiology of diverticulosis and diverticulitis has given rise to a great variety of opinions, but we still know little about the actual cause. In this regard there are presumably two factors, first, some cause for raised intracolonic pressure, and secondly, for the individual diverticulum, a locus minoris resistentiae in the bowel wall. The work of Painter (1964) and Arfwidsson (1964) has shown that patients with diverticulosis, and possibly its precursor state, develop pressures higher than those of normal subjects, when under certain influences, such as in the postprandial period, and in response to certain drugs, of which morphia is an example.

They have shown that the segmenting action of the sigmoid colon is so great in these patients that short sections of the colon may be completely isolated from the bowel lumen above and below, when contraction will give rise to very high pressures within that area. But much is still not known. The site of maximum muscle abnormality is such (Hughes, 1969c) that in many cases catheters inserted through a sigmoidoscope must lie below this level, so that pressures at a higher level may be quite different. Again large diverticula are frequently found in the proximal colon, where the bowel shows no tendency to narrow and increased muscular thickening is not seen. Although barium enema studies show that considerable segmenting activity can occur at this level, our knowledge of the degree of pressures developed proximal to the region within reach of the sigmoidoscope is meagre. However, there is little doubt that proximal to the sigmoid small arteries perforating the muscle of the bowel wall constitute the weakness through which the diverticula protrude, for the diverticula in this part of the bowel regularly follow the pattern of the macroscopic blood vessels.

Whereas workers studying sigmoid pressures have reported fairly uniform results, the same is not true of the significance of perforating blood vessels in this region. Diverticula usually appear in two rows along the lateral aspect of the bowel, at sites corresponding to the perforating arteries. Slack (1960) and Arfwidsson (1964) believed that the relationship was a causal one (as did Hamilton Drummond in 1917), but Fleischner, Ming, and Henken (1964) could not confirm this. The two types of early lesions seen in this series (Fig. 5) suggest that more than one mechanism may exist governing the local development of diverticula. These two findings, distinct gaps in the circular muscle and areas of 'pressure atrophy', have previously been noted (Buie, 1939), and the presence of two mechanisms would help to reconcile the opposing views put forward by different workers.

RELATIONSHIP OF DIVERTICULA TO OTHER POSSIBLE AETIOLOGICAL FACTORS A great many conditions have been suggested at different times as important in the aetiology of diverticulosis, with different workers giving contrary opinions. Obesity is a typical example, as shown in the statement by Hamilton Drummond (1917): 'Klebs, who investigated the condition, emphasized that the sacculi occurred in fat people. Hanseman pointed out that in his cases they occurred in thin people. Other observers have stated that they are most commonly found in people who were at one time well nourished and had now become thin.' Drummond himself could

verify none of these statements, and that is the situation in this series, where diverticula bore no relation to obesity as measured by subcutaneous fat thickness at the umbilicus.

Sir Arthur Keith suggested in 1910 that the basic abnormality in this condition was excessive spasm of the longitudinal muscle of the colon, presumably most marked in the sigmoid region. No relationship between overall length of the colon and diverticular disease was found in this series, but this may not reflect changes localized to the sigmoid colon. Ulcerative colitis is a condition in which the colon becomes grossly shortened as a result of muscle thickening and spasm, but does not bear any resemblance to the colon in diverticular disease.

Saint's triad of gallstones, hiatus hernia, and diverticulosis has recently been questioned as a clinical entity. Horner (1958) showed an association between hernia and diverticulosis. In this series the combination of gallstones and diverticular disease was examined, and the relationship was no greater than might be expected to exist on chance association of two very common conditions.

An attempt was made to assess ischaemia as a possible aetiological factor. There are several reasons for putting this forward as a hypothesis. Ischaemia is becoming increasingly recognized as a cause of bowel pathology, both in acute and chronic forms. However, a considerable deprivation of blood—at least temporarily—is required to produce the syndromes currently recognized. On the other hand, a much lesser degree of anoxia might interfere with neuromuscular function without producing histologically recognizable damage. The inferior mesenteric artery is commonly affected by atherosclerotic disease, and the portion of the colon maximally involved with diverticulosis is midway between the collateral sources of middle colic and middle rectal vessels. Assessment of arterial deprivation in an attempt to investigate these speculations is not easy. Unfortunately, it was not possible to examine the inferior mesenteric artery in all cases. Instead, a subjective assessment of aortic atheroma, together with the diastolic pressure, had to be accepted as general evidence of vascular disease. Hypertension showed no association, but there was a relationship between aortic atheroma and diverticulosis. There is no proof that this relationship was causal, and in fact it is more likely that both were linked with age. This speculation regarding ischaemia must await further experimental work.

EFFECT OF AGE Aging alone requires consideration as a possible initiating cause of the disease or as a factor in its progression. There is no doubt that age

is of significance in any discussion of diverticulosis, for the disease is rare in the young adult and the incidence increases progressively with age. However, extension of the disease is not so closely related to increasing age as might be expected. Table IV shows that the median age of patients with minimal diverticular disease is essentially similar to that with involvement of the whole left colon. However, total colonic involvement occurred on the average a decade later than did lesser degrees. Horner (1958) showed that only 28% of cases showed progression over a period of five or more years; the other two-thirds remained static. These findings suggest that there may be some other factor which is more potent than aging alone in determining progression of the disease.

DIVERTICULITIS The finding in this series that 12% of patients with diverticula show some evidence of recent or old diverticulitis indicates that some degree of inflammatory change in association with diverticular disease is obviously very common; presumably pathological changes occur more frequently than would be suspected on clinical grounds. Inflammatory complications in this series showed a strong association with extensive diverticulosis (diverticula extended beyond the sigmoid colon in nine of 10 cases). Of even more interest than the high incidence is the lack of correlation with symptoms. Apart from the two patients in whom perforated diverticulitis was the cause of death, symptoms were mild, six complaining of none, and only one having suffered a clinical attack of diverticulitis. It is likely that some of these patients may have forgotten minor symptoms, but unlikely that all would have forgotten a major attack of diverticulitis. Furthermore, one patient (Fig. 5) had severe inflammation of the sigmoid colon with no bowel symptoms at all. In fact it does not seem possible to predict the pathological findings in most cases of diverticular disease from the clinical and radiological features.

This lack of correlation between pathological findings and symptoms suggests that mild inflammatory changes found in resected specimens should not be used to justify operation. It would seem that operation should be recommended only because of severe clinical symptoms, and when the natural course of the disease would suggest that a particular patient is likely to have more trouble in the future (Bolt and Hughes, 1966).

SUMMARY AND CONCLUSIONS

A study of diverticulosis and diverticulitis in 200 colons examined at necropsy has been made to

build a picture of the disease in the general population. It was found that diverticulosis is very common in the normal elderly population, with an incidence of 43% of all necropsies, and 48% in necropsies on patients aged 50 years or more. The extent and site of diverticula were similar to those of other surveys.

Analysis of various possible aetiological agents gave largely negative results. No association was found between the presence of diverticula and obesity, length of the colon, gallstones, or hypertension. There was a positive relationship between diverticulosis and increasing degrees of atheroma of the aorta, possibly associated with the effect of age on both conditions. A study of early diverticula revealed two types of local change in the circular muscle wall of the bowel, suggesting that there may be more than one mechanism giving rise to diverticula.

Evidence of recent or old inflammatory disease was found in 12% of all cases with diverticula, mostly in cases with extensive diverticulosis. In two cases, diverticulitis had been the cause of death, and in other cases its presence was not anticipated from the clinical picture.

Caecal diverticula were present in 12% of the colons, somewhat more than half being associated with diverticula elsewhere in the colon. All cases were of the 'false', thin-walled variety, and no evidence of recent or old inflammation was found in any case. The concept that most solitary diverticula are of the 'true' congenital type is questioned.

An analysis was made of bowel symptoms recorded in the history of the terminal illness. These included two groups of symptoms; those which might be expected to accompany frank inflammatory disease, and the less obtrusive intermittent symptoms commonly associated with uncomplicated diverticular disease. In both cases the correlation between clinical symptoms and pathological findings was poor. It is important to realize that diverticulosis is such a common condition among the general population after middle age that any apparent association between symptoms and the presence of diverticula should be considered to be a chance one until proved otherwise. Evidence of clinical or pathological disease of considerable magnitude should be required before extensive therapeutic measures are considered justified.

REFERENCES

- Arfwidsson, S. (1964). Pathogenesis of multiple diverticula of the sigmoid colon in diverticular disease. *Acta chir. scand.*, suppl. 342.
- Bolt, D. E., and Hughes, L. E. (1966). Diverticulitis: A follow up of 100 cases. *Brit. med. J.*, 1, 1205-1209.
- Buie, L. A. (1939). Diverticula of the colon. *New Engl. J. Med.*, 221, 593-598.

- Bumm, R. (1933). Die Divertikel des Dickdarms und ihre Komplikationem. *Langenbecks Arch. klin. Chir.*, 174, 14.
- Dearlove, T. P. (1954). Diverticulitis and diverticulosis, with a report on a rare complication. *Med. J. Aust.*, 1, 470-475.
- Drummond, H. (1917). Sacculi of the large intestine, with special reference to their relations to the blood vessels of the bowel wall. *Brit. J. Surg.*, 4, 407-413.
- Edwards, H. C. (1954). Intestinal diverticulosis and diverticulitis. *Ann. roy. Coll. Surg.*, 14, 371-388.
- Fleischner, F. G., Ming, S. C., and Henken, E. M. (1964). Revised concepts on diverticular disease of the colon. I. Diverticulosis. *Radiology*, 83, 859-872.
- Horner, J. L. (1958). The natural history of diverticulosis of the colon. *Amer. J. dig. Dis.*, 3, 343-350.
- Hughes (1969b). The relationship of bowel symptoms to diverticular disease. To be published.
- (1969c). The muscle abnormality of diverticular disease of the sigmoid colon. A functional study using the polysiloxane foam enema. To be published.
- Keith, A. (1910). A demonstration on diverticula of the alimentary tract of congenital or of obscure origin. *Brit. med. J.*, 1, 376-380.
- Kohler, (1963). R. The incidence of colonic diverticulosis in Finland and Sweden. *Acta chir. scand.*, 126, 148-155.
- Manousos, O. N., Truelove, S. C., and Lumsden, K. (1967). Prevalence of colonic diverticulosis in the general population of Oxford area. *Brit. med. J.*, 3, 762-763.
- Mourgues, P. de (1913). Des Diverticules acquis du gros intestin. Thesis, Lyons.
- Ochsner, H. C., and Bargaen, J. A. (1935). Diverticulosis of the large intestine. *Ann. intern. Med.*, 9, 282-296.
- Painter, N. S. (1964). The aetiology of diverticulosis of the colon with special reference to the action of certain drugs on the behaviour of the colon. *Ann. roy. Coll. Surg.*, 34, 98-119.
- Slack, W. W. (1960). Diverticula of the colon and their relation to the muscle layers and blood vessels. *Gastroenterology*, 39, 708-712.
- , (1962). The anatomy, pathology and some clinical features of diverticulitis of the colon. *Brit. J. Surg.*, 50, 185-190.
- Spriggs, E. I., and Marxer, O. A. (1925). Intestinal diverticula. *Quart. J. med.*, 19, 1-34.
- Watt, J., and Marcus, R. (1964). The pathology of diverticulosis of the anti-mesenteric intertaenial area of the pelvic colon. *J. Path. Bact.*, 88, 97-105.
- Williams, K. L. (1960). Acute solitary ulcers and acute diverticulitis of the caecum and ascending colon. *Brit. J. Surg.*, 47, 351-358.

Part II The muscular abnormality in the sigmoid colon

Diverticula of the sigmoid colon and associated diverticulitis were described clearly and fully in the early years of this century (Telling and Gruner, 1917). It was noted at this time that thickening of the bowel wall and of the longitudinal muscle in particular was a common finding (Keith, 1910). Since that time, the muscular thickening has often been noted, and shown clearly in illustrations of pathological specimens, but does not seem to have been considered as an element of the disease in its own right. Rather, it has been looked on as a subsidiary and unimportant aspect in comparison with the inflammatory complications. This perhaps stems from the view of Spriggs and Marxer (1925), derived from radiological studies, that the muscle abnormality was more a part of the prediverticular state than part of the established disease. An insight into the true significance of the muscle disorder was first given by Morson, who pointed out that many cases subjected to resection for supposed diverticulitis showed no evidence of inflammatory disease, but that a very considerable degree of muscular thickening was present in all the specimens (Morson, 1963). This paper has stimulated interest in the muscular aspect of diverticular disease, and comprehensive descriptions of radiological appearances (Williams, 1963, 1967b) and of manometric studies (Painter, 1964; Arfwidsson, 1964) have appeared. In these papers, the muscle change often present in the sigmoid colon has been discussed at considerable length, taking as a starting point the advanced stage of the condition which

is characteristic and readily recognized. However, no detailed analysis has been made in that this muscle abnormality has not been defined, and no accurate description has been made of its frequency, extent, and relation to diverticular pathology or clinical symptoms.

An investigation of colons at necropsy has been carried out in an attempt to remedy some of these deficiencies, and in particular, to put forward a tentative basis for further research. The main purpose of the work described in this paper has been to obtain an overall view of this abnormality in the general population, and to assess its relationship to diverticular disease as a whole. Studies on a smaller experimental group have been used to give a more detailed histological picture of the abnormality and its spatial relationship to the sigmoid colon and associated diverticula, and this work is to be reported elsewhere. The introduction of sigmoid myotomy (Reilly, 1966), for the relief of symptoms which have been ascribed to this muscular thickening, has added significance to studies of this type.

MATERIALS AND METHODS

Two hundred unselected consecutive colons were studied at necropsy as set out previously (Hughes, 1968). The colons were examined carefully in a fixed, undistended state. Details of diverticula, muscular thickening, mucosal folds, and evidence of associated pathology were recorded. Sections were taken for histological study of all colons showing any macroscopic abnormality.