

Giant duodenal ulcer

K. LUMSDEN, J. C. MACLARNON, AND J. DAWSON

From the Radcliffe Infirmary, Oxford, and the Royal Hampshire County Hospital, Winchester

SUMMARY Twenty-five cases of benign giant duodenal ulcer have been studied. In every case a barium meal examination showed an ulcer crater with a radiographic diameter of at least 2 centimetres.

Abdominal pain was the commonest symptom but less than half of the patients had had pain characteristic of chronic peptic ulcer. Haemorrhage from the ulcer occurred in a large majority of them.

The radiological appearances are described, and it has been shown that the giant ulcer may be missed through being mistaken for the duodenal cap or else misdiagnosed.

It appears that the death rate in this condition has been falling but it is still high. The management of patients with giant ulcers is discussed.

Most of the ulcer craters found in the duodenum on barium meal examination have a diameter in the radiographs of less than 1 cm. Occasionally, craters with a diameter between 1 and 2 cm are found. Craters with a diameter of 2 cm or more are not at all common.

In the literature, Brdiczka (1931) is given credit for the first description of exceptionally large duodenal ulcers, but it was Knutsson (1932) who first applied the term 'giant' to them. Since then the term 'giant duodenal ulcer' has been used in different ways. Bullock and Snyder (1952) suggested that it should be restricted to benign ulcers greater than 2.5 cm and that if the diagnosis was based upon radiographs or there had been no histological examination, there should be a three-year follow up to avoid including carcinomas of the duodenum. In later reports, measurement of the ulcer craters in radiographs has been the usual basis for selection of cases, but while the craters in some reports have had a diameter of more than 2.5 cm, in others they have measured 2 cm or more.

Brdiczka (1931) reported three cases of giant ulcer and Knutsson (1932) four cases, in one of which the ulcer was carcinomatous. After these

early articles there was a long period in which the literature consisted almost entirely of single case reports. Then the literature was reviewed and eight cases were added by Stainton and Growdon (1957), and another review with the addition of six further cases was contributed by Dawson (1958). These and many other authors have emphasized that the large ulcer crater is liable to be missed in barium meal examinations because it is mistaken for a normal, or perhaps slightly deformed, duodenal cap.

Further reviews have been published by Mistilis, Wiot, and Nedelman (1963), who found 34 previously reported cases and tabulated the clinical findings in 14 cases of their own, by Lemaire, Blanchon, Emerit, Yean, Tavernier, and Giorgi (1966), who added two cases to 40 found in the literature, and by Kirsh and Brendel (1968). The last named authors accepted as proven cases of benign giant duodenal ulcer only those in which the crater was at least 2 cm in size, an x-ray examination had preceded a surgical operation or necropsy, and there was proof that the lesion was benign. Of 53 cases in the literature, 42 were accepted as proven, and a correct radiological diagnosis had been made in only 24. Recently, Rosenquist (1969) has reported

nine cases of giant ulcer with a diameter more than 2.5 cm.

A study of 25 cases of benign giant duodenal ulcer is reported in the present paper.

The Present Series

Fourteen of the cases we report were seen in the United Oxford Hospitals during the period 1960 to 1969. The remaining 11 were seen in Winchester during the period 1955 to 1969.

In every case there was a barium meal examination showing an ulcer crater with one diameter measuring at least 2 cm on the radiographs. Confirmation of the presence of a benign duodenal ulcer by operation or necropsy was obtained in 18 cases. In most of the remainder there was a favourable response to medical treatment, and this was accompanied in two of them by radiological healing of the ulcer.

Clinical features of the cases are shown in Table I, and the treatment, outcome, and operative or postmortem findings are summarized in Table II.

CASE REPORTS

Case 1

A young man, aged 23 years, had been having upper abdominal pain for four years. At first it had come in attacks but more recently it had been continuous and radiating to the back. Some months after the onset of pain he had a haematemesis which responded to medical treatment. A barium-meal examination was interpreted as showing a giant ulcer in the duodenal bulb (Fig. 1) and a course of medical treatment was started. Substantial symptomatic improvement followed and the ulcer became smaller but further radiographs taken three months after the first examination showed that the ulcer had not healed. Vagotomy and gastroenterostomy were performed with a satisfactory result.

Case 2

A 67-year-old man was admitted to hospital as an emergency with diarrhoea containing altered blood. He had had diarrhoea for six weeks and had noticed blood in the stools on one occasion three months previously. The Hb was 58%, and it was thought that he had bled from the large

Case No.	Sex	Age (yr)	Ulcer Crater in Radiographs		Length of History	Symptoms		
			Site	Size (cm)		Pain	Haemorrhage	Other
<i>Oxford cases</i>								
1	M	23	Bulb	4.0	5 years	Radiating to back	Haematemesis	
2	M	67	Bulb	3.5	3 years	Dyspepsia	Melaena and haematemesis	Diarrhoea
3	M	58	Bulb	3.0	21 years	Radiating to back	None	Vomiting, weight loss
4	M	66	Postbulbar	2.5	4 years	Epigastric	Occult blood in stools ++	
5	M	39	Postbulbar	3.0	3 years	Right abdomen	Haematemesis	
6	M	75	Bulb	3.5	3 years	Radiating to back	Passage of fresh blood per rectum	
7	M	13	Bulb	3.5	8 months	Epigastric pain and heartburn	Haematemesis	Anorexia, diarrhoea
8	M	67	Postbulbar	4.5	4 months	Radiating to back	Melaena and haematemesis	Anorexia, vomiting, weight loss
9	M	65	Bulb	4.0	5 years	Epigastric and in both iliac fossae	Melaena	Vomiting, weight loss
10	M	84	Bulb	3.0	2 years	Epigastric	Melaena	Diarrhoea
11	M	82	Bulb	2.0	4 months	Dyspepsia	Coffee-grounds vomit	Vomiting, weight loss
12	M	66	Bulb	2.0	Several weeks	General abdominal	None	Vomiting, weight loss
13	M	69	Bulb	2.0	3 months	Epigastric	Haematemesis and melaena	Weight loss
14	F	83	Bulb	3.5	45 years	Epigastric	Coffee-grounds vomit	Vomiting
<i>Winchester cases</i>								
15	M	76	Bulb	2.5	1 month	General abdominal	None	Vomiting
16	F	68	Bulb	2	2 years	Left iliac fossa	Haematemesis	Vomiting
17	M	55	Bulb	2.5	Several years	Radiating to back	None	
18	M	50	Bulb	2.5	2 weeks	Epigastric	None	
19	F	42	Bulb	2	4 years	Left abdomen	None	Diarrhoea, weight loss
20	M	50	Bulb	2	10 years	Epigastric	Melaena	Vomiting
21	M	62	Bulb	2	12 years	Epigastric	Anaemia (Hb 56%)	
22	M	70	Bulb	2.5	Few weeks	None admitted	Anaemia (Hb 40%)	Insomnia
23	M	85	Bulb	3	2 months	Abdominal colic	Melaena	Diarrhoea
24	F	67	Bulb	2.5	6 months	Right hypochondrium	None	Vomiting
25	F	61	Bulb	2	Many years	Epigastric	Melaena	Vomiting

Table I Clinical features of 25 patients with benign giant duodenal ulcers

Case No.	Treatment	Year of Operation	Outcome	Operative or Postmortem Findings
<i>Oxford cases</i>				
1	Vagotomy and gastrojejunostomy	1962	Survived	Very large ulcer with gross scarring
2	Polya gastrectomy	1960	Died 5 days later	Large ulcer invading pancreas
3	Vagotomy and gastrojejunostomy	1964	Alive 2½ years; well	Dense adhesions and scarring (duodenum not opened)
4	Vagotomy and Billroth I gastrectomy	1967	Alive 6 months; well	Large ulcer eroding thickened pancreas
5	Vagotomy and gastrojejunostomy	1966	Alive 3 years; well	No operation note available
6	Vagotomy and gastrojejunostomy	1964	Alive 3 years; frequent vomiting	Very large ulcer with gross deformity
7	Vagotomy and gastrojejunostomy	1964	Alive 3 years; well	Penetrating ulcer adherent to pancreas and liver
8	Vagotomy and pyloroplasty, and 3 months later Polya gastrectomy	1968	Survived	Huge ulcer eroding pancreas
9	Vagotomy and gastrojejunostomy	1969	Survived	Massive ulcer invading pancreas, and lesser curve gastric ulcer
10	Medical		Died after 8 months	Necropsy: large ulcer 1.5 cm from pylorus
11	Medical		Died after 3 months	Necropsy: large anterior ulcer with 1 cm perforation
12	Medical		Alive 6 months; improved	
13	Medical		Alive 6 months; well	
14	Medical		X-ray: ulcer healed Alive 3 months; well	
<i>Winchester cases</i>				
15	Gastrojejunostomy	1955	Died after 10 days	Necropsy: chronic ulcer (2 cm) on posterior wall of bulb
16	Polya gastrectomy	1955	Alive 2 months; well	Large duodenal ulcer
17	Polya gastrectomy	1957	Survived	Large penetrating ulcer on posterior wall
18	Polya gastrectomy	1959	Died 4th week after operation	Necropsy: subphrenic abscess and leaking duodenal stump
19	Polya gastrectomy	1960	Alive 3 months; well	Large ulcer invading pancreas
20	Polya gastrectomy	1960	Alive 4 months; well	Large posterior ulcer invading pancreas
21	Vagotomy and gastrojejunostomy	1968	Alive 6 months; well	Large duodenal ulcer
22	Medical		Alive 6 years; well	
23	Medical		Alive 1 month ¹	
24	Medical		Alive 7 years; recurrent epigastric pain	
25	Medical		Alive 12 months; well X-ray: ulcer healed	

Table II Treatment, outcome, and operative findings in 25 patients with giant duodenal ulcers

¹Lost to follow up.

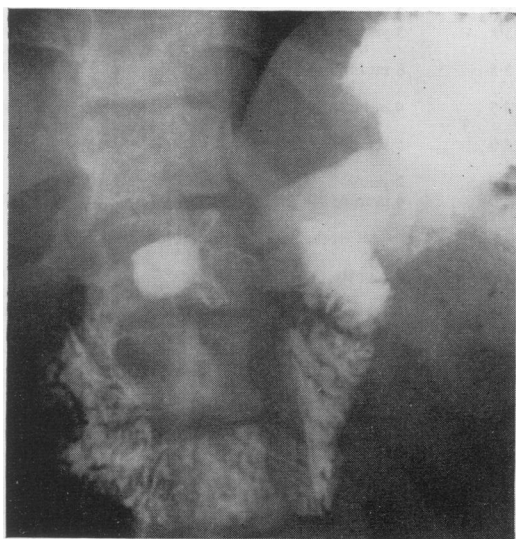

Fig. 1 Case 1: supine view showing a giant ulcer crater almost entirely replacing the bulb.

bowel. But after a blood transfusion he had a haematemesis, and then admitted to having had slight indigestion for about three years. A barium meal (Fig. 2) was reported as showing 'a grossly deformed cap containing apparent tumour—almost certainly blood clot and an ulcer crater'. Laparotomy revealed a large duodenal ulcer eroding the pancreas, with a bleeding vessel in its floor. Partial gastrectomy was carried out without removal of the ulcer, and there was difficulty in closing the duodenal stump. The patient died five days later.

Case 3

A man aged 58 years was admitted to hospital complaining of abdominal pain and vomiting. At the age of 37 years he had had a perforated duodenal ulcer treated by surgical repair, and thereafter he had been well for about 12 years. Then he had begun to have attacks of epigastric pain radiating to the back, and recently had been vomiting and had lost 1 stone in weight in six weeks. A barium meal was interpreted as

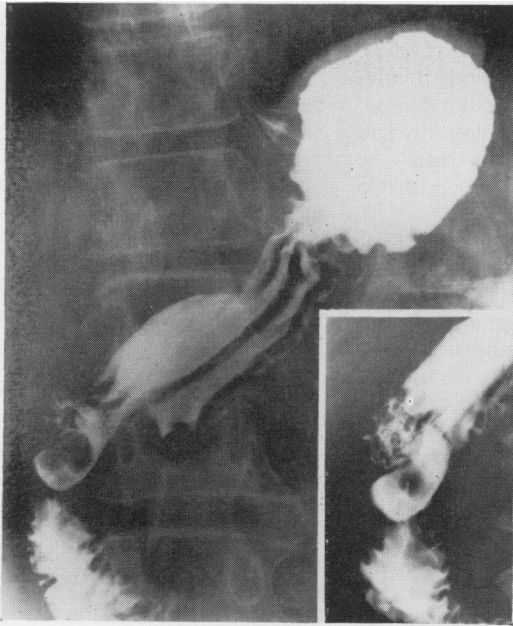


Fig. 2 Case 2: two supine views of a huge bulbar ulcer in which there is a filling defect probably caused by blood clot.

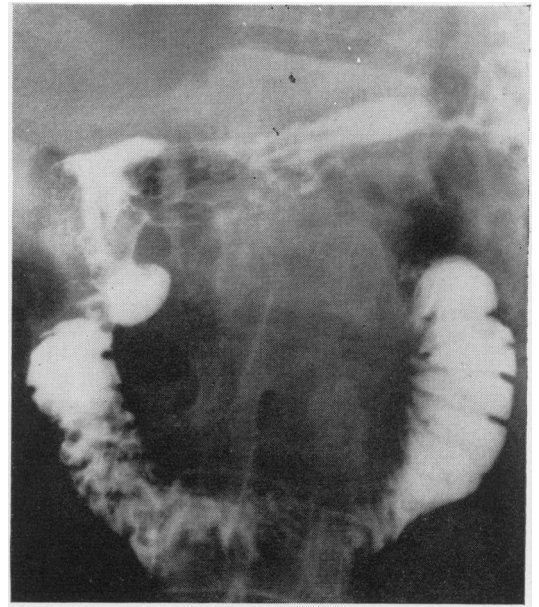


Fig. 4 Case 4. A large postbulbar ulcer which was found, at operation, to be eroding the pancreas.

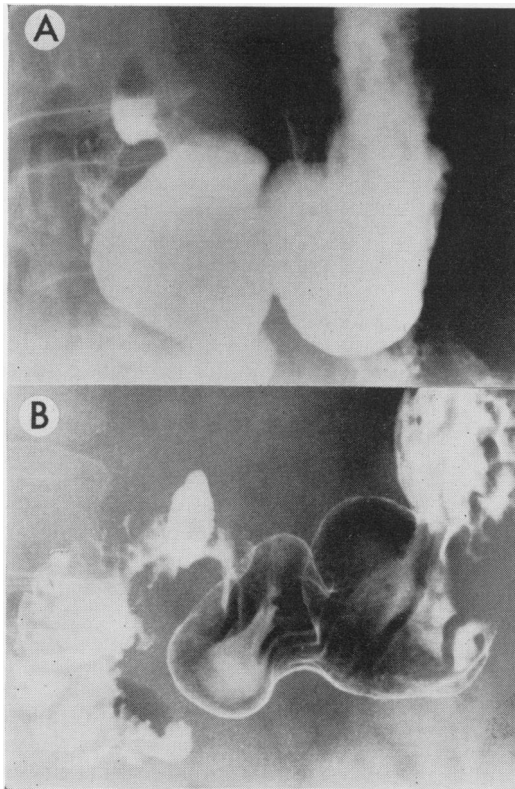


Fig. 3 Case 3. (A) Erect view showing an air-fluid level in a giant bulbar ulcer. (B) Supine view showing a "reversed-3" sign due to pancreatic swelling associated with the ulcer.

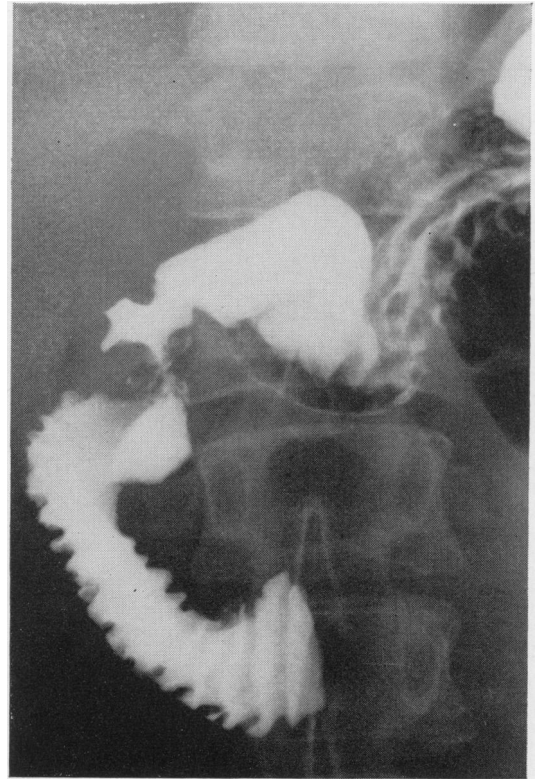


Fig. 5 Case 5. A giant postbulbar ulcer crater with a well-marked proximal constriction.

showing a very large ulcer in the duodenal bulb with swelling of the head of the pancreas (Fig. 3). At operation there were many adhesions involving the pylorus and first part of the duodenum, so the duodenum was not opened. Vagotomy and gastroenterostomy were performed and the patient remained well during a follow up of two and a half years.

Case 4

After emergency admission to hospital on account of upper abdominal pain, a publican aged 66 was found to be anaemic (Hb 53%) and to have a large amount of occult blood in his stools. For four years he had had attacks of epigastric pain which was worse on lying down, and had had two previous barium meals, neither of which had shown any definite duodenal lesion, though the report on the second mentioned the possibility of pancreatitis. A third barium meal revealed a large postbulbar duodenal ulcer (Fig. 4) and this was confirmed at operation. The ulcer was eroding the pancreas and there was thickening of the body as well as the head of this organ. Vagotomy and partial gastrectomy were performed, and the patient made a good recovery.

Case 5

A man aged 39 years was admitted after vomiting

about 1 pint of blood, and gave a history of pain in the right abdomen for three years. The pain was eased by meals and had at times been bad enough to take him off work. The Hb was 88%, a barium meal showed an abnormal proximal duodenum, and he was presumed to have bled from a duodenal ulcer. After rapid improvement with medical treatment he was discharged. But seven months later he was getting frequent bouts of pain and a repeat radiograph showed a postbulbar ulcer 3 cm diameter (Fig. 5). The patient was readmitted, and vagotomy and gastroenterostomy were performed. He made an uneventful recovery.

Case 6

A 75-year-old man was admitted to hospital after he had collapsed in the street and passed fresh blood per rectum. He had been having attacks of abdominal pain radiating round to the back for three years, but a cholecystogram had been normal and a barium meal had shown only a doubtful duodenal lesion, possibly a diverticulum. A further barium meal performed soon after his admission showed unusual appearances (Fig. 6), and the presence of a giant ulcer in a greatly dilated duodenal bulb seemed the most likely explanation. At operation the presence of a giant ulcer was confirmed, and vagotomy and gastroenterostomy were carried out. Frequent vomiting persisted during a three-year follow up.

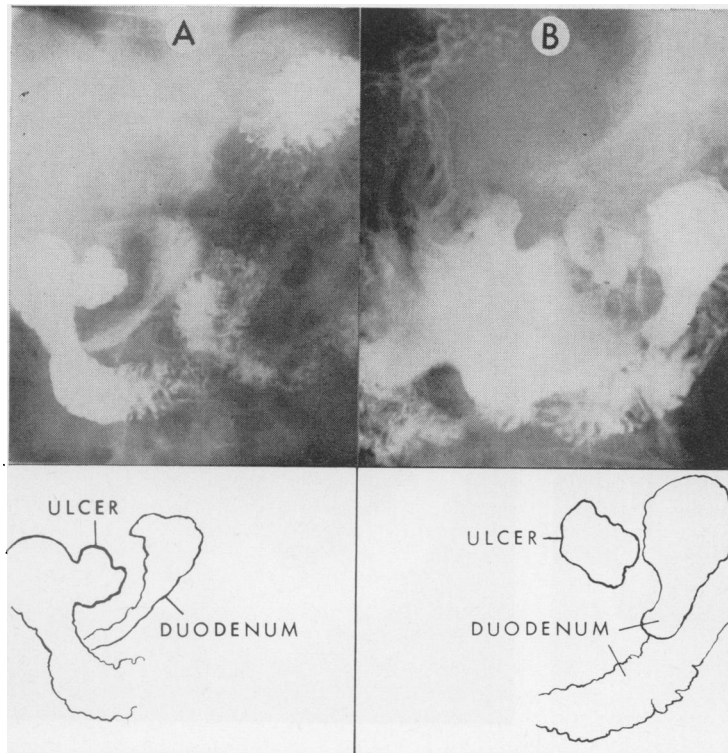


Fig. 6 Case 6. (A) Supine view of a large irregular ulcer crater surrounded by a wide radiolucent band in a megabulbus. (B) Prone view.

CLINICAL FEATURES

Twenty of our patients were male and five female. Their ages ranged from 13 to 85 years and the average age was 62 years.

Abdominal pain was the most common symptom but less than half of the patients had suffered from intermittent epigastric pain characteristic of chronic peptic ulcer. The pain in some of them was felt in the right hypochondrium and in five it radiated to the back, so that gallbladder disease and pancreatitis were considered as possible causes. The intensity of the pain was very variable, some patients having had very severe pain while others had experienced only slight indigestion.

The duration of symptoms varied from several weeks up to many years. In a few instances the presence of a duodenal ulcer had been discovered by radiology some time before the giant ulcer was found, and in two cases (3 and 14) there had been a previous perforation which had been treated by surgical repair.

Haemorrhage from the ulcer occurred at some stage in a majority of the patients. Some had melaena, some haematemesis, and some had both these symptoms. One passed fresh blood per rectum after collapsing in the street. Two others, who had not had overt haemorrhage, were anaemic. Vomiting and loss of weight were also frequent, and were so pronounced in a few

cases that a gastric neoplasm was suspected. Anorexia and diarrhoea were less common.

More than half the patients were ill enough at some stage to require urgent admission to hospital. The usual cause of the emergency was haemorrhage from the ulcer, and in three cases a surgical operation was performed for control of the haemorrhage. In one (case 11) the reason for admission was perforation of the ulcer.

RADIOLOGICAL APPEARANCES

The one cardinal sign of any duodenal ulcer is the shadow of the ulcer crater. In the case of giant ulcers, the crater, because of its large size, may be mistaken for the entire bulb, for a pseudodiverticulum of the bulb, or for a true duodenal diverticulum.

In any radiograph of such an ulcer the appearances depend on (1) the position of the patient, (2) the projection, and whether the ulcer is shown *en face* or *en profile*, (3) the relationship of the ulcer to anatomical structures such as the pylorus, and (4) whether an inflammatory mass is present.

The giant ulcer crater, as many authors have pointed out, remains remarkably constant in size and shape during a barium meal examination and is always associated with loss of mucosal pattern. It is often round or oval, but sometimes irregular. The long axis of an oval crater may run in the direction of the duodenal lumen or at right angles to it. The outline of the crater is usually sharp.

The crater does not contract as the duodenal bulb does, because it is a cavity with rigid walls, but barium may be drained out of it by changing the position of the patient. With the patient erect, a fluid level may be seen in it, and when the ulcer is posterior and the patient prone, it may appear mainly filled with air. There is a tendency for barium to be retained in it, and a late film, taken some hours after the examination, may show a residue of barium in the crater after the stomach has emptied.

Filling defects due to nodularity of the floor of the ulcer are a feature of some cases (Mistilis *et al*, 1963).

A constriction of the duodenal lumen distal to the crater is a common finding. The appearances proximal to the crater vary with the size of the crater and its relation to the pylorus. In some cases the pylorus is unaffected and the fornices of the bulb can be identified. In some the pylorus is involved and is patulous. In others there is a constriction proximal to the crater, involving the pylorus and part of the gastric antrum.

Postbulbar ulcers commonly have a proximal as well as a distal constriction. Some produce an oval shadow which is medial to the normal position of the second part of the duodenum and gives the impression of displacement of this part of the duodenum towards the ulcer.

Occasionally, in our experience, the large ulcer has a radiolucent band or collar round it, just as some gastric ulcers have.

In addition to the radiological signs already mentioned, there are others which are probably best regarded as signs of complications. There may be gastric retention and other signs of pyloric obstruction. There may be signs of perigastric adhesions, eg, the 'trapped air sign' (Lumsden and Pexman, 1968). There may be signs of pancreatic swelling such as the widening of the duodenal loop with a pressure defect on its medial aspect, or the 'reversed-3' sign. There may be dilatation of the duodenum due to compression of the third part by an inflamed and swollen mesentery. Among our cases there were examples of most of these.

DIFFERENTIAL DIAGNOSIS

As we have already mentioned, a giant duodenal ulcer may be missed because the crater is mistaken for a normal or slightly deformed duodenal cap. This error, which many authors admit having made, is particularly liable to occur when a large ulcer has completely destroyed the posterior wall of the bulb and is eroding into the pancreas (Dawson, 1958). A difficult examination, eg, of a patient who is very ill, or a failure to obtain good radiographs for some other reason, increases the risk of this mistake.

In cases where a giant ulcer in the bulb looks like a pseudodiverticulum, or a postbulbar one like a true diverticulum, the distinction will depend chiefly on observation of the unchanging size and shape of the crater, but recognition of other signs may also help. If a giant ulcer in the bulb is associated with a well marked distal constriction and a patulous pylorus, there is a danger of the constriction being mistaken for the pylorus and the duodenal lesion being mistaken for a gastric one. If there is nodularity of the floor of the crater and filling defects are a conspicuous feature in the radiographs, the giant ulcer may be misinterpreted as a neoplasm. But knowledge that filling defects occur with giant ulcers should prevent this mistake. It is true that a neoplasm, eg, a carcinoma or lymphosarcoma, can cause similar radiological appearances, but such lesions of the duodenum are rare.

PATHOLOGY

Most giant duodenal ulcers are situated posteriorly. Many of them have destroyed a large part of the wall of the bulb, or of the duodenum just distal to the bulb, and penetrated deeply into the pancreas. In two published cases (Stainton and Growdon, 1957) the ulcer had extended circumferentially around the wall of the duodenum and almost completely encircled the lumen.

Pancreatic penetration was observed in most

of our cases in which the duodenum was opened at operation or examined at necropsy. It was also found in the series reported by Mistilis *et al* (1963) in all 10 cases in which there was an operation or necropsy. Penetration of the ulcer into other organs such as the liver occurs less often. Adhesions between the duodenum and surrounding structures such as the gallbladder, liver, and omentum are common. There is often an indurated inflammatory mass surrounding the ulcer, and in one reported case a mistaken diagnosis of pyloric carcinoma was made at operation, and a block resection of the pylorus, first part of the duodenum, right transverse colon, and part of the pancreas was done (Bullock and Snyder, 1952).

The inflammatory mass is responsible for some of the radiological signs. It produces the radio-lucent band or collar round the ulcer; it is at least partly responsible for the proximal and distal constrictions which are so common; and it causes the changes in the duodenum which result from pancreatic enlargement or swelling of the mesentery.

According to Mistilis *et al* (1963), the filling defects sometimes seen in giant ulcer craters represent necrotic pancreas, granulation tissue, or blood clots.

The histological appearances are those of benign peptic ulcers.

Discussion

It is of interest to consider how often giant duodenal ulcers are missed or misdiagnosed on radiological examination. We have already mentioned a review of the literature by Kirsh and Brendel (1968) in which 42 cases were regarded as proven and there had been a correct radiological diagnosis in only 24. In a series of their own, which they did not report in detail, there was a correct diagnosis in 25 out of 30 cases. The diagnosis was accurate in six of the nine cases reported by Rosenquist (1969). In our series the radiological reports were correct in 17 cases, incorrect in five, and equivocal in three. Taking all these figures into consideration, we find that the chance of a mistaken diagnosis is about one in three.

Among reported cases of giant duodenal ulcer there has been a high mortality, which can be attributed to a number of factors. Many of the patients have been elderly; there has often been delay in diagnosis; complications such as haemorrhage from the ulcer and pyloric obstruction have been common; and after partial gastrectomy there has often been some post-operative complication such as peritonitis due to leakage from the duodenal stump.

Stainton and Growdon (1957) noted that giant ulcers of the duodenum had proved to be almost uniformly fatal unless an accurate diagnosis had

been made and surgical treatment instituted. But later reports show that the death rate in this condition has been falling. Lemaire *et al* (1966) found 15 deaths in 37 published cases, a mortality of 40.5%. Since then Kirsh and Brendel (1968) have reported one death in six cases and Rosenquist one in nine; these added to our own figures (five deaths in 25 cases) give a total of seven deaths in 40 cases, a mortality of 17.5%.

There have been very few reports of a giant ulcer healing with medical treatment. Mistilis *et al* (1963) saw some degree of healing in two out of four medically treated patients, but complete healing in none. Rosenquist reported healing of the ulcer in two patients, but in one of these the ulcer recurred. We ourselves have seen healing in two cases (13 and 25).

Kirsh and Brendel (1968) thought that the mere presence of a giant duodenal ulcer should be regarded as an indication for surgery, but we believe that whenever possible medical treatment should be tried first. In many cases it will be simply a prelude to surgery, its aim being to improve the patient's general condition and allow time for any inflammatory swelling around the ulcer to subside. In other cases, for instance, when there is no chance of the patient becoming well enough for an elective operation, it will have to be continued indefinitely.

At present, vagotomy and pyloroplasty is probably the operation most often performed when elective surgery is undertaken for a duodenal ulcer. But in the case of a giant ulcer, pyloroplasty may be technically almost impossible, or at least hazardous, and then it is better to leave the duodenum alone and do a vagotomy and gastroenterostomy.

When emergency surgery is required for continuing haemorrhage from a duodenal ulcer, it is common practice to underrun the bleeding ulcer and at the same time perform a vagotomy and pyloroplasty. But in the case of a giant ulcer, where the blood may be coming directly from the gastroduodenal or pancreaticoduodenal artery, this procedure carries a high risk of recurrent bleeding. A recurrence of haemorrhage following this procedure did actually occur in case 8. To avoid this, many surgeons would perform an immediate Polya gastrectomy.

In the performance of a gastrectomy in such circumstances, it is of the utmost importance that the ulcer base should either be entirely removed or else left *in situ* and completely excluded from the duodenal stump, and in the event of difficulty in closing the stump tube drainage may have to be provided.

We are grateful to Mr C. U. Webster for giving us a surgeon's viewpoint on giant duodenal ulcers, and we thank the Department of Medical Illustration, the Radcliffe Infirmary, for help with

the illustrations, and Miss P. Lumsden for typing the manuscript.

References

- Brdiczka, J. G. (1931). Das grosse Ulcus duodeni im Röntgenbilde. *Fortschr. Röntgenstr.*, **44**, 177-181.
- Bullock, W. K., and Snyder, E. N., Jr. (1952). Benign giant duodenal ulcer. *Gastroenterology*, **20**, 330-336.
- Dawson, J. (1958). Giant duodenal ulcer. *Brit. J. Radiol.*, **31**, 666-668.
- Kirsh, I. E., and Brendel, T. (1968). The importance of giant duodenal ulcer. *Radiology*, **91**, 14-19.
- Knutsson, F. (1932). Die Nischendiagnostik bei sehr grossen Duodenalgeschwüren. *Acta radiol. (Stockh.)*, **13**, 35-40.
- Lemaire, A., Blanchon, P., Emerit, J., Yean, Y. K., Tavernier, C., and Giorgi, H. (1966). Ulcère géant du bulbe duodéal. *Presse méd.*, **74**, 1233-1236.
- Lumsden, K., and Pexman, J. H. W. (1968). The trapped air sign: its value in the interpretation of antral deformities. *Clin. Radiol.*, **19**, 211-220.
- Mistilis, S. P., Wiot, J. F., and Nedelman, S. H. (1963). Giant duodenal ulcer. *Ann. intern. Med.*, **59**, 155-164.
- Rosenquist, C. J. (1969). Clinical and radiographic features of giant duodenal ulcer. *Clin. Radiol.*, **20**, 324-328.
- Stainton, R. M., and Growdon, J. H. (1957). Benign giant duodenal ulcer. *Amer. Surg.*, **23**, 1081-1096.