

Ultrastructure of the liver in non-cirrhotic portal fibrosis with portal hypertension

B. N. TANDON, R. LAKSHMINARAYANAN, S. BHARGAVA, N. C. NAYAK, AND S. K. SAMA

From the All India Institute of Medical Sciences, Department of Medicine, Ansari Nagar, New Delhi-16, India

SUMMARY The aetiology of the ultrastructural abnormalities of non-cirrhotic portal fibrosis is not known. In an attempt to elucidate the pathophysiology of this condition, the hepatic ultrastructure in nine cases of non-cirrhotic portal fibrosis with portal hypertension has been studied.

A large series from Japan (Imanaga, Yamamoto, and Kuroyanagi, 1962) and several reports from the west (Tisdale, Klatskinn, and Glenn, 1959; Hallenbeck and Adson, 1961; Pérez, 1961; Miller and Brandt, 1962; Polish, Christie, Cohen, and Sullivan, 1962; Siderys and Vellios, 1964; Mikkelsen, Edmondson, Peters, Redeker and Reynolds, 1965) have described patients with idiopathic portal hypertension, who had neither cirrhosis of the liver nor portal or hepatic venous obstruction. A lucid description of this entity from North India (Ramalingaswami, Wig, and Sama, 1962; Wig, 1966) stimulated several investigators to study the pathophysiology and aetiology of this disorder with the help of recent techniques (Basu, Boyer, Bhattacharya, Basu Mallick, and Sen Gupta, 1967; Basu Mallick, Sen Gupta, Biswas, Pal, and Boyer, 1967; Boyer, Sen Gupta, Biswas, Pal, Basu Mallick, Iber, and Basu, 1967; Datta, 1969; Wig, Tandon, Bhargava, Sama, and Nayak, 1969). It is suggested that between 3% and 5% of the cases of portal hypertension in the west may be idiopathic (Iber, 1969). The disease is probably more prevalent in India and has been called 'non-cirrhotic' portal fibrosis (Basu *et al*, 1967; Basu Mallick *et al*, 1967; Boyer *et al*, 1967; Datta, 1969).

Clinically the disease is characterized by splenomegaly of long duration, repeated gastrointestinal bleeding with only minimal features of hepatocellular failure (Wig, 1966; Basu *et al*, 1967; Boyer *et al*, 1967; Datta, 1969; Wig *et al*, 1969). Splenoportovenograms show marked dila-

tation of the portal vein, the presence of collaterals, and no evidence of any block. The intrahepatic pattern of the portal vein is not greatly disturbed (Wig, 1966; Basu *et al*, 1967; Basu Mallick *et al*, 1967; Boyer *et al*, 1967; Datta, 1969). Haemodynamic studies show marked rise of splenic pulp pressure with normal or slight elevation of hepatic wedge pressure. The gradient between hepatic wedge pressure and splenic pulp pressure is markedly increased (Boyer *et al*, 1967; Datta, 1969; Wig *et al*, 1969), hepatic blood flow is normal (Boyer *et al*, 1967; Datta, 1969; Wig *et al*, 1969), and liver biopsies tend to be essentially normal or show minimal fibrosis (Ramalingaswami *et al*, 1962). Recently, a careful study has demonstrated subintimal thickening in the smaller intrahepatic radicles of the portal vein (Nayak and Ramalingaswami, 1969). The present study of the hepatic ultrastructure is an attempt to elucidate the pathophysiology of portal hypertension in non-cirrhotic portal fibrosis.

Method and Materials

Nine cases of non-cirrhotic portal fibrosis with portal hypertension were selected on the basis of criteria previously described by us (Wig, 1966; Nayak and Ramalingaswami, 1969). Serum albumin, globulin, bilirubin, and alkaline phosphatase were estimated, and in each case a liver biopsy was obtained using a Vim Silverman needle. One part of the biopsy specimen was

studied by light microscopy; the other was processed for electron microscopy. The specimen was fixed first in 3% glutaraldehyde and then in 2% osmium tetroxide (Karnovsky, 1965) and was embedded in epoxy resin (Luft, 1961). An LKB 4801 A ultratome was used to obtain thin sections (600Å to 700Å) which were stained with uranyl acetate (Watson, 1958) and lead citrate (Reynolds, 1963) and examined with a Hitachi Hu 11A electron microscope. A section (one micron thick) was simultaneously examined for proper orientation of the tissue.

Liver biopsies from two healthy control subjects were also studied.

Results

Splenomegaly with anaemia was a prominent feature in seven cases and two patients had haematemesis as the presenting symptom. No patient had ascites, jaundice, or any signs of hepatocellular failure. Oesophageal varices were demonstrated by barium swallow in eight of the nine cases. Splenoportovenography revealed patent, but dilated, portal and splenic veins. Collaterals were seen in all the cases. Serum bilirubin, albumin, alkaline phosphatase, and thymol turbidity were normal in all the cases. Liver histology was essentially normal with preservation of normal lobular architecture (Fig. 1). There was no evidence of cirrhosis and only in three cases was mild portal scarring present. Silver stains revealed some increase in reticulum fibres in the portal areas in a few of the cases and a suggestion of increased argyrophilia in the perisinusoidal framework.

The ultrastructure of nuclei and nuclear membranes in non-cirrhotic portal fibrosis is normal. No intranuclear bodies are observed. The mitochondria of hepatocytes are normal in size and shape. There is no evidence of mitochondrial swelling or degeneration and the double membrane and cristae are intact (Fig. 2). The rough endoplasmic reticulum is abundant while smooth endoplasmic reticulum is sparse. The hyaloplasm is rich in glycogen bodies. Autophagic vacuoles are occasionally seen (Fig. 3).

In this condition the cell membrane between two hepatocytes shows widening with the development of microvilli. The Disse's spaces are also widened because of the laying down of collagen bundles, which occasionally extend into the intercellular space, but most often spread into the perisinusoidal space (Fig. 4). Mesenchymal cells are well developed close to collagen bundles. Microvilli at the hepatocyte membranes which line sinusoids are abundant. An attempt at capillary formation of sinusoids is occasionally shown by the development of endothelial lining (Fig. 5).

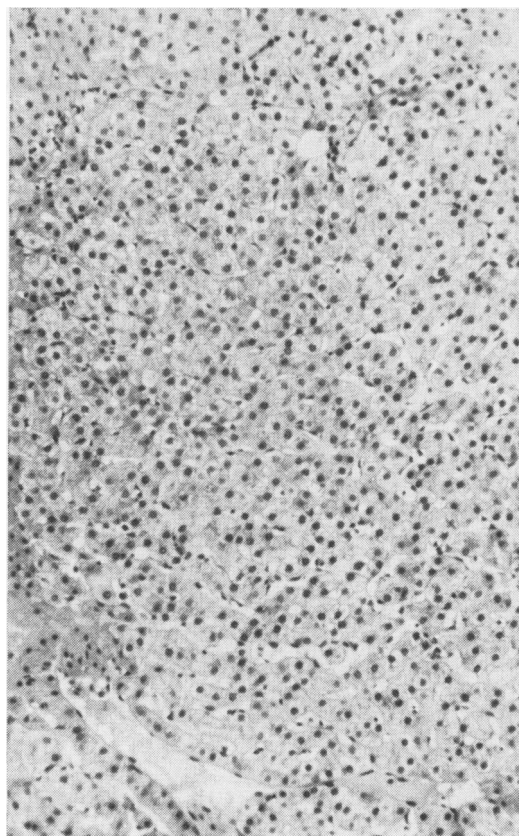


Fig. 1 Needle biopsy of a patient with non-cirrhotic portal hypertension. The liver architecture and structure appears normal. (H and E, $\times 110$.)

Discussion

Non-cirrhotic portal fibrosis is characterized by two ultrastructural findings: (1) normal nuclear and intracytoplasmic components of the hepatocytes, and (2) abnormalities of the cell membrane and perisinusoidal space. These abnormalities include widening of the intercellular and Disse's spaces and fibrogenesis in the perisinusoidal space which often extends into the intercellular space. These observations help in the understanding of the pathophysiology of portal hypertension in this disease.

Previous haemodynamic studies have indicated raised splenic pulp pressure, normal or occasionally raised hepatic wedge pressure, and a noticeable increase in the gradient between hepatic wedge pressure and splenic pulp pressure (Boyer *et al*, 1967; Datta, 1969; Wig *et al*, 1969). These findings suggest a presinusoidal or a perisinusoidal block. The presence of large numbers of collagen bundles in the perisinusoidal area and the spaces of Disse might possibly be the anatomical lesion related to the portal hypertension in this disease. Formation of capillaries from sinu-

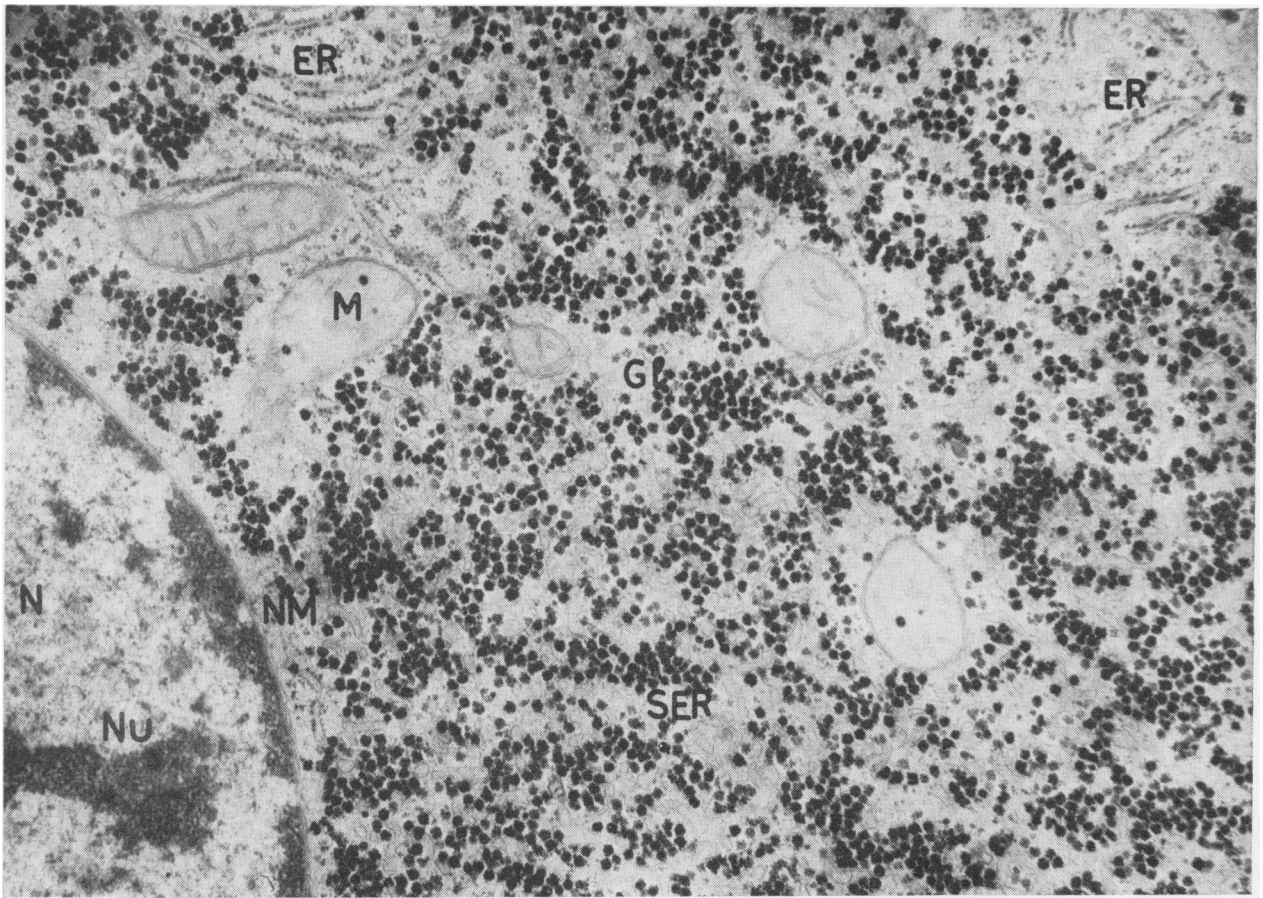


Fig. 2 Ultrastructure of hepatocytes in non-cirrhotic portal fibrosis. Nucleus and cytoplasmic organelles do not show any abnormality. (N, nucleus; Nu 2, nucleolus; NM, nuclear membrane; M, mitochondria; ER, rough endoplasmic reticulum; SER, smooth endoplasmic reticulum; Gl, glycogen.) $\times 24,000$.

soids might aggravate portal hypertension. Presinusoidal block might also be localized to the smaller radicle of the portal vein (Nayak and Ramalingaswami, 1969), but such a localization would fail to explain the raised hepatic wedge pressure observed in some of these patients. The obliterative porto-venopathy described in this disease (Nayak and Ramalingaswami, 1969) may be secondary to the rise in portal pressure or might result from perisinusoidal fibrosis. Alternatively the same aetiological factor might simultaneously produce the lesion in the smaller radicle of the portal vein and in the perisinusoidal area. It is important to note that perisinusoidal fibrosis is a rather diffuse lesion compared with obliterative portovenopathy which, is most often patchy and may be missed in a liver biopsy specimen (Nayak and Ramalingaswami, 1969).

Clinical and liver function data indicate that hepatocellular function is well preserved in non-

cirrhotic portal fibrosis. Even massive gastrointestinal bleeding does not produce hepatic encephalopathy in these patients (Wig, 1966). The normal ultrastructure of hepatocytes corroborates these observations. The development of large numbers of microvilli in the intercellular cell membrane seems to be an adaptive phenomenon which provides a wider area of contact between sinusoidal fluid and the liver cell. The adaptation may compensate for the barrier due to collagen bundles in the perisinusoidal space. Similar observations have been recorded in cirrhosis of the liver (Philips and Steiner, 1965).

The aetiology of the ultrastructural abnormalities observed in non-cirrhotic portal fibrosis is not known. Reviews of hepatic fibrosis (Popper, Paronetto, Schaffner, and Pérez, 1961) and parenchymal fibrogenesis (Popper, Schaffner, Hutterer, Paronetto, and Barka, 1960) do not describe similar abnormalities in animals or humans.

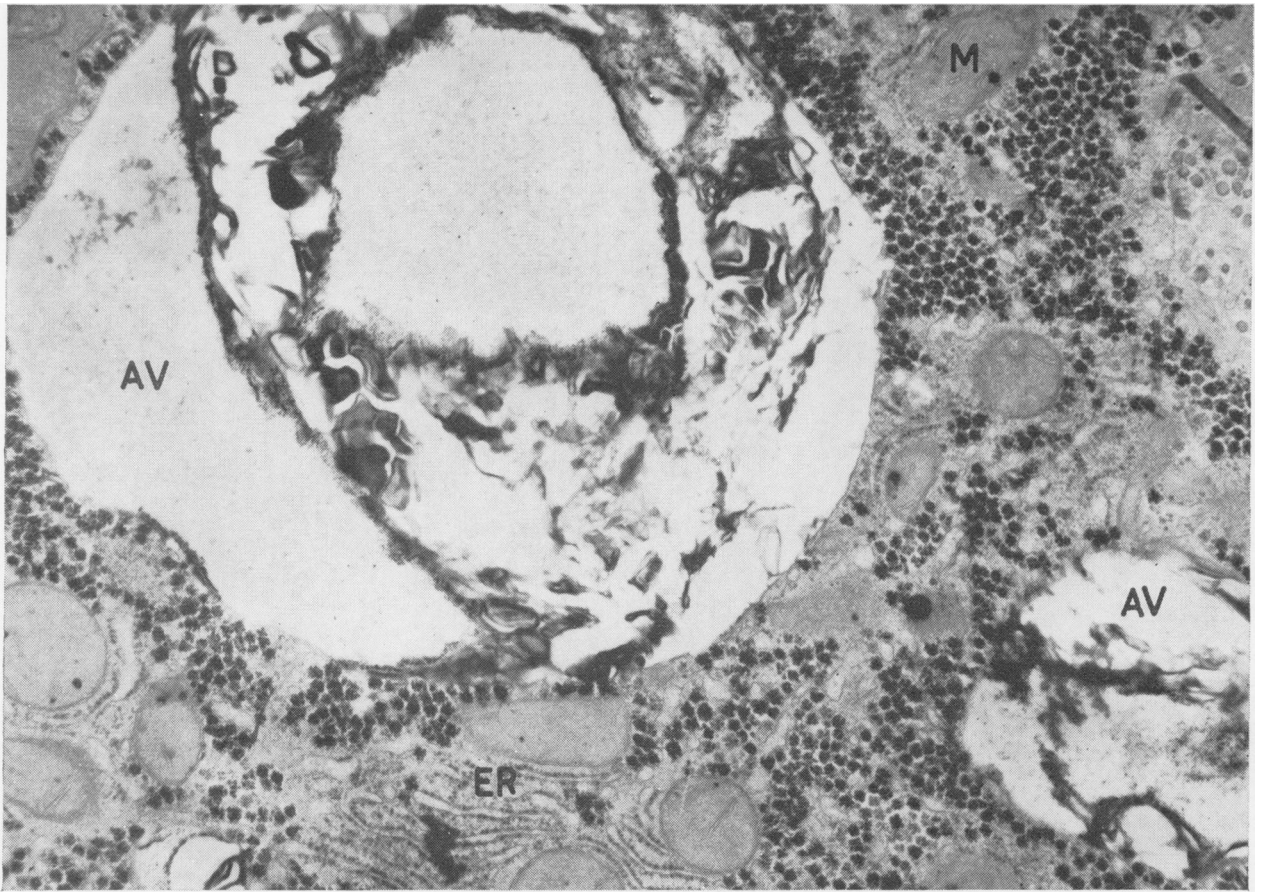


Fig. 3

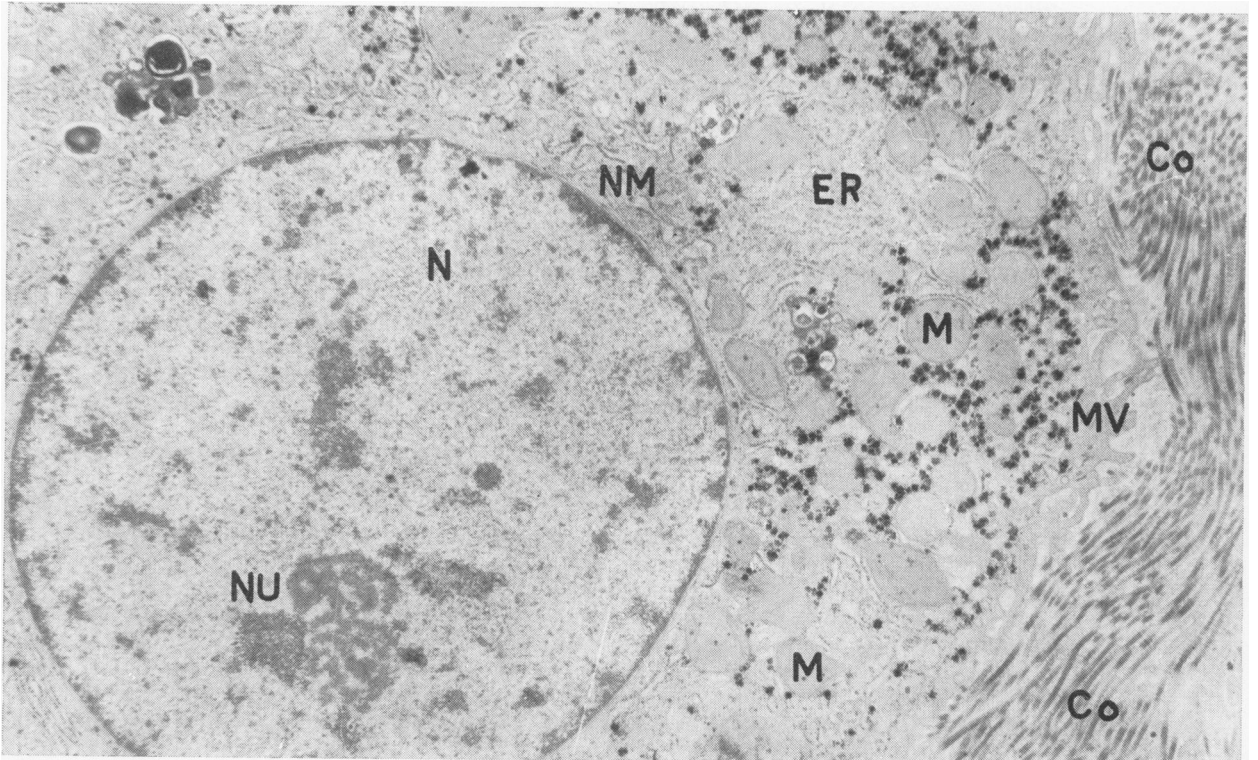


Fig. 4

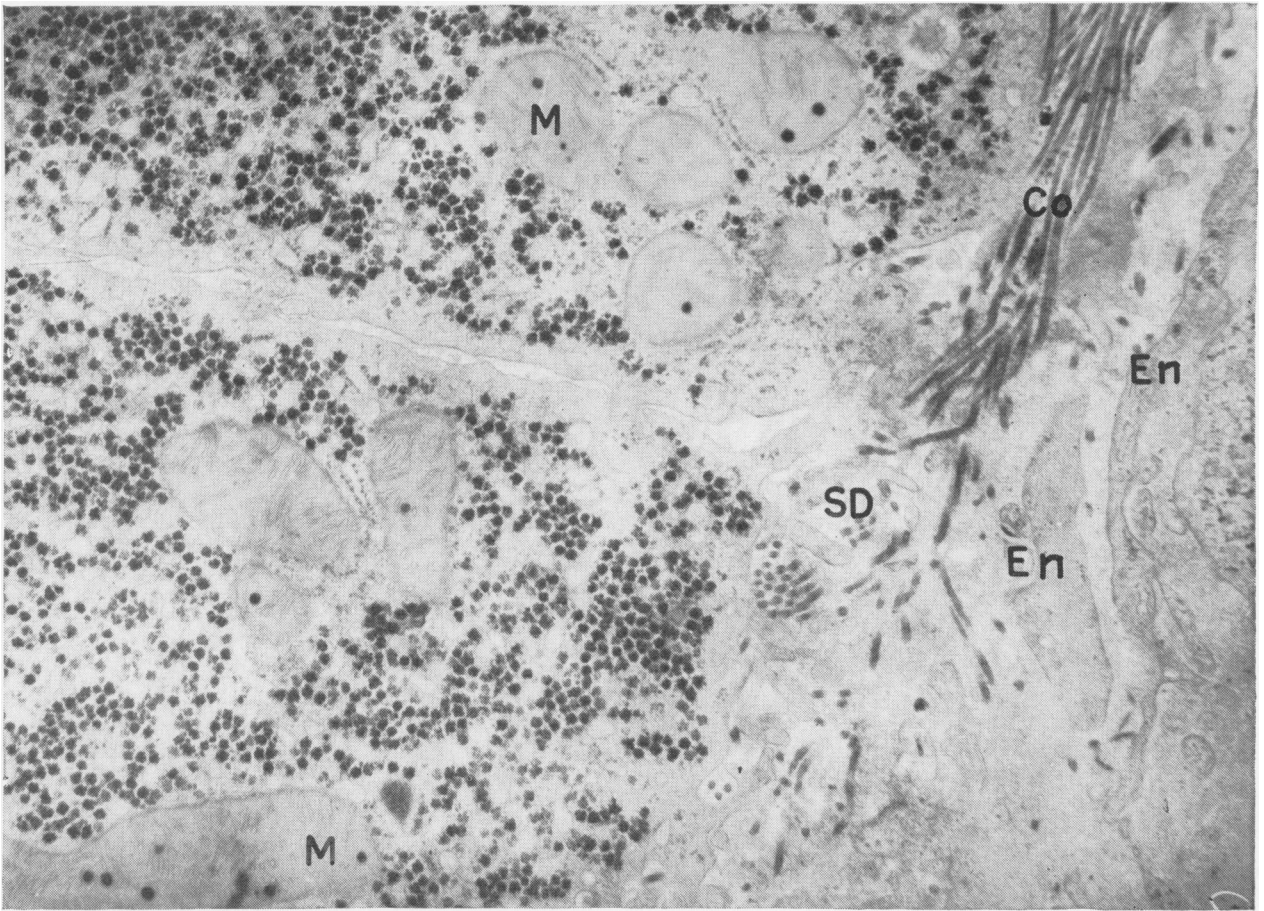


Fig. 3 Two autophagic vacuoles (AV) in a hepatocyte of a patient with non-cirrhotic portal fibrosis. $\times 24,000$.

Fig. 4 A large number of collagen bundles (Co) in the perisinusoidal space. $\times 21,000$. (MV, microvilli; other abbreviations as in Figure 2.)

Fig. 5 Collagen bundles in the space of Disse and development of the endothelial lining of the sinusoid. (En, endothelial lining; SD, space of Disse; other abbreviations as in Figure 2.) $\times 25,000$.

The authors are very grateful to Dr K. L. Wig and Dr V. Ramalingaswami who initiated their interest in the studies of non-cirrhotic portal fibrosis and have been the main investigators on this condition in India. The technical help of Mrs K. Anand, Mr P. Ganguli, and Mr P. C. Gandhi in electron microscopy is acknowledged with thanks.

References

- Basu, A. K., Boyer, J., Bhattacharya, R., Basu Mallick, K. C., and Sen Gupta, K. P. (1967). Non-cirrhotic portal fibrosis with portal hypertension. I. Clinical and function studies and results of operations. *Indian J. med. Res.*, **55**, 336-350.
- Basu Mallick, K. C., Sen Gupta, K. P., Basu, A. K., Biswas, S. K., Pal, N. C., and Boyer, J. (1967). Non-cirrhotic portal fibrosis with portal hypertension. II. Histopathological studies. *Indian J. med. Res.*, **55**, 351-359.
- Boyer, J. L., Sen Gupta, K. P., Biswas, S. K., Pal, N. C., Basu Mallick, K. C., Iber, F. L., and Basu, A. K. (1967). Idiopathic portal hypertension; comparison with the portal

- hypertension of cirrhosis and extrahepatic portal vein obstruction. *Ann. intern. Med.*, **66**, 41-68.
- Datta, D. V. (1969). Workshop on non-cirrhotic portal fibrosis. *Indian Council med. Res.*, 24-28.
- Hallenbeck, G. A., and Adson, M. A. (1961). Esophagogastric varices without hepatic cirrhosis. A clinical study of treatment for their bleeding in 72 cases. *Arch. Surg.*, **83**, 370-383.
- Iber, F. L. (1969). Obliterative portal venopathy of the liver and 'idiopathic portal hypertension'. *Ann. intern. Med.*, **71**, 660-661.
- Imanaga, H., Yamamoto, S., and Kuroyanagi, Y. (1962). Surgical treatment of portal hypertension according to state of intrahepatic circulation. *Ann. Surg.*, **155**, 42-50.
- Karnovsky, J. (1965). A formaldehyde-glutaraldehyde fixative of high osmolality for use in electron microscopy. *J. Cell. Biol.*, **27**, 137.
- Luft, J. H. (1961). Improvement in epoxy resin embedding methods. *J. biophys. biochem. Cytol.*, **9**, 409-414.
- Mikkelsen, W. P., Edmondson, H. A., Peters, R. L., Redeker, A. G., and Reynolds, T. B. (1965). Extra and intrahepatic portal hypertension without cirrhosis (hepatoportal sclerosis). *Ann. Surg.*, **162**, 602-620.
- Miller, M. C., and Brandt, J. L. (1962). Portal hypertension in the absence of both liver disease and vascular obstruction. *Amer. J. dig. Dis.*, **7**, 442-448.
- Nayak, N. C., and Ramalingaswami, V. (1969). Obliterative portal venopathy of the liver. *Arch. Path.*, **87**, 359-369.

- Pérez, M. A. (1961). Portal hypertension of splenic origin. *Amer. J. dig. Dis.*, **6**, 780-783.
- Philips, M. J., and Steiner, J. W. (1965). Electron microscopy of liver cells in cirrhotic nodules. I. The lateral cell membranes. *Amer. J. Path.*, **46**, 985-1005.
- Polish, E., Christie, J., Cohen, A., and Sullivan, B., Jr. (1962). Idiopathic presinusoidal portal hypertension (Banti's syndrome). *Ann. intern. Med.*, **56**, 624-627.
- Popper, H., Paronetto, F., Schaffner, F., and Pérez, V. (1961). Studies on hepatic fibrosis. *Lab. Invest.*, **10**, 265-290.
- Popper, H., Schaffner, F., Hutterer, F., Paronetto, F., and Barka, T. (1960). Parenchymal fibrogenesis: the liver. *Ann. N.Y. Acad. Sci.*, **86**, 1075-1088.
- Ramalingaswami, V., Wig, K. L., and Sama, S. K. (1962). Cirrhosis of the liver in Northern India. A clinico pathological study. *Arch. intern. Med.*, **110**, 350-358.
- Reynolds, E. S. (1963). The use of lead citrate at high pH as an electron-opaque stain in electron microscopy. *J. Cell. Biol.*, **17**, 208-212.
- Siders, H., and Vellios, F. (1964). Portal hypertension without cirrhosis or extrahepatic obstruction. Report of a case. *Amer. J. Surg.*, **108**, 785-789.
- Tisdale, W. A., Klatskinn, G., and Glenn, W. W. L. (1959). Portal hypertension and bleeding esophageal varices. *New Engl. J. Med.*, **261**, 209-218.
- Watson, M. L. (1958). Staining of tissue sections for electron microscopy with heavy metal. *J. biophys. Biochem. Cytol.*, **4**, 475-478.
- Wig, K. L. (1966). Liver cirrhosis in Indian adults: clinical features, in *Symposium on Liver Cirrhosis Feb. 5, 1966*, pp. 1-10. Indian Academy of Medical Sciences, New Delhi.
- Wig, K. L., Tandon, B. N., Bhargava, S., Sama, S. K., and Nayak, N. C. (1968). Clinical grand round on non-cirrhotic portal fibrosis. *Bull. India Inst. med. Sci.*, **2**, 152-165.