

SPLEEN TRANSPLANTATION IN A LEUKAEMIC INDIVIDUAL FROM HIS HEALTHY IDENTICAL TWIN

G. RACCUGLIA AND A. LANSING

*University of Louisville, School of Medicine, Department of Medicine; and
Department of Surgery, Louisville, U.S.A.*

(Received 16 October 1972)

SUMMARY

The results of spleen transplantation from a healthy individual to his leukaemic identical twin are reported. The rationale for the procedure and its significance in relation to present hypotheses of tumour growth and spread are reviewed. Although lymphocytes of both the donor and recipient showed specific immune capacity to destroy tumour cells *in vitro*, there was evidence for partial inhibition of the immunological effector process that destroys the tumour cells in the diminished lymphocyte phytoagglutinin stimulation, hypoglobulinaemia, and marked deficiency of IgA in the leukaemic twin. These abnormalities and the final relapse in spite of transplantation of the spleen as a source of immunocompetent cells could also be considered the result of growth potential in the tumour, capable of overriding any immunological control.

INTRODUCTION

Attempts to induce a 'resistance' to tumour implantation or growth, go back to the early period of immunological discoveries. Referring to his experiments in this area Ehrlich stated, in 1909: 'If metastasis formation be imitated experimentally by re-inoculating animals after they had been successfully inoculated with a rapidly growing tumour, then the second inoculation does not take.' (Ehrlich, 1906). By 1929 the field of tumour immunology had developed enough to allow Woglom to write a comprehensive review of the subject (Woglom, 1929). Fundamental work was carried out in the 1940s by Snell who demonstrated that neoplastic growth could be inhibited by re-inoculating tumour cells and that tumours have their own antigen (Snell *et al.*, 1946; Snell & Stimpfling, 1966). An early experimental attempt to control cancer by immunization was carried out by Gross (1943) whose work was confirmed and expanded by that of Foley (1953) and of Prehen and Main (1957).

Correspondence: Dr Giovanni Raccuglia, University of Louisville, Louisville General Hospital, Hematology Section, Hall 2B, 323 East Chestnut Street, Louisville, Kentucky 40202, U.S.A.

It became evident later that the immunological mechanism operative in tumour control differed from the immediate type of hypersensitivity obtainable by bacterial products. The participation of the lymphatic tissue, including plasma cells, to these peculiar processes began to be intensively investigated in the 1950s. Mitchison (1954) showed that the ability to react to normal transplantation antigens could be passively transferred to a non-immunized animal by lymph nodes from an immune animal. The ability of lymphocytes to kill cancer cells *in vitro* was demonstrated by a number of investigators (Rosenau & Moon, 1961; Winn, 1961; Chu *et al.*, 1967). Theoretical rationalization of the functions of the lymphatic system was given by Burnet (1959). This investigator postulated that the cellular identity of an organism is preserved by a 'surveillance system' represented a great part by lymphatic elements. Failure of this system would result in the survival of mutated cells and in their disorderly multiplication.

Conversely replacement of a failed system with a competent one has been envisioned as a means of controlling cancer. This therapeutic possibility appears more attainable in view of the recent developments of tissue matching techniques. Discussing these developments Good was quoted as follows: '... one would employ allogeneic cells to take advantage of the genetic differences that appear to affect susceptibility to leukaemia and then to utilize immunologic reconstitution to replace a 'failed' anticancer surveillance system with one still competent against cancer' (Granting Immunity, Editorial, 1970).

An example of this possibility existing in earlier literature may be the apparent 'cure' of leukaemia observed in the recipient of bone marrow transplantation by Mathé *et al.* (1963).

The present paper describes the attempt of controlling a neoplasia by providing a leukaemic patient with immune tissue from his healthy identical twin.

CASE REPORT

The patient was a highly intelligent 40-year-old Englishman, an executive in an American industrial firm. He was born in India and moved to London during childhood, where he remained until the age of 19. He travelled extensively from the age of 19–32 in East and South Africa. While abroad he contracted malaria twice. He also suffered from 'amoebic dysentery' and from a number of minor illnesses of undefined nature and experienced numerous insect bites including those of tsetse flies, without known consequences. In 1955 he had an episode of painless haematuria and an i.v. pyelogram revealed lack of excretion on the left side. He was told that he had lost the function of one kidney, which the patient attributed to previous boxing trauma. The family history revealed that the patient's father died of leukaemia in 1965. A study of the father's record indicated that the disease was lymphocytic in nature. It had similar characteristics to the patient's illness and lasted 6 years. The patient's mother, his only sister, and his identical twin brother lived in Great Britain and were healthy.

The patient was diagnosed to suffer from lymphocytic leukaemia by his family doctor in February 1968. The clinical and morphologic characteristics of this process suggested its possible lymphosarcomatous derivation. There was splenomegaly and generalized lymphadenopathy. The peripheral blood showed between 21,000 and 42,000 WBC mm³ of which up to 85% were lymphocytes. The sternal aspiration demonstrated a 'tight' bone marrow. The scanty material obtained was composed almost entirely by immature lymphocytes.

Laboratory results on hospital admission were as follows: Hgb 13.0 g/100 ml, Htc 38%, WBC 21,200 mm³ with 26% segmented cells, 70% lymphocytes, 4% monocytes. Platelet count was 160,000 mm³. The BUN was 48 mg%, serum uric acid 20.3 mg%, serum calcium 17.4 mg%. The urinalysis showed specific gravity of 1.011, pH 5.5, a few granular casts, and bacteria, but no sugar or protein. The bone X-ray survey was normal.

The azotaemia was believed to be related to the presence of a single kidney combined with acute hypercalcaemia, a reduced glomerular filtration rate, and hyperuricaemia (Fig. 1). The patient was treated for this with corticosteroids and fluids, and the high doses employed were also part of an attempt to induce leukaemic remission. The BUN rose to 84 mg% and then fell to 55 mg% as the urine volume increased and the serum calcium decreased to 9.5 mg%. Following his recovery from this episode of hypercalcaemia the patient was treated with oral and i.v. cyclophosphamide and methotrexate. The symptoms regressed entirely until June 1969 when lymphadenopathy and splenomegaly re-appeared. Further chemotherapy with cyclophosphamide was ineffective and it was thought that the leukaemic process had acquired resistance to this form of treatment. Therapy with triethylenmelamine was instituted. The clinical and haematologic response to this drug was initially good, but eventually severe pancytopenia developed. At this point, the patient contracted a cellulitis that started in the left inguinal region and spread over one-third of the body. *Escherichia coli* bacteraemia was demonstrated by blood cultures and septicæmic shock followed. The patient was treated with 2 g q.i.d. of chloramphenicol and corticosteroids intravenously. The inguinal abscess was drained following the administration of 21 units of packed platelets. In the ensuing several weeks the patient developed pleural effusion and scattered nodular lesions of both lungs that were radiologically consistent with either leukaemic or granulomatous infiltrates. Several attempts to demonstrate fungal or tubercular infection by culture of the pleural fluid failed. Eventually anti-tubercular therapy with streptomycin, isoniazide and PAS was started empirically although periodic tuberculin tests were negative. Concomitantly, the pleural effusion and the infiltrates decreased and disappeared in approximately 6 weeks. Splenomegaly and lymphadenopathy also regressed gradually and periodic follow-up demonstrated haematologic values within normal limits. The WBC was quantitatively normal, and although a lymphocytosis of 50–70% was consistently present the lymphocytes appeared morphologically mature. Bone marrow examinations showed a normal cellular distribution. We deemed that during this period a substantial reduction of the leukaemic burden had been attained. Immunologic treatment was considered at this point and spleen transplantation from the patient's identical twin was planned. The operation was carried out on 24 February 1970. Because the patient's apparent continuing remission, further chemotherapy immediately preceding the transplant was not administered.

The surgical plan was to place the healthy donor's spleen in the normal anatomic position. Unfortunately, the recipient's spleen was found to be surrounded by numerous enlarged lymph nodes, which impeded the appropriate isolation of the splenic pedicle. It was therefore necessary to complete the splenectomy, close this area and expose the right iliac fossa by an extraperitoneal approach. The recipient's internal iliac artery and external iliac vein were exposed and the procedure interrupted. At this point the donor was anaesthetized while the surgical team changed garments to avoid transfer of leukaemic cells or any infectious agent into the healthy twin. The donor splenectomy was performed without major obstacle, except that in order to obtain sufficiently long splenic vessels the tip of the donor's

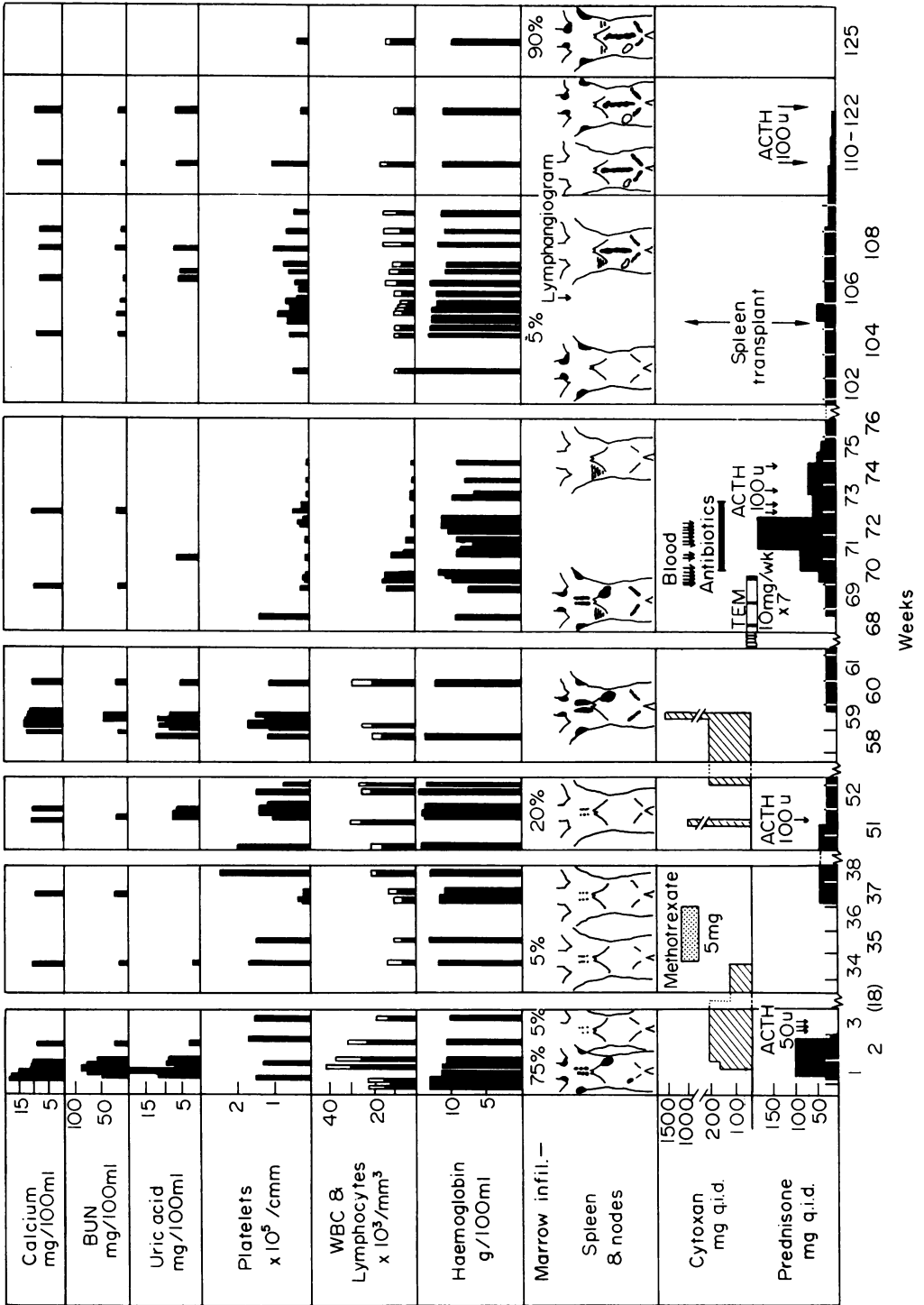


FIG. 1. Course and treatment of the patient before and after spleen transplantation.

pancreas had to be amputated and left attached to the graft. The danger of pancreatic fistula in either the donor or the recipient was foreseen but this risk was considered less than that of injury to delicate splenic veins during the attempt to free them from the pancreatic tissue. Systemic heparin was administered to the donor before the splenic vessels were divided, and neutralized by an equivalent dose of protamine immediately after. The organ was not perfused or cooled, but was carried immediately into the recipient's room. The splenic artery was anastomosed end-to-end to the divided internal iliac artery, while the splenic vein was joined end-to-side to the external vein.

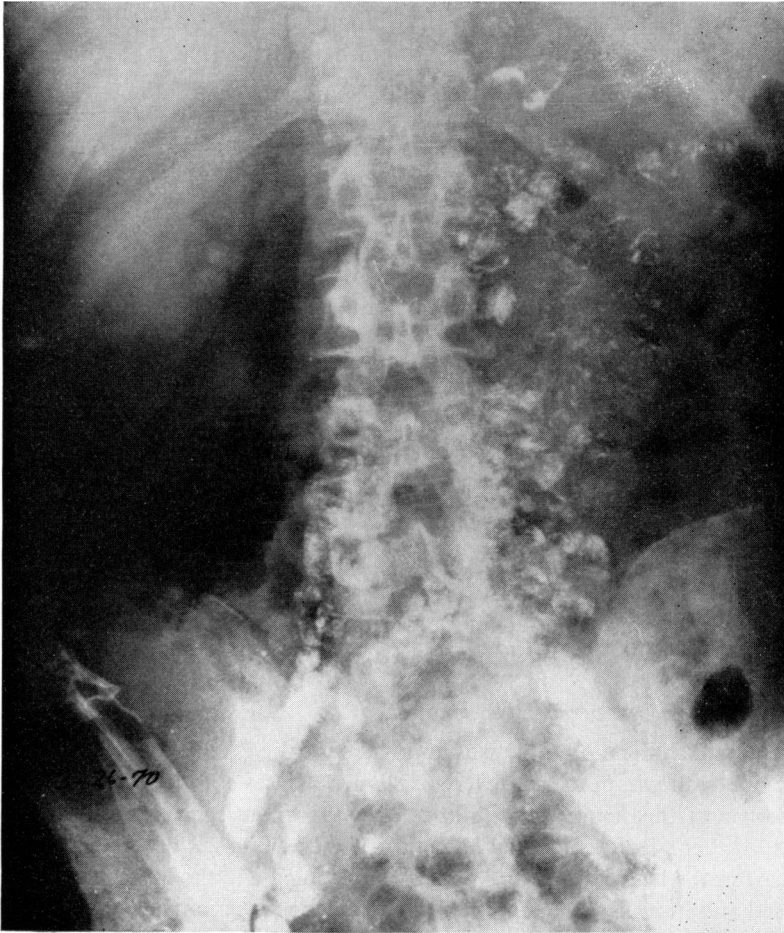


FIG. 2. Lymphangiogram performed after the spleen transplantation showing the extensive involvement of the retroperitoneal nodes by the tumour. A spleen scan of the heterotopic organ is also shown, super-imposed to the X-ray.

Special studies and post-operative course

Light and electron microscopy studies

Because of the patient's extensive sojourn in Africa including areas in which Burkitt's

lymphoma is endemic, a cervical lymph node biopsy was obtained at the onset of the disease to exclude this process before initiating therapy. The preparation was diagnostic of lymphocytic leukaemia or lymphosarcoma without distinguishing characteristics. A biopsy taken from periaortic lymph nodes at time of spleen transplant showed essentially the same pattern.

The spleen taken out of the recipient during the surgical procedure was of normal size and weighed 150 g. No gross abnormalities were noted on macroscopic examination of the outer or cut surfaces. Microscopically, no lymphosarcomatous changes or other outstanding abnormalities were observed.

Electron microscopic studies of peripheral blood buffy coat and bone marrow showed morphologic patterns of lymphocytes indistinguishable from normal.

Lymphangiographic studies

A lymphangiogram was done after the operation to evaluate the extent of the intra-abdominal disease which had been unsuspected pre-operatively. The process was diffuse as shown in Fig. 2.

Organ scanning procedures

The patient's spleen and liver scans by Technetium sulphur colloid showed no enlargement of the organs and uniform uptake in the pre-operative period.

Following the transplantation, the spleen placement, size and blood supply were determined by similar technique. The organ shown in Fig. 2 is in anomalous position but of normal size. Scanning was repeated periodically to demonstrate viability and size of the organ and the distribution of the isotope; these remained constant.

Establishment of homozygosity of recipient and donor

Blood typing showed the following results for both the perspective donor and recipient: K-; Fy (a- b+); Jk (a+); Le (a- b+); S+ s+; M+N+; P₁+; Lu (a-).

Tissue typing by the Terasaki technique was done pre-operatively. The results are shown in Table 1. The homozygosity of the twins may be inferred from these results.

Preoperative studies of the perspective donor

After the establishment of the twins uniovularity the procedure was proposed to the perspective donor to whom its risks were explained. The theoretical reasons that suggested the transplant and the scanty probabilities of a therapeutic success of this procedure in treating his brother's leukaemia were also thoroughly discussed with this highly intelligent individual. After the healthy twin had agreed to participate in the experiment, the procedure was proposed and its risks were explained to the perspective recipient. Once he accepted the procedure, the healthy twin was brought to the U.S.A. and hospitalized for a pre-operative examination.

The healthy twin was an executive, who had lived in London, England since infancy except for a 1-year residency in North Africa for military service. The history, review of systems and physical examination were entirely negative.

X-ray examination of the chest was negative. An i.v. pyelogram obtained for comparison with that of his brother, revealed both kidneys to be present and normal. A tuberculin test showed an induration of 2 cm and an erythema of 4 cm in 24 hr.

Laboratory results were as follows: Hgb 15.4 g/100 ml, WBC 7,800 mm³ with 49% segs, 37% lymphs, 5% monocytes, 7% eosinophils and 2% basophils. The urinalysis was normal; the tests of the sequential multiple analysis (SMA-12) were normal; platelets were 222,000 mm³. The results of studies of proteins, serum electrophoresis, and immune globulins are shown in Fig. 3 where they are compared to those of the recipient.

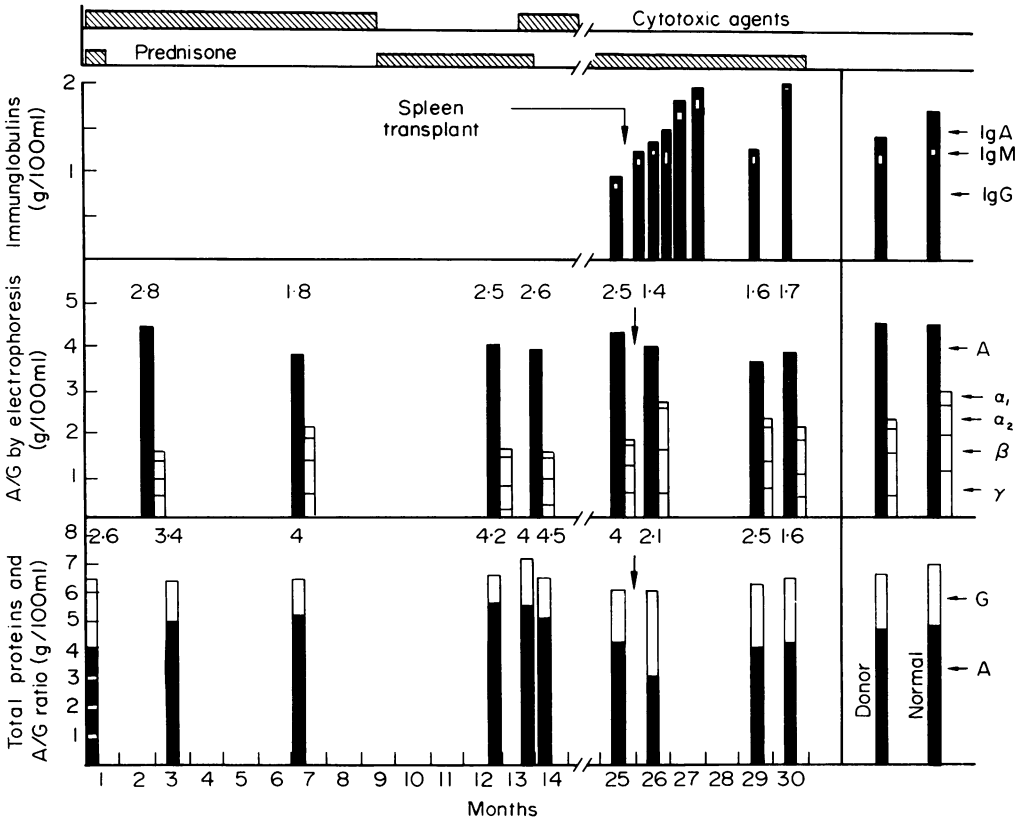


FIG. 3. Patient's serum proteins and immunoglobulins before and after spleen transplantation. The use of drug therapy is indicated at the top of the graph, and the values in the donor and normal controls are also indicated.

Light and electron microscopic examination of buffy coat and bone marrow were normal. Cytogenetic studies were performed on bone marrow cells with the method of short incubation. The karyotype was a normal xy as it was for the leukaemic brother.

Lymphocyte phytoagglutinin stimulation test

Thymidine uptake by lymphocytes upon phytoagglutinin stimulation was evaluated with the technique of Hungerford *et al.* (1959) and Walker & Fowler (1965). The test was performed in both twins pre-operatively and periodically in the recipient following the transplantation; the results are shown in Fig. 4. The pre-operative lymphocyte thymidine uptake upon stimulation was lower in the leukaemic twin (32%) than in his leukaemic

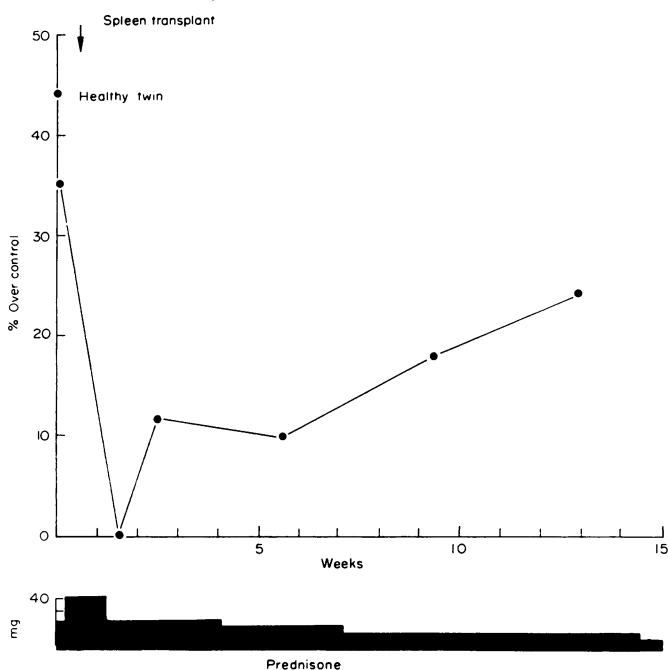


FIG. 4. Phytohaemagglutinin stimulation test with the patient's lymphocytes before and after spleen transplantation. The results obtained pre-operative with the lymphocytes of the healthy twin are also indicated.

brother (44%). Both values were, however, within the limits of the standard deviation. A fall of the uptake values of the leukaemic brother followed the transplant operation but coincided also with the temporary use of high doses of prednisone during the stress of surgery and the post-operative period. The titre increased toward normal values again in ten weeks. Follow-up of the donor was not obtained due to his return to Europe shortly after the operation.

Immunoglobulin studies

The patient's serum protein and immunoglobulin patterns were frequently studied both before the transplant and in the post-operative period. Three different techniques were used; the colorimetric method of the sequential multiple analysis (SMA-12), serum electrophoresis by the acrylamide gel method and the modified semiquantitative immune diffusion technique. The results are shown in Fig. 3. The patient's values are compared with the normal and the healthy twin's pre-operative values. The patient demonstrated a persistent hypoglobulinaemia and, in particular, a variable deficiency of IgA. The IgA values dropped as low as zero on one occasion. The healthy brother's patterns were within normal limits but the semiquantitative immunodiffusion demonstrated a slight decrease of IgA below normal. As it may be seen from Fig. 3, following the transplantation, the recipient's IgA rose temporarily, but fell again with the relapse of the disease.

Other studies

Tissue samples including blood, bone marrow, lymph nodes and skin were obtained from

both twins in the course of the surgical procedures. The spleen of the leukaemic twin was also available. These specimens were carried immediately to the laboratories of the Public Health Service, National Institute of Health, Viral Leukaemia and Lymphoma Branch and those of the M. D. Anderson Hospital in Houston, Texas.

A laborious search for a suitable specimen of peri-aortic lymphatic tissue from the healthy twin yielded only a small sample that was proven histologically to be a lymph node. This tissue was divided and sent to the two laboratories, but unfortunately one of the specimens contained inadequate lymphatic tissue and could not be cultured as planned.

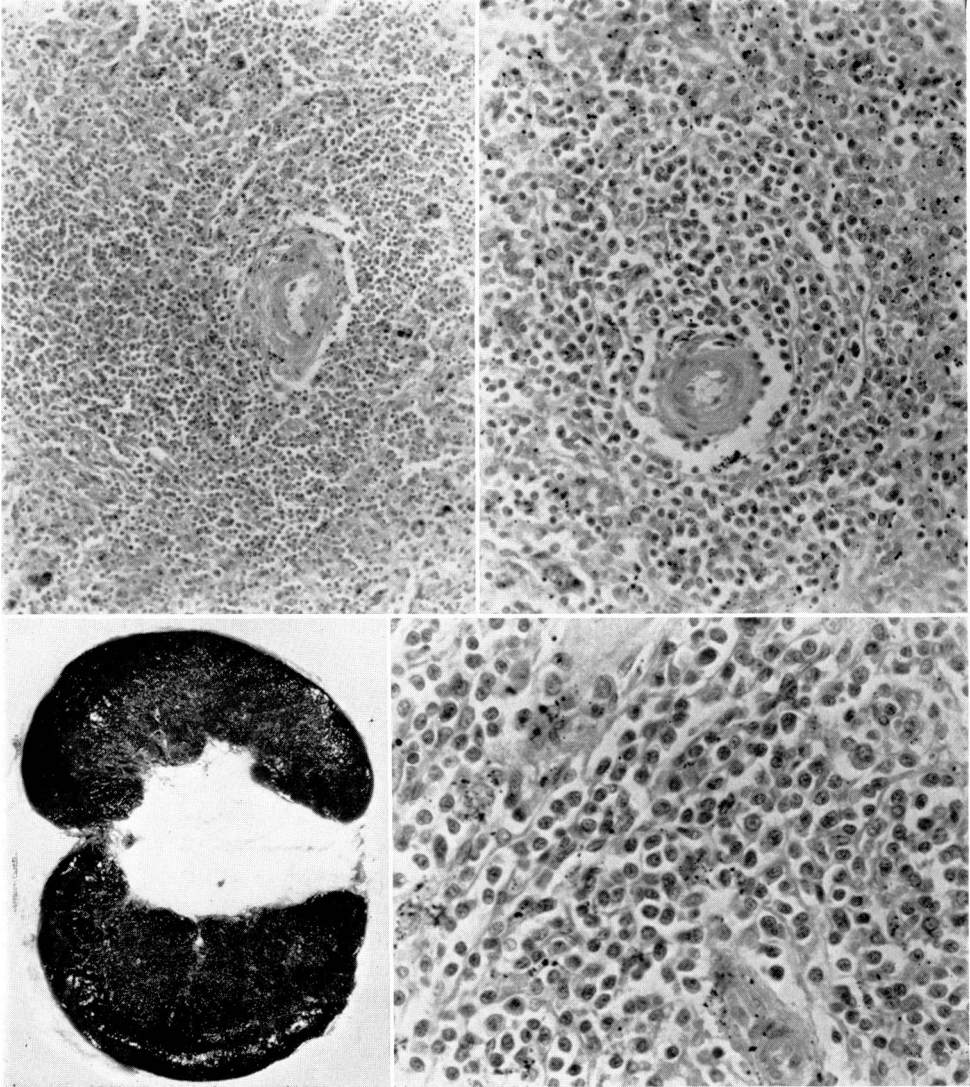


FIG. 5. Gross and microscopic picture of the transplanted spleen observed at autopsy, 11 months after implantation.

From the other specimen a culture of normal lymphocytes were obtained. Cellular growth was obtained in both laboratories with tissue from the leukaemic lymph node and cytotoxic tests were performed with the available material. Results communicated by the NIH laboratories showed that both the patient's and his brother's blood lymphocytes had specific immune capacity to destroy tumour cells from lymph node *in vitro*. Other studies performed by the NIH laboratory included separate electron microscopy and serum titration for the Epstein-Barr virus antibodies. No evidence of viral infection was obtained by electron microscopy. The antibody titre was 640 in the affected twin and 320 in his healthy brother.

Clinical evaluation and follow-up

The pre-operative and post-transplantation course and laboratory results of the affected

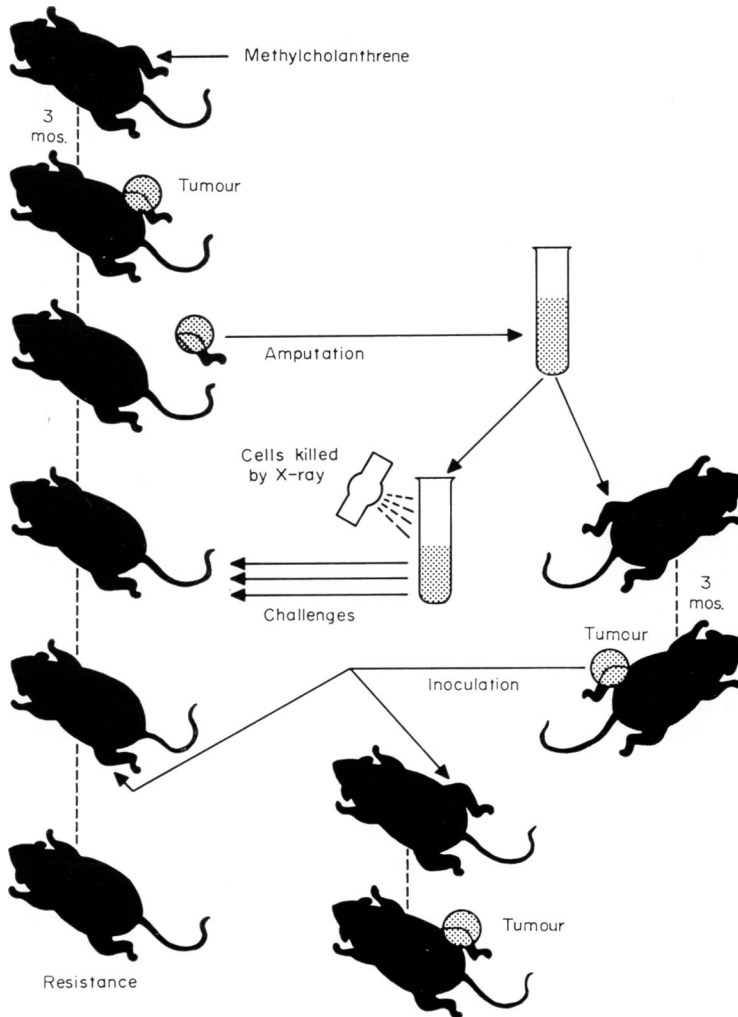


FIG. 6. Demonstration of the ability of an animal to develop immunity against an autochthonous tumour (modified from Klein *et al.*, 1960).

twin are shown in Figs 1, 3 and 4. The parameters chosen to follow the progress of his disease included the usual clinical, radiologic, laboratory and haematologic criteria, periodic re-assessment of size of lymph nodes visualized by the lymphangiogram, evaluation of spleen viability and size by scanning, follow-up of serum protein pattern, semiquantitative estimation of immune globulins and thymidine uptake of the lymphocytes after stimulation by phytoagglutinin. The donor was discharged the tenth post-operative day to return to London, England.

The recipient was discharged on the sixteenth post-operative day. He had to be re-admitted 1 week later, however, because of right lower quadrant discomfort. The only major difference between the laboratory results obtained this admission and those obtained at time of discharge was the serum amylase of 734 units and serum calcium of 8.3 mg%. A spleen scan showed a viable organ, unchanged in size since the previous examination. The symptomatology and the abnormal amylase were attributed to secretory activity of transplanted pancreatic tissue. The area was drained and fat necrosis was observed in the surrounding tissues. Immediate improvement of subjective symptoms occurred, the amylase fell to 264 units in 4 days and the patient was discharged on the fifth hospital day. The drain was kept in place until expelled spontaneously 4 weeks later, and no further problems developed in this area.

No chemotherapy was administered after discontinuation of tryethylenmelamine the previous summer. Prednisone was tapered slowly and finally discontinued. The tuberculin test which had been repeated periodically was done again after discontinuation of prednisone still with negative results. The chest X-ray continued to be essentially normal. Haematologically the leucocyte count remained normal and the absolute count of the lymphocytes decreased significantly in the post-operative period. The number of these cells, usually prevalent over the segmented cells, decreased to 35% of the total count. The platelets rose gradually to 97,000/mm³. Periodic spleen scans showed that size and uptake of the organ remained the same until October 1970 when an increased retention of the radioactive medium was detected.

Following the demonstration of intra-abdominal lymphadenopathy by operation and lymphangiogram, the periodic re-evaluation of the node size was accepted as an important follow-up criterion. Repeated plain X-rays of the abdomen using a consistent exposure technique were obtained, but no decrease in the size of the nodes was observed in the months following the operation.

The patient returned to work, but in June 1970 his general condition deteriorated significantly. Lymphadenopathy re-appeared and became generalized; haematologically the peripheral blood showed an increase of the lymphocytes and a return to their predominance over the granulocytes; the bone marrow again became 'tight', with the scanty material obtained showing only rather immature lymphocytes and 'basket cells'. Chest X-ray demonstrated an increase of the pleural effusion. The hypogammaglobulinaemia also worsened and the IgA decreased to zero.

Antileukaemic therapy with daily doses of 150 mg of cyclophosphamide was re-instituted in the fall of 1970 with substantial improvement. At this time the transplanted spleen was still viable and of the same size. The final hospital admission was on 29 December 1970. At this time the patient manifested generalized bleeding tendency and progressive dyspnea due to recurring massive right pleural effusion. He received blood and platelet transfusions with diminishing periods of benefit. Laboratory results included: Hgb 7.9 g/100 ml, WBC 14,000/

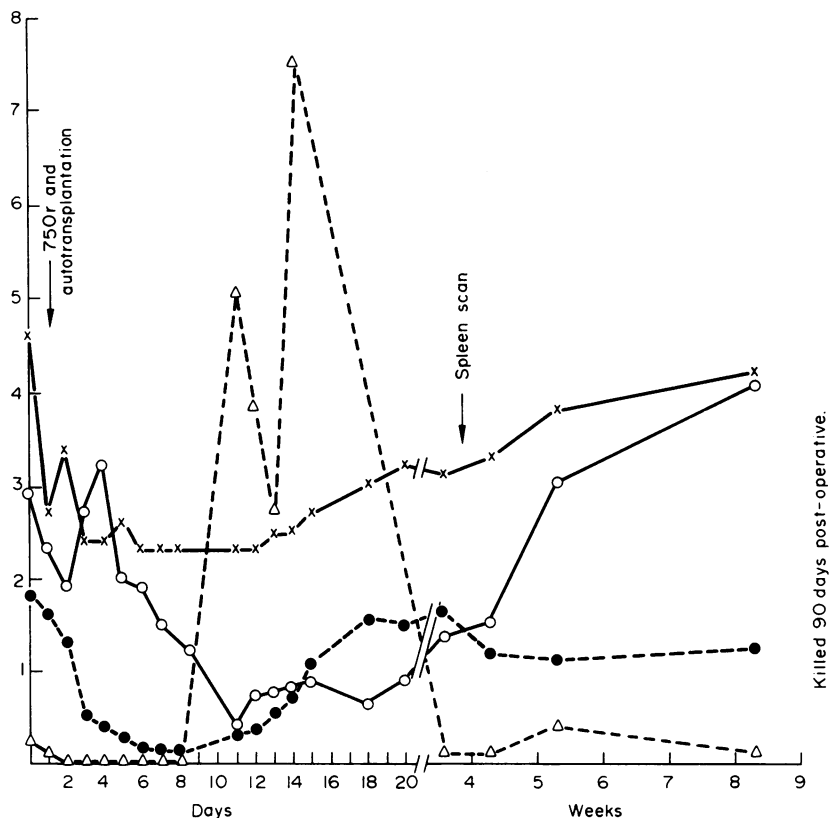


FIG. 7. Dog 9, irradiation autotransplantation. Haematological values in a typical animal following splenectomy, total body irradiation, and splenic re-implantation. (x) Haematocrit (in %) $\times 10$; (●) leucocytes $\times 10^4$; (○) platelets $\times 10^5$; (Δ) reticulocytes (in %).

mm^3 with 26% segmented leucocytes, 6% monocytes and 68% lymphocytes. The platelets were $4000/\text{mm}^3$. Platelet and blood transfusions, prednisone and antibiotics were employed. He died 3rd January 1971.

At post-mortem examination the bleeding tendency was evidenced by petechiae, ecchymoses and bilateral haemothorax. Massive tumoural involvement of the abdominal and thoracic lymph nodes was present. The lungs showed bilateral atelectasis, haemorrhages and multiple leukaemic infiltrations. The bone marrow showed massive lymphocytic involvement.

The transplanted spleen weighed 320 g. The organ showed no evidence of infarction and appeared to have been viable until the death of the patient. A fibrous capsule and dense scar tissue surrounded the organ. The blood vessels were patent and the anastomoses were intact. Microscopically the organ showed congestion and diffuse deposits of haemosiderin. Endothelial cells were prominent. The lymphatic tissue was abundant but the follicular small lymphocytes were decreased. The lymphocytes present could not be classified as leukaemic. Some of these mononuclear cells were seen within the sinusoidal spaces. There was no

vasculitis. No histologic signs of immunological rejection or graft-versus-host reaction were observed. Clusters of bacteria were found in random areas within the splenic pulp.

The organ and the microscopic picture of the tissue are shown in Fig. 5.

DISCUSSION

The procedure carried out in our patient was suggested by the following hypotheses: (1) the disease of the leukaemic twin resulted from environmental influences which had not been operative in his brother. Adequate 'immunological competence' had been retained by the healthy twin while it had been lowered or lost by the patient; (2) by transplanting immune tissue from the healthy twin 'immunological reconstitution' could be expected. An immunological attack by the donated immune cells against the recipient's leukaemic cells could thus be made possible; (3) the spleen was a suitable source of immune cells.

The first was our fundamental assumption. The hypothesis that only one of two identical twins may lose immunological competence and thus become the host of a malignant process may be considered an expression of the first of three principles enunciated by Burnet. According to this investigator 'any carcinogenic process would be successful only if this control ('surveillance') can be overcome: (1) by inhibition of the effector process of control which is presumed to be by the direct action of immunological competent cells; (2) by loss of antigens recognizable as foreign; (3) by the development of growth potential capable of over-riding any immunological control.' (Burnet, 1964).

Support of Burnet's first principle on carcinogenesis is derived from the observation that carriers of cancers manifest a worse prognosis if their lymphocytic elements are scanty (Black *et al.*, 1953; Riesco, 1970; Lukes & Butler, 1966); from the experiences of Gross concerning the development of malignancies in the elderly (Gross, 1965) or in the early newborn period (Gross, 1951), ages characterized by immunological deficiencies; from the observation that individuals with hypogammaglobulinaemia and congenital lymphopenic diseases incur higher risk of developing leukaemia (Page *et al.*, 1963); and above all from the now recognized fact that individuals on immunosuppressive therapy have a high susceptibility to malignancy (Wilson *et al.*, 1968; Doak *et al.*, 1968).

The fact that our patient lived one-third of his life in an environment where frequent exposure to possible viral agents was possible, and that he experienced the influence of other exogenous factors such as malaria infections, independently from his twin, suggest that an imbalance between insult and defence might have been an individual phenomenon. Malaria has been considered to be a factor depressing immunological defences and a contributory cause in the development of Burkitt's lymphoma (Kafuko *et al.*, 1969), a theory that has received experimental support (Jerusalem, 1968). Indications of immunological differences between the twins included the positive tuberculin reaction which was repeatedly positive in the healthy brother and negative in the patient. IgA was severely depressed in the leukaemic twin throughout the disease, while in the healthy brother this value was not significantly decreased. The activity of the lymphocytes in the phytoagglutination test was higher in the healthy brother than in the patient.

Our next hypothesis, regarding the 'immunological reconstitution' using tissue of a homozygous twin with the intent of restraining the malignant growth is valid, but clinical or experimental support for it is scanty. An experimental model with syngeneic animals that would create conditions similar to ours was devised by Burnet (Burnet, personal communi-

cation). Antibodies and cytotoxic activity against melanoma cells were demonstrated by the serum and lymphocytes of a twin apparently cured of melanoma, this activity being effective against the cancer cells of his brother still suffering from this disease (Klein & Oettgen, 1969). Experimentally the ability of an organism to reject an autochthonous tumour has been demonstrated by Klein *et al.* (1960). These investigators induced a methylcholanthrene sarcoma in the leg of an animal (Fig. 6) and amputated the limb before the invasive stage of the disease. This tumour was re-implanted in another subject, a host animal, and time allowed for the establishment of the malignancy. Cells from this growing tissue were harvested, killed by X-ray and inoculated into the now cancer-free donor in an attempt to induce immunity. Harvested sarcoma cells from the same source were also re-implanted later, live, in the original donor animal but failed to attain full growth. This failure of the sarcoma to take was attributed to inhibition by antibodies formed against the autochthonous tumour cells.

A tumour developing in one of a set of identical twins may be considered autochthonous for the healthy brother. Pre-operative 'immunization' of the donor by killed leukaemic cells would therefore have rendered our experimental procedure comparable to that of Klein *et al.* (1960). We considered administering pre-operatively X-ray killed leukaemic cells to the healthy twin, but ruled this procedure out as ethically unacceptable because of the danger of transmission of infectious agents or viable leukaemic cells.

Indications that the transplantation may have contributed to an immunological improvement included the increase of immunoglobulins observed in the blood of the patient and the drop of his peripheral blood absolute lymphocyte count. These changes were however transient.

The question raised whether the lymphatic system of the donor was 'competent' or if it was genetically inadequate could not be answered. The known familial disposition to leukaemia (Heath & Moloney, 1965), also evident in our patient's history, and the known higher incidence of this disease in twins of affected subjects (Anderson & Herrmann, 1955) indicated a negative answer. The slight decrease of IgA was, however, the only objective suggestion of an immune defect that we could detect in the healthy twin.

Our third thesis regarded the choice of the organ to attain 'immunological reconstitution'. In choosing the spleen as a graft, we were influenced by a number of considerations. The spleen is a known source of totipotent cells and 'non-committed' lymphocytes. The role of this organ in the restoration of the haemopoietic functions following exposure to lethal doses of ionizing radiation is well known from the experiences of Jacobson *et al.* (1949). As a follow-up of these investigations, we carried out spleen transplantations in dogs following superlethal irradiation (Raccuglia & Lansing, 1967). The animals were given 750–900 r total body irradiation immediately following splenectomy. The spleen was re-implanted surgically within 1 hr after X-ray exposure. These animals recovered rapidly (Fig. 7) while all the controls succumbed. Jacobson *et al.* (1950) also demonstrated that antibodies could be produced in the spleen by shielding this organ during exposure of the animal to total body irradiation. 'Colony-forming cells' are present in the spleen (Lahiri & Van Potten, 1969) as well as bone marrow and actual production of lymphocytes in the spleen has been demonstrated (Andreasen & Ottesen, 1945; Ehrich, 1929). While the density of totipotent cells seems to be higher in the bone marrow, the total number of cells which may be donated with the spleen transplant should be larger because of the heavier quantity of tissue transferred with this technique.

Attempts to use spleen cells for the immunotherapy of human cancer include those of Woodruff and Nolan who administered spleen cells to patients suffering from malignant melanoma (Woodruff & Nolan, 1963). Marchioro *et al.* performed spleen transplantations in four individuals suffering from various forms of malignancies (Marchioro *et al.*, 1964). In these experiments unmatched allogeneic tissues were used. In some of the recipients the use of immunosuppressive agents was necessary. These drugs may forestall the graft-versus-host reaction but interact with the possible antitumour activity of the cells which should stem from the transplanted organ. In our case the choice of an identical twin as donor for his brother made the use of immunosuppressive agents unnecessary.

The fact that the fate and condition of the transplanted organ could be followed by scanning and uptake evaluation by surface counting was considered of no little importance; if bone marrow elements from an identical twin are employed, no definite proof of survival of the donor cells in the recipient is obtainable. Repeated scans demonstrated the post-operative viability of the donated spleen, which did not enlarge or change uptake until the clear relapse of the disease, when the surface count increased substantially.

While other interpretations are possible, the negative results of our experiment may be explained by the third principle on carcinogenesis of Burnet, namely by the fact that the number of immune elements donated to the leukaemic twin was not commensurate with the burden of his tumour. The possible temporary improvement of some of the tests indicated above, and the regression observed as relapse occurred, suggest the importance of an overwhelming growth potential in the tumour that was capable of over-riding any immunological control. The possibility that cancer cells may be protected from the lymphocytic attack by an interfering serum factor (Hellström *et al.*, 1969), cannot be excluded. This alternative would be explained by the second principle on carcinogenesis of Burnet.

A postulate of the third principle is that if the load of cancer cells is decreased by surgery, radiation or chemotherapy, the natural immune defences may keep the remaining malignant cells in check and retard the process for a long time or even cure it (Dunphy, 1950; Mathé Amiel, 1964; Burkitt, 1967). The pre-operative conditions of the patient led us to believe that the leukaemic load before transplantation was not heavy and that the aggressive chemotherapy previously administered had favoured an equilibrium between growth and defences. Unfortunately the lymphangiogram was not done pre-operatively and the abdominal localization of the disease was discovered only during the operation.

ACKNOWLEDGMENTS

We thank Dr Harold G. Eskin for the referral of his patient; Dr R. Schrod of the Department of Pathology of the University of Louisville Medical School for the electron microscopic preparations of the peripheral blood buffy coat; Dr Ira Fowler of the University of Kentucky for performing the lymphocyte phytoagglutinin stimulation tests; Dr Joseph Sinkovics, Dr Daniel Rubin, Dr Paul Levine, Dr Ronald Herberman and Dr Eugene Rosenberg for viral, antibody and cytotoxicity studies.

This study was supported in part by the special grant from the Jewish Hospital, Louisville, Kentucky; by the Leukemia Research Fund of the Section of Hematology, University of Louisville School of Medicine; and by the Transplantation Fund of the Section of Cardiovascular Surgery.

REFERENCES

- ANDERSON, R.C. & HERRMANN, H.W. (1955) Leukemia in twin children. *J.A.M.A.* **158**, 652.
- ANDREASEN, E. & OTTESEN, J. (1945) Studies on the lymphocyte production. Investigation on nucleic acid turnover in the lymphoid organs. *Acta Physiol. Scand.* **10**, 258.
- BLACK, M.M., KERPE, S. & SPEER, F.D. (1953) Lymphnode structure in patients with cancer of breast. *Amer. J. Path.* **29**, 505.
- BURKITT, D. (1967) Long term remissions following one and two dose chemotherapy for African lymphoma. *Cancer*, **20**, 756.
- BURNET, F.M. (1959) *The Clonal Selection Theory of Acquired Immunity*. Vanderbilt and Cambridge Univ. Press, 1959.
- BURNET, F. M. (1964) Immunological factors in the process of carcinogenesis. *Brit. med. Bull.* **20**, 154.
- CHU, E.H.Y., STJERNSWÄRD, J., CLIFFORD, P. & KLEIN, G. (1967) Reactivity of human lymphocytes against autochthonous and allogeneic normal and tumor cells *in vitro*. *J. nat. Cancer Inst.* **39**, 595.
- DOAK, P.B., MONTGOMERIE, J.A., NORTH, J.D.K. & SMITH, F. (1968) Reticulum cell sarcoma after renal homotransplantation and azathioprine and prednisone therapy. *Brit. Med. J.* **4**, 746.
- DUNPHY, J.E. (1950) Some observations on the natural behaviour of cancer in man. *New Engl. J. Med.* **242**, 167.
- EHRICH, W. (1929) Studies of the lymphatic tissue. *J. exp. Med.* **49**, 361.
- EHRlich, P. (1906) Experimentelle Karzinomastadien an mausem. *Zeitschr. f. Aertzliche Fortbildung*, **7**, 205.
- FOLEY, E.J. (1953) Antigenic properties of methylcholanthrene-induced tumors in mice. *Cancer Res.* **13**, 835.
- GRANTING IMMUNITY (1970) Editorial (J.S.) in *The Sciences*. *N.Y. Acad. Sci.* **10**, 10.
- GROSS, L. (1943) Experimental immunization against implantation of cancer. *Quart. Bull. Polish Inst. Arts and Sci. America*, **1**, 418.
- GROSS, L. (1965) Immunological defect in aged population and its relationship to cancer. *Cancer*, **18**, 201.
- GROSS, L. (1951) 'Spontaneous' leukemia developing in C3H mice following inoculation in infancy, with AK-leukemic extracts, or AK-embryos. *Proc. Soc. exp. Biol. (N.Y.)*, **76**, 27.
- HEATH JR, C.W. & MOLONEY, W.C. (1965) Familial leukemia. *New Engl. J. Med.* **272**, 882.
- HELLSTRÖM, I., HELLSTRÖM, K.E., EVANS, C.A., HEPNER, G.H., PIERCE, G.E. & YANG, J.S. (1969) Serum mediated protection of neoplastic cells from lymphocytes immune to their tumor specific antigens. *Proc. nat. Aca. Sci. (Wash.)*, **62**, 362.
- HUNGERFORD, D.A., DONNELLY, A.J., NOWELL, P.C. & BECK, S. (1959) The chromosome constitution of a human phenotypic intersex. *Amer. J. Human Genetics*, **11**, 215.
- JACOBSON, L.O., MARKS, E.K., GASTON, E.O., ROBSON, M. & ZIRKLE, R.E. (1949) The role of spleen in radiation injury. *Proc. Soc. exp. Biol. (N.Y.)*, **70**, 740.
- JACOBSON, L.O., ROBSON, M.J. & MARKS, E.K. (1950) The effect of X-radiation on antibody formation. *Proc. Soc. exp. Biol. (N.Y.)*, **75**, 145.
- JERUSALEM, C.Z. (1968) Relationship between malaria and malignant lymphoma in mice. *Z. Tropenmed Parasit.* **19**, 94.
- KAFUKO, G.W., BAINGANA, N., KNIGHT, E.M. & TIBEMANYA, J. (1969) Association of Burkitt's tumor and holoendemic malaria in West Nile District, Ugandi. Malaria as a possible aetiological factor. *E. Afr. med. J.* **46**, 414.
- KLEIN, G., SJOGREN, H.O., KLEIN, E. & HELLSTRÖM, K.E. (1960) Demonstration of resistance against methylcholanthrene-induced sarcomas in the primary autochthonous host. *Cancer Res.* **20**, 1561.
- KLEIN, G. & OETTGEN, H.F. (1969) Immunologic factors involved in the growth of primary tumors in human or animal host. *Cancer Res.* **29**, 1741 (citing work of B. Papermaster).
- LAHIRI, S. K. & VAN POTTEN, L.M. (1969) Distribution and multiplication of colony forming units from bone marrow and spleen after injection in irradiated mice. *Cell Tissue Kinetics*, **2**, 21.
- LUKES, R.J. & BUTLER, J.J. (1966) The pathology and nomenclature of Hodgkin's disease. *Cancer Res.* **26**, 1063.
- MARCHIORO, T.L., ROWLANDS JR, D.T., RIFKIND, D., WADDELL, W.R. & STARZL, T.E. (1964) Splenic homotransplantation. *N.Y. Acad. Sci.* **120**, 626.
- MATHÉ, G. & AMIEL, J.L. (1964) Immunotherapy, new method of treatment of leukemias. *Nouv. Rev. Franç. Hémat.* **4**, 211.
- MATHÉ, G., AMIEL, J.L., SCHWARZENBERG, L., CATTAN, A. & SCHNEIDER, M. (1963) Haemopoietic chimera in man after allogeneic (homologous) bone-marrow transplantation. *Brit. Med. J.* **2**, 1633.

- MITCHISON, N.A. (1954) Passive transfer of transplantation immunity. *Proc. Roy. Soc. B* **142**, 72.
- PAGE, A.R., HANSEN, A.E. & GOOD, R.A. (1963) Occurrence of leukemia and lymphoma in patients with agammaglobulinemia. *Blood*, **21**, 197.
- PREHEN, R.T. & MAIN, J.M. (1957) Immunity to methylcholanthrene-induced sarcomas. *J. nat. Cancer Inst.* **18**, 769.
- RACCUGLIA, G. & LANSING, A. (1967) Spleen transplantation in superlethally irradiated dogs. Its role in the search for protector cells. *First Int. Congress of Transplantation Soc.*, Dr. Mathé's Symposium on Bone Marrow Transplantation, Paris, France.
- RIESCO, A. (1970) Five year cancer cure; relation to total amount of peripheral lymphocytes and neutrophils. *Cancer*, **25**, 135.
- ROSENAU, W. & MOON, H.D. (1961) Lysis of homologous cells by sensitized lymphocytes in tissue culture. *J. nat. Cancer Inst.* **27**, 471.
- SNELL, G.D., CLOUDMAN, A.M., FAILOR, E., DOUGLASS, P. & JACKSON, R.B. (1946) Inhibition and stimulation of tumor homoiotransplants by prior injections of lyophilized tumor tissue. *J. nat. Cancer Inst.* **6**, 303.
- SNELL, G.D. & STIMPFLING, J.H. (1966) Genetics of tissue transplantation. *Biology of Laboratory Mouse, Second Edition* (Ed. by E. L. Green), Chapter 24, p. 457. McGraw-Hill Co.
- WALKER, R.I. & FOWLER, I. (1965) Granulocyte inhibition of human peripheral blood lymphocyte growth *in vitro*. *Exp. Cell Res.* **38**, 379.
- WILSON, R.E., HAGER, E.B., HAMPERS, C.L., CORSON, J.M., MERRILL, J.P. & MURRAY, J.E. (1968) Immunologic rejection of human cancer transplanted with a renal allograft. *New Engl. J. Med.* **278**, 479.
- WINN, H.J. (1961) Immune mechanism in homotransplantation. II. Quantitative assay of the immunologic activity of lymphoid cells stimulated by tumor homograph. *J. Immunol.* **86**, 228.
- WOGLOM, W.H. (1929) Immunity to transplantable tumors. *Cancer Rev.* **4**, 129.
- WOODRUFF, M.F.A. & NOLAN, B. (1963) Preliminary observations on treatment of advanced cancer by injection of allogeneic spleen cells. *Lancet*, **ii**, 426.