

Expression of T cell receptors $\alpha\beta$ and $\gamma\delta$ in the ileal mucosa of patients with Crohn's disease and with spondylarthropathy

C. A. CUVELIER*, N. DE WEVER*, H. MIELANTS†, M. DE VOS‡, E. M. VEYS† & H. ROELS* *Department of Pathology, †Department of Rheumatology, and ‡Department of Gastroenterology, University Hospital Ghent, Belgium

(Accepted for publication 1 August 1992)

SUMMARY

The expression of the $\alpha\beta$ and $\gamma\delta$ heterodimer of the T cell receptor (TCR) was studied in normal human ileal mucosa or in ileal biopsies featuring Crohn's disease or acute and chronic spondylarthropathy-related gut inflammation. With an immunohistochemical technique we demonstrated that the increase of mucosal lymphocytes per mm mucosa in Crohn's disease and spondylarthropathy-related ileitis is exclusively due to expansion of the $\alpha\beta^+$ T cell compartment. In Crohn's disease and chronic ileitis observed in some spondylarthropathy patients the $\alpha\beta^+$ T cells were increased amongst intraepithelial lymphocytes (IEL). The lamina propria lymphocytes (LPL) were augmented in all studied inflammatory conditions. The $\gamma\delta^+$ T cells showed no changes in IEL or LPL and their proportions were not altered. They were evenly dispersed throughout the ileal mucosa and did not seem to participate in the inflammatory process. This study confirms that $\gamma\delta$ T cells are a distinct subset in the intestinal mucosa. The increase in $\alpha\beta^+$ T cells suggests augmented mucosal antigen handling and involvement of the major histocompatibility complex in the pathogenesis of spondylarthropathy-related gut inflammation and Crohn's disease.

Keywords T cell receptor Crohn's disease ileitis spondylarthropathy

INTRODUCTION

Foreign antigenic peptides are recognized by T lymphocytes and their CD3 associated $\alpha\beta$ T cell receptor (TCR) in the context of major histocompatibility complex (MHC) molecules. Antigen associated with class II MHC molecules is recognized by CD4⁺ T cells with their CD3 $\alpha\beta$ TCR whereas CD8⁺ T cells pick up antigen associated with class I MHC molecules. A second TCR, the $\gamma\delta$ TCR heterodimer encoded by two rearranging TCR genes, has been discovered on a small number of thymic and peripheral lymphocytes [1–3]. However, it is not yet clear what antigens are recognized by the $\gamma\delta$ TCR. It has been reported that $\gamma\delta$ T cells are activated by mycobacterial antigens and heat shock proteins [4–10].

The intestinal intraepithelial lymphocytes (IEL) are a particular population featuring the CD8⁺ phenotype in more than 80% of IEL [11–14]. In mice it was demonstrated that this subset contains predominantly the $\gamma\delta$ TCR [15–17]. It has been postulated that these cells play a role in autologous surveillance, by removing damaged epithelial cells by recognition of heat shock proteins of homology between prokaryotes and eukaryotes [5,9,18]. However, in human intestinal mucosa the IEL have the $\alpha\beta$ TCR with CD8⁺ phenotype, and of the CD3⁺ IEL, 1–15% have the $\gamma\delta$ TCR [19–21].

Correspondence: C. Cuvelier MD, N. Goormaghtigh Institute of Pathology, University Hospital, De Pintelaan 185, B-9000 Ghent, Belgium.

Previously, we have described mainly asymptomatic gut inflammation in 62% of patients with spondylarthropathy (reactive arthritis and peripheral arthritis in ankylosing spondylitis) [22,23]. The terminal ileum and ileocaecal valve are the most affected sites of inflammation. There are histological and immunohistochemical features of acute and chronic inflammation resembling acute bacterial enterocolitis, although systematic stool culture was always negative, and early or subclinical Crohn's disease [24, 25]. Features like aphthoid ulceration, epithelioid microgranulomas, and pseudopyloric metaplasia were frequent in the latter group [23]. The evolution of the arthritic symptoms correlates with the activity and type of gut inflammation [25–27]. The increased HLA-DR expression observed in actively inflamed mucosa may play a role in the pathogenesis of the clinical expression of spondylarthropathy in genetically predisposed persons [28–30]. The mechanism of both types of inflammation may be that increased (chronic) antigen stimulation of the gut causes T cell activation and lymphoid hyperplasia.

Immunoglobulin G and T cell mediated responses can induce antigen–antibody reactions with the HLA-B27 structure or with B27-associated structures on cells by molecular mimicry. This can result in activation of the complement cascade and cytokine production and elicit inflammatory reactions in tendons and joints.

Because the TCR are the antigen-recognizing elements of the effector cells of the immune system we studied the presence of

TCR in ileal biopsies of patients with spondylarthropathy. As a proportion of patients with spondylarthropathy may have subclinical Crohn's disease [23–31] we also used biopsies of patients with established Crohn's disease in order to compare the TCR in both groups. The autologous surveillance hypothesis would imply that at sites of active inflammation there is a rise in the number of $\gamma\delta^+$ T cells.

MATERIALS AND METHODS

For the study, the approval of the Central Ethical Committee as well as the patient's verbal informed consent were obtained.

Patients

Ileal mucosa of four groups of patients was investigated.

Control patients. In this group patients had ileocolonoscopy because of chronic constipation, spastic colon, colonic polyps or adenocarcinoma. They had no evidence of inflammatory bowel disease or rheumatic diseases and their ileal biopsies featured normal histology. The 20 patients consisted of 12 women and eight men with a mean age of 41 years (range 21–71).

Patients with Crohn's disease. Biopsies of 14 patients were examined. They showed histological features of Crohn's disease with different degrees of inflammatory activity. The patients were six females and eight males with a mean age of 32.3 years (range 12–55). Nine patients were treated with oral sulphasalazine.

Patients with spondylarthropathy and acute gut inflammation. From this group 18 patients were studied. They consisted of 10 females and eight males, mean age 36.5 years (range 12–61). Their biopsies showed acute gut inflammation with granulocytic epithelial infiltration, crypt abscess formation and preserved villous architecture [23].

Ten patients were treated with the non-steroidal anti-inflammatory drugs (NSAIDs) piroxicam or indomethacin.

Patients with spondylarthropathy and chronic gut inflammation. Biopsies of 12 patients (nine women and three men) with a mean age of 27.3 years (range 19–39) were used. The histological examination of their biopsies revealed chronic inflamed gut mucosa. Summarized, the changes represent fused and blunted ileal villi, villous colonic surface, distortion of crypts, increased cellularity in the lamina propria and basal lymphoid aggregates in the propria [23]. In this group eight patients were treated with the NSAIDs piroxicam or indomethacin.

Methods

Tissue staining procedure. Terminal ileal mucosal biopsies freshly obtained during ileocolonoscopy were snap-frozen in isopentane, cooled to -120°C in liquid nitrogen and stored at -70°C until the slides were sectioned.

Serial 5 μm thick frozen sections were mounted on chrome gelatin coated slides. They were air dried and fixed for 10 min in acetone. Then the slides were washed in Tris buffered saline (TBS) at pH 7.6 and incubated for 30 min with the MoAbs anti-Leu-4 (CD3; Becton Dickinson, Mountain View, CA), TCR δ 1, directed against the δ chain of the $\gamma\delta$ TCR, and β F1, MoAb to the β chain of the $\alpha\beta$ TCR (T Cell Sciences, Cambridge, MA), all diluted 1:10. After incubation the slides were washed with TBS for 2 min, treated with 1:50 diluted rabbit anti-mouse IgG (Dakopatts, Glostrup, Denmark) for 30 min and again washed in TBS for 2 min. Then the sections were incubated with the

alkaline phosphatase–anti-alkaline phosphatase (APAAP) complex, diluted 1:50, for 30 min and again washed in TBS. The staining was developed using the Fast Red TR substrate for 12 min. All incubations were carried out in a humid chamber at room temperature.

Quantification of TCR. For each MoAb, the number of stained cells was counted per mm mucosa length in three well-orientated consecutive sections. Therefore an integrating disk turret with graticule system (Carl Zeiss) was put on a standard light microscope and a correction for shrinkage of the biopsy was applied as previously described [24]. The number of IEL and LPL was counted separately.

Statistical analysis. The data were analysed according to the non-parametric χ^2 -test. The rejection level of the null hypothesis was fixed at $P < 0.05$.

RESULTS

The APAAP-stained slides always contained an internal control in the enterocytic brush border which is alkaline phosphatase positive. The data on TCR in IEL and LPL are summarized in Tables 1 and 2. The proportion of $\alpha\beta$ TCR and $\gamma\delta$ TCR in IEL and LPL is expressed as percentage of the total number of CD3⁺ cells. These data are summarized in Table 3.

Intraepithelial lymphocytes

The majority of CD3⁺ IEL possessed the $\alpha\beta$ TCR in normal and inflamed mucosa (Fig. 1a) and 12–16% of the IEL featured the $\gamma\delta$ TCR. Whereas the amount of $\alpha\beta$ TCR was increased amongst IEL in Crohn's disease and chronic ileitis ($P < 0.05$ versus

Table 1. Intraepithelial lymphocytes: number of stained cells (\pm s.d.) per mm ileal mucosa of inflamed and control biopsies

Diagnosis	n	Monoclonal antibodies		
		Anti-CD3	β F1	TCR δ 1
Controls	(20)	23 (\pm 6)	21 (\pm 6)	3 (\pm 1)
Crohn's disease	(14)	32 (\pm 11)	31 (\pm 11)*	4 (\pm 2)
Acute ileitis	(18)	32 (\pm 10)	27.5 (\pm 7)	5 (\pm 2)
Chronic ileitis	(12)	36 (\pm 9)*	33 (\pm 8)*	5 (\pm 2)

* $P < 0.05$ versus controls.

Table 2. Lamina propria lymphocytes: stained cells (\pm s.d.) per mm terminal ileal mucosa in inflamed and control biopsies

Diagnosis	n	Monoclonal antibodies		
		Anti-CD3	β F1	TCR δ 1
Controls	(20)	138 (\pm 31)	128 (\pm 32)	12 (\pm 7)
Crohn's disease	(14)	356 (\pm 95)*	336 (\pm 92)*	23 (\pm 10)
Acute ileitis	(18)	256 (\pm 54)*	243 (\pm 57)*	15 (\pm 10)
Chronic ileitis	(12)	308 (\pm 83)*	292 (\pm 81)*	18 (\pm 7)

* $P < 0.05$ versus controls.

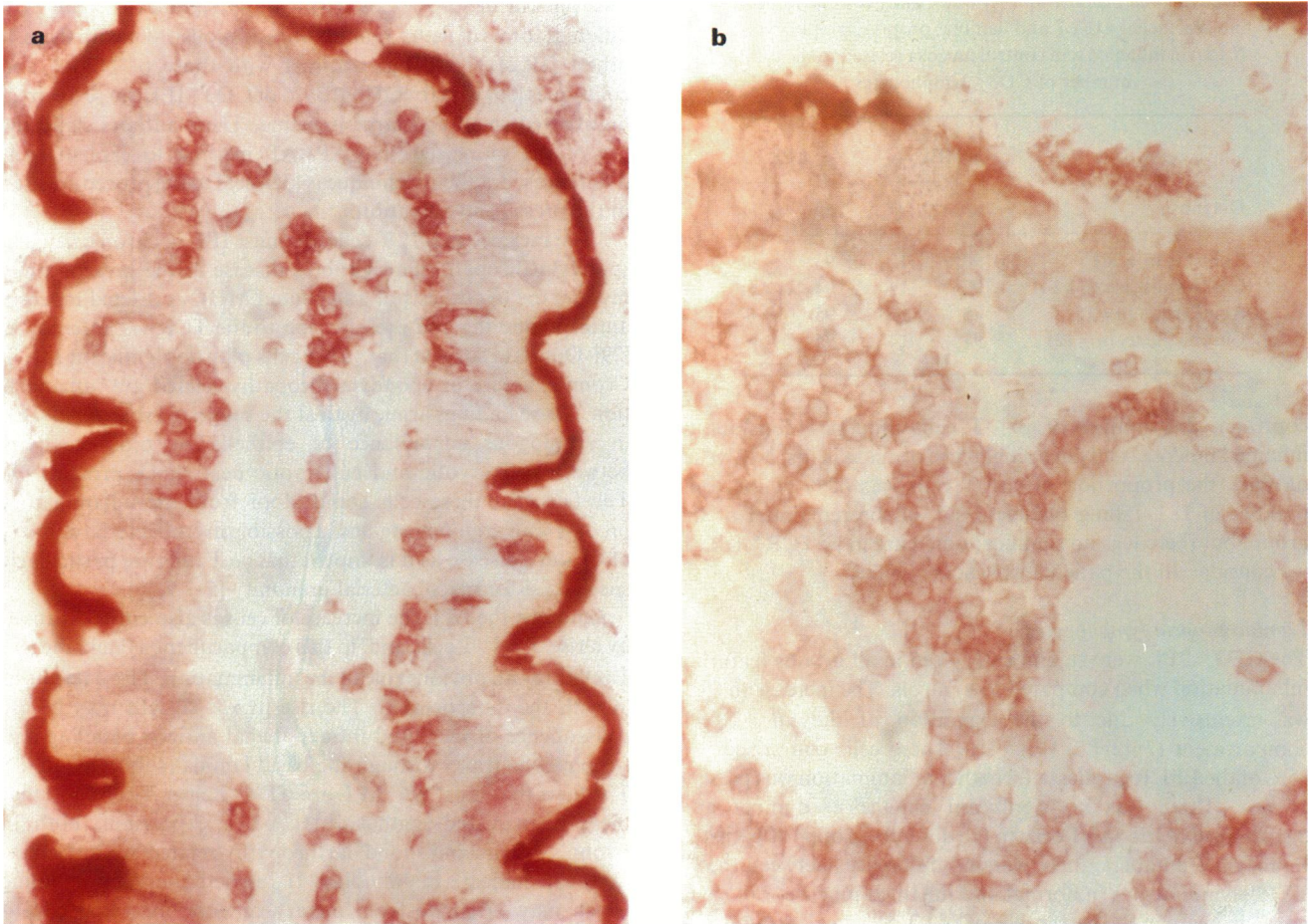


Fig. 1. Cryostat sections stained by the APAAP technique and haematoxylin counterstain: (a) $\alpha\beta$ TCR in normal ileal mucosa: the cells are present intraepithelially and in the lamina propria ($\times 420$). (b) $\alpha\beta$ TCR in chronic inflamed ileal mucosa: abundant cells in lamina propria and in surface and crypt epithelium ($\times 420$).

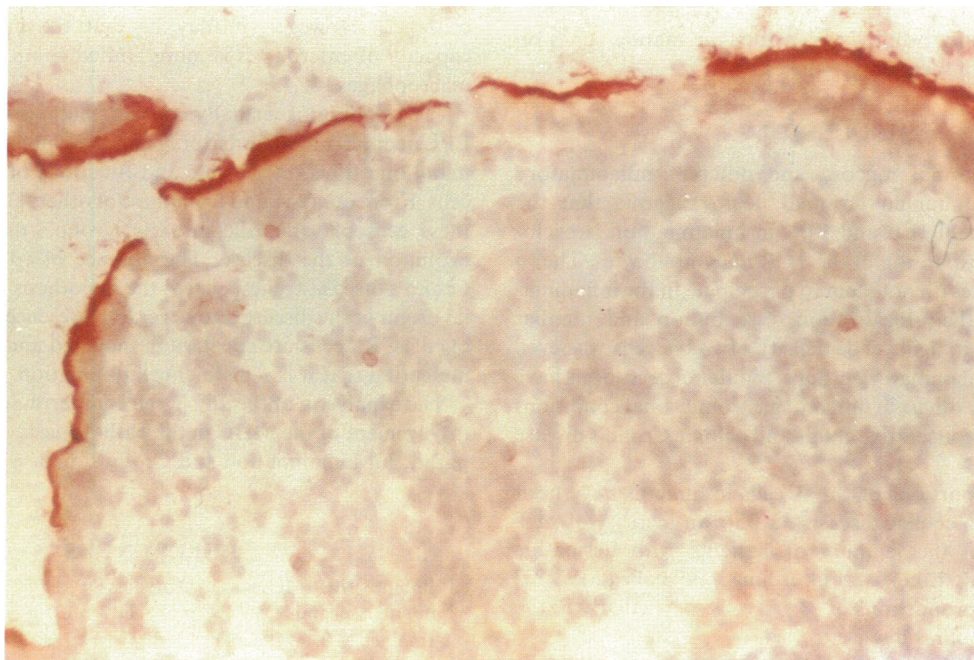


Fig. 2. Cryostat section stained by the APAAP technique and haematoxylin counterstain: dispersed, scarce $\gamma\delta^+$ T cells are present in the lamina propria and in the surface epithelium of inflamed ileal mucosa ($\times 420$).

Table 3. The proportion (%) of $\alpha\beta$ and $\gamma\delta$ TCR in ileal intraepithelial (IEL) and lamina propria lymphocytes (LPL) in inflamed and control mucosa related to the total number of CD3⁺ lymphocytes

Diagnosis	IEL		LPL	
	$\alpha\beta$	$\gamma\delta$	$\alpha\beta$	$\gamma\delta$
Controls ($n=20$)	90	12	93	9
Crohn's disease ($n=14$)	97	14	94	6
Acute ileitis ($n=18$)	86	16	95	6
Chronic ileitis ($n=12$)	91	14	95	6

controls), the number of $\gamma\delta$ ⁺ T cells remained constant in inflamed mucosa. Only in a single case of acute ileitis, a 12-year-old girl, the proportion of $\gamma\delta$ ⁺ T cells was 62% of the total number of IEL falling outside 3 s.d. of the remainder of the group, but there was no significant increase in $\gamma\delta$ TCR⁺ IEL, if we consider all the patients with acute ileitis.

Lamina propria lymphocytes

The CD3⁺ LPL were significantly risen in all groups featuring inflammation when compared to controls. The increase in LPL was exclusively due to the expansion of the $\alpha\beta$ ⁺ T cell compartment ($P < 0.05$) (Fig. 1b). These cells comprised 93–95% of the LPL regardless of whether inflammation was present or not. There was no significant change in number and distribution of the $\gamma\delta$ ⁺ T cells in the different groups of patients. In absolute numbers, there were no differences between the $\gamma\delta$ TCR⁺ lymphocytes in normal and inflamed mucosa, but there was a decrease in the percentage of $\gamma\delta$ ⁺ T cells in all groups with inflammation, because the increase in LPL was due only to a rise in $\alpha\beta$ ⁺ T cells, the number of $\gamma\delta$ ⁺ T cells remaining constant.

The distribution of the $\gamma\delta$ ⁺ T cells was diffuse, without specific topographic localization (Fig. 2). These cells were present intra-epithelially, close to the basal membrane, dispersed in the lamina propria and within the mantle zones or germinal centres of secondary follicles.

DISCUSSION

This study of normal mucosa and different inflammatory conditions in the human terminal ileum suggests that the increased amount of IEL and LPL in inflammation is exclusively due to the expansion of the TCR $\alpha\beta$ lymphocytes. The $\gamma\delta$ TCR⁺ lymphocytes do not seem to participate in the inflammatory process as their localization, distribution and number remain unaltered in ileitis. The density of $\gamma\delta$ ⁺ T cells was even decreased in all inflammatory groups. Similar observations have also been made by others in different gastrointestinal conditions amongst which are ulcerative colitis and colonic Crohn's disease [32,33].

Increased proportions of $\gamma\delta$ ⁺ T cells in humans have been reported in IEL in coeliac disease [32–35]. An increase of $\gamma\delta$ T cells was seen in the jejunum of patients with dermatitis herpetiformis [36]. Like us, Fukushima and colleagues [37] found decreased proportions of $\gamma\delta$ ⁺ T cells, particularly in the distal ileum of Crohn's disease.

Unlike murine IEL where the vast majority bears the $\gamma\delta$ TCR, human IEL feature mostly the $\alpha\beta$ TCR [16,19]. We found $\gamma\delta$ ⁺ T

cells present in 12–16% of IEL without significant changes in different forms of ileitis. Our findings are consistent with these of others [19,21,37,38], but contrast with those of Ullrich and colleagues [39] who found that 39% of CD3⁺ IEL are $\gamma\delta$ ⁺ cells in uninvolved small and large intestine. These authors claim the use of the more sensitive APAAP method to explain their differences, but their technique is identical to the procedure used in the present investigation.

The increase in $\alpha\beta$ ⁺ T cells amongst IEL in chronic ileitis in spondylarthropathy and Crohn's disease in the present study favours the hypothesis of augmented MHC-restricted mucosal antigen handling and presentation to the TCR via enterocytes [29]. Our data suggest that $\gamma\delta$ ⁺ T cells play no significant role in Crohn's disease or spondylarthropathy-related gut inflammation. These findings argue against the suggested role of $\gamma\delta$ ⁺ IEL in autologous surveillance of epithelia by cross-reactivity between prokaryotic and eukaryotic heat shock proteins [9]. The fact that these cells stand aloof from the inflammatory process is an argument against a possible mycobacterial etiology of Crohn's disease as it is known that $\gamma\delta$ T cells are particularly specialized for mycobacterial immunity [5–7,9,40].

Amongst the LPL the increase of cells is also entirely caused by a rise of $\alpha\beta$ ⁺ T cells and, in this compartment as well, the $\gamma\delta$ ⁺ T cells play no obvious role in the inflammation. These results fit in with the data on IEL. The rise in $\alpha\beta$ ⁺ T cells may be the consequence of increased intraepithelial antigen handling and lymphocytic travel through the basal lamina (submitted data). The facts that most $\alpha\beta$ ⁺ LPL are CD4⁺ helper T cells and that there is increased epithelial HLA-DR expression, both in Crohn's disease and spondylarthropathy-related gut inflammation, can indicate mainly class II restricted antigen handling which may originate from dietary or enterobacterial constituents [13,29]. Increased class II molecule expression has been found in ileal and colonic epithelial cells in inflammatory bowel disease [41]. Though the significance of class II molecules on enterocytes is not yet fully established, it has been demonstrated that Ia⁺ human gut epithelial cells can function as accessory cells [42]. However, it may be that the antigen-processing capacity of enterocytes is more limited compared with that of macrophages [41,43].

The finding of virtually constant numbers of $\gamma\delta$ ⁺ IEL and LPL in different inflammatory conditions in human ileum raises many questions on the role and functions of intestinal $\gamma\delta$ ⁺ T cells. From our data and from these of others [32], it appears as if these cells play no role in early Crohn's disease nor in the evolution of the disease. The absence of $\gamma\delta$ ⁺ cells in (early) Crohn's disease argues against the hypothesis of a mycobacterial origin of the disease. However, the presence and proportions of $\gamma\delta$ TCR⁺ cells are constant in inflamed and normal mucosa, indicating that it is a distinct cell population.

The expansion of the $\alpha\beta$ ⁺ T cell compartment emphasizes the involvement of the MHC in the pathogenesis of spondylarthropathic gut inflammation and Crohn's disease.

REFERENCES

- 1 Brenner MB, McLean J, Dialynas DP, *et al.* Identification of a putative second T cell receptor. *Nature* 1986; **322**:145–9.
- 2 Brenner MB, McLean J, Scheft H, *et al.* Two forms of the T-cell receptor γ protein found on peripheral blood cytotoxic T lymphocytes. *Nature* 1987; **325**:689–94.

- 3 Strominger JL. Developmental biology of T cell receptors. *Science* 1989; **244**:943-50.
- 4 Happ MP, Kubo RT, Palmer E, Born WK, O'Brien RL. Limited receptor repertoire in a mycobacteria-reactive subset of $\gamma\delta$ T-lymphocytes. *Nature* 1989; **342**:696-8.
- 5 Haregewoin A, Soman G, Hom RC, Finberg RW. Human $\gamma\delta^+$ T cells respond to mycobacterial heat-shock protein. *Nature* 1989; **340**:309-12.
- 6 Holoshitz J, Koning F, Coligan JE, De Bruyn J, Strober S. Isolation of CD4⁻CD8⁻ mycobacteria-reactive T lymphocyte clones from rheumatoid arthritis synovial fluid. *Nature* 1989; **339**:226-9.
- 7 Janis EM, Kaufmann SHE, Schwartz RH, Pardoll DM. Activation of $\gamma\delta$ T cells in the primary immune response to *Mycobacterium tuberculosis*. *Science* 1989; **244**:713-6.
- 8 Modlin RL, Pirmez C, Hofman FM, *et al.* Lymphocytes bearing antigen-specific $\gamma\delta$ T-cell receptors accumulate in human infectious disease lesions. *Nature* 1989; **339**:544-8.
- 9 Raulat DH. Antigens for $\gamma\delta$ T cells. *Nature* 1989; **339**:342-3.
- 10 Born W, Hall L, Dallas A, *et al.* Recognition of a peptide antigen by heat shock-reactive $\gamma\delta$ T lymphocytes. *Science* 1990; **249**:67-9.
- 11 Cerf-Bensussan N, Jarry A, Brousse N, Lisowska-Grosppierre B, Guy-Grand D, Griscelli C. A monoclonal antibody (HML-1) defining a novel membrane molecule present on human intestinal lymphocytes. *Eur J Immunol* 1987; **17**:1279-85.
- 12 Cerf-Bensussan N, Schneeberger EE, Bhan AK. Immunohistologic and immunoelectron microscopic characterization of the mucosal lymphocytes of human small intestine by the use of monoclonal antibodies. *J Immunol* 1983; **130**:2615-22.
- 13 Cuvelier C, Dierick A-M, Mielants H, De Vos M, Veys E, Roels H. Ileal mucosal mononuclear cells in patients with seronegative spondylarthropathy. *Clin Exp Rheumatol* 1990; **8**:137-43.
- 14 Guy-Grand D, Cerf-Bensussan N, Malissen B, Malassis-Seris M, Briottet C, Vassalli P. Two gut intraepithelial CD8⁺ lymphocyte populations with different T cell receptors: a role for the gut epithelium in T cell differentiation. *J Exp Med* 1991; **173**:471-81.
- 15 Bonneville M, Janeway CA Jr, Ito K, Haser W, Ishida I, Nakanishi N, Tonegawa S. Intestinal intraepithelial lymphocytes are a distinct set of $\gamma\delta$ T cells. *Nature* 1988; **336**:479-81.
- 16 Goodman T, Lefrancois L. Expression of the $\gamma\delta$ T-cell receptor on intestinal CD8⁺ intraepithelial lymphocytes. *Nature* 1988; **333**:855-8.
- 17 Takagaki Y, Decloux A, Bonneville M, Tonegawa S. Diversity of $\gamma\delta$ T-cell receptors on murine intestinal intraepithelial lymphocytes. *Nature* 1989; **339**:712-4.
- 18 Janeway CA, Jones B, Hayday A. Specificity and function of T cells bearing $\gamma\delta$ receptors. *Immunol Today* 1988; **9**:73-6.
- 19 Groh V, Porcelli S, Fabbi M, *et al.* Human lymphocytes bearing T cell receptor $\gamma\delta$ are phenotypically diverse and evenly distributed throughout the lymphoid system. *J Exp Med* 1989; **169**:1277-94.
- 20 Spencer J, Isaacson P. Human T-cell receptor expression. *Nature* 1989; **337**:416.
- 21 Trejdosiewicz LK, Smart CJ, Oakes DJ, Howdle PD, Malizia G, Campana D, Boylston AW. Expression of T-cell receptors TcR 1 (γ/δ) and TcR 2 (α/β) in the human intestinal mucosa. *Immunology* 1989; **68**:7-12.
- 22 Mielants H, Veys E, Cuvelier C, De Vos M, Botelberghe L. HLA-B27 related arthritis and bowel inflammation. Part 2. Ileocolonoscopy and bowel histology in patients with HLA-B27 related arthritis. *J Rheumatol* 1985; **12**:293-8.
- 23 Cuvelier C, Barbatis C, Mielants H, De Vos M, Roels H, Veys E. Histopathology of intestinal inflammation related to reactive arthritis. *Gut* 1987; **28**:394-401.
- 24 Cuvelier C, Mielants H, De Vos M, Veys E, Roels H. Immunoglobulin containing cells in terminal ileum and colorectum of patients with arthritis related gut inflammation. *Gut* 1988; **29**:916-25.
- 25 De Vos M, Cuvelier C, Mielants H, Veys E, Barbier F, Elewaut A. Ileocolonoscopy in seronegative spondylarthropathy. *Gastroenterology* 1989; **96**:339-44.
- 26 Mielants H, Veys E, Joos R, Cuvelier C, De Vos M. Repeat ileocolonoscopy in reactive arthritis. *J Rheumatol* 1987; **14**:456-8.
- 27 Mielants H, Veys E, Cuvelier C, De Vos M. Subclinical involvement of the gut in undifferentiated spondylarthropathies. *Clin Exp Rheumatol* 1989; **7**:499-501.
- 28 Mielants H, Veys EM, Joos R, Suykens S, Cuvelier C, De Vos M. Familial aggregation in seronegative spondyloarthritis of enterogenic origin. A family study. *J Rheumatol* 1986; **13**:126-8.
- 29 Cuvelier C, Mielants H, De Vos M, Veys E, Roels H. Major histocompatibility complex class II antigen (HLA-DR) expression by ileal epithelial cells in patients with seronegative spondylarthropathy. *Gut* 1990; **31**:545-9.
- 30 Mielants H, Veys E, Joos R, Noens L, Cuvelier C, De Vos M. HLA antigens in seronegative spondylarthropathies. Reactive arthritis and arthritis in ankylosing spondylitis: relation to gut inflammation. *J Rheumatol* 1987; **14**:466-71.
- 31 Mielants H, Veys E. The gut in the spondylarthropathies. *J Rheumatol* 1990; **17**:7-10.
- 32 Spencer J, Isaacson PG, Diss TC, MacDonald TT. Expression of disulfide-linked and non-disulfide-linked forms of the T cell receptor γ/δ heterodimer in human intestinal intraepithelial lymphocytes. *Eur J Immunol* 1989; **19**:1335-8.
- 33 Trejdosiewicz LK, Calabrese A, Smart CJ, *et al.* $\gamma\delta$ T cell receptor-positive cells of the human gastrointestinal mucosa: occurrence and V region gene expression in *Helicobacter pylori*-associated gastritis, coeliac disease and inflammatory bowel disease. *Clin Exp Immunol* 1991; **84**:440-4.
- 34 Halstensen TS, Scott H, Brandtzaeg P. Intraepithelial T cells of the TCR γ/δ^+ CD8⁻ and V δ 1/J δ 1⁺ phenotypes are increased in coeliac disease. *Scand J Immunol* 1989; **30**:665-72.
- 35 Viney J, MacDonald TT, Spencer J. Gamma/delta T cells in the gut epithelium. *Gut* 1990; **31**:841-4.
- 36 Savilahti E, Reunala T, Mäki M. Increase of lymphocytes bearing the $\gamma\delta$ T cell receptor in the jejunum of patients with dermatitis herpetiformis. *Gut* 1992; **33**:206-11.
- 37 Fukushima K, Masuda T, Ohtani H, Sasaki I, Funayama Y, Matsuno S, Nagura H. Immunohistochemical characterization, distribution and ultrastructure of lymphocytes bearing T cell receptor γ/δ in inflammatory bowel disease. *Gastroenterology* 1991; **101**:670-8.
- 38 Inghirami G, Zhu BY, Chess L, Knowles DM. Flow cytometric and immunohistochemical characterization of the γ/δ T-lymphocyte population in normal human lymphoid tissue and peripheral blood. *Am J Pathol* 1990; **136**:357-67.
- 39 Ullrich R, Schieferdecker HL, Ziegler K, Riecken EO, Zeitl M. $\gamma\delta$ T cells in the human intestine express surface markers of activation and are preferentially located in the epithelium. *Cell Immunol* 1990; **128**:619-27.
- 40 Kabelitz D, Bender A, Schondermaier S, Schoel B, Kaufmann SHE. A large fraction of human peripheral blood γ/δ^+ T cells is activated by *Mycobacterium tuberculosis* but not by its 65-kD heat shock protein. *J Exp Med* 1990; **171**:667-79.
- 41 Mayer L, Eisenhardt D, Salomon P, Bauer W, Plous R, Piccinini L. Expression of class II molecules on intestinal epithelial cells in humans. Differences between normal and inflammatory bowel disease. *Gastroenterology* 1991; **100**:3-12.
- 42 Mayer L, Schlien R. Evidence for function of Ia molecules on gut epithelial cells in man. *J Exp Med* 1987; **166**:1471-83.
- 43 Bland PW, Whiting CV. Antigen processing by isolated rat intestinal villus enterocytes. *Immunol* 1989; **68**:497-502.