

CHILDREN'S MERCY HOSPITAL

Infant Pulmonary Hemorrhage in a Suburban Home with Water Damage and Mold (*Stachybotrys atra*)

Susan M. Flappan, Jay Portnoy, Patricia Jones, and Charles Barnes

Department of Allergy, Asthma, and Immunology, Children's Mercy Hospital, Kansas City, Missouri, USA

The American Academy of Pediatrics recently issued guidelines regarding the potential toxic effect of indoor molds. We now report another case of an infant with pulmonary hemorrhage whose residential environmental assessment revealed the presence of the toxigenic mold *Stachybotrys atra*. We used a questionnaire to identify environmental factors that could predispose the home to fungal contamination. We collected air samples from multiple locations in the home that we felt would reflect areas of relevant exposure. Surface samples were collected with a piece of transparent tape for semiquantitative measurement of spores present. We classified spores into their respective genera based on shape, size, and color. We also measured mycotoxin levels. Air sampling revealed significantly elevated total spore counts in the patient's bedroom and in the attic. *Aspergillus/Penicillium* species were predominant. *Stachybotrys* spores were found in the air sampled in the patient's bedroom, as well as from surfaces sampled in the patient's closet and the attic ceiling. Additionally, a small patch of *Stachybotrys*-contaminated area in the closet ceiling was sent for mycotoxin analysis. This material proved to be highly toxigenic. As the link between the presence of *Stachybotrys* in the home and pulmonary hemorrhage in infants increases, further efforts should be made to educate physicians, health care providers, and new parents about the potential toxic effects of this mold. **Key words:** floods, fungus, idiopathic pulmonary hemorrhage, IPH, mold exposure, mycotoxins, *Stachybotrys*, toxic mold, tricothecenes, water damage. *Environ Health Perspect* 107:927-930 (1999). [Online 20 October 1999] <http://ehpnet1.niehs.nih.gov/docs/1999/107p927-930flappan/abstract.html>

Pulmonary hemorrhage is a relatively infrequent condition in infants that can result in significant morbidity and mortality (1). Its diagnosis is based on the identification of alveolar hemosiderin-laden macrophages (iron-staining white cells) from bronchoalveolar lavage or biopsy. A cluster of 10 cases of idiopathic pulmonary hemorrhaging (IPH) occurred during 1993 and 1994 at Rainbow Babies and Children's Hospital in Cleveland, Ohio. In the decade preceding these years, there had been only 3 cases of IPH at the same hospital (2). An examination of the circumstances that may have led to pulmonary hemorrhage in these infants suggested a link between IPH and water damage in the patients' homes. Higher exposures to fungi, and particularly to *Stachybotrys atra*, were found in case homes versus control homes. (3) Ninety percent of the patients in the study were also exposed to tobacco smoke. The residences were an average of 75 years old and most were in poor repair, suggesting that socioeconomic factors may predispose patients to this type of fungal exposure. (4).

We now report another case of pulmonary hemorrhage in an infant who resided in a newer, middle-class home located in the

suburbs. Environmental testing of the residence was conducted a few days after the child was hospitalized. This allowed evaluation of the home at nearly identical conditions as those present before the patient's hospitalization.

Case Presentation

A 1-month-old infant presented to the emergency department at Children's Mercy Hospital, Kansas City, Missouri, with acute onset of respiratory distress and shock. He was a full-term, healthy baby at birth and had had no prior symptoms preceding this sudden illness. That morning he had vomited at home, became very fussy, and was difficult to console. By the afternoon he was breathing rapidly and was grunting. On arrival at the hospital he was pale and cyanotic. He had developed nasal flaring and intercostal retractions. He had a blood pressure of 57/17 and a rectal temperature of 36.3°C. He was also lethargic and nonresponsive to pain. His extremities were cool and mottled.

The patient's condition deteriorated over the next 30 min. Due to progressive respiratory distress, an endotracheal tube was inserted without trauma. A moderate amount of bright

red blood was suctioned from the tracheal tube immediately after insertion and several times thereafter. Bronchoalveolar lavage demonstrated that 2% of the macrophages contained iron-positive material, an indication of hemosiderosis (white blood cells engulfing red blood cells). Hemosiderosis indicates long-term bleeding and does not result from an acute episode of pulmonary hemorrhaging (2).

Other laboratory test results showed an elevated white blood cell count (30,400/m³) with no left shift, a decreased hemoglobin and hematocrit (10.1 g/dL and 29.3, respectively); an elevated prothrombin time (17.7 sec; normal 10-14.3 sec); and an elevated platelet count of 457,000/dL. Bacterial cultures collected from the blood, urine, cerebrospinal fluid, and tracheal aspirate were all negative. This made a diagnosis of disseminated intravascular coagulation due to septicemia very unlikely. Viral cultures of the nasopharynx and rectum were also negative. A supine chest radiograph showed diffuse bilateral alveolar densities throughout the lungs with no pleural effusions or pneumothorax. Milk-specific IgE was negative.

Because the attending physician was aware of the information relating pulmonary hemorrhage to fungal exposure (5), the environmental health specialist from the allergy section was requested to assess the patient's home for *Stachybotrys*. Supportive care was provided and the infant recovered; he subsequently was discharged to live in his maternal grandparents' home until the paternal grandparents could address environmental concerns raised by this investigation.

Address correspondence to S.M. Flappan, Children's Mercy Hospital, Department of Allergy and Immunology, 2401 Gillham, Kansas City, MO 64108 USA. Telephone: (816) 234-3097. Fax: (816) 346-1301. E-mail: Sflappan@cmh.edu

The authors thank K. Wible and M. Sheffield, Children's Mercy Hospital; B. Jarvis, University of Maryland; D. Dearborn, RB&C Hospital, Cleveland, Ohio; and R. Etzel, American Academy of Pediatrics for their assistance.

This study was supported by Children's Mercy Hospital; KB Richardson Fund.

Received 19 July 1999; accepted 27 August 1999.

Methods

A home visit by a certified industrial hygienist was performed 4 days after the infant presented to the emergency department. During that visit, responses of family members to a questionnaire were used to identify potential environmental factors that could predispose the home to fungal contamination.

Air samples were obtained using an Allergenco MK-3 volumetric spore trap (Allergenco/Blewstone Press, San Antonio, TX) (Figure 1). The device was set to collect 10-min air samples at 15 L/min in the infant's bedroom, the bedroom closet, the attic space above the closet, the family room, and the kitchen. We considered these locations to be relevant to the patient's exposure. We collected the samples during a cold period in the winter when the outdoor mold count was negligible. The Allergenco MK-3 drew airborne particles through a small opening (1.1 × 14.5 mm) in its lid. Particles impacted onto a grease-coated slide positioned in a slide carrier underneath the opening. A line of particle deposition formed called a trace. After each sampling period, the slide carrier automatically advanced to a new position to allow a new trace to form. Thus, each trace represented a room or location sampled. The slide was stained with Calberla's (6) in the laboratory and read microscopically at 1000× magnification. Counts per cubic meter were calculated based on the number of spores observed in five horizontal sweeps of a trace.

We collected surface samples with transparent cellophane tape (tape prep) for semiquantitative measurement of mold contamination. All spores were classified into their respective genera based on shape, size, and color.



Figure 1. Photograph of the Allergenco MK-3 air sampler (Allergenco/Blewstone Press, San Antonio, TX). Airborne particulates drawn through a small opening (1.1 × 14.5 mm) in the lid impact onto a microscope slide underneath. Both viable and nonviable spores are detected by direct microscopy.

Results

The infant's exposure occurred at the paternal grandparents' house where he shared a small bedroom with his mother. Water damage to the house occurred when shingles on the roof, which had recently been replaced and improperly installed, were damaged during a hail storm. This allowed rainwater to enter the attic and the baby's bedroom closet located directly below the leak. As a consequence, fungal contamination developed on the attic ceiling and in the closet (Figure 2).

Airborne spore counts were taken in the five locations shown in Table 1. *Stachybotrys* spores were observed in the air collected from the infant's bedroom. Four surface samples taken from water-damaged building materials also contained *Stachybotrys* spores: one from the closet ceiling, one from the closet door, and two from black stains on the attic ceiling. Several other microbials were also identified from visually contaminated sites including *Aspergillus/Penicillium*, *Memnoniella*, *Alternaria*, ascospores, *Cladosporium*, *Chaetomium*, *Torula*, and bacterial bacilli.

We collected additional surface samples of dust in the infant's bedroom to determine the extent of spore migration from the original sites of colonization. One sample taken from the bedroom supply vent contained a moderate amount of *Stachybotrys*. *Stachybotrys* was also present in dust from the infant's crib and mattress (after the sheets had been removed). Other surface samples from the room fan (free-standing, portable electric fan), the miniblinds, and the television contained an assortment of fungal spores including *Cladosporium*, *Periconia*, ascospores, *Aspergillus/Penicillium*, *Chaetomium*, *Alternaria*, and *Myxomycetes* species, but no *Stachybotrys* was observed. A tape prep collected from the washable electrostatic furnace filter was heavily contaminated with *Aspergillus/Penicillium* species, and also a rare *Stachybotrys* spore was observed. The detection of *Stachybotrys* on the furnace filter indicated that these spores had entered into the ventilation system. The *Stachybotrys* spores could be distributed to

other parts of the home via the ductwork unless the furnace filter captured them from the circulating air.

We used a sterile swab to collect samples for culture from a small area of closet wall-board where *Aspergillus/Penicillium* species had been detected. This swab was then inoculated onto blood and malt extract agar and incubated at room temperature. Our goal was to further differentiate the *Penicillium/Aspergillus* genera into more specific classifications. We observed growth of two types of *Penicillium* species, gram-negative rods, and *Rhodotorula* yeast.

To determine if the *Stachybotrys* spores were toxigenic, we removed a 10-cm² area of contaminated closet ceiling after thoroughly wetting it down to prevent aerosolization of spores. This specimen was sealed in a bag and shipped to Bruce Jarvis at the University of Maryland for mycotoxin analysis by HPLC. High quantities of several potent tricothecenes were detected in this sample. The mycotoxins Roridin L-2, Roridin E, and Satratoxin H were measured at levels of 0.5, 0.7, and 3.2 ng/cm², respectively.

Environmental Remediation

Our primary recommendation was that the cause of water entry, the leak in the roof, should be repaired. We also suggested that visible mold and mold-contaminated items should be disinfected and/or removed in accordance with the *Stachybotrys* remediation guidelines written by the New York City Department of Health (7). A third suggestion was that the family should filter, clean, vacuum, and dust all surfaces and items which might contain migrant spores, including the ventilation system. We strongly advised this family to prevent the infant from entering the contaminated home until the cleanup was complete because many infants diagnosed with *Stachybotrys*-associated pulmonary hemorrhage continue to have hemosiderosis for up to 6 months after hospital release (2). We also emphasized that the infant should not be exposed to environments contaminated with tobacco smoke. Ideally, a follow-up survey should be done to confirm that fungal contamination has been

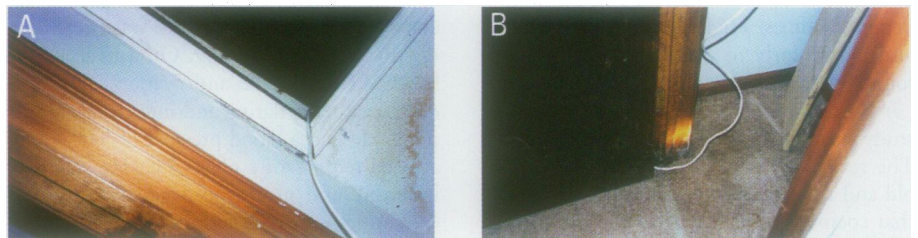


Figure 2. Photographs of the (A) ceiling and (B) floor of the closet in the child's bedroom. Stains indicate water damage from rain entry. *Stachybotrys* mold growth was found; other microbials were also present, including *Chaetomium*, *Cladosporium*, and *Aspergillus/Penicillium* mold spores; *Rhodotorula* yeast; and gram-negative bacteria.

resolved before an infant returns to an affected environment. Because this family elected to have the infant move to a different home, follow-up measurements were not performed. Although the threat of IPH appears to decline after 1 year of age (8), it is still preferable for the infant to avoid mold and smoke-contaminated environments after that time.

Discussion

To determine if the Cleveland cluster of 10 IPH cases during 1993 and 1994 was related to environmental exposures, the Centers for Disease Control and Prevention (CDC) conducted a case-control study (4). In that study, the Cleveland cases were matched with 30 controls having similar zip codes (lived in similar areas) and ages. Air and surface samples from rooms where the infants spent the most time were collected and analyzed. Mean total spore and *Stachybotrys atra* spore counts from air samples were found to be significantly elevated in case homes as compared to control homes. Surface samples in case versus control homes also had much higher concentrations of *Stachybotrys* spores. Etzel et al. (4) concluded that infants who experienced pulmonary hemorrhaging and hemosiderosis were 16 times more likely than controls to have lived in homes with water damage due to roof leaks, plumbing leaks, or flooding. The authors identified no differences between cases and controls with regard to pesticide exposure, infant products used, or cocaine use of family members. Exposure to tobacco smoke increased the odds of pulmonary hemorrhaging by 8-fold (4).

There are a number of similarities between the Cleveland cluster of IPH cases (4,9) and the case study reported here. Our patient lived in a home with water damage, in this case due to a roof leak. In both the Cleveland homes and this case study, mold damage had not been cleaned up before environmental testing, although there was a longer time interval in Cleveland between occurrence of hemorrhage and the environmental survey. As in the Cleveland cluster of case homes, this home had elevated levels of airborne spores, with the highest concentration found in the patient's bedroom. Airborne *Stachybotrys* was among the spores detected. As was true for the Cleveland homes, the patient's home revealed significant amounts of *Stachybotrys* from surface samples. In both instances, several other microorganisms were present in addition to *Stachybotrys*, raising the question of whether IPH may be caused by interactive or synergistic effects of a combination of biocontaminants and/or their metabolites (9). Mycotoxin analysis of the *Stachybotrys*-contaminated plaster from the closet ceiling in this case showed a high level

Table 1. Air sample spore counts per cubic meter by genus in five different rooms.

	Patient's bedroom	Closet of bedroom	Attic above bedroom	Family room	Kitchen
Total spores/m ³	13,440	4,368	2,856	2,520	1,512
A/P sp.	11,256	4,032	2,352	2,184	1,092
<i>Cladosporium</i>	1,512	252	336	252	168
<i>Alternaria</i>	0	0	84	84	0
Ascospores	168	84	84	84	84
<i>Periconia</i>	84	0	0	0	0
<i>Chaetomium</i>	0	84	0	0	0
<i>Stachybotrys</i>	420	0	0	0	0

A/P sp., *Aspergillus*/*Penicillium* species.

of toxicity, as was true of isolates taken from air and surface samples in the Cleveland homes (10).

Additional similarities between the Cleveland cluster of cases and this reported case include *a*) the ages of the infants (4–16 weeks); *b*) bottle-feeding infants a cow's milk-based formula; *c*) tobacco smoking by the parents; *d*) red blood cell profiles consistent with normochromic, normocytic anemia; *e*) chest X rays showing diffuse bilateral infiltration consistent with pulmonary hemorrhaging; and *f*) no other sources of bleeding. Microbiology cultures of the blood, urine, and bronchoalveolar lavage from almost all of the Cleveland infants were negative for bacterial, fungal, and viral pathogens, as was true for this case (4). The majority of Cleveland infants had signs of respiratory failure before signs of internal pulmonary bleeding became apparent (2), as happened in our case study.

There are also some important differences between our patient and those in the Cleveland cluster. The 10 infants in Cleveland were all African American and lived in an inner-city area. Their residences were an average of 75 years old and many were in poor repair (4). In contrast, our infant was white and he lived in a 15-year-old suburban home that was in relatively good repair. Water damage to our patient's home was a result of faulty workmanship, not because of neglect. This demonstrates that water contamination with resultant *Stachybotrys* contamination can occur in any type of home and that it is not a condition limited to the inner city. A moisture problem that is not properly cleaned up in a reasonable amount of time can lead to indoor mold growth regardless of the home's age or location.

Stachybotrys atra is a fungus that originates in soil and plant debris, and it has a wide geographic distribution. To grow in indoor environments, *Stachybotrys* requires long-term water saturation of cellulose-based material such as paper, cardboard, wood, plasterboard (wallboard), or jute-backed carpet. Plumbing leaks, roof leaks, or rainwater flooding into basements can provide the needed moisture for this mold to thrive.

Stachybotrys spores are sticky while still moist, but the fungus becomes powdery when the substrate dries out. The spores can become aerosolized if disturbed (2). Their small size and ellipsoid shape allow them to be inhaled and to reach the lower respiratory tract (Figure 3) (2,11).

Stachybotrys was first associated with a toxic response in animals in Eastern Europe and the Ukraine in the 1930s. Horses consuming contaminated straw or hay showed shock, dermal necrosis, leukopenia, nervous disorders, and death. This condition was later termed stachybotryotoxicosis. Since then, similar problems have been reported throughout the world, primarily in Eastern Europe (12).

The first reported cases of stachybotryotoxicosis in people occurred in the 1940s. Russians who handled tainted hay or slept on straw-filled mattresses experienced dermatitis, pain, and inflammation of the mucous membranes; burning nasal passages; tightness of chest; bloody rhinitis; cough; fever; headache; and fatigue (12).

From the 1950s to the 1980s, more papers were published on the topic, but few reports identified *Stachybotrys* in homes or buildings. In 1986, Croft et al. (13) reported an outbreak of mycotoxicosis in a Chicago home with chronic moisture problems. Extracts of mold-contaminated materials from this residence were shown to be highly toxic to test animals. After the mold problems had been corrected, the multisystem symptoms (headaches, sore throats, hair loss, flu symptoms, diarrhea, fatigue, dermatitis, severe leg pains, malaise, and depression) of the family resolved (13).

There have been other reports regarding the relationship between *Stachybotrys* and health effects to humans. In a controlled study, Johanning et al. (14) compared chronically exposed office workers to nonexposed office workers. Significant differences were found between exposed employees ($n = 53$) and controls ($n = 21$) in regard to lower respiratory, dermatologic, eye, chronic fatigue, and immune system symptoms (14).

Many studies have demonstrated that *Stachybotrys atra* is capable of producing

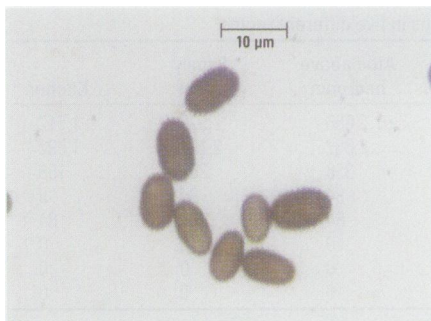

Figure 3. *Stachybotrys* spores (at 1000× magnification) are ellipsoid in shape, are 4–6 μm × 7–12 μm in size, and have an aerodynamic diameter of 5 μm (10). Particles with aerodynamic diameters < 7 μm can have appreciable (> 9%) alveolar deposition (11).

potent tricothecene mycotoxins (10,12–17). These include the macrocyclic tricothecenes Roridin E, Roridin L-2, Satratoxin H, and Satratoxin G, all of which are potent protein synthesis inhibitors and highly cytotoxic to eukaryotic cells. Experimental laboratory animals have shown physiologic effects similar to those observed in farm animals with stachybotrytoxicosis. Tricothecenes are thought to be the primary reason for the health problems. *Stachybotrys* spores are also capable of producing spirolactones, spirolactams, and cyclosporin, mycotoxins with immunosuppressant effects (10). Infants may be especially susceptible to the effects of spore-borne mycotoxins due to their high breathing rate, immature lungs, and rapid growth. Exposure to tobacco smoke may serve to augment overt expression of pulmonary bleeding.

A question that remains to be answered is how exposure to *Stachybotrys* can lead to IPH or other health symptoms if so few spores are actually airborne. A number of possibilities have been suggested, including the presence of antigens or mycotoxins in the air that are not associated with intact spores, volatile organics, or high numbers of spores dispersed intermittently. The latter

possibility, that spores were dispersed intermittently, is supported in this case study because there was an electric fan in our patient's bedroom. Fans may promote greater dispersal of spores, making them available for inhalation and human contact. Over 87% of the Cleveland cases also had electric room fans (9).

Conclusion

From 1993 to 1998, a total of 37 cases of IPH were found in the Cleveland area. Twelve of these infants died. Another 138 cases have been reported to the CDC from all over the country in that same period (2). In June 1998 the American Academy of Pediatrics (AAP) published an article warning that infants under 1 year of age should not be exposed to chronically mold-contaminated indoor environments (5). The AAP recommended that if an infant presents with symptoms of IPH, parents should be questioned about water damage in the home. The AAP recommended that if an infant dies suddenly from an unknown cause, an autopsy that includes Prussian blue staining of lung tissue should be performed to check for hemosiderin-laden macrophages (5).

With these recent AAP recommendations, the medical community has become more aware of the association between exposure to *Stachybotrys* mold and the incidence of IPH. However, cause and effect have yet to be firmly established. As more cases of IPH are documented throughout the country, the correlation with *Stachybotrys* exposure may be strengthened. It is important that this information be passed on to the general public in a timely manner, with special emphasis given to parents of young infants, physicians, and hospital personnel.

REFERENCES AND NOTES

1. Acute pulmonary hemorrhage among infants—Chicago, April 1992–November 1994. *Morb Mortal Wkly Rep* 44:67,73–74(1995).
2. Dearborn DG, Yike I, Sorenson WG, Miller MJ, Etzel RA.

An overview of the investigations into pulmonary hemorrhage among infants in Cleveland, Ohio. *Environ Health Perspect* 107(suppl 3):495–499 (1999).

3. Update: pulmonary hemorrhage/hemosiderosis among infants—Cleveland, Ohio, 1993–1996. *Morb Mortal Wkly Rep* 46:33–35 (1997).
4. Etzel RA, Montana E, Sorenson WG, Kullman GJ, Allan TM, Dearborn DG, Olson DR, Jarvis BB, Miller JD. Acute pulmonary hemorrhage in infants associated with exposure to *Stachybotrys atra* and other fungi. *Arch Pediatr Adolesc Med* 152:757–762 (1998).
5. Toxic effects of indoor molds. American Academy of Pediatrics. Committee on Environmental Health. *Pediatrics* 101:712–714 (1998).
6. Cage B, Schreiber K, Barnes C, Portnoy J. Evaluation of four bioaerosol samplers in the outdoor environment. *Ann Allergy* 77(1):1–7 (1996).
7. New York City Department of Health. Guidelines on Assessment and Remediation of *Stachybotrys atra* in Indoor Environments. New York:New York City Department of Health, 1993.
8. U.S. EPA. Potential Association between Indoor Mold Growth and Pulmonary Hemorrhage in Infants. Washington, DC:U.S. Environmental Protection Agency, 1997.
9. Montana E, Etzel RA, Allan T, Horgan TE, Dearborn DG. Environmental risk factors associated with pediatric idiopathic pulmonary hemorrhage and hemosiderosis in a Cleveland community. *Pediatrics* 99:E5 (1997).
10. Jarvis BB, Sorenson WG, Hintikka EL, Nikulin M, Zhou Y, Jiang J, Wang S, Hinkley S, Etzel RA, Dearborn D. Study of toxin production by isolates of *Stachybotrys chartarum* and *Memnoniella echinata* isolated during a study of pulmonary hemosiderosis in infants. *Appl Environ Microbiol* 64:3620–3625 (1998).
11. ACGIH. 1998 TLVs and BEIs: Threshold Limit Values for Chemical Substances and Physical Agents; Biological Exposure Indices. Cincinnati, OH:American Conference of Governmental Industrial Hygienists, 1998.
12. Nelson B. *Stachybotrys chartarum*, the toxic indoor mold. St. Paul, MN:The American Phytopathological Society, 1999. APSnet Plant Pathology On-line. Available: <http://www.scisoc.org/feature/stachybotrys/> [cited 28 February 1999].
13. Croft W, Jarvis BB, Yatawara SC. Airborne outbreak of tricothecene toxicosis. *Atmos Environ* 20:549–552 (1986).
14. Johanning E, Biagini R, Hull D, Morey P, Jarvis B, Landsbergis P. Health and immunology study following exposure to toxigenic fungi (*Stachybotrys chartarum*) in a water-damaged office environment. *Int Arch Occup Environ Health* 68:207–218 (1996).
15. Andersson MA, Nikulin M, Koljalg U, Andersson MC, Rainey F, Reijula K, Hintikka EL, Salkinoja-Salonen M. Bacteria, molds, and toxins in water-damaged building materials. *Appl Environ Microbiol* 63:387–393 (1997).
16. Nikulin M, Reijula K, Jarvis BB, Veijalainen P, Hintikka EL. Effects of intranasal exposure to spores of *Stachybotrys atra* in mice. *Fundam Appl Toxicol* 35:182–188 (1997).
17. Nikulin M, Reijula K, Jarvis BB, Hintikka EL. Experimental lung mycotoxicosis in mice induced by *Stachybotrys atra*. *Int J Exp Pathol* 77:213–218 (1996).

THE LATEST WORD ON ENVIRONMENTAL HEALTH
AT YOUR FINGERTIPS.



<http://ehis.niehs.nih.gov/>

VISIT US ON THE WEB TODAY!