

Histogenesis of Pancreatic Carcinogenesis in the Hamster: Ultrastructural Evidence

by Bojan Flaks*

Pancreatic carcinogenesis in the Syrian hamster, induced by β -oxidized derivatives of *N*-nitroso-di-*n*-propylamine, constitutes a valuable model of human cancer of the exocrine pancreas. In both species the majority of tumors are adenocarcinomas: superficially, on the basis of their histological appearance, these appear to be ductal in origin. However, sequential analysis, by electron microscopy, of the development of pancreatic neoplasia in the hamster model indicates that acinar cells may participate in the histogenesis of "ductal" adenomas and carcinomas. Acinar cells appear to undergo changes in differentiation, including pseudoductular transformation, giving rise to a new population of cells that resemble ductular or centroacinar types. This new population may then proliferate to form, first, cystic foci and subsequently cystadenomas and adenocarcinomas. Mucous metaplasia appears to develop at late stages of tumor development. Although the participation of ductular and centroacinar cells in pancreatic carcinogenesis cannot be excluded, very few tumors arise from the ductal epithelium.

It is possible that some human pancreatic adenocarcinomas may also have their origin from dysplastic acinar cells, by analogy with the hamster model: focal acinar dysplasia being common in human pancreatic cancer patients.

Introduction

The purpose of this review is to consider the histogenesis of experimentally induced tumors of the hamster exocrine pancreas, in the light of morphological evidence arising largely from electron microscope studies, and to attempt to relate it to other animal models as well as to the human disease.

The principal spur to the development of experimental models of pancreatic carcinogenesis has been the dramatic and continuing increase in the prevalence of human pancreatic cancer in industrial societies over recent decades (1-7). The human disease carries a poor prognosis (7-9), mainly due to the difficulty of early detection. It appears to be associated with environmental factors and industrialization (10,11). Although various chemical carcinogens have been thought to be possible causative agents (12,17), and both dietary habits (18) and cigarette smoking (3,15,18,19) may be contributory factors, it has not proved possible to attribute the high incidence of pancreatic cancer to any specific cause (7,20).

Ideally, an animal model of the human disease should closely parallel the latter with respect to its biological behavior, morphology and histogenesis.

Histogenesis of Human Pancreatic Cancer

Tumors of the human exocrine pancreas were classified by Ewing in 1919 (21) as either "cylindrical cell carcinoma" or "carcinoma simplex." On the basis of their histological appearance he considered that these arose from ductal and acinar cells, respectively. Subsequent classification became more elaborate (22-25). By far the greatest proportion of human nonendocrine pancreatic tumors are classified as adenocarcinomas (25), corresponding to Ewing's "cylindrical cell carcinomas." Although Baylor and Berg (24) were cautious about the histogenesis of these tumors, most authors have asserted that they originate from the pancreatic ducts (22,25,26), largely owing to the histological similarities between their epithelia. Evidence considered to support this view includes the presence within such tumors of mucin-secreting cells (26,27) and observations of atypical hyperplasia of ductal epithelium (25,28) and goblet cell metaplasia (25,26) in the uninvolved pancreatic tissue of pancreatic cancer patients. However, such ductal lesions have been thought, instead, to be secondary to obstruction of the ducts by tumors (29). Furthermore, Walters (30) has observed goblet cell metaplasia in pancreatic ductules and centroacinar cells. Mucinous and eosinophilic metaplasia of these pancreatic elements in man have been suggested by Pour and his collaborators (31) to be related to pancre-

*Department of Pathology, University of Bristol Medical School, Bristol, England.

atic tumorigenesis. Thus, a ductular rather than an exclusively ductal origin of pancreatic adenocarcinomas came to be envisaged.

While acinar cell carcinoma of the pancreas is considered to be relatively rare in man (23,25,32), some authors have reported that it may account for up to 15% of the pancreatic exocrine tumors in their surveys (22, 28,33). Additionally, mixed acinar-ductal carcinomas are known (22,26,32), complicating the question of histogenesis. Longnecker and his collaborators (34-36) have demonstrated the presence of multiple foci and nodules of dysplastic acinar cells in a substantial proportion of patients with pancreatic adenocarcinoma. Electron microscope studies of human pancreatic cancer, which might be expected to shed some light on their histogenesis, are sparse and most have described acinar cell tumors (37-39). However, a recent fine structural study of a human cystadenocarcinoma showed it to be of acinar type (40). The authors noted the likelihood that prior to the use of thin plastic sections or electron microscopy such neoplasms would have been classified as mucinous or serous adenocarcinomas (of ductal origin).

Clearly, conventional histological techniques alone are not adequate to establish unequivocally the ductal origin of all human pancreatic adenocarcinomas and the possibility has not been excluded that ductular, centro-acinar or even acinar cells may play a role in the histogenesis of some of these neoplasms. The sequential analysis of neoplastic development in the pancreas that is necessary for determination of the histogenesis of tumors is not practicable in man and therefore requires suitable experimental models.

Animal Models

Experimental pancreatic carcinogenesis was the subject of an excellent review in 1979 by Reddy, Scarpelli and Rao (41), who summarized the development of several animal models. The major available models currently utilize the rat, guinea pig and Syrian hamster.

Rat

In the rat, pancreatic tumors can be induced by various carcinogens, including 4-hydroxyaminoquinoline-1-oxide (HAQO) (42), azaserine (43-45) and nafenopin (47) and also 7,12-dimethylbenz[a]anthracene (DMBA) when this agent is directly implanted into the pancreas (48). There has been little controversy surrounding the histogenesis of most of these rat carcinomas: they appear to be of acinar cell origin. As a result, their comparability with the human disease is not immediately evident. However, Longnecker and his collaborators (45,46) have drawn attention to the fact that, while most azaserine-induced rat pancreatic tumors are pure acinar adenocarcinomas of varying degrees of differentiation, a minority are mixed tumors with ductal or cystic elements. Thus, as Longnecker noted, the spectrum of rat pancreatic neoplasia overlaps that of

man. In the rat, focal acinar dysplasias precede the development of pancreatic carcinomas (43,46). This is of particular interest in the light of Longnecker's findings of similar lesions in the human pancreas. Shinozuka and his co-workers (49) observed that atypical acinar cell nodules induced by HAQO showed fine structural changes indicative of partial loss of differentiation and suggested that further alteration would result in the development of tumors totally without acinar characteristics.

At first, the rat pancreatic tumors induced by DMBA were reported by Dissin and his collaborators (48) to resemble those of man in being adenocarcinomas with pronounced ductal characteristics. DMBA in addition induced ductal atypia and hyperplasia; however acinar and "ductular" hyperplasia were also present in a few animals. Furthermore, Bockman and his co-workers (50), in an electron microscope study of DMBA-induced adenocarcinomas, observed the presence within them of cells with distinctive acinar cell characters, casting considerable doubt upon their ductal origin. Subsequently, Bockman and his colleagues (51-53) found that epithelial tubular complexes which develop at early stages of tumor induction in this model, and which might be interpreted on the basis of their histology as ductal or ductular proliferation, contain cells of intermediate character between acinar and ductal types. It appeared likely that these tubular complexes developed by the dedifferentiation of acinar tissue. Bockman has also demonstrated that, at least in the rat, the exocrine pancreas is not a true acinous structure but rather a system of anastomosing tubules (53,54). On anatomical grounds, therefore, it is feasible that pseudo-ductular structures, mimicking proliferated ductules, can result from acinar dedifferentiation.

Guinea Pig

In the guinea pig, pancreatic adenocarcinomas can be induced by *N*-methyl-*N*-nitrosourea (MNU) or *N*-methyl-*N*-nitrosourethane (55-57), albeit at the cost of a high initial mortality and relatively low incidence. The histological appearance of these tumors suggests a ductal histogenesis, but Reddy and Rao (57,58) have observed that MNU causes acinar cells to proliferate and undergo dedifferentiation, giving rise to pseudoductular structures. Ductular or pseudoductular transformation of acini may thus constitute a pathway for the development of so-called "ductal" adenocarcinomas from acinar cells in the guinea pig (41).

Hamster

The third major experimental model was developed following the discovery by Krüger, Pour and their collaborators (59-61) that a very high incidence of pancreatic carcinomas could be induced rapidly in the Syrian hamster by *N*-nitroso-bis(2-hydroxypropyl)amine (BHP), with little initial mortality. Other β -oxidized

derivatives of *N*-nitroso-di-*n*-propylamine (61,62), as well as *N*-nitroso-2,6-dimethylmorpholine (63) also have been shown to be potent pancreatic carcinogens, but only in this species. It is possible that this species-specific organotropy is related to the fact that aged hamsters spontaneously develop a variety of pancreatic lesions, including "ductular hyperplasia" associated with mucous metaplasia (65).

The majority of pancreatic tumors induced in the hamster were reported by Pour and his collaborators (60,66-88) to be multifocal and to comprise adenomas with a cystic, tubular or cystic-papillary structure and adeno-carcinomas of various subtypes and to resemble closely those of man, both in having marked ductal characteristics and also with respect to their biological behavior. In addition to these "ductal" tumors, these workers also obtained a low incidence of acinar cell carcinomas and, occasionally, mixed acinar-ductal and ductal-islet cell tumors. It is arguable that pancreatic carcinogenesis in the hamster may be the best currently available model of the human disease, in terms of experimental convenience as well as the similar morphology and biology of the tumors. The histogenesis of these hamster tumors is therefore likely to be particularly relevant to their human counterparts. Largely on the basis of their histological studies, Pour and his collaborators, having first reported that the pancreatic adenocarcinomas of the hamster were ductal (60,61,69), subsequently suggested that most of them arose from ductules (70,71) and, further claimed that the progenitor cells are "stem cells" within the ductules (72) which proliferate to form new islets of Langerhans (73,74), particular emphasis being placed upon the role of intra- and peri-insular ductules. Levitt and his co-workers (75) similarly considered the cell of origin to be ductal or ductular but, although obtaining only adenocarcinoma in their study (76), also reported mitotic activity among acinar cells. In contrast to other workers, Scarpelli and Rao (77) have suggested that dedifferentiated acinar cells may play a part in the histogenesis of these tumors and have observed that treatment with a single dose of a pancreatic carcinogen gives rise to acinar cell dedifferentiation and a new population of zymogen-free eosinophilic cells (78). Evidently an exclusively ductal or ductular histogenesis of pancreatic adenocarcinoma of the hamster had not been established beyond doubt.

Fine Structural Study of Pancreatic Carcinogenesis in the Hamster

With the aim of elucidating the pathogenesis of experimental pancreatic neoplasia in the hamster model, a series of morphological studies have been carried out on the tumors, proliferative lesions and pancreatic changes induced by BHP (79-84). Male WO strain Syrian hamsters were given once weekly subcutaneous injections of 250 mg/kg body weight of BHP for life.

Groups of animals were killed at closely spaced intervals throughout the experiment. A sample of each pancreas (and any visible tumor) was prepared for electron microscopy, the bulk of the tissue being prepared for histology and serially sectioned. One adenocarcinoma was transplanted subcutaneously and has been serially passaged (80).

Histologically (and ultrastructurally) the normal hamster pancreas is similar to that of the rat and other species. In view of Bockman's work (54) on rat pancreas, a three-dimensional reconstruction of hamster pancreatic tissue was carried out from serial sections. This showed that, as in the rat, much of the acinar tissue exists in the form of anastomosing tubules (Flaks and Moore, unpublished observations). Centroacinar cells are sited in isolation among acinar cells, as well as at the ductular terminations.

Changes in Acinar Cells

Conventional histology revealed little change in the hamster pancreas until after 9 weeks of BHP treatment, when an apparent increase in centroacinar or ductular-type cells became evident (79,84). A quantitative study (Moore, unpublished observations) showed, over the first 15 weeks of treatment, a progressive increase in groups containing three or more centroacinar cells and a decline in single cells. However, examination of semithin plastic sections showed that this apparent increase could be accounted for partly by the presence of abnormally pale acinar cells with few zymogen granules.

Throughout the period of study (approximately 45 weeks) the pancreatic ductules retained a normal fine structure, except for occasional surface blebbing of ductular cells. Intraductal proliferation was rare and neither new islet formation nor early proliferation of intra-insular ductules were observed. However, fine structural changes in acinar cells were evident from the earliest stages and involved at least half of the acinar cell populations after 30 weeks (83,84). The earliest change was the appearance of dark and light cells, differing in the electron density of their ground cytoplasm and nucleoplasm, as shown in Figure 1. Other initial changes included enlargement of acinar lumina and separation of cells at their lateral aspects. Increasing numbers of acinar cells developed conformational alterations of their rough ER including gross cisternal enlargement. Sometimes numerous intercisternal anastomoses were present. The cisternal contents were abundant, showing that this change was not merely due to swelling. In addition, abnormal zymogen granules were occasionally present. In some light cells the rough ER was vesiculated. However, these changes were not accompanied by any visible detachment of ribosomes and thus they do not resemble the degenerative changes produced by acute nonspecific injury. Indeed, BHP treatment resulted in very little acinar necrosis, although mitotic cells were observed. However, these

rough ER changes are not specific either to BHP or to carcinogens (84).

The light acinar cells often contained reduced numbers of zymogen granules and, as treatment progressed, a reduced abundance of rough ER. In addition, their nuclei were often indented or irregular in outline. The sizes of the zymogen granules showed considerable variation (Fig. 2), and in some cells their shape was also variable. Autophagic vacuoles were present in many acinar cells. With increased duration of exposure to BHP, these tended to become more numerous and larger. Some of the largest vacuoles contained mature zymogen granules and rough ER. Similar large autophagic vacuoles, also packed with zymogen granules were observed within pale cells that otherwise resembled centroacinar cells (83).

As treatment continued it was observed that many acini were composed of cells with an abnormally scanty, dispersed, rough ER, few zymogen granules and a Golgi apparatus having an "empty" appearance, surrounding an enlarged lumen.

At the same time, centroacinarlike cells were observed which exhibited one or more abnormal features. These features included an increase in rough ER, a well-developed Golgi apparatus and a few zymogen granules (Fig. 3). Thus, a heterogeneous population of pale cells developed, as shown in Figure 4, some of which had the appearance of normal centroacinar cells and others whose acinar cell character was betrayed by

the presence of zymogen. These various cell types formed a spectrum that ranged from moderately altered acinar cells to cells that were difficult to distinguish from centroacinar cells. Certainly this would not be possible by conventional light microscopy.

The decrease in zymogen and rough ER and atrophy of the Golgi apparatus induced in acinar cells by BHP represents a loss of differentiation. The ultrastructural observations are consistent with the view (83) that this may be effected by a process of selective autophagy of rough ER and zymogen, the cellular end product of which has the fine structural morphology of a centroacinar or ductular cell. Although a similar loss of differentiation has been shown to result from nontumorigenic insults (85-87), it is significant that acinar cell dedifferentiation is also a characteristic feature of pancreatic carcinogenesis in both the rat (50) and the guinea pig (57,58).

Pseudoductular Transformation

By 15 weeks after the start of BHP treatment, significant numbers of pseudoductules became evident in histological preparations of pancreatic tissue (Fig. 5). They developed, in individual animals, before tumors had arisen and at later stages came to replace the acini of entire lobes. On the basis of their histological appearance they might have been considered to represent ductular proliferation. However, high resolution

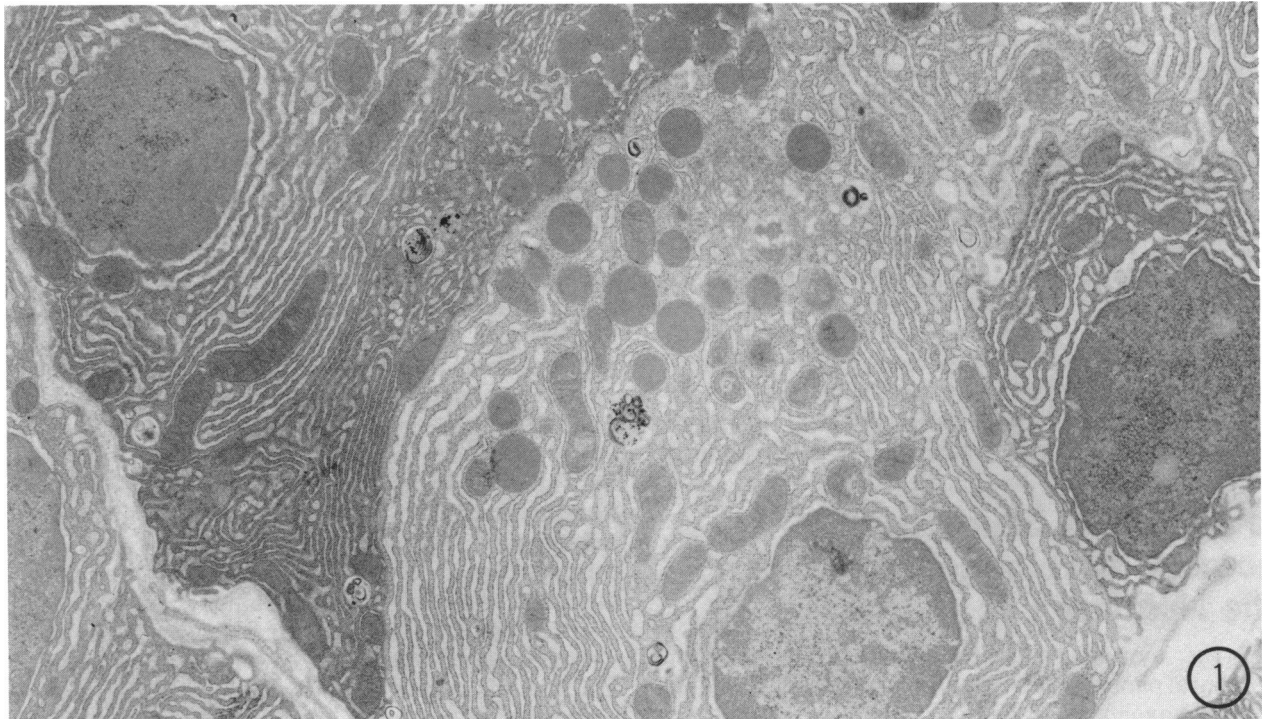


FIGURE 1. Electron micrograph showing mixed population of dark and light acinar cells in hamster pancreas after a short period of BHP treatment. Magnification: $\times 8500$.

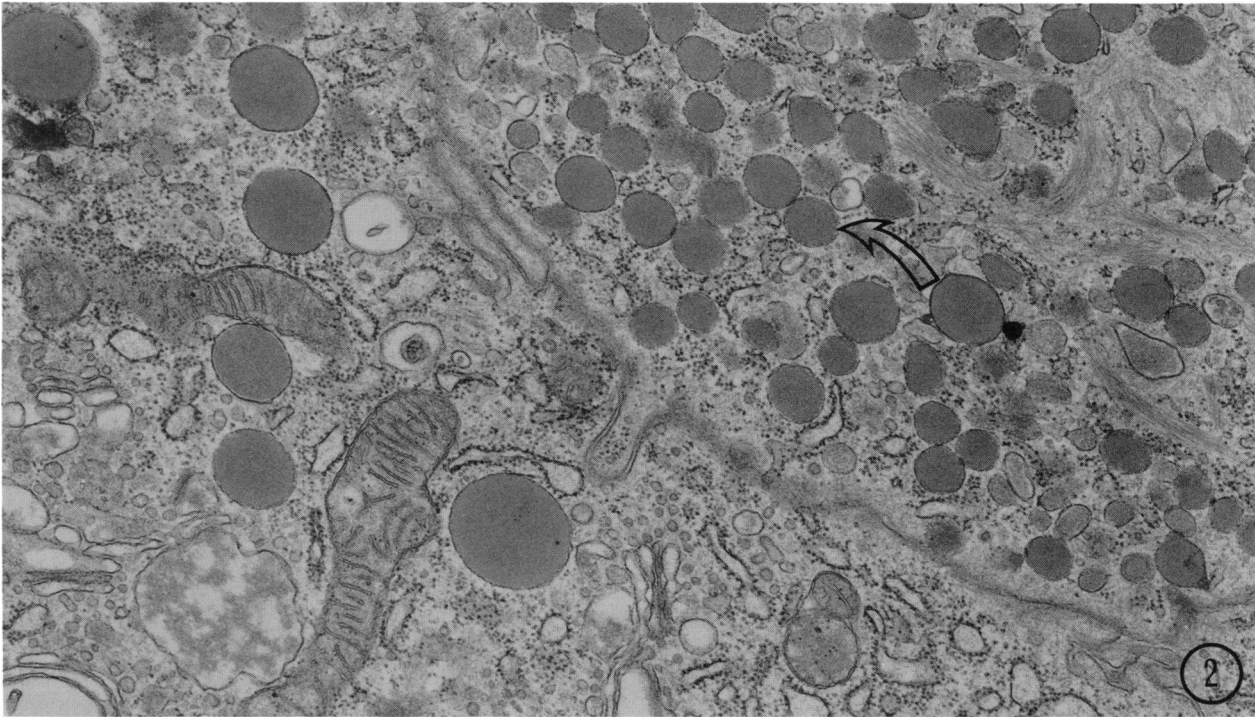


FIGURE 2. Electron micrograph showing zymogen granules of reduced size (arrow), following BHP. Granules of normal size are present in the adjoining cell. Magnification: $\times 23,000$.

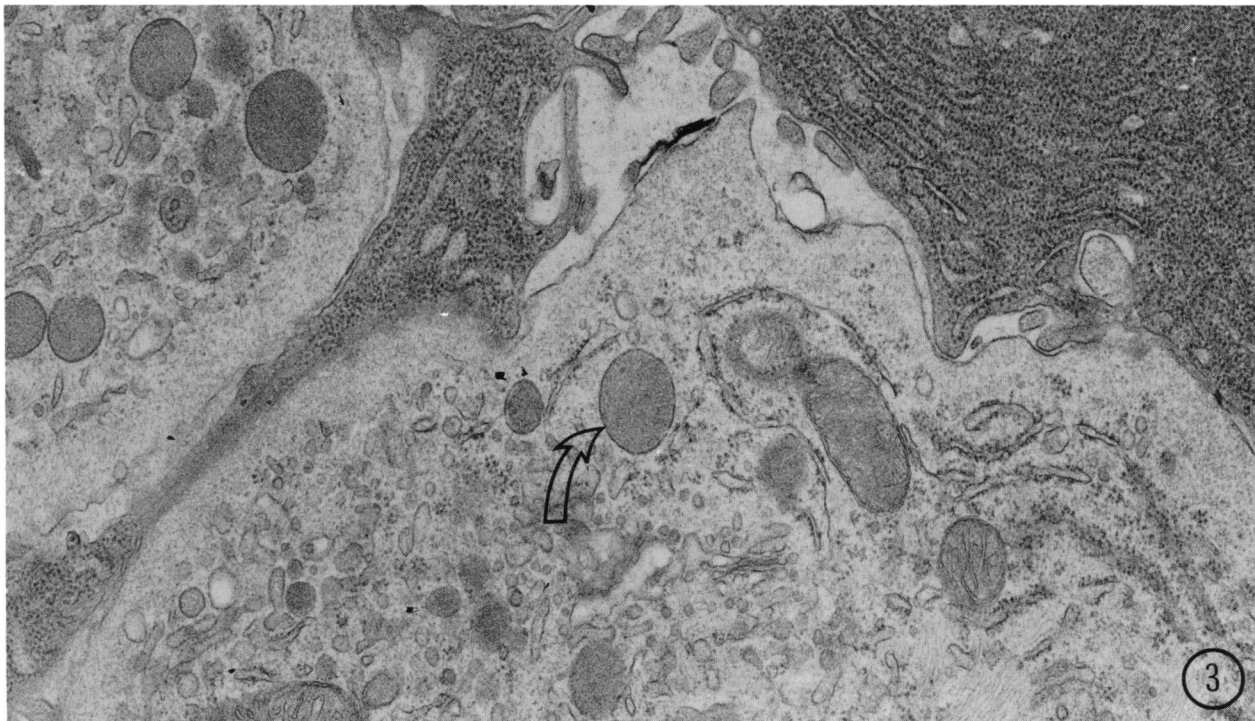


FIGURE 3. BHP-treated hamster pancreas. Details of cytoplasm of two pale centroacinarlike cells, showing the presence of a few zymogen granules (arrow). Magnification: $\times 22,000$.

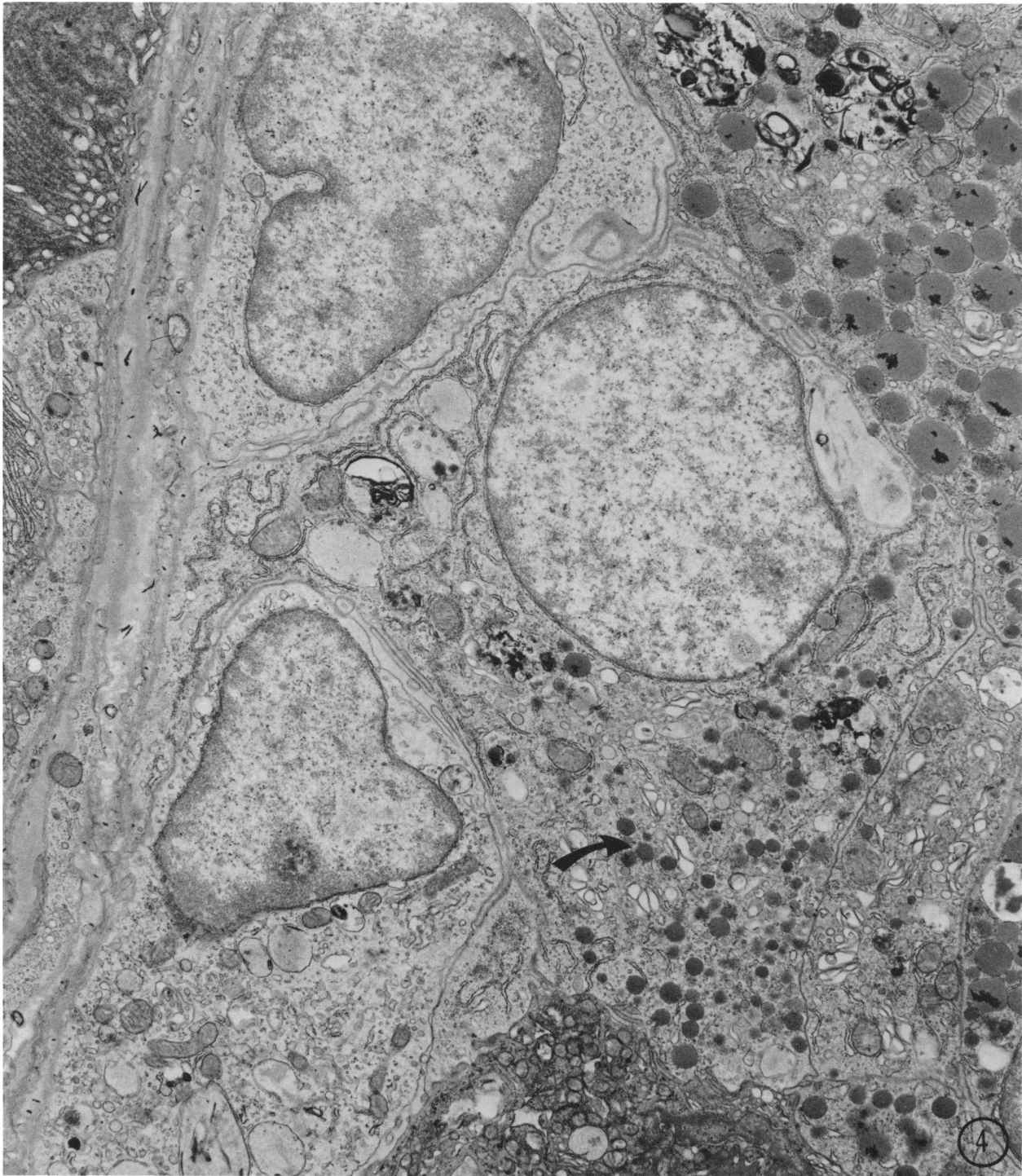


FIGURE 4. Electron micrograph of three pale, centroacinarlike cells in the pancreas of a hamster treated with BHP for 24 weeks. Zymogen granules (arrow) of reduced size are present in one of these cells, which also contains more rough ER than is found in normal centroacinar cells. Magnification: $\times 10,000$.

light microscopy of plastic sections revealed that they were composed of a mixture of cells, some of which appeared to contain zymogen granules while others resembled ductular cells (Fig. 6). Some of these structures appeared to be abnormal acini, while others

appeared to be ductules. Occasionally the "ductular" cells contained large autophagic vacuoles. The lumina varied in size and the larger pseudoductules had the appearance of small cysts. Electron microscopy (82) confirmed that some cells were entirely ductular in

morphology while others had a few zymogen granules (usually of reduced size) and some arrays of rough ER (Fig. 7). These were clearly acinar cells that had undergone partial loss of differentiation. Their Golgi zones were small and their nuclei were often irregular in outline. Cells lacking zymogen, as well as altered cells, sometimes contained smaller cytoplasmic bodies and bundles of tonofibrils in their apical cytoplasm. Increased numbers of free ribosomes were present in some of the cells of pseudoductules.

Occasionally pseudoductular cells were observed that were almost entirely ductular in fine structure, except that they possessed large autophagic vacuoles of striking appearance (Fig. 8) that contained mostly rough ER and zymogen granules, the latter being identical in appearance to those of adjacent acinar cells. The presence of a very few free zymogen granules (Fig. 9) betrayed the acinar cell nature of some cells that otherwise would have been identified as centroacinar or ductular cells by reason of their possessing a sparse, fragmented rough ER, small mitochondria and pale, irregular nuclei. Such free zymogen granules indicated that the large autophagic vacuoles were not due to heterophagy of acinar cell fragments by ductular cells.

Pour (74) considered that the occurrence of pseudoductular transformation in the hamster pancreas was due to a proliferation of centroacinar and ductular cells in response to acinar degeneration and necrosis. However, in our studies (79,82-84) an acinar cell origin

was indicated and we encountered very little necrosis. In addition, since pseudoductular transformation occurred in nontumor-bearing animals it is unlikely that it was a consequence of obstruction of the ductal system of the gland. Recently, another group at Heidelberg (88,89) has also noted the similarity of pseudoductular transformation to ductular proliferation and has observed the presence of zymogen-containing autophagic vacuoles within "ductular" cells.

Thus, the available ultrastructural evidence suggests that, in response to BHP, acinar cells in the hamster can undergo a rapid total re-differentiation to acquire the morphology of ductular cells, as well as becoming more gradually dedifferentiated to varying degrees. In both cases the mechanism appears to involve selective autophagy and the end result is the appearance of new centroacinar- or ductularlike cells.

Cystic Foci

Possible precursors of pancreatic tumors in the hamster appeared to be cystic foci (75,79), lined by flattened or low cuboidal cells. Their development was often associated with sites of pseudoductular transformation and large pseudoductules were difficult to distinguish from small cysts. They could reach a large size but were associated with little stroma. In thin plastic sections, a few acinarlike cells were observed within these cysts, as shown in Figure 10.

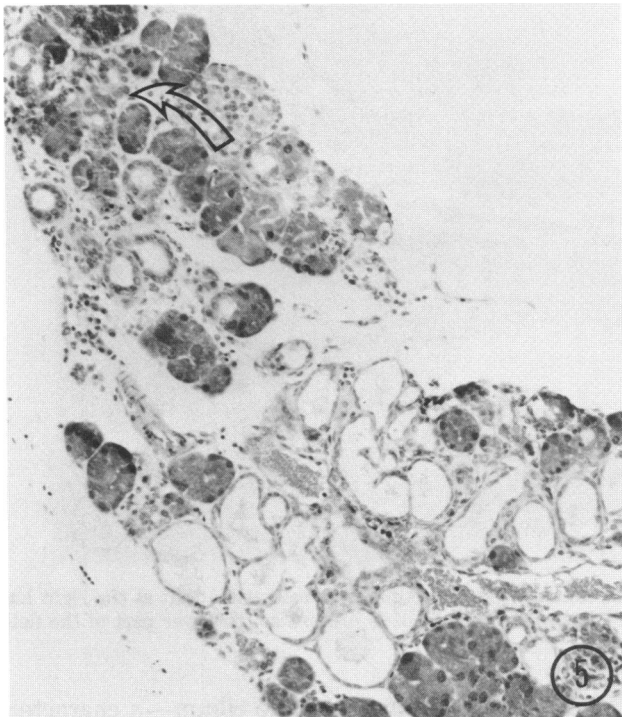


FIGURE 5. Section of hamster pancreas after BHP treatment showing small area of pseudoductular transformation (arrow). A cystic focus is also present at the lower part of the field. Hematoxylin and eosin. Magnification: $\times 130$.

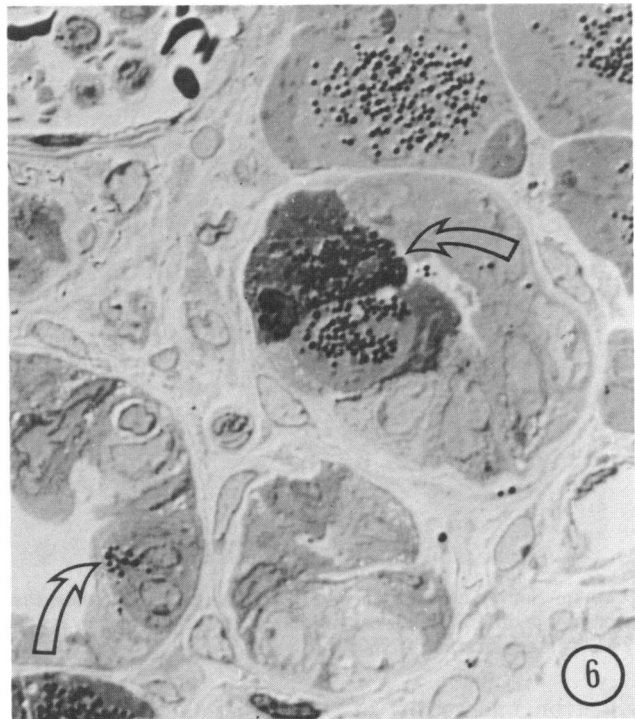

FIGURE 6. High resolution light micrograph of pseudoductules in BHP-treated hamster pancreas. Note the presence of acinarlike cells in these structures (arrows). Toluidine blue, differential interference contrast. Magnification: $\times 900$.

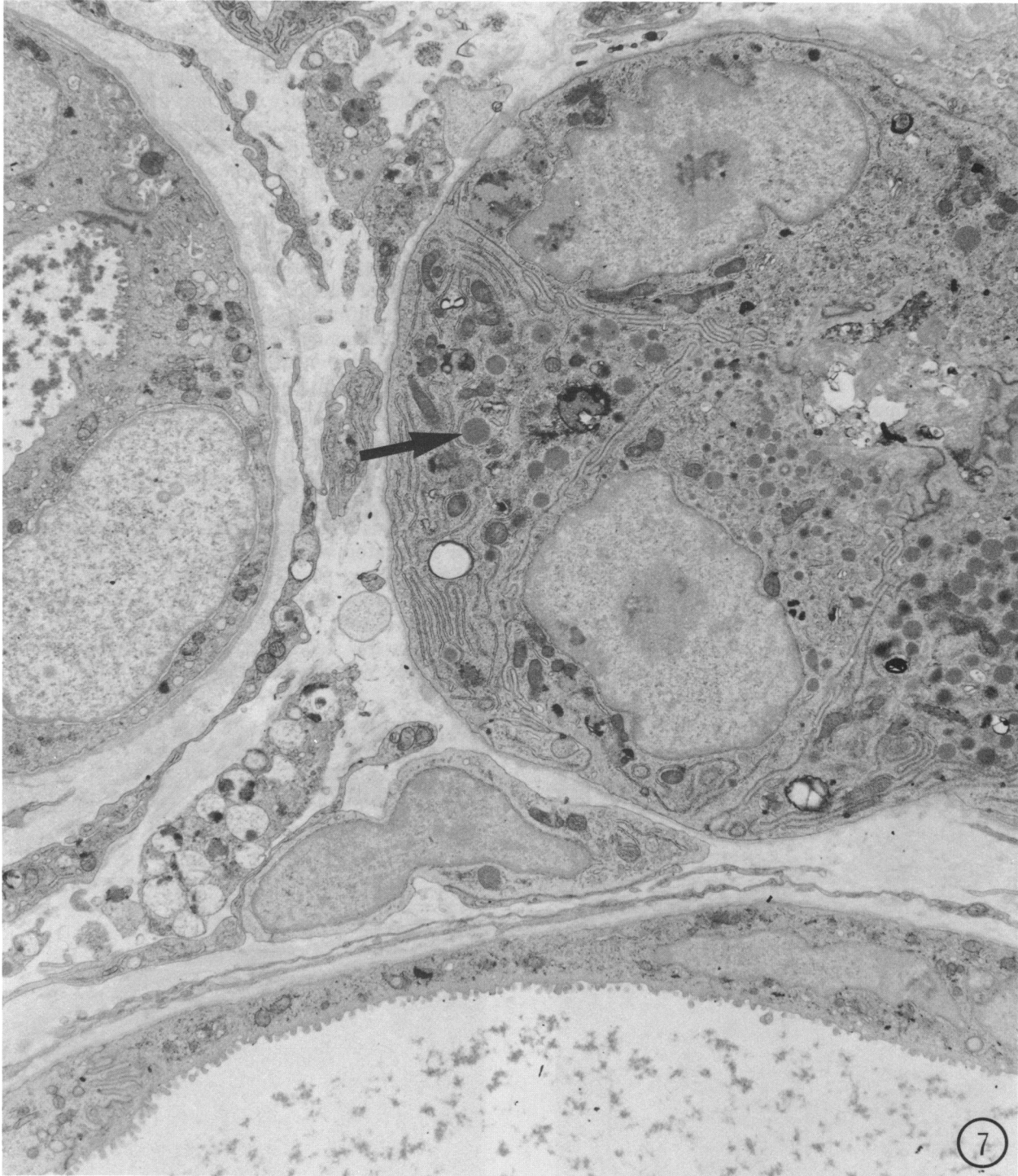


FIGURE 7. Survey electron micrograph of two pseudoductules; that at the left is composed of ductular-type cells while that at the right has partially dedifferentiated acinar cells containing zymogen granules (arrow). Part of a cystic focus is present at the lower part of the field shown. Magnification $\times 7500$.

Electron microscopy of cystic foci showed that the majority of their cells, whether flattened (Fig. 11) or cuboidal (Fig. 12), had a relatively simple fine structure. Their nuclei were irregular in shape, sometimes being deeply lobed. The luminal cell surfaces bore numerous

microvilli and sometimes a single cilium—a characteristic of normal ductular cells. The cytoplasm contained relatively few organelles but often possessed an increased abundance of free ribosomes. A distinct basement membrane was present. Thus, such cells were

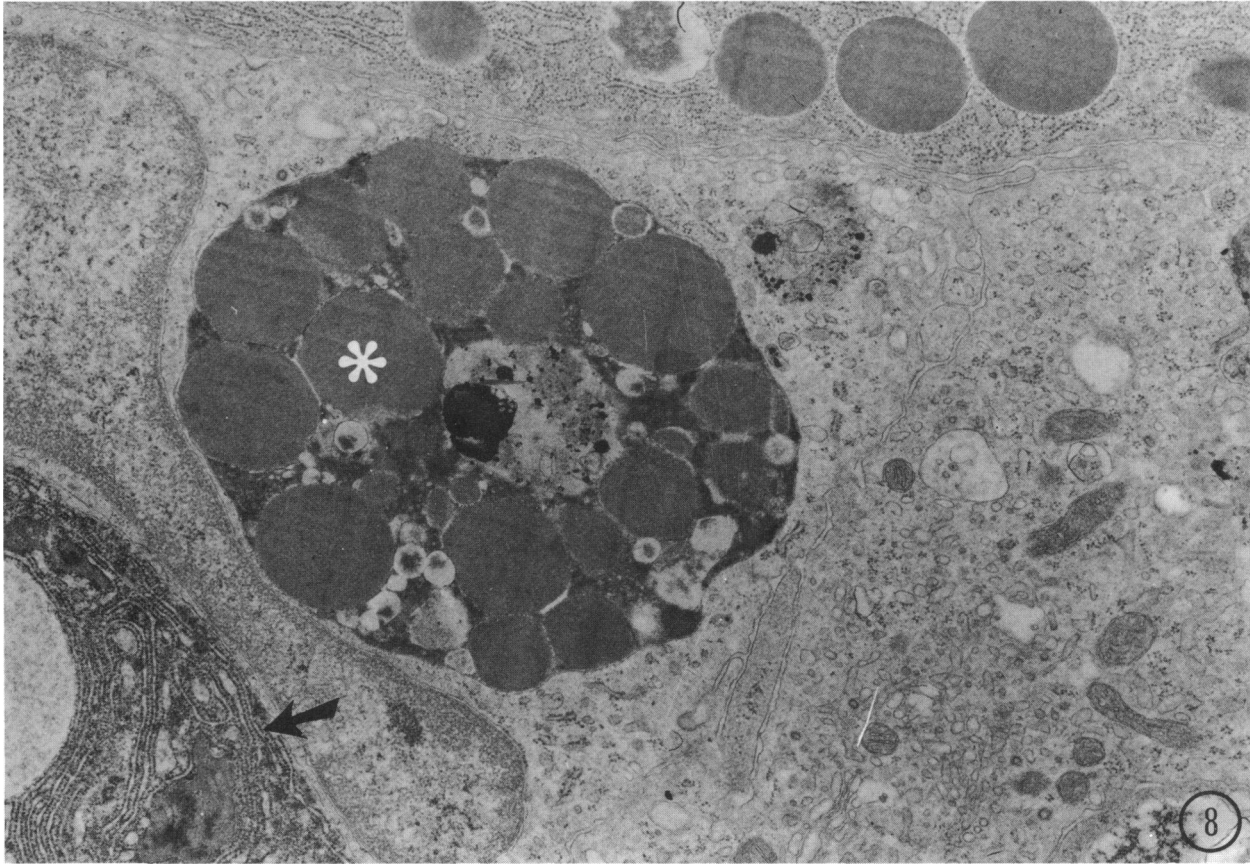


FIGURE 8. BHP-treated hamster pancreas. Pseudoductular cell containing large autophagic vacuoles which enclose large amounts of rough ER (arrow) and zymogen granules (*). Magnification: $\times 16,000$.

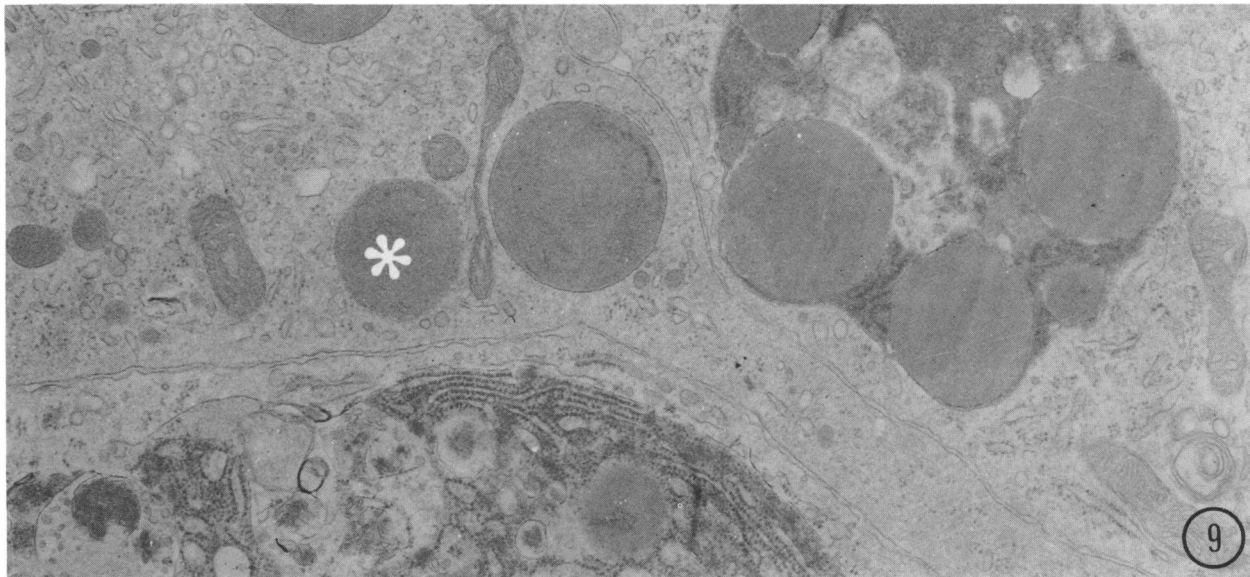


FIGURE 9. Electron micrograph showing free zymogen granules (*) in the cytoplasm of a pseudoductular cell and demonstrating its acinar cell origin. Magnification: $\times 19,000$.

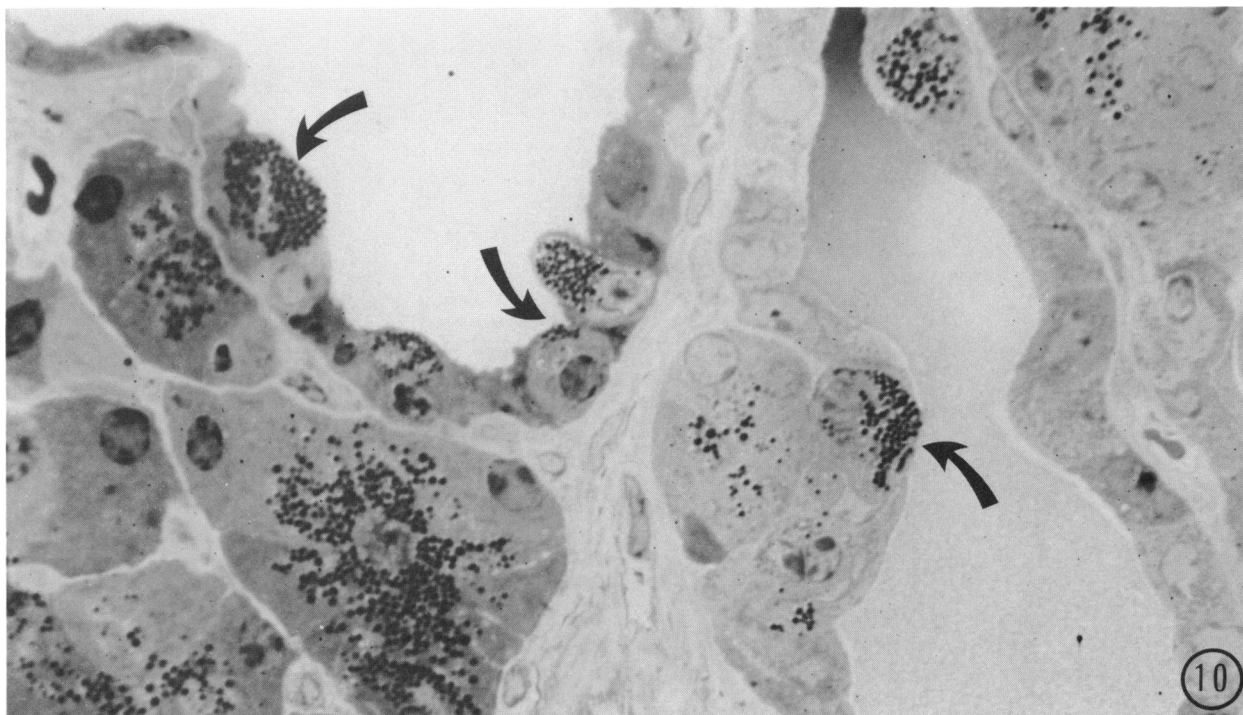


FIGURE 10. High resolution light micrograph of cystic focus in the pancreas of a BHP-treated hamster. Note the presence within the cyst epithelium of several acinarlike cells (arrows). Toluidine blue, differential interference contrast. Magnification: $\times 1250$.

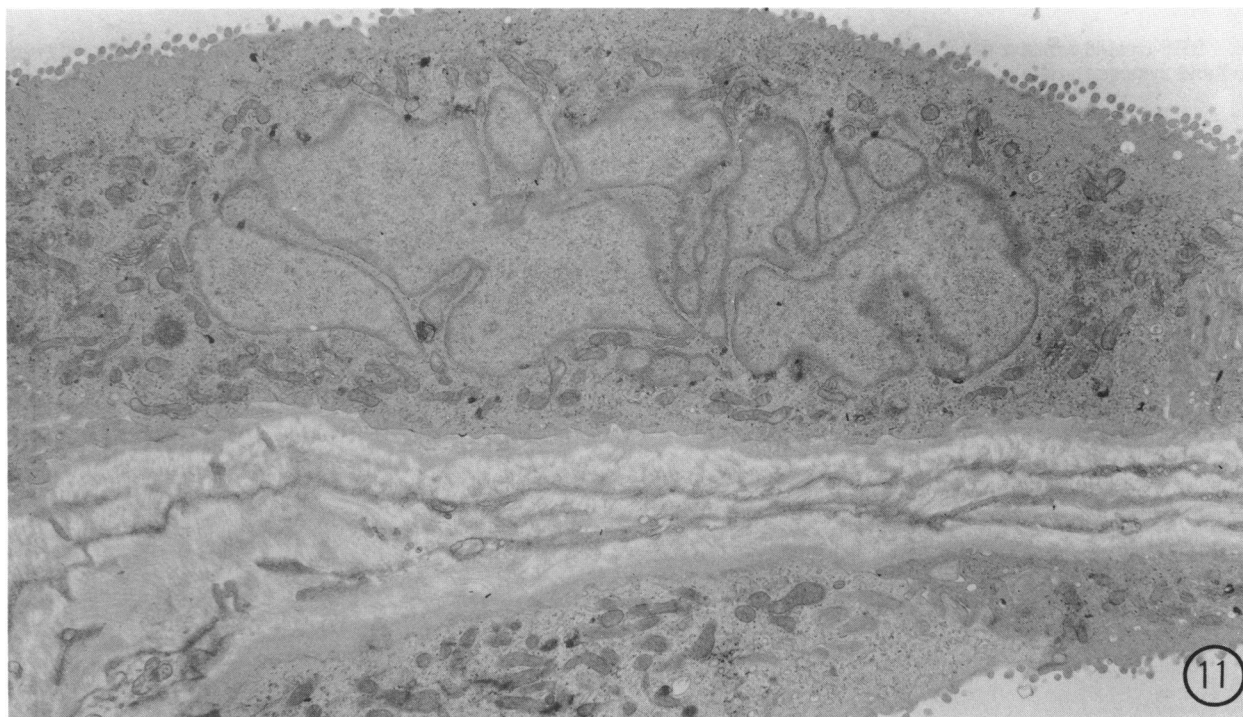


FIGURE 11. Electron micrograph of part of a cystic focus showing the morphology of the flattened variety of typical, ductular-type cells. Magnification: $\times 8000$.

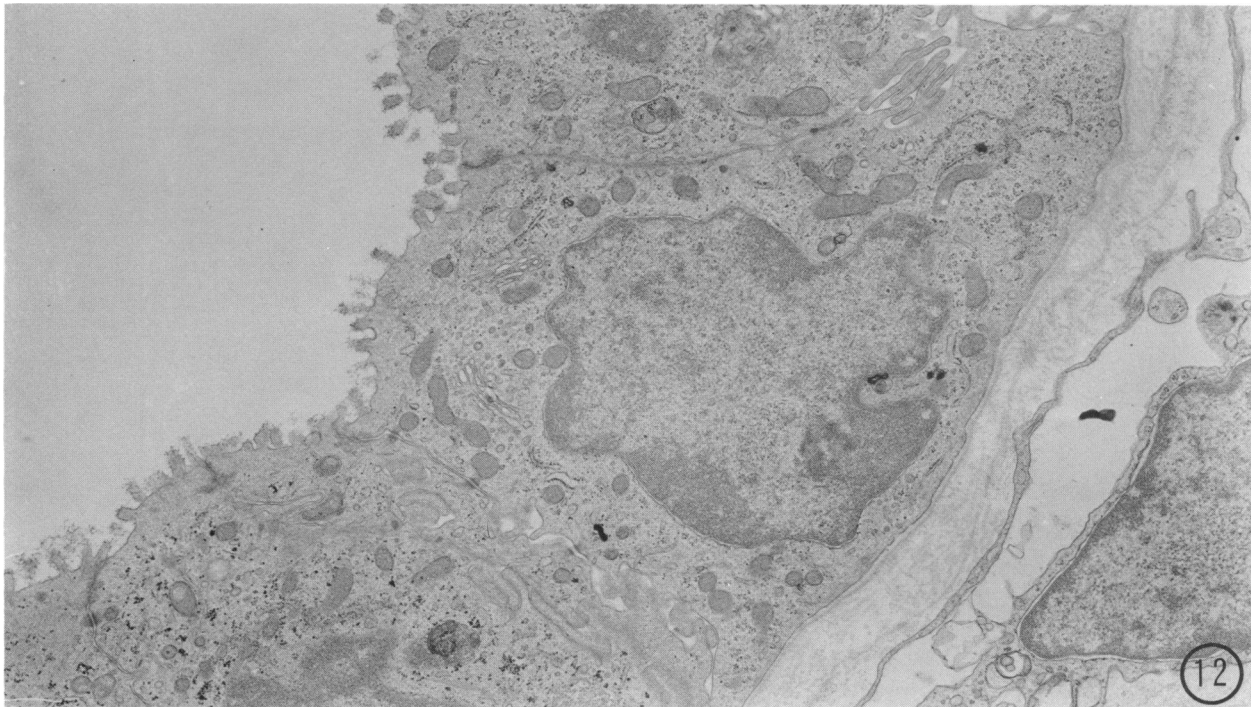


FIGURE 12. Cuboidal cells of ductular type in a cystic focus induced by BHP. Magnification: $\times 12,000$.

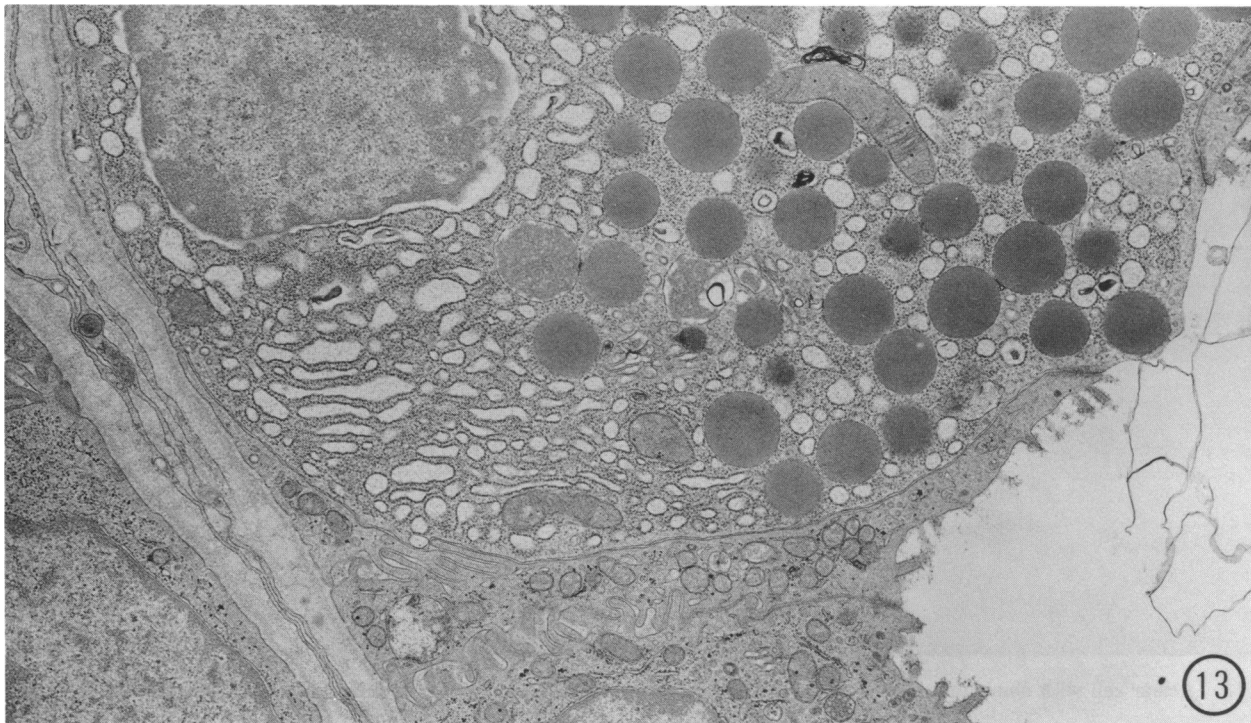


FIGURE 13. Acinar cell in the lining of a BHP-induced cystic focus, showing abundant zymogen granules and a reduced rough ER. Note the tight junctions formed with adjacent ductular-type cells at the luminal surface. Magnification: $\times 14,000$.

essentially similar to ductular cells. However, some of them showed the presence of glycogen (indicating a disturbance of carbohydrate metabolism) and a few contained mucigenlike granules in their apical cyto-

plasm. Sharing the lumina of the cysts with the typical cells were others having zymogen granules (Fig. 13), which were clearly acinar cells, although usually with a reduced rough ER. These cells formed tight junctions

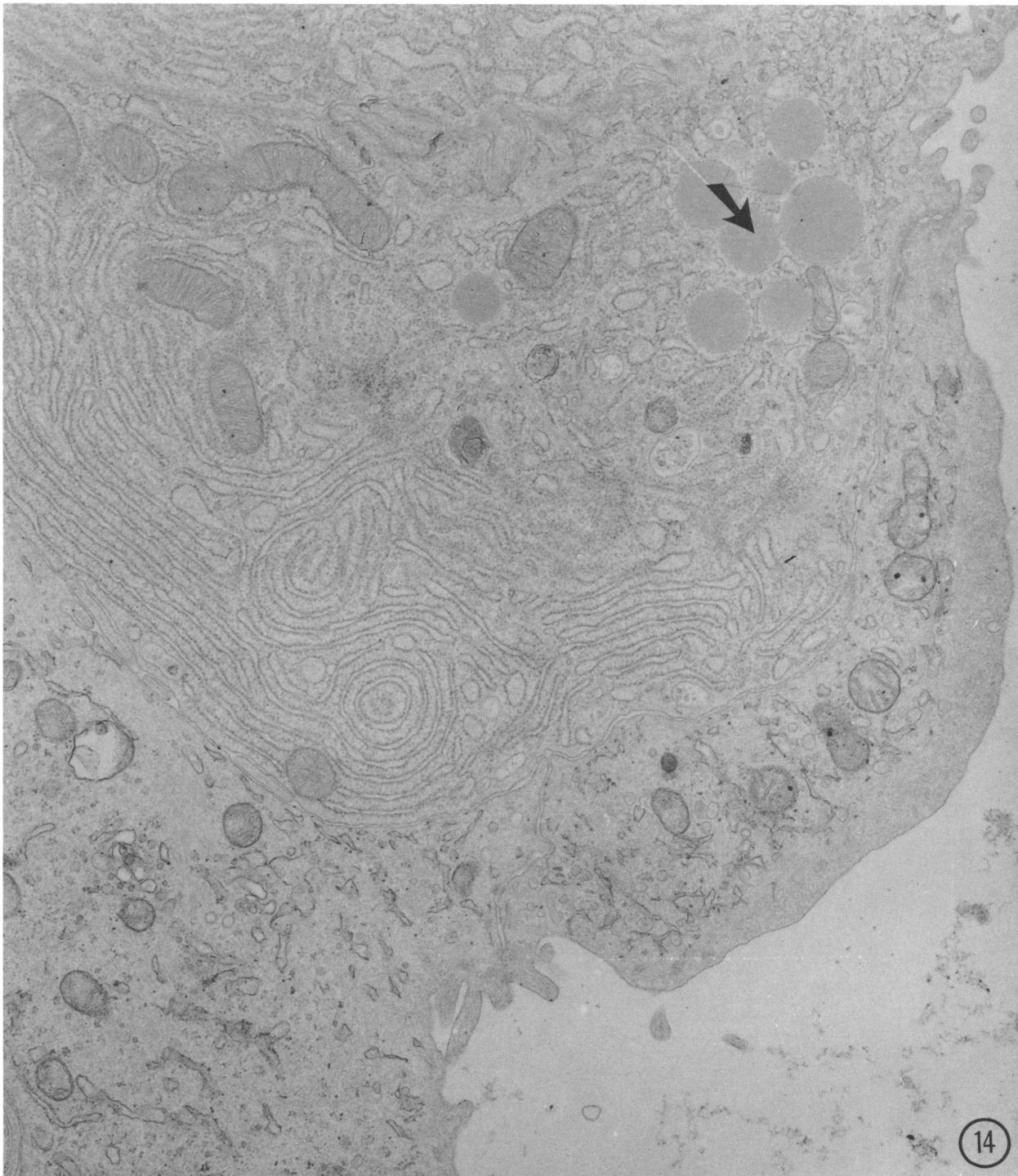


FIGURE 14. Acinar cell with abundant rough ER and a few zymogen granules (arrow) in a cystic focus. Magnification: $\times 24,000$.

with their "ductular" neighbors and rested upon a common basement membrane. Some had very few zymogen granules but a relatively well-developed rough ER (Fig. 14), while other cells only differed from the ductular type in possessing more rough ER. The presence of a few free zymogen granules within the lumina of the cysts indicated active secretory activity. Morpho-

logically, therefore, there appears to be a developmental relationship between pseudoductules and cystic lesions.

Cystadenomas and Adenocarcinomas

Large lesions resembling cystic foci but showing a marked stromal development were (somewhat arbi-

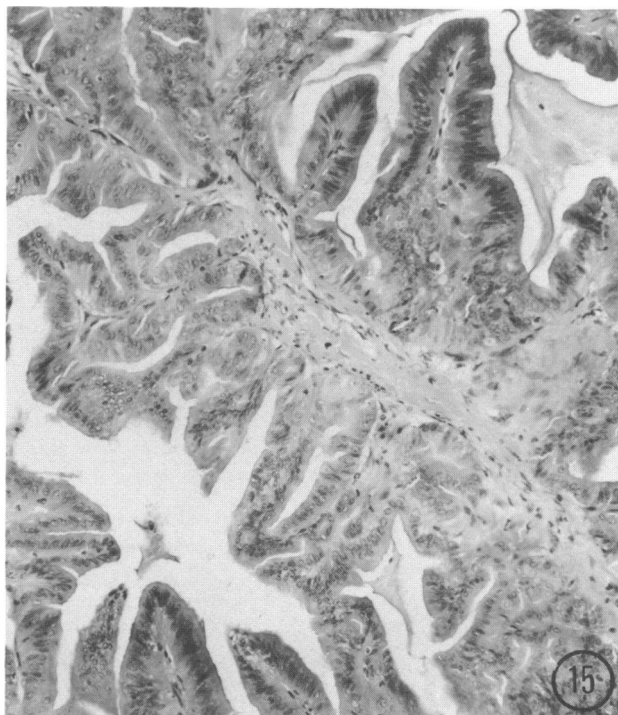


FIGURE 15. Section of the central region of a pancreatic papillary adenocarcinoma induced in a hamster by BHP. Hematoxylin and eosin. Magnification: $\times 130$.

trarily) classified (79) as cystadenomas. Acinarlike cells were less frequently found in these lesions. Their fine structure resembled that of the typical ductular-type cells of cysts, although surface irregularity was more common. Large tumors, including adenocarcinomas, typically consisted of central papillary regions having a columnar epithelium (Fig. 15) and peripheral cystic lesions (Fig. 16). The epithelium was sometimes multilayered and goblet cell metaplasia was often observed in the central regions. Electron microscopy (Fig. 17) showed that the fine structure of the columnar tumor cells was essentially similar to that of the cuboidal and flattened varieties. However, nuclear abnormalities and glycogen accumulation were more common than in the otherwise similar cells of cystic foci and, in the central zones of these tumors, a frequent observation was of cells with either abundant mucigenlike granules or mucous inclusions. Some tumor cells contained both types of inclusion, as shown in Figure 18.

Transplantable pancreatic adenocarcinomas of the hamster have been established (80,90). We studied one which retained the morphology of the primary tumor over several transplant generations (80). Ultrastructurally the cells were typical of this kind of tumor: the epithelium was either multilayered or columnar, its cells often containing mucous or mucigen granules. Localized goblet cell metaplasia was frequently observed in the central areas. An interesting observation was that the

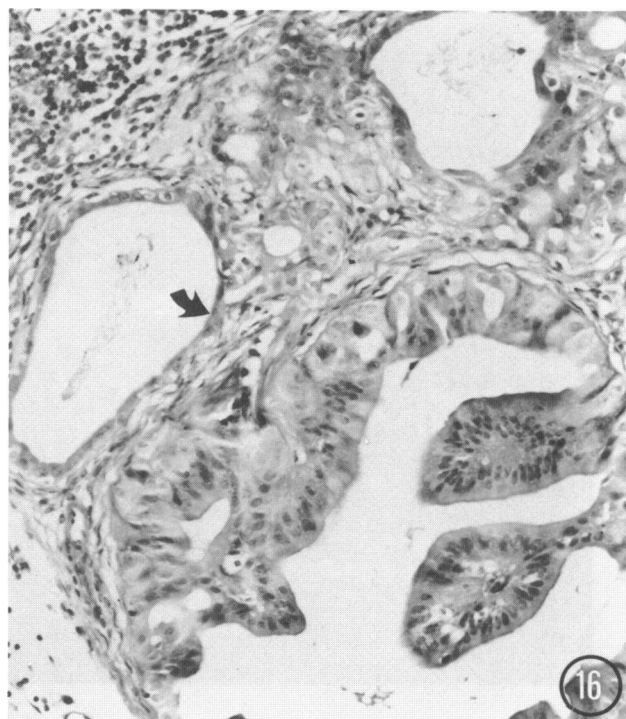


FIGURE 16. Section of the periphery of a BHP-induced pancreatic adenocarcinoma showing flattened epithelium (arrow) in a cystic area. Hematoxylin and eosin. Magnification: $\times 190$.

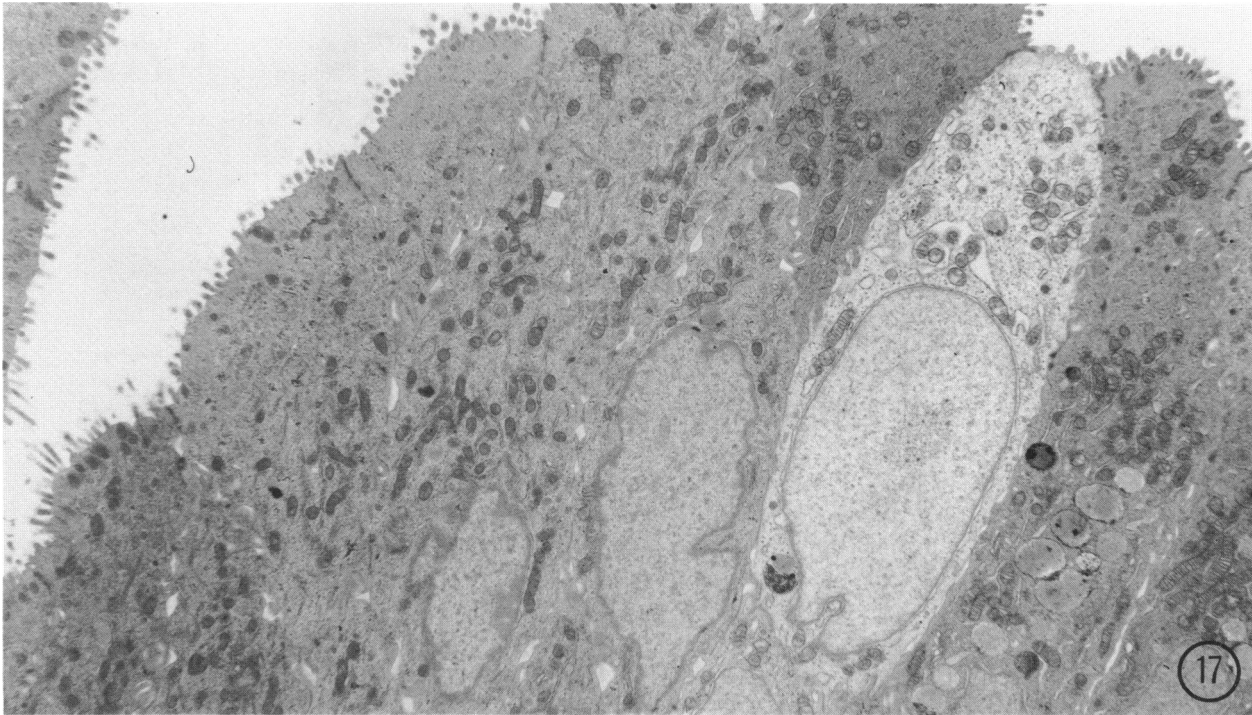


FIGURE 17. Electron micrograph of columnar cells of a BHP-induced hamster pancreatic adenocarcinoma. Magnification: $\times 6000$.

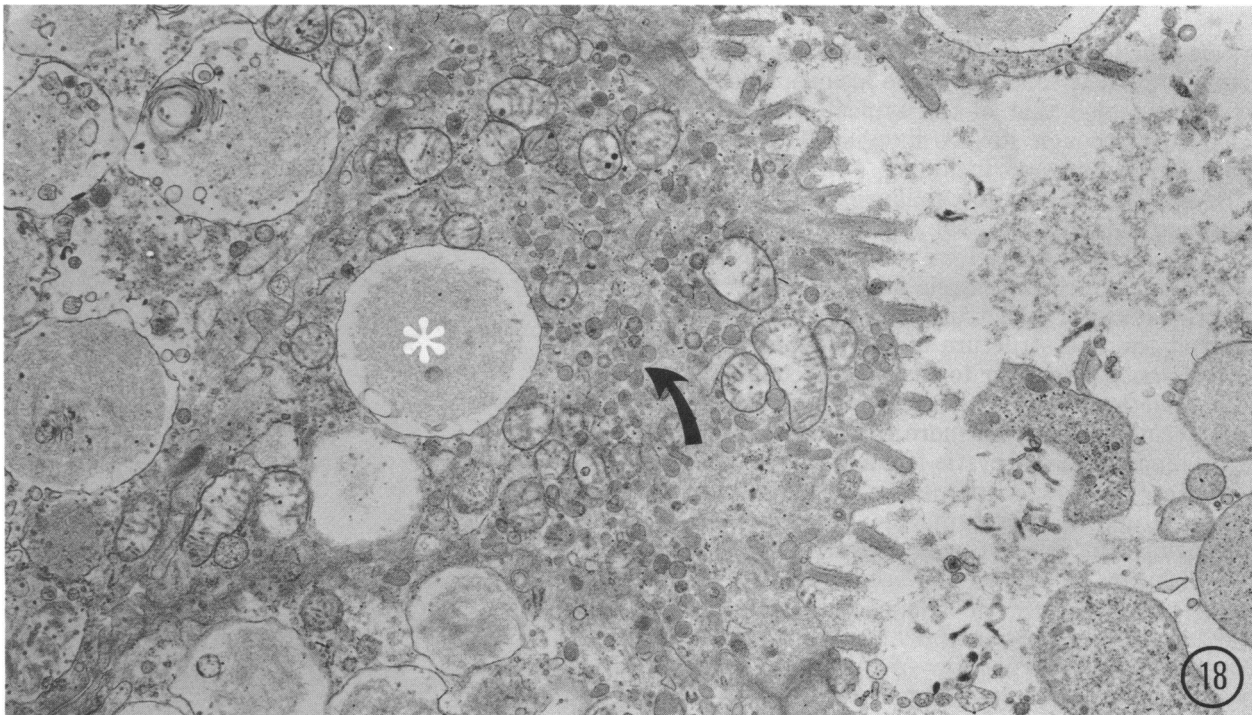


FIGURE 18. Details of apical cytoplasm of BHP-induced adenocarcinoma cell, showing the presence of mucous (*) and mucigen inclusions (arrow). Magnification: $\times 15,000$.

peripheral regions of growing tumor implants resembled that of many primary pancreatic tumors in being invariably cystic in structure and were lined by a flattened epithelium. Ultrastructurally this epithelium was similar to that of cystic foci or cystadenomas (Flaks, unpublished observations). This suggests that the morphology of the tumor cells may reflect their position within the lesion and their degree of maturation rather than their malignant potential.

Conclusions

Electron microscope studies of BHP-induced carcinogenesis have furnished morphological evidence that it is the acinar cells of the hamster pancreas that are the first to respond to BHP, ductular cells showing only minimal change. The acinar cells undergo a gradual progressive loss of rough ER and zymogen that results in their dedifferentiation to form cells that may be difficult or impossible to distinguish from centroacinar or ductular cells. The mechanism appears to be one that involves selective autophagy. Study of areas of apparent ductular proliferation shows that this should rather be considered to be pseudoductular transformation, in view of the presence of altered acinar cells. There is evidence suggesting that selective autophagy may also operate on an extensive scale in exocrine cells during pseudoductular transformation, rapidly removing most or all of their component of zymogen and rough ER. It is likely that proliferation of some of the resulting dedifferentiated cells leads to the formation of cystic foci and cystadenomas, since some isolated, altered, but identifiable, acinar cells are retained in these lesions. Further progression probably leads to the development of tumors whose cells are entirely devoid of acinar cell characters and which appear to be ductal or ductular adenocarcinomas, comparable to those of human patients. Mucous or goblet cell metaplasia appears to be a secondary phenomenon. If elimination of acinar cell characters is incomplete, this may result in the development of mixed acinar-ductal tumors, as has been reported to occur in the hamster. Although the evidence discussed here does not exclude the participation of ductular cells in pancreatic tumorigenesis in the hamster, it is consistent with the view that the acinar cell is a major progenitor of so-called ductular tumors. There appears to be no compelling evidence, on the other hand, that a ductular stem cell is necessarily involved in their histogenesis.

Thus, there are similarities between the hamster, rat and guinea pig models of pancreatic carcinogenesis, with respect to loss of acinar cell differentiation and pseudoductular transformation. These processes may not be specific *per se* to neoplastic induction but may give rise to a new cell type with increased susceptibility to further stimulation by carcinogens. If it is accepted that pancreatic carcinogenesis in the hamster closely resembles the human disease, then evidence of an

acinar cell histogenesis of pancreatic tumors in the hamster lends new significance to observations of acinar dysplasias in human pancreatic tissue (34-36) and suggests that the supposed ductal or ductular origin of pancreatic adenocarcinomas in man may need to be reconsidered critically.

I thank Mr. Clifford C. Jeal for his photographic assistance. Figures 4, 7 and 10 have been published elsewhere previously (82,83), and I thank the publishers, IRL Press, for permitting their reproduction.

REFERENCES

1. Breslow, L. Epidemiology as a tool in cancer research. In: Proceedings 3rd National Cancer Conf., Lippincott, Philadelphia, 1957, pp. 15-26 (1957).
2. Hammond, E. C. Trends in cancer deaths. *Ann. Intern. Med.* 50: 300-312 (1959).
3. Krain, L. S. The rising incidence of carcinoma of the pancreas: an epidemiological appraisal. *Am. J. Gastroenterol.* 54: 500-507 (1970).
4. Biometry Branch, National Cancer Institute. The Third National Cancer Survey Advanced Three Year Report, 1969-1971 (Excluding Carcinoma in situ), DHEW, Publ. No. 74-637, U.S. Department of Health, Education and Welfare, Bethesda (1974).
5. Office of Population Censuses and Surveys. Registrar General's Statistical Review of England and Wales for the year 1973, Part 1(B) Tables Medical, Her Majesty's Stationery Office, London (1976).
6. Devesa, S. S., and Silverman, D. T. Cancer incidence and mortality trends in the United States: 1935-74. *J. Natl. Cancer Inst.* 60: 545-571 (1978).
7. Levin, D. L., Connelly, R. R., and Devesa, S. A. Demographic characteristics of cancer of the pancreas: mortality, incidence and survival. *Cancer* 47: 1456-1468 (1981).
8. Macdonald, J. S., Widerlite, L., and Schein, P. S. Current diagnosis and management of pancreatic carcinoma. *J. Natl. Cancer Inst.* 56: 1093-1099 (1976).
9. Gudjonsson, B., Livstone, E. M., and Spiro, H. M. Cancer of pancreas. Diagnostic accuracy and survival statistics. *Cancer* 24: 2494-2506 (1978).
10. Haenszel, W., and Kurihara, M. Mortality from cancer and other diseases among Japanese in the United States. *J. Natl. Cancer Inst.* 40: 43-68 (1968).
11. Levin, D. L., and Connelly, R. R. Cancer of the pancreas. Available epidemiological information and its implications. *Cancer* 31: 1231-1236 (1973).
12. Dörken, H. Einige Daten bei 280 Patienten mit Pankreaskrebs Häufigkeit, Vord- und Begleitkrankheiten, exogene Faktoren. *Gastroenterologia* 102: 47-77 (1964).
13. Mancusor, T. F., and El-Attar, A. A. Cohort study of workers exposed to 2-naphthylamine and benzidine. *J. Occup. Med.* 9: 227-235 (1967).
14. Li, F. P., Fraumeni, J. F., Jr., Mantel, N., and Miller, R. W. Cancer mortality among chemists. *J. Natl. Cancer Inst.* 43: 1159-1164 (1969).
15. Mainz, D. L., and Webster, P. D. Pancreatic carcinoma. A review of etiological considerations. *Am. J. Dig. Dis.* 19: 459-464 (1974).
16. Millham, S. Jr. Cancer mortality patterns associated with exposure to metals. *Ann. N.Y. Acad. Sci.* 271: 243-249 (1976).
17. Mirvish, S. S. *N*-Nitroso compounds: their chemical and *in vivo* formation and possible importance as environmental carcinogens. *J. Toxicol. Environ. Health* 2: 1267-1277 (1977).
18. Wynder, E. L. An epidemiological evaluation of the causes of cancer of the pancreas. *Cancer Res.* 35: 2228-2233 (1975).
19. Wynder, E. L., Mabucki, K., Maruchi, N., and Fortner, J. G. Epidemiology of cancer of the pancreas. *J. Natl. Cancer Inst.* 50: 645-666 (1973).

20. Mack, T. M., and Paganini-Hill, A. Epidemiology of pancreas cancer in Los Angeles. *Cancer* 47: 1474-1483 (1981).
21. Ewing, J. *Neoplastic Diseases*. W. B. Saunders, Philadelphia-London, 1919.
22. Miller, J. R., Baggenstoss, A. H., and Comfort, M. W. Carcinoma of the pancreas. Effects of histological type and grade of malignancy on its behaviour. *Cancer* 4: 238-241 (1951).
23. Franz, V. K. Tumors of the pancreas. Atlas of Tumor Pathology, Section VIII, Fascicles 27 and 28. American Registry of Pathology, Armed Forces Institute of Pathology, Washington, DC, 1959.
24. Baylor, S. M., and Berg, J. W. Cross classification and survival characteristics of 5,000 cases of cancer of the pancreas. *J. Surg. Oncol.* 5: 335-338 (1973).
25. Cubilla, A. L., and Fitzgerald, P. J. Morphological patterns of primary non-endocrine human pancreas carcinoma. *Cancer Res.* 35: 2234-2248 (1975).
26. Cubilla, A. L., and Fitzgerald, P. J. Morphological lesions associated with human primary invasive non-endocrine pancreas cancer. *Cancer Res.* 36: 2690-2698 (1976).
27. Roberts, P. F., and Burns, J. A histochemical study of mucins in normal and neoplastic human pancreatic tissue. *J. Pathol.* 107: 87-94 (1972).
28. Sommers, S. C., and Meissner, W. A. Unusual carcinomas of the pancreas. *Arch. Pathol.* 58: 101-111 (1954).
29. Graner, F. W. Pancreatic carcinoma. *Arch. Intern. Med.* 63: 884-898 (1939).
30. Walters, M. N.-I. Goblet cell metaplasia in ductules and acini of the exocrine pancreas. *J. Pathol. Bacteriol.* 89: 569-572 (1965).
31. Pour, P., Salmosi, S. Z., and Runge, R. G. Ductular origin of pancreatic cancer and its multiplicity in man comparable to experimentally induced tumours. *Cancer Lett.* 6: 89-97 (1979).
32. Halpert, B., Mark, L., and Jordan, G. L. A retrospective study of 120 patients with carcinoma of the pancreas. *Surg. Gynecol. Obstet.* 121: 91-96 (1965).
33. Leach, W. B. Carcinoma of the pancreas. A clinical analysis of thirty-nine autopsied cases. *Am. J. Pathol.* 26: 333-347 (1950).
34. Longnecker, D. S., Shinozuka, H., and Dekker, A. Focal acinar cell dysplasia in human pancreas. *Cancer* 45: 534-540 (1980).
35. Longnecker, D. S., Hashida, Y., and Shinozuka, H. Relationship of age to prevalence of focal acinar cell dysplasia in the human pancreas. *J. Natl. Cancer Inst.* 65: 63-66 (1980).
36. Shinozuka, H., Lee, R. E., Dunn, J. L., and Longnecker, D. S. Multiple atypical acinar cell nodules in human pancreas. *Human Pathol.* 11: 389-391 (1980).
37. Burns, W. A., Matthews, M. J., Hamosh, M., Weide, G. V., Blum, R., and Johnson, F. B. Lipase-secreting acinar cell carcinoma of the pancreas with polyarthropy: a light and electron microscopic histochemical study. *Cancer* 33: 1002-1009 (1974).
38. Kakudo, K., Sakurai, M., Miyazi, T., Ikeda, Y., Satani, M., and Manabe, H. Pancreatic carcinoma in infancy: an electron microscope study. *Acta Pathol. Japon.* 26: 719-726 (1976).
39. Schrieber, V. D., and Probst, H. J. Sekretorisch aktives Karzinom des exokrinen Pankreas: Fullbericht und Literatur-übersicht. *Zentralbl. Allg. Pathol.* 121: 114-121 (1977).
40. Cantrell, B. B., Cubilla, A. L., Erlandson, R. A., Fortner, J., and Fitzgerald, P. J. Acinar cell cystadenocarcinoma of human pancreas. *Cancer* 47: 410-416 (1981).
41. Reddy, J. K., Scarpelli, D. G., and Rao, M. S. Experimental pancreatic carcinogenesis. In: *Advances in Medical Oncology, Research and Education, Vol. 9. Digestive Cancer* (N. Thatcher, Ed.), Pergamon Press, Oxford-New York, 1979, pp. 99-109.
42. Hayashi, Y., and Hasegawa, T. Experimental pancreatic tumor in rats after intravenous injection of 4-hydroxyaminoquinoline-1-oxide. *Gann* 62: 329-330 (1971).
43. Longnecker, D. S., and Crawford, B. G. Hyperplastic nodules and adenomas of exocrine pancreas in azaserine-treated rats. *J. Natl. Cancer Inst.* 53: 573-578 (1974).
44. Longnecker, D. S., and Curphey, T. J. Adenocarcinoma of the pancreas in azaserine-treated rats. *Cancer Res.* 35: 2249-2258 (1975).
45. Longnecker, D. S., Roebuck, B. D., Yager, J. D., Jr., Lilja, H. S., and Siegmund, B. Pancreatic carcinoma in azaserine-treated rats: induction, classification and dietary modulation of incidence. *Cancer* 47: 1562-1572 (1981).
46. Longnecker, D. S. Animal model of human disease. Carcinoma of the pancreas in azaserine-treated rats. *Am. J. Pathol.* 105: 94-96 (1981).
47. Reddy, J. K., and Rao, M. S. Malignant tumors in rats fed nafenopin, a hepatic peroxisome proliferator. *J. Natl. Cancer Inst.* 59: 1645-1647 (1977).
48. Dissin, J., Mills, L. R., Mainz, D. L., Black, O., Jr., and Webster, P. D. III. Experimental induction of pancreatic adenocarcinoma in rats. *J. Natl. Cancer Inst.* 55: 857-864 (1975).
49. Shinozuka, H., Popp, J. A., and Konishi, Y. Ultrastructures of atypical acinar cell nodules in rat pancreas induced by 4-hydroxyaminoquinoline-1-oxide. *Lab. Invest.* 34: 501-509 (1976).
50. Bockman, D. E., Black, O., Jr., Mills, L. R., Mainz, D. L., and Webster, P. D. III. Fine structure of pancreatic adenocarcinoma induced in rats by 7,12-dimethylbenz(a)anthracene. *J. Natl. Cancer Inst.* 57: 931-936 (1976).
51. Bockman, D. E., Black, O., Jr., Mills, L. R., and Webster, P. D. III. Origin of tubular complexes developing during induction of pancreatic adenocarcinoma by 7,12-dimethylbenz(a)anthracene. *Am. J. Pathol.* 90: 645-658 (1978).
52. Bockman, D. E., and Black, O., Jr. Evidence of pancreatic exocrine dedifferentiation during tumour induction and non-specific injury. *Anat. Rec.* 93: 160-161 (1979).
53. Bockman, D. E. Cells of origin of pancreatic cancer: experimental animal tumors related to human pancreas. *Cancer* 47: 1528-1534 (1981).
54. Bockman, D. E. Anastomosing tubular arrangement of the exocrine pancreas. *Am. J. Anat.* 147: 113-118 (1976).
55. Druckney, H., Ivankovic, S., Bücheler, J., Preussmann, R., and Thomas, C. Erzeugung von Magen- und Pankreas-Krebs beim Meerschweinchen durch Methylnitroso-harnstoff und Urethan. *Z. Krebsforsch.* 71: 167-182 (1968).
56. Reddy, J. K., Svoboda, D. J., and Rao, M. S. Susceptibility of an inbred strain of guinea pigs to the induction of pancreatic adenocarcinoma by *N*-methyl-*N*-nitrosourea. *J. Natl. Cancer Inst.* 52: 991-993 (1974).
57. Reddy, J. K., and Rao, M. S. Pancreatic adenocarcinoma in inbred guinea pigs induced by *N*-methyl-*N*-nitrosourea. *Cancer Res.* 35: 2269-2277 (1975).
58. Rao, M. S., and Reddy, J. K. Histogenesis of pseudoductular changes induced in the pancreas of guinea pigs treated with *N*-methyl-*N*-nitrosourea. *Carcinogenesis* 1: 1027-1037 (1980).
59. Krüger, F. W., Pour, P., and Althoff, J. Induction of pancreas tumours by di-isopropanolnitrosamine. *Naturwissenschaften* 61: 328 (1974).
60. Pour, P., Krüger, F. W., Althoff, J., Cardesa, A., and Mohr, U. Cancer of the pancreas induced in the Syrian golden hamster. *Am. J. Pathol.* 76: 349-358 (1974).
61. Pour, P., Krüger, F. W., Althoff, J., Cardesa, A., and Mohr, U. Effects of beta-oxidized nitrosamines on Syrian golden hamsters. III. 2,2'-Dihydroxy-di-*n*-propylnitrosamine. *J. Natl. Cancer Inst.* 54: 141-145 (1975).
62. Pour, P., Althoff, J., Gingell, R., Kupper, R., Krüger, F. W., and Mohr, U. *N*-nitrosobis(2-acetoxypropyl)amine as a further pancreatic carcinogen in Syrian golden hamsters. *Cancer Res.* 36: 2877-2884 (1976).
63. Pour, P., Althoff, J., Krüger, F. W., and Mohr, U. A potent pancreatic carcinogen in Syrian hamsters: *N*-nitrosobis(2-oxopropyl)amine. *J. Natl. Cancer Inst.* 58: 1449-1453 (1977).
64. Mohr, U., Reznik, G., Emminger, E., and Lijinsky, W. Induction of pancreatic duct carcinomas in the Syrian hamster with 2,6-dimethylnitrosomorpholine. *J. Natl. Cancer Inst.* 58: 429-432 (1977).
65. Takahashi, M., and Pour, P. Spontaneous alterations in the pancreas of the aging Syrian golden hamster. *J. Natl. Cancer Inst.* 60: 355-364 (1978).
66. Pour, P., Althoff, J., Krüger, F. W., Schmahl, D., and Mohr, U. Induction of pancreatic neoplasms by 2,2'-dioxopropyl-*N*-propylnitrosamine. *Cancer Letters* 1: 3-6 (1975).

67. Pour, P., Mohr, U., Cardesa, A., Althoff, J., and Krüger, F. W. Pancreatic neoplasms in an animal model—morphological, biological and comparative studies. *Cancer* 36: 379–389 (1975).
68. Pour, P., Krüger, F. W., Althoff, J., and Mohr, U. A new approach for induction of pancreatic neoplasms. *Cancer Res.* 35: 2259–2268 (1975).
69. Althoff, J., Pour, P., Malick, L., and Wilson, R. B. Pancreatic neoplasms induced in Syrian golden hamsters. I. Scanning electron microscope observations. *Am. J. Pathol.* 83: 517–530 (1976).
70. Pour, P., Althoff, J., and Takahashi, M. Early lesions of pancreatic ductal carcinoma in the hamster model. *Am. J. Pathol.* 88: 291–308 (1977).
71. Takahashi, M., Pour, P., Althoff, J., and Donnelly, T. Sequential alteration of the pancreas during carcinogenesis in Syrian hamsters by *N*-nitrosobis(2-oxopropyl)amine. *Cancer Res.* 37: 4602–4607 (1977).
72. Pour, P., Runge, R. G., Birt, D., Gingell, R., Lawson, T., Nagel, D., Wallcave, L., and Salmasi, S. Z. Current knowledge of pancreatic carcinogenesis in the hamster and its relevance to the human disease. *Cancer Res.* 47: 1573–1587 (1981).
73. Pour, P. Islet cells as a component of pancreatic ductal neoplasms. I. Experimental study: ductular cells, including islet cell precursors, as primary progenitor cells of tumors. *Am. J. Pathol.* 90: 295–316 (1978).
74. Pour, P. Experimental pancreatic ductal (ductular) tumors. In: *Tumors of the Pancreas* (A. R. Moossa, Ed.), Williams and Wilkins, Baltimore and London, 1980, pp. 111–139.
75. Levitt, M. H., Harris, C., Squire, R., Springer, W., Wenk, M., Mollolelo, C., Thomas, D., Kingsbury, E., and Newkirk, C. Experimental pancreatic carcinogenesis. I. Morphogenesis of pancreatic adenocarcinoma in the Syrian golden hamster induced by *N*-nitroso-bis(2-hydroxypropyl)amine. *Am. J. Pathol.* 88: 5–28 (1977).
76. Levitt, M. H., Harris, C., Squire, R., Wenk, M., Mollolelo, C., and Springer, S. Experimental pancreatic carcinogenesis. II. Lifetime carcinogenesis studies in the outbred Syrian golden hamster with *N*-nitroso-bis(2-hydroxypropyl)amine. *J. Natl. Cancer Inst.* 60: 701–705 (1978).
77. Scarpelli, D. G., and Rao, M. S. Pathogenesis of pancreatic carcinoma in hamsters induced by *N*-nitrosobis(2-oxopropyl)amine (BOP). *Fed. Proc.* 37: 231 (1978).
78. Scarpelli, D., and Rao, M. S. Early changes in regenerating hamster pancreas following a single dose of *N*-nitrosobis(2-oxopropyl)amine (NBOP) administered at the peak of DNA synthesis. *Cancer* 47: 1552–1561 (1981).
79. Flaks, B., Moore, M. A., and Flaks, A. Ultrastructural analysis of pancreatic carcinogenesis: morphological characterization of *N*-nitroso-bis(2-hydroxypropyl)amine-induced neoplasms in the Syrian hamster. *Carcinogenesis* 1: 423–438 (1980).
80. Flaks, A., Moore, M. A., and Flaks, B. Ultrastructural analysis of pancreatic carcinogenesis: II. Establishment and morphology of a transplantable pancreatic adenocarcinoma, FCP. *Carcinogenesis* 1: 513–522 (1980).
81. Flaks, B., Moore, M. A., and Flaks, A. Ultrastructural analysis of pancreatic carcinogenesis. III. Multifocal cystic lesions induced by *N*-nitroso-bis(2-hydroxypropyl)amine in the hamster exocrine pancreas. *Carcinogenesis* 1: 693–706 (1980).
82. Flaks, B., Moore, M. A., and Flaks, A. Ultrastructural analysis of pancreatic carcinogenesis. IV. Pseudoductular transformation of acini in the hamster pancreas during *N*-nitroso-bis(2-hydroxypropyl)amine carcinogenesis. *Carcinogenesis* 2: 1241–1253 (1981).
83. Flaks, B., Moore, M. A., and Flaks, A. Ultrastructural analysis of pancreatic carcinogenesis. V. Changes in differentiation of acinar cells during chronic treatment with *N*-nitroso-bis(2-hydroxypropyl)amine. *Carcinogenesis* 3: 485–498 (1982).
84. Flaks, B., Moore, M. A., and Flaks, A. Ultrastructural analysis of pancreatic carcinogenesis. VI. Early changes in hamster acinar cells induced by *N*-nitroso-bis(2-hydroxypropyl)amine. *Carcinogenesis* 3: 1063–1070 (1982).
85. Boquist, L., and Edstrom, C. Ultrastructure of pancreatic acinar and islet parenchyma in rats at various intervals after duct ligation. *Virchows Arch. Pathol. Anat. Abt. A* 349: 69–79 (1970).
86. Herman, L., and Fitzgerald, P. The degenerative changes in pancreatic acinar cells caused by DL-ethionine. *J. Cell Biol.* 12: 277–296 (1962).
87. Volk, B. W., Wellman, K. F., and Lewitan, A. The effect of irradiation on the fine structure and enzymes of the dog pancreas. I. Short term studies. *Am. J. Pathol.* 48: 721–753 (1966).
88. Moore, M. A., Takahashi, I., Ito, N., and Bannasch, P. Early lesions during pancreatic carcinogenesis induced in Syrian hamster by DMPN or DOPN. I. Histologic, histochemical and radioautographic findings. *Carcinogenesis* 4: 431–437 (1983).
89. Moore, M. A., Takahashi, M., Ito, N., and Bannasch, P. Early lesions during pancreatic carcinogenesis induced in Syrian hamster by DMPN or DOPN. II. Ultrastructural findings. *Carcinogenesis* 4: 439–448 (1983).
90. Scarpelli, D. G., and Rao, M. S. Transplantable ductal adenocarcinoma of Syrian hamster pancreas. *Cancer Res.* 39: 452–458 (1979).