

Evaluation of *N*-Acetylcysteine and Methylprednisolone As Therapies for Oxygen and Acrolein-Induced Lung Damage

by Julian A. J. H. Critchley,* J. Michael Beeley,[†]
Robin J. Clark,[†] Mark Summerfield,[‡] Stephen Bell,[‡]
Mark S. Spurlock,[§] Jack A. G. Edginton,[§]
and John D. Buchanan[†]

Reactive oxidizing species are implicated in the etiology of a range of inhalational pulmonary injuries. Consequently, various free radical scavengers have been tested as potential prophylactic agents. The sulfhydryl compound, *N*-acetylcysteine (NAC) is the only such compound clinically available for use in realistic dosages, and it is well established as an effective antidote for the hepatic and renal toxicity of paracetamol. Another approach in pulmonary injury prophylaxis is methylprednisolone therapy. We evaluated NAC and methylprednisolone in two rat models of inhalational injury: 40-hr exposure to >97% oxygen at 1.1 bar and 15-min exposure to acrolein vapor (210 ppm). For oxygen toxicity, NAC (80 mg) or methylprednisolone (10 mg) were given IP every 2 or 6 hr, respectively. For acrolein, single doses of NAC (1 g/kg) and methylprednisolone (30 mg/kg) were given intravenously 15 min before exposure. In sham-exposed control animals, neither treatment favorably effected mortality, lung wet/dry weight ratios, or pulmonary histology. The increases in lung wet/dry weight ratios, seen with both oxygen and acrolein toxicity were reduced with both treatments. However, with oxygen, NAC therapy was associated with considerably increased mortality and histological changes. Furthermore, IP NAC administration resulted in large volumes of ascitic fluid. With acrolein, IV, NAC had no significant effect on mortality or pulmonary histological damage. Methylprednisolone had no beneficial effects on either the mortality or histological damage observed in either toxicity model. We caution against the ad hoc use of NAC in the management of inhalational pulmonary injury.

Introduction

Reactive oxygen species resulting in oxidant-antioxidant imbalance in the lung have been implicated in the pathogenesis of a number of inhalational pulmonary injuries. Hyperoxia leads to the formation of reactive species of oxygen at a rate that overwhelms the natural defense mechanisms of the pneumocytes. The reactive species include superoxide (O_2^-) and hydrogen peroxide (H_2O_2) that may then interact, resulting in the extremely reactive hydroxyl (OH^\cdot) radical (1). Singlet

oxygen (1O_2) can also be produced, which like the hydroxyl radical, can initiate destructive lipid peroxidation of cell membranes (2,3).

Pneumoprotection against such reactive species depends on the cells' antioxidant defense mechanisms, which involve vitamins E and C, β -carotene, superoxide dismutase, catalase, and the glutathione peroxidase system (4). The latter is a key enzyme for the detoxification of lipid peroxides, and the maintenance of reduced glutathione is essential for its function. Acrolein, a highly reactive aldehyde gas that is a conspicuous component of many harmful fire smokes, is similarly inactivated by glutathione conjugation (5).

Several thiol compounds have been shown to protect tissues against oxygen toxicity, either by supporting glutathione biosynthesis or by acting as direct scavengers of reactive electrophilic species via the chemical reactivity of their thiol group (6-9). Four years ago we began a series of experiments to see whether the clinically

*Department of Clinical Pharmacology, University of Edinburgh, UK.

[†]Royal Naval Hospital Haslar, Gosport, UK.

[‡]Admiralty Research Establishment, Alverstoke, UK.

[§]Chemical Defence Establishment, Porton Down, UK.

Address reprint requests to J.A.J.H. Critchley, Department of Clinical Pharmacology, University of Edinburgh, UK.

available thiol-containing drug *N*-acetylcysteine (NAC) had a potential role in the prophylaxis and treatment of oxygen and other forms of pulmonary toxicity such as that from acrolein and phosgene inhalation. NAC has been used for its mucolytic properties for many years and, more recently, has become well established as treatment for oral paracetamol poisoning (10).

A relatively minor pathway of paracetamol metabolism involves cytochrome P-450-dependent microsomal enzymes and leads to the formation of a highly reactive intermediate. In normal dosage, this is harmlessly inactivated by combination with reduced glutathione. However, following overdosage, the glutathione peroxidase system is overwhelmed and severe hepatic and renal damage can occur. The administration of IV or oral NAC within 8 hr of tablet ingestion effectively protects against such tissue damage by either replenishing reduced glutathione stores or combining directly with the toxic intermediate (11).

NAC has proven extremely safe and free from side effects, despite the large IV doses that are given to treat paracetamol poisoning: 150 mg/kg over 15 min, followed by 50 mg/kg over the next 1 hr, and then 100 mg/kg over 16 hr (12). More than 1 g/kg can be tolerated parenterally by rodents (13).

NAC was, and still is, the only free radical scavenger clinically available for intravenous usage in dosages likely to be effective. Thus, although there are theoretically more effective scavengers available in the laboratory, these are many years of development away from routine clinical usage. Consequently, we considered that there was a pressing need for NAC to be evaluated in an animal model, thus mimicking its possible therapeutic use in man for the prevention of oxygen and other forms of inhalational pulmonary toxicity.

Using rats, our oxygen toxicity model was 40 hr of oxygen (> 97%) with the rats breathing at 1.1 bar. We chose acrolein as the noxious gas, and exposed rats to 210 ppm for 15 min. In both models, we compared the effect of NAC treatment with methylprednisolone that had been previously shown in rabbits to decrease mortality following acrolein inhalation (14).

Unfortunately, our results with NAC were very disappointing. Although NAC appeared relatively non-toxic on its own, it potentiated toxicity in both the models. Recently, however, there has been increasing evidence of the beneficial effects of NAC in isolated tissue models (9) and even in whole animals. One report suggested it reduced the mortality from 7 days of oxygen breathing (8), and another report alleged a protective action of NAC against hyperbaric oxygen exposure based on reduced increases in lung wet and dry weights (15).

Somewhat alarmingly, the possible involvement of reactive species in their etiology has resulted in the suggested and actual use of NAC for various lung pathologies, ranging from cystic fibrosis to bleomycin and zinc chloride toxicity (15-17). The use of an unsubstantiated therapy is understandable when treating a life-threatening condition, providing the therapy is safe and

will not exacerbate the underlying pathology. However, the results that we now present below indicate that this may not be the case with NAC.

Methods

The studies were conducted at the Admiralty Research Establishment (Alverstoke, UK) and the Chemical Defence Establishment (Porton Down, UK) under United Kingdom Home Office licenses to experiment on living animals; they were designed to ensure that the minimum number of animals was used to obtain meaningful results. The conduct of the studies was in accord with that recommended in the NIH report *Guide for the Care and Use of Laboratory Animals* (18).

Wistar rats weighing 200 to 250 g were used. They were housed six to a cage and were given food and water *ad libitum*.

Pulmonary Insults

Oxygen Exposure. Exposure was achieved by keeping the caged rats in the two-man airlock of a ten-man therapeutic recompression chamber. The oxygen concentration was kept above 97% and a pressure of 1.1 bar was maintained for 40 hr. Control animals were kept in cages placed in the airlock of an identical ten-man chamber that was open to the atmosphere (i.e., sham exposure).

Acrolein Exposure. Rats were placed in groups of 12 in a 50-L exposure chamber, and acrolein vapor was generated by injecting acrolein (British Drug Houses Ltd.) through an atomizer into the inflow supply of air to the chamber. The volatility of acrolein is such that the evaporation of the fine aerosol is almost instantaneous. Previous experience established that the mixing properties of the chamber were such that the concentrations of acrolein rose to the desired level within a minute of delivering the substance into the atomizer. Concentrations of acrolein vapor during the 15-min exposure, measured using on-line infrared gas analysis, ranged between 207 to 214 ppm (476-514 mg/m³). The control animals were placed in the chamber but not exposed to acrolein (i.e., sham exposure).

Treatments

NAC Administration. Parvolex (Duncan, Flockhart & Co. Ltd.) formulated for IV administration to man was used.

OXYGEN TOXICITY EXPERIMENTS. Twelve rats received 80 mg of NAC (0.4 mL) IP every 2 hr during the course of oxygen exposure. The injections were completed within 10 min, and the oxygen concentration in the chamber returned to over 97% within a further 5 min. Another 12 rats received 0.4 mL 0.9% saline IP every 2 hr during oxygen exposure.

ACROLEIN INHALATION EXPERIMENTS. Twelve rats received a single 1-g/kg dose of NAC IV 15 min prior to acrolein inhalation. Another twelve rats received

0.9% saline (5 mL/kg) IV 15 min prior to acrolein inhalation.

Methylprednisolone Administration. OXYGEN TOXICITY EXPERIMENTS. Twelve rats received 10 mg of methylprednisolone IP every 6 hr during oxygen exposure.

ACROLEIN INHALATION EXPERIMENTS. Twelve rats received a single dose of 300 mg/kg of methylprednisolone IV 15 min prior to acrolein inhalation.

Control Animals. Controls are defined as the rats given one of the three treatments (NAC, methylprednisolone, or saline) but receiving only sham exposure to either oxygen or acrolein. There were four animals in the three treatment groups for each type of sham exposure, except for 12 in the sham oxygen exposure group receiving IP NAC.

Assessment Criteria

Premature Mortality. OXYGEN TOXICITY EXPERIMENTS. During exposure to high concentrations of oxygen, the rats were observed at the injection times every 2 hr. Times of premature death were noted and the animals were assessed as described below. The animals were sacrificed at the end of the 40-hr oxygen exposure period and were treated like those that had died spontaneously.

ACROLEIN INHALATION EXPERIMENTS. Following acrolein inhalation the rats were observed at 2-hr intervals. Times of premature death were noted and the animals assessed as described below. At 24 hr, the surviving animals were sacrificed and treated in a similar manner to those that had died spontaneously.

Lung Preparation. After opening the chest, the pleural cavity was examined for the presence of fluid and volumes greater than 0.2 mL were removed for subsequent analysis for osmolarity and protein content.

The trachea was cannulated, a ligature placed around the root of the main lobe of the left lung, and this lung removed. The lung was placed on a previously weighed

piece of foil, weighed, and then dried in an oven (120°C, in air) for 24 hr before being reweighed. The lung wet/dry weight ratio was then calculated.

Immediately after removal of the left lung, the right lung was inflated *in situ* with modified Millonigs phosphate-buffered formalin forced through the trachea until it was distended to a size equivalent to normal inspiratory expansion. This was achieved by exerting a pressure of 20 to 25 cm of H₂O. The trachea was ligatured. After removal from the animal, the larynx, trachea, heart, and lung were immersed in the same fixative. The right lung was sectioned horizontally into slices 0.5 cm thick. Each slice was imbedded in paraffin and sectioned for light microscopy using hematoxylin and eosin staining.

Histologic Scoring of Lungs. A system of quantifying lung damage was developed so that the extent and severity of changes in the lungs of different animals could be compared (14). Specified histopathologic features were each scored in every lung slice according to the criteria shown in Table 1. The scores for each slice were tabulated and totaled; for each lung, the mean total for all the slices combined was calculated (14).

Peritoneal Fluid. The abdomen was also opened. If a significant volume of peritoneal fluid was present, its volume was measured.

Results

Results for the groups are given as means ± standard deviations, but they were compared by the non-parametric Mann-Whitney (Wilcoxon) two-sample rank sum test unless otherwise stated.

Premature Deaths

The percentage of premature deaths, i.e., those occurring before the experiments were terminated by sacrifice of all the surviving animals, is shown for each treatment group in Figure 1. No premature deaths nor deteriora-

Table 1. Lung histologic scoring.^a

Histological feature	Severity score			
	0	1	2	3
Bronchial wall	Normal	Surface damage	Partial necrosis	Complete necrosis
Alveolar wall	Normal	Cells desquamated	Focal necrosis or hemorrhage	Confluent necrosis or hemorrhage
Pulmonary edema	} Absent	Interstitial	Alveolar	Confluent
Vascular congestion		Mild	Moderate	Severe
Periarterial inflammation				
	Area score			
	Whole slice normal	One-third slice damaged	One- to two-thirds damaged	Two-thirds to whole slice damaged

^aLung histologic scoring: The discriminatory features used for the final scores are shown. The score for each histologic slice was obtained by multiplying the severity score by the area score. These scores for each slice were tabulated, totaled, and the mean total for each lung calculated.

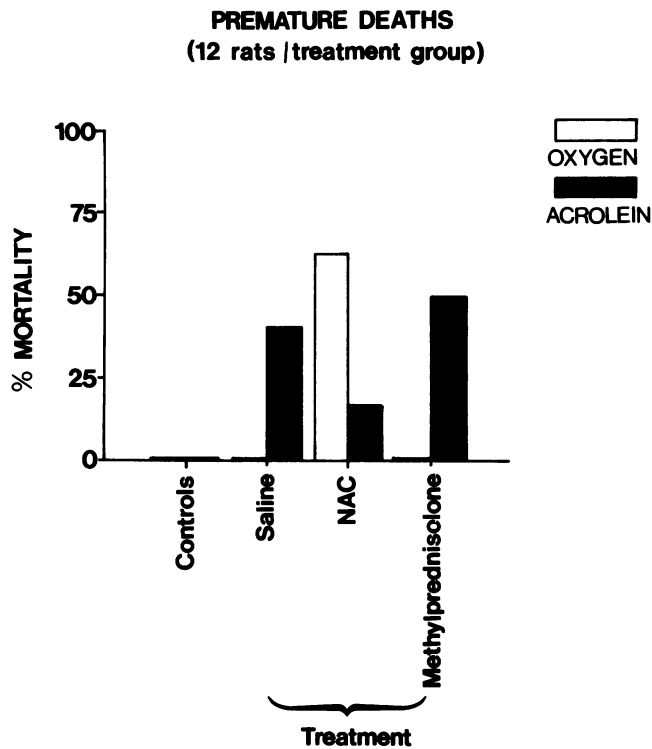


FIGURE 1. Premature deaths (mortality) expressed as a percentage of the total number of animals in each of the three treatment groups. Oxygen-exposed (□) and acrolein-exposed (■) groups are shown as separate histograms. All three treatments are combined for the control (sham-exposed) data.

tion in gross clinical appearance occurred in any of the sham-exposed control groups, indicating that both NAC and methylprednisolone alone were fairly well tolerated.

With oxygen exposure, premature deaths only occurred in the animals receiving NAC, and the mortality of 8 out of the 12 animals—compared with no deaths in the other groups—was significant ($p < 0.05$) by a chi-square test. The NAC group deaths occurred between 36 to 40 hr, and the surviving animals all looked very unwell, compared with those in the other two oxygen-exposed groups.

With acrolein exposure, premature deaths were seen in all three treatment groups. The lowest mortality was

in the NAC treatment groups. The lowest mortality was less than half that in the other two groups, it was not a significant difference by a chi-squared test. The mean times of premature death with their ranges were 11 (5–14) hr, 12 (11–13) hr, and 14.5 (6–21) hr for the saline, NAC, and methylprednisolone groups, respectively.

Pleural Fluid

Significant amounts of pleural fluid were only found in the rats exposed to oxygen, and the mean volumes, osmolarities, and total protein contents are given in Table 2. The sham-exposed control rats in the oxygen experiment and the rats in the acrolein experiment had no significant pleural fluid.

Peritoneal Fluid

Significant amounts of peritoneal fluid were only found in those animals which had received IP NAC. The mean volumes in the oxygen-exposed and sham-oxygen-exposed control animals were 18 ± 16 and 28 ± 19 mL, respectively.

Lung Wet/Dry Weight Ratios

The mean wet/dry weight ratios expressed as a percentage of the mean ratios from the sham-exposed control animals for each pulmonary insult are given in Figure 2. The treatments alone had no favorable effect on the ratio. Thus, for the oxygen and acrolein sham exposures, the data from the three groups were combined to give the mean control values and then were expressed as 100%.

Oxygen exposure resulted in a highly significant increase in the wet/dry lung weight ratios ($p = < 0.0001$), suggesting the presence of pulmonary edema. With both the active treatments the mean ratios were less than with saline. This difference was not significant for NAC but was significant for methylprednisolone ($p = < 0.05$).

Acrolein exposure resulted in a small increase in the mean wet/dry lung weight ratio that was not seen in the two groups receiving active treatments. Thus, the mean ratios in the NAC and methylprednisolone groups were significantly less than that of the saline group ($p = < 0.05$ and < 0.01 , respectively).

Table 2. Pleural fluid in rats exposed to oxygen for 40 hr.

Treatment (number of rats)	Volume, mL	Osmolarity, mOsm/kg	Protein, g/L
Controls (20) ^{a,b} (sham exposure)	< 0.2	—	—
Saline (12)	4.4 ± 2.6	293 ± 17	42 ± 4
NAC (12)	1.3 ± 0.9^c	339 ± 30^c	41 ± 5
Methylprednisolone (12)	6.2 ± 1.2^c	366 ± 45^c	49 ± 4^c

^aThe three treatment groups combined.

^bSignificantly different from saline treatment group; $p = < 0.01$ by the Mann-Whitney (Wilcoxon) two-sample rank sum test.

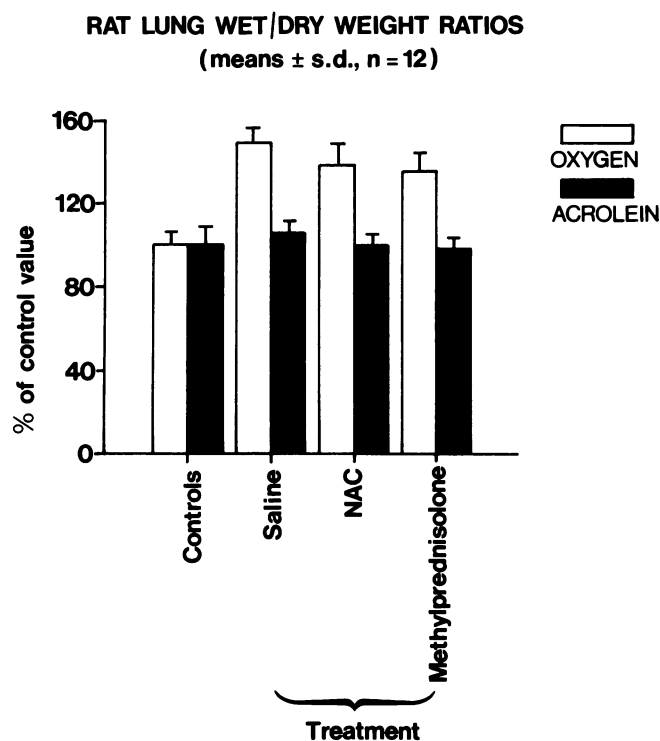


FIGURE 2. Mean (\pm SD.) rat lung wet/dry wt ratios expressed as a percentage of the control data for each of the three treatment groups. Oxygen-exposed (□) and acrolein-exposed (■) groups are shown as separate histograms. All three treatments are combined for the control (sham-exposed) data which is plotted as 100%.

Lung Histology Scores

The means of the individual lung mean totals for the histology scores are given in Table 3. The methylprednisolone data are incomplete, but the full histology data are to be published in a subsequent paper. The toxic effects of both oxygen and acrolein exposure are clear. All the treatment groups for acrolein exposure had equally severe laryngeal damage that was not seen following oxygen exposure. This and bronchial wall damage were major features of acrolein exposure, unlike the oxygen exposure where alveolar damage was a distinctive feature. General tissue edema and vascular congestion were prominent features of both pulmonary insults.

Neither of the active treatments alone (i.e., in sham-exposed animals) appeared to have an effect on lung histology. However, NAC treatment appeared to exacerbate, markedly, the toxic effects of both oxygen and acrolein. With oxygen exposure this difference (from the saline group) was highly significant ($p = < 0.01$).

Discussion

Both our pulmonary insult regimens produced definite lung injury, based on histological criteria, and significant increases in lung wet/dry weight ratios.

The histological changes were qualitatively different. Oxygen exposure caused predominant alveolar damage, while substantial laryngeal and airway edema followed acrolein exposure. This explains the different patterns of premature mortality. While none of the animals died prematurely with oxygen exposure alone, when exacerbated by the NAC therapy, the clinical condition of all the animals steadily deteriorated over the 40-hr exposure period and 8 of the 12 died prematurely after 36 hr. The survivors looked very unwell and hypoxic, suggesting a significant impairment in alveolar gas exchange. However, although acrolein exposure resulted in a 50% premature mortality, the deaths tended to occur early, and the surviving animals looked fairly well. This exposure is compatible with death resulting from upper airway obstruction secondary to edema and less generalized alveolar damage.

NAC treatment, contrary to protecting against oxidant lung damage, actually appeared to exacerbate it on the basis of histological criteria, and—in the case of oxygen toxicity—a dramatic increase in mortality. Variable results have been reported using vitamins E and C, superoxide dismutase, and sulfhydryl compounds to protect against oxidants (4, 6–9, 15–20). Favorable effects with NAC or cysteamine have been described but several are based on reduced lung wet weights (8,15,21) or pleural fluid volumes (21). We also found significant reductions in lung wet weights and pleural fluid volumes using NAC treatment, despite increased histological damage; these findings suggest that these changes may be a consequence of an osmotic or dehydrating effect of the treatment. The smaller volumes of pleural fluid with NAC treatment had a significantly higher osmolarity than those from the saline-treated, oxygen-exposed animals.

Table 3. Lung histology scores: means \pm SD of individual lung mean totals.

Treatment (number of rats)	Oxygen exposure	Acrolein exposure
Control (16, 12) ^a (sham exposure)	3 \pm 1	2 \pm 1
Saline (12,12)	10 \pm 4 ^c	10 \pm 9 ^c
NAC (12,12)	17 \pm 6 ^c	16 \pm 5 ^c
Methylprednisolone (12)	—	8 \pm 8 ^c

^aThe respective treatment groups combined.

^bSignificantly different from controls ($p = < 0.01$).

^cSignificantly different from controls and saline group; $p = < 0.01$ by the Mann-Whitney (Wilcoxon) two-sample rank sum test.

Patterson and coworkers (8) reported a reduction in mortality from 78 to 28% when treating rats with 7 days of 99% oxygen exposure and with continuous infusions of NAC in a dose of 390 mg/kg/day, but they did not perform lung histology. Their results were less favorable when the dose was increased to 600 mg/kg/day (mortality 43%).

We chose higher doses still, which may explain why we encountered adverse effects on mortality that were possibly due to NAC acting as an electron donor at high concentrations in an environment rich in reactive species. From our control data, these high doses of NAC did not appear toxic in the absence of an oxidant pulmonary insult.

For the oxygen toxicity study, the NAC dose was based on the initial dose used to treat paracetamol poisoning in man. The frequency of administration was based on the short half-life of sulfhydryl compounds in plasma. Our pilot experiments revealed that the elevated sulfhydryl group activity following IV NAC administration fell rapidly with a half-life of less than 1 hr when measured by a 5,5'-dithiobis-(2-nitrobenzoic acid), (DTNB) based assay (22). Similar results had been obtained in man using an HPLC assay (D. R. Jarvie, unpublished observations). Since IV administration would have been impractical in our oxygen toxicity model and NAC therapy is effective orally in man, we gave the NAC by IP injections at intervals of 2 hr. Although this regimen alone did not have any noticeable effects on the general condition of the animals or their lungs, it did result in a local reaction as manifested by the accumulation of large volumes of peritoneal fluid.

We did not confirm the favorable action of methylprednisolone on the mortality from acrolein exposure reported by Beeley and coworkers (14). As the latter workers found, methylprednisolone did not reduce the amount of histological damage. On the other hand, it did result in significant reductions in lung wet/dry weight ratios with both acrolein and oxygen exposure. However, the volumes of pleural fluid and their osmolarity and protein content were significantly increased with methylprednisolone in the oxygen toxicity experiments.

The value of methylprednisolone in the treatment of oxidant-type pulmonary insults remains an open question. However, our results suggest that NAC administration may exacerbate the lung damage from such insults, and we caution against its indiscriminate or ad hoc use in man.

We thank Surgeon Commander John D. Buchanan, Royal Naval Hospital, Haslar, Gosport, Hampshire, UK, for the histological examination of the rat lungs.

REFERENCES

1. Pryor, W. A. Oxy-radicals and related species: their formation,

- their lifetimes, and their reactions. *Ann. Rev. Physiol.* 48: 657-667 (1986).
2. Halliwell, B., and Gutteridge, J. M. C. Oxygen toxicity, oxygen radicals, transition metals and disease. *Biochem. J.* 219: 1-14 (1984).
3. Jamieson, D. D., Chance, B., Cadenas, E., and Boveris, A. The relation of free radical production to hyperoxia. *Ann. Rev. Physiol.* 48: 703-719 (1986).
4. Riley, D. J., and Kerr, J. S. Oxidant injury of the extracellular matrix: potential role in the pathogenesis of pulmonary emphysema. *Lung* 163: 1-13 (1985).
5. Boor, P. J., Sanduja, R., Nelson, T.J., and Ansari, G. A. *In vivo* metabolism of the cardiovascular toxin, allylamine. *Biochem. Pharmacol.* 36: 4347-4353 (1987).
6. Gerschman, R., Gilbert, D. L., Nye, S. W., Dwyer, P., and Fenn, W. O. Oxygen poisoning and X-irradiation: a mechanism in common. *Science* 119: 623-626 (1954).
7. Gerschman, R., Gilbert, D. L. and Caccamise, D. Effects of various substances on survival times of mice exposed to different high oxygen tensions. *Am. J. Physiol.* 192: 563-571 (1958).
8. Patterson, C. E., Butler, J. A., Byrne, F. D., and Rhodes, M. L. Oxidant lung injury: intervention with sulfhydryl reagents. *Lung* 163: 23-32 (1985).
9. Cotgreave, I. A., and Moldeus, P. Lung protection by thiol-containing antioxidants. *Bull. Eur. Physiopathol. Respir.* 23: 275-7 (1987).
10. Prescott, L. F., Illingworth, R. N., Critchley, J. A. J. H., Stewart, M. J., Adam, R. D., and Proudfoot, A. T. Intravenous N-acetylcysteine: the treatment of choice for paracetamol poisoning. *Br. Med. J.* 2: 1097-1100 (1979).
11. Prescott, L. F., and Critchley, J. A. J. H. The treatment of acetaminophen poisoning. *Ann. Rev. Pharmacol. Toxicol.* 23:87-101 (1983).
12. APBI Data Sheet Compendium 1988-89. Datapharm Publications Limited, Whitehall, London, 1988.
13. Johnston, R. E., Hawkins, H. C., and Weikel, J. H., Jr. The toxicity of N-acetylcysteine in laboratory animals. *Semin. Oncol.* 10(Suppl. 1): 17-24 (1983).
14. Beeley, J. M., Crow, J., Jones, J. G., Minty, B., Lynch, R. D., and Pryce, D. P. Mortality and lung histopathology after inhalational lung injury. The effect of corticosteroids. *Am. Rev. Respir. Dis.* 133: 191-196 (1986).
15. Jamieson, D. D., Kerr, D. R., and Unsworth, I. Interaction of N-acetylcysteine and bleomycin on hyperbaric oxygen-induced lung damage in mice. *Lung* 165: 239-247 (1987).
16. Jensen, T., Kharazmi, A., Schitz, P. O., Nielsen, H., Stenvang-Pedersen, S., Stafanger, G., Koch, C., and Hiby, N. Effect of oral N-acetylcysteine administration on human blood neutrophil and monocyte function. *APMIS* 96: 62-67 (1988).
17. Hjorts, E., Qvist, J., Bud, M. I., Thomsen, J. L., Andersen, J. B., Wiberg-Jrgensen, F., Jensen, N. K., Jones, R., Reid, L. M., and Zapol, W. M. ARDS after accidental inhalation of zinc chloride smoke. *Intensive Care Med.* 14: 17-24 (1988).
18. Department of Health Education and Welfare. Guide for the care and use of laboratory animals. 1978 Revised Ed. Office of Science and Health Reports. DRR/NIH, DHEW Publication No. 80-23, Bethesda, MD, 1980.
19. Currie, W. D., Gelein, R. N., and Sanders, A. P. Comparison of protective agents against hyperbaric oxygen in large animals. *Aerospace Med.* 44: 996-998 (1973).
20. Schatte, C., and Swansinger, A. Effect of dietary "antioxidant" supplementation on the susceptibility to oxygen toxicity in mice. *Aviat. Space Environ. Med.* 47: 147-150 (1976).
21. Bakhle, Y. S., and Stuart, E. F. Reversal by N-acetyl cysteine (NAC) of lung injury induced by α -naphthylthiourea (ANTU) in rats. In: *Proceedings of Chemicals and Lung Toxicity, BALR Summer Meeting, 1988.*
22. Ellman, G. L. Tissue sulfhydryl groups. *Arch. Biochem. Biophys.* 82: 70-77 (1959).