

# Structure and Function of the Somatosensory System: A Neurotoxicological Perspective

by Joseph C. Arezzo\*, Herbert H. Schaumburg\* and Peter S. Spencer\*

The somatosensory system comprises those elements of the peripheral nervous system (PNS) and the central nervous system (CNS) subserving the modalities of touch, vibration, temperature, pain and kinesthesia. Specific modalities can be associated with unique peripheral receptors, peripheral axons of stereotyped diameter and specific central projection pathways. Several features of the somatosensory system render regions of it vulnerable to a wide variety of toxicants. The present report highlights these features and, furthermore, suggests that analysis of these regions is invaluable in studying the three most common varieties of toxic neuropathy: toxic distal axonopathy, toxic myelinopathy and toxic sensory neuronopathy.

## Receptors

### Structure and Function

Since the early nineteenth century, various specialized receptors have been associated with the somatosensory system. These receptors, located in skin, hair follicles, joints and muscles, transduce mechanical or thermal energy. Minimally, a receptor includes a peripheral axon terminal of one primary afferent neuron, whose cell body is sited proximally in the dorsal root ganglion. Receptors often include nonneural elements which incorporate and interact with the axon terminal in initiating generator potentials. Multiple generator potentials may summate to the threshold necessary for triggering a nerve impulse (action potential). Three major categories of somatosensory receptors can be identified: mechanoreceptors, thermoreceptors and

nociceptors. These categories are further subdivided on the basis of location and rate of adaptation.

Mechanoreceptors are sensitive to nondamaging mechanical disturbances of skin or hair. An example of a slowly adapting position detector is a Type I Iggo corpuscle, featured by a myelinated axon terminating at the base of a small dome-like elevation in the skin (Merkel cells). Displacement of the dome by as little as 5  $\mu\text{m}$  can result in a supra-threshold generator potential within the Merkel cell-axon terminal complex. Mechanoreceptors sensitive to rapid transients are exemplified by the Pacinian corpuscles. The Pacinian corpuscle is principally composed of an outer capsule formed of connective tissue lamellae separated by fluid-filled interlamellar spaces, and an inner core of tightly spaced lamellae (Fig. 1). Proximally, the outer core is penetrated by a canal which contains a single myelinated pre-terminal axon (7-11  $\mu\text{m}$  across), continuous with a long naked axon terminal deep in the center of the corpuscle. The long terminal axon is elliptical in section, is provided with juxtaposed filopod processes, and has a bulbous ultraterminal ending from whose entire surface filopod processes emanate in a hydra-like array. Filopod processes appear to con-

---

\*Institute of Neurotoxicology, Departments of Neuroscience, Neurology and Pathology (Neuropathology), Rose F. Kennedy Center, Albert Einstein College of Medicine, Bronx, New York 10461.

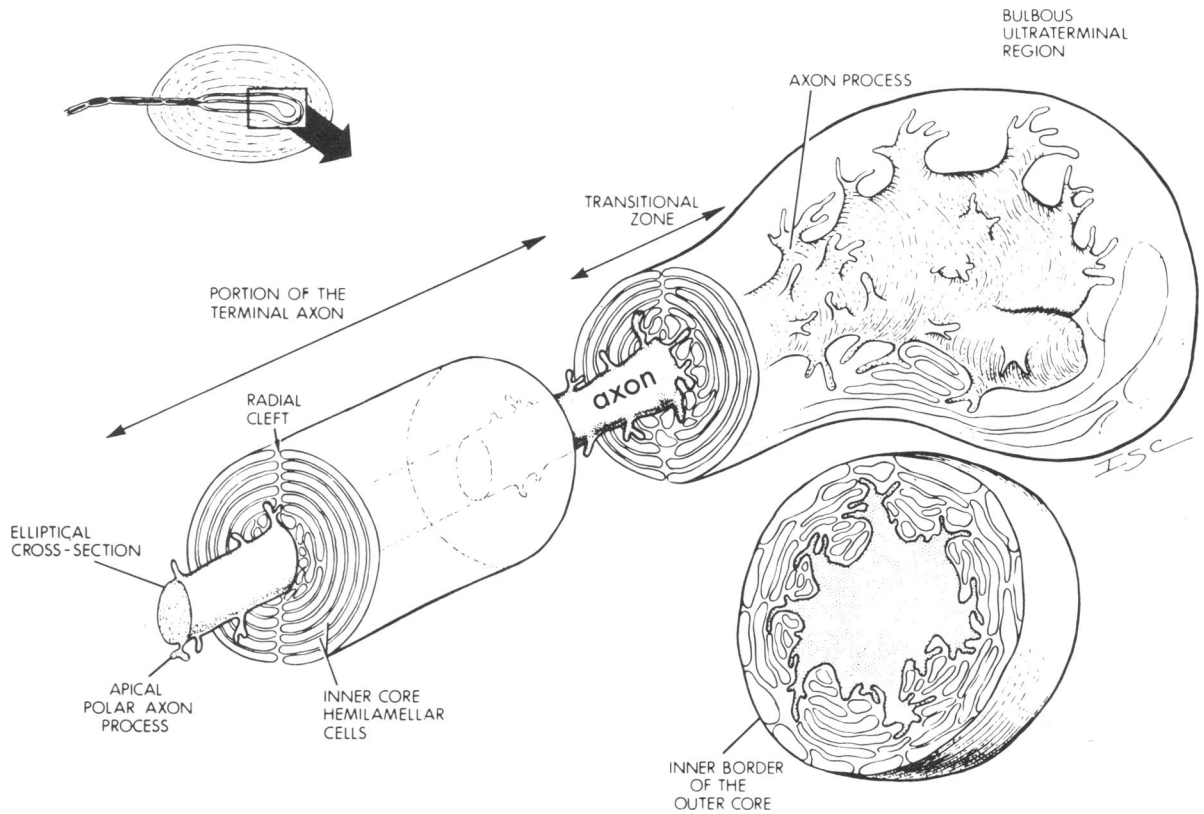


FIGURE 1. Three-dimensional diagram of a Pacinian corpuscle indicated by the boxed area in the upper left diagram, illustrating the distal end of the terminal segment, the transitional zone and the ultraterminal region. Lower right: a cross-sectional view of the ultraterminal chamber. From Spencer and Schaumburg (1).

tact the inner core lamellae. This physical relationship may provide the substrate for transmitting fast pressure changes characteristic of these rapidly adapting vibration receptors (1).

Cutaneous thermoreceptors display three consistent properties: static discharge at constant temperature; dynamic response to temperature change; and relative insensitivity to mechanical stimuli. Although both warm and cold skin spots have been repeatedly mapped, no specific encapsulated or corpuscular receptor has been consistently identified. Thermoreceptors most likely are branching matrices of naked axons terminating in the stratum papillare. Their terminations contain numerous small vesicles and mitochondria. Nociceptors for pain also appear to be "free nerve" endings in skin and muscle.

## Neurotoxicology

Toxic neuropathy characterized by degeneration in the distal segments of large-diameter axons (distal axonopathy) is a common morphological reaction

of the peripheral nervous system to exogenous toxins (2, 3). The neural elements of somatosensory receptors in the hands and feet represent the distal extreme of long afferent fibers, and thus, are particularly vulnerable in the distal axonopathies. Selective receptor inactivation is an early change following exposure to certain neurotoxins, e.g., failure of the generator potential, followed by loss of the axon filopod processes in Pacinian corpuscles, are early physiological and morphological alterations following acrylamide intoxication (4, 5). Toxic sensory neuronopathy, characterized by degeneration of dorsal root ganglion cells, produces degeneration in sensory axons of peripheral nerves and, presumably, of their axon terminals in receptors (6).

## Peripheral Nerve

### Structure and Function

Large nerves, such as the tibial, consist of several fascicles containing numerous myelinated and

### Environmental Health Perspectives

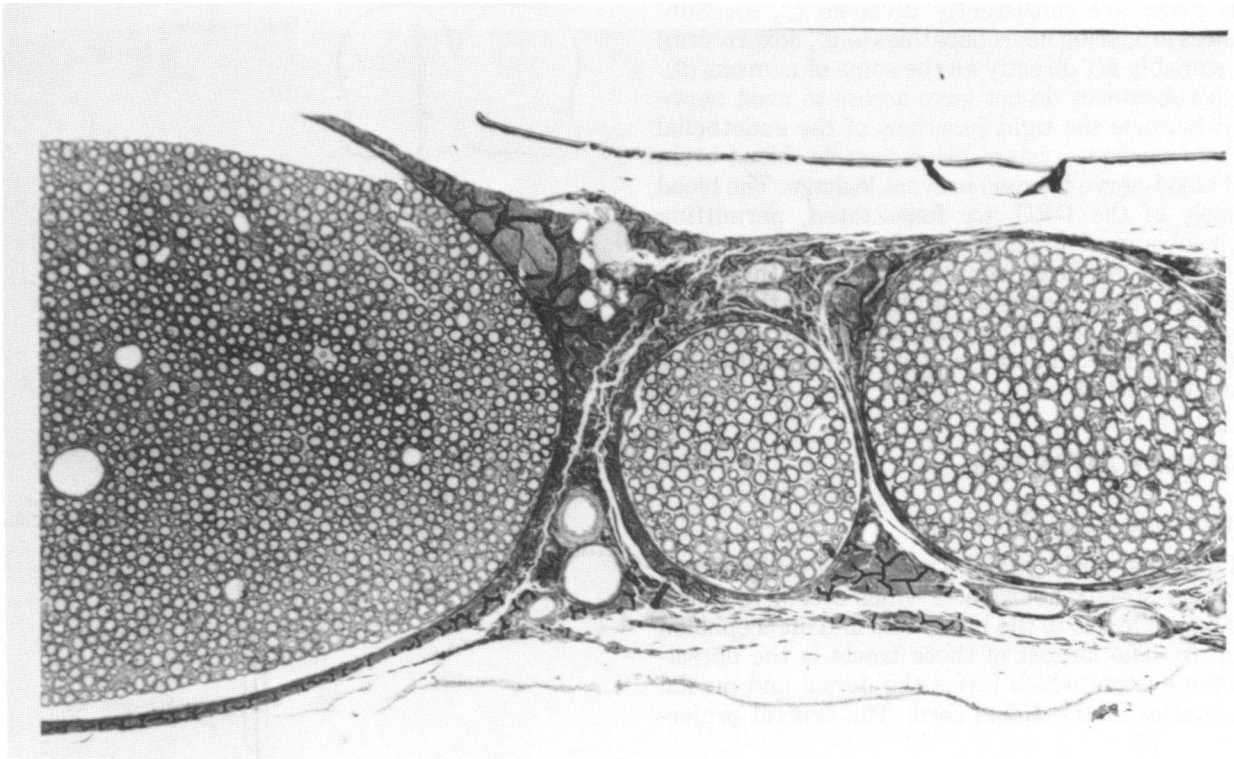


FIGURE 2. Light micrograph of a transverse section of a portion of mammalian tibial nerve and its branches, each containing numerous myelinated axons. Epoxy section, 1  $\mu\text{m}$ , stained with toluidine blue.  $\times 180$ .

unmyelinated axons (Fig. 2). Each fascicle is enclosed by a perineurial ensheathment, which serves as a diffusion barrier and accounts for much of the tensile strength of the nerve. Distally, the perineurium fuses with the connective tissue of encapsulated sensory receptors, but does not cover free nerve endings. Proximally, the perineurium surrounds the dorsal root ganglia, which contains the cell body of the primary afferent fiber, and is continuous with the root sheaths. The axon of nerve fibers is ensheathed by a chain of Schwann cells. In myelinated fibers, this ensheathment takes the form of a multilayered membranous structure (myelin), a product of the Schwann cell. Interruptions between each length of myelin sheath, called nodes of Ranvier, occur at regularly spaced intervals along the length of the nerve fiber.

Afferent fibers of the somatosensory system vary in cross-sectional diameter from approximately 0.4  $\mu\text{m}$  to 20  $\mu\text{m}$ . The rate of impulse conduction varies directly with the diameter of the axon. Heavily myelinated axons are fast conductors, while thinly myelinated and unmyelinated axons conduct less rapidly. Subpeaks of the compound action potential can be used to classify axons as to size and conduc-

tion velocity. Mechanoreceptors are predominately subserved by medium- and large-size myelinated fibers, while thermoreceptors and nociceptors rely on relatively small myelinated and unmyelinated fibers. However, there is considerable overlap, and no conduction velocity uniquely specifies a receptor class.

### Neurotoxicology

The bipolar dorsal root ganglion cell (DRG) and its long, heavily myelinated axons are exquisitely vulnerable to each of the three common types of neurotoxic injury. Distal axonopathies (e.g., acrylamide, *n*-hexane) are characterized by selective degeneration of long large-diameter axons. Therefore, bipolar DRG neurons whose peripheral processes extend the length of the sciatic nerve, and whose central processes traverse the length of the spinal cord to the gracile nucleus, are early affected. Toxic myelinopathies (e.g., hexachlorophene, acetyl ethyl tetramethyltetralin) are associated with bubbling of PNS and CNS myelin sheaths. The long, heavily myelinated axons of the bipolar DRG neuron, extending for great lengths both to CNS

and PNS, are consistently involved (7, 8). Substances producing neuropathies (e.g., doxorubicin) presumably act directly on the soma of neurons (9). Such substances do not have access to most nerve cells because the tight junctions of the endothelial cells of nervous system blood vessels (blood-brain and blood-nerve barrier) prevent leakage. The blood vessels of the DRG are fenestrated, permitting such substances to leak out and selectively damage these neurons (toxic sensory neuropathy). This produces rapid degeneration throughout the length of peripheral sensory axons and dorsal columns. Sensory nerves in upper and lower extremities are equally affected.

## Spinal Pathways

### Structure and Function

The spinal cord contains a number of well-defined, modality-specific fiber tracts which ascend from the segmental levels to the brainstem and diencephalon (Fig. 3). The largest of these tracts is the dorsal-column system which forms the dorsal and medial boundaries of the spinal cord. The central projec-

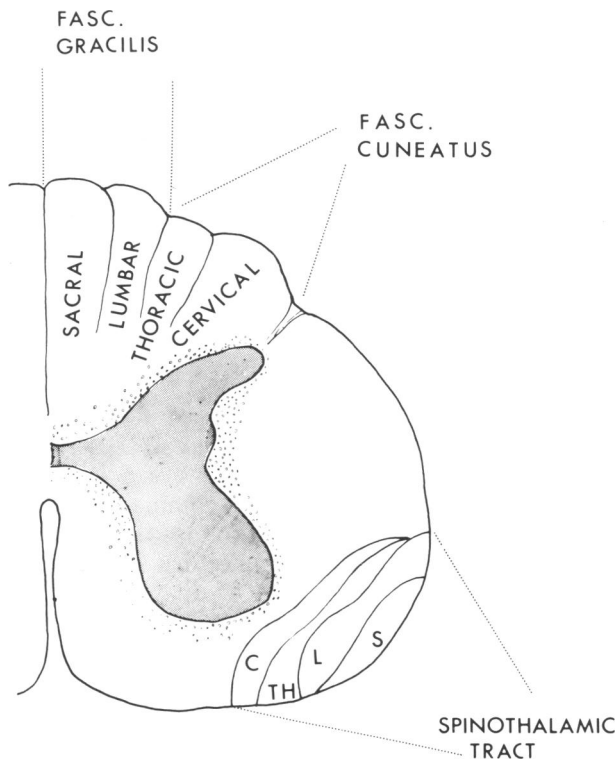


FIGURE 3. Schematic diagram of a cervical segment of the human spinal cord outlining the dorsal column and spinothalamic fiber tracts.

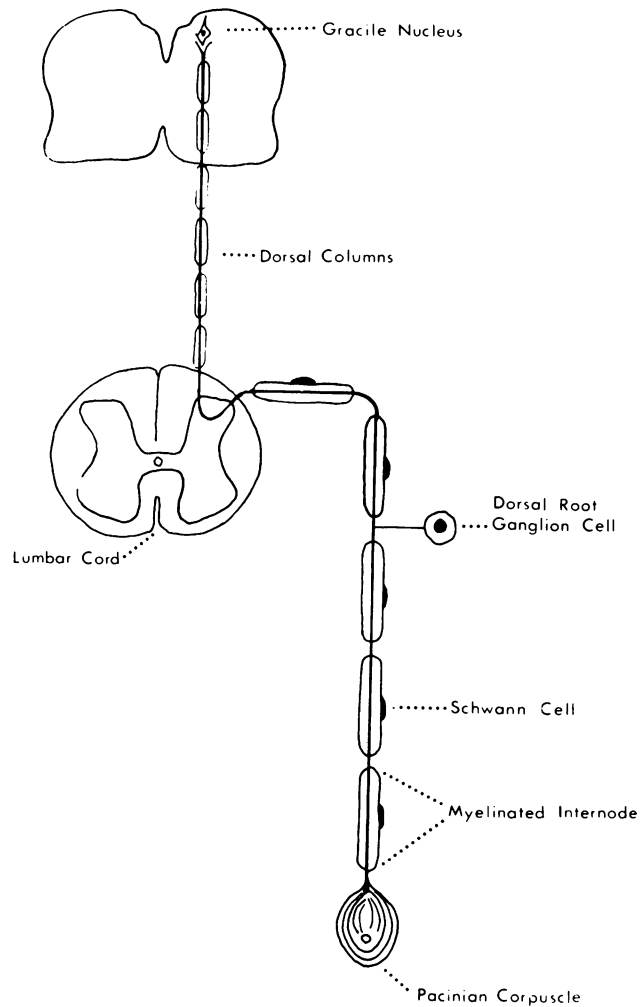


FIGURE 4. Diagram of a dorsal root ganglion cell, depicting the ascending (central) branch of the bipolar axon terminating in the gracile nucleus and the descending (peripheral) branch ending in a Pacinian corpuscle.

tions of dorsal root ganglia course in the medial division of the dorsal root, enter the spinal cord and divide into a long ascending and a short descending branch (Fig. 4). Fibers from caudal-most levels become located medially in the dorsal columns at progressively higher levels, as entering axons are laid down at the lateral margin of the tracts. Thus, the medial bundle of fibers (fasciculus gracilis) originates from segments below the mid-thoracic region while the lateral portion (fasciculus cuneatus) contains fibers from upper thoracic and cervical segments. In addition to the large-diameter fibers entering directly from DRG neurons (primary afferents), the dorsal columns contain many small-diameter primary afferents (conducting under 25 m/sec). Approximately 10% of the dorsal column fibers origi-

nate from cells within the spinal cord (nonprimary afferents). Sensations of touch, vibration and kinaesthesia are conveyed by the dorsal columns. The termination of this system is in the ipsilateral dorsal column nuclei of the medulla oblongata.

The anterior and lateral spinothalamic tracts convey modalities of pain and temperature, as well as touch. Primary afferents of this system course through the lateral division of the dorsal root and enter the spinal gray matter where they contact several interneurons. Axons of the last neuron in the local relay obliquely cross the cord, within one segment of entry, and ascend in the spinothalamic tract. There is both topographic and modality-specific organization within the spinothalamic tracts. The most lateral fibers represent the caudal segments of the body, and fibers concerned with pain are, in general, anterior to those conveying temperature. The central projections of the spinothalamic tracts are complex and include several thalamic nuclei (VPL, intralaminar, posterior), as well as reticular nuclei of the brainstem.

The spinocervical tract is a recently discovered pathway responsive to hair movement and skin stimulation. This tract arises entirely within the spinal cord from cells in the dorsal horn of the grey

matter. Small fibers of the dorsal root enter the cord and synapse on dorsal-horn neurons. Axons of these cells ascend as spinocervical tract fibers within the dorsolateral fasciculus on the side of root entry, terminating in the lateral cervical nucleus at the uppermost level of the spinal cord. Axons from cells in the lateral cervical nucleus cross the midline and terminate within the VPL nucleus of the thalamus.

A spinoreticular pathway also courses in the ventral quadrant of the spinal cord. The origin of this pathway is complex and largely unknown.

## Neurotoxicology

Many of the dorsal-column fibers represent central projections of bipolar DRG cells, and, as described in the previous section, are exquisitely vulnerable in the three common forms of neurotoxic injury. Myelinopathic agents may cause in bubbling of myelin throughout the length of the dorsal columns. Toxins producing distal axonopathy cause degeneration that is initially confined to the rostral ends of the long fibers ascending the gracile fasciculi. The shorter fibers of the cuneate fasciculi are relatively spared in the distal axonopathies (Fig. 5). Neuronopathic agents affect DRG cells at multiple

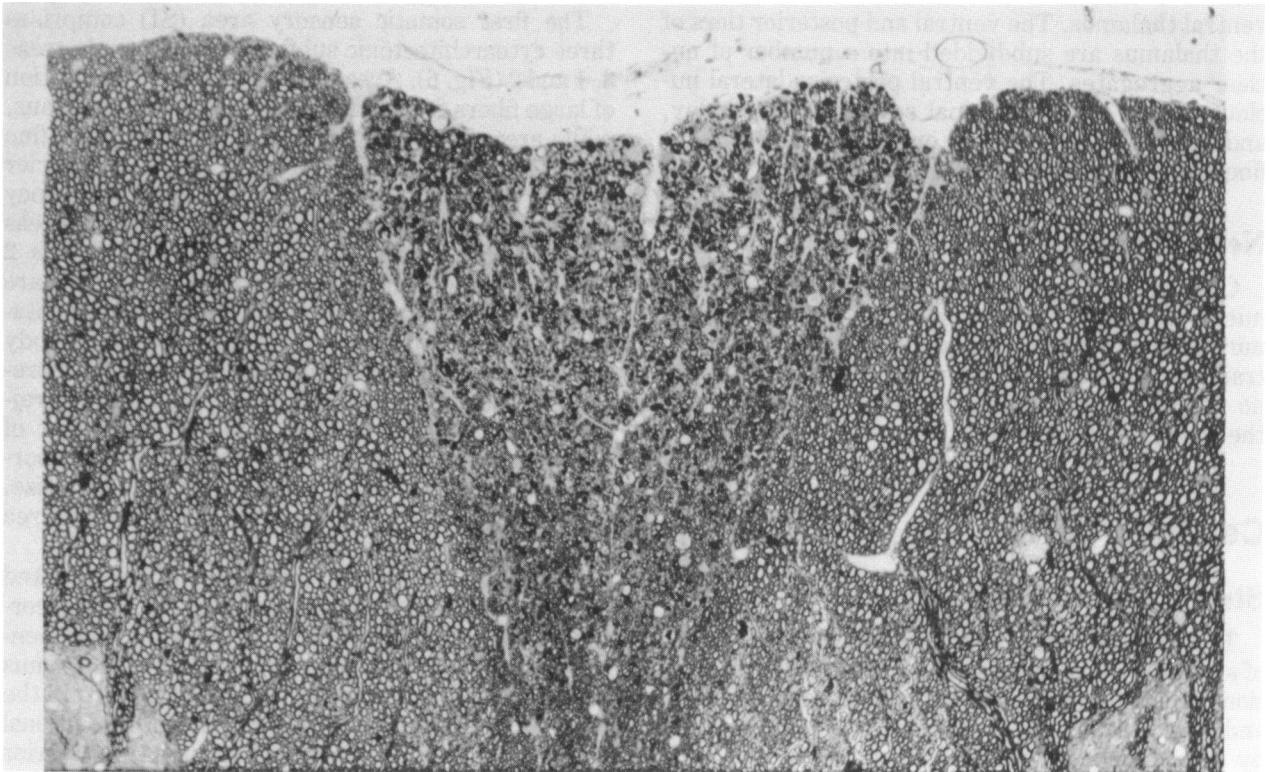


FIGURE 5. Medulla oblongata of a rat with hexacarbon distal axonopathy showing selective degeneration of the gracile tracts (center).  $\times 240$ . From Spencer and Schaumburg (2).

levels resulting in virtually simultaneous axonal degeneration throughout the length of the gracile and cuneate fasciculi.

Other ascending spinal somatosensory pathways are relatively unaffected in neurotoxic conditions. Degeneration in rostral spinocervical axons occasionally occurs in experimental distal axonopathies.

## Relay Nuclei

### Structure and Function

Neurons in somatosensory relay nuclei, (dorsal column, ventral thalamic, lateral cervical) receive projections from ascending spinal tracts, then project to more rostral structures in the neuraxis. Integration of activity and modification of the ascending volley by corticofugal influences occurs at these sites. Pre- and postsynaptic feedback inhibition characterizes all levels of the somatosensory system and significantly alters the afferent volley.

The dorsal column nuclei (gracile and cuneate) maintain a remarkable degree of topographic and modality specificity. Axons from cells in these nuclei cross as internal arcuate fibers in the low medulla and ascend in the medial lemniscus to the ventral thalamus. The ventral and posterior tiers of the thalamus are subdivided into a number of nuclear aggregates. The ventral posterior lateral nucleus (VPL) is the principal somatosensory relay, and serves as the site of origin for the primary fibers of the thalamo-cortical radiations.

## Neurotoxicology

Changes in the dorsal column and lateral cervical nuclei following various types of neurotoxic injury mirror those of the dorsal columns and spinocervical tracts described in the previous section. There are no reports of neurotoxin-induced degeneration in the thalamic relay nuclei.

## Cerebral Cortex

### Structure and Function

The cerebral cortex controls conscious perception of somatosensory events. The previous simple division of the sensorimotor cortex into precentral (motor) and postcentral (sensory) strips has been replaced by a broad based, multiple mapping of the body surface onto the cortex. Serial and parallel processing of somatosensory information occur at disparate cortical locations and involve extensive interneuron

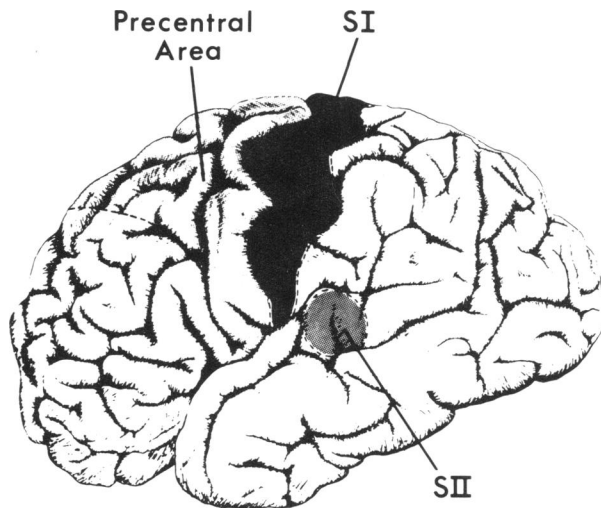


FIGURE 6. Lateral view of the human cerebral cortex outlining the location of the SI, SII and precentral somatosensory regions. Additional somatosensory areas can be found on the medial surface and within the banks of the central and Sylvian fissures.

pools, making it difficult to localize the site of action of neurotoxic agents on cortical activity.

The first somatic sensory area (SI) comprises three cytoarchitectonic subfields, Brodmann's areas 3, 1 and 2 (Fig. 6). Area 3 receives a dense projection of large fibers from the ventral tier of the thalamus, while areas 1 and 2 receive less dense input of fine fibers from this region. Area 3 and the anterior portion of area 1 principally process short-latency cutaneous and muscle-spindle afferents, whereas the posterior portion of area 1 and all of area 2 receive inputs from deep lying receptors. There are at least two independent mirror-image representations of body surface within SI. For each body representation the caudal dermatomes are represented medially; progressively rostral regions project to more lateral cortical areas. The extent of cortical representation of a body region is proportioned to the use of that region, and not to its size. Thus, in the sensory homunculus, the thumb area exceeds that of the remainder of the arm.

Electrophysiological studies have documented short-latency somatosensory activity within the cortex forming the precentral gyrus (10). Independent, direct projections from the ventral thalamus can be traced to this region, terminating within the anterior bank of the central sulcus (area 4). Additional cortical somatosensory regions include the superior and inferior parietal lobule, the SII region within the Sylvian fissure, the retroinsular field and polysensory frontal cortex.

## Neurotoxicology

It is clear that many neurotoxicants diffusely affect the cerebral cortex by provoking a variety of morphological, pharmacological and physiological reactions. This is especially common following acute exposure to these agents. None appears selectively to involve the somatosensory cortex. Similarly, among substances that produce CNS degeneration only after prolonged or subacute exposure, few predominantly affect the somatosensory cortex. However, methylmercury frequently produces widespread, selective degeneration of small neurons in the pre- and postcentral gyrus, with only minor involvement of the regions of the frontal and parietal lobe. Mercury also affects small neurons of the calcarine cortex granule cell layer of the cerebellum and dorsal root ganglion cells.

## Monitoring of the Somatosensory System: Relevance for Neurotoxicology

A salient feature of the somatosensory system is the remarkable length and heavy myelination of its lower conduction pathways. The length of the lower pathways allows noninvasive physiological monitoring at several points. For example, human sensory nerve and spinal-cord conduction velocity measurements are routine clinical procedures. Recent advances in computer-averaged electrophysiological procedures enable the noninvasive recording of activity within somatosensory fiber tracts of higher levels of the CNS in man and experimental animals (11, 12) (Fig. 7). Somatosensory-evoked potentials are currently being applied to trace the onset of

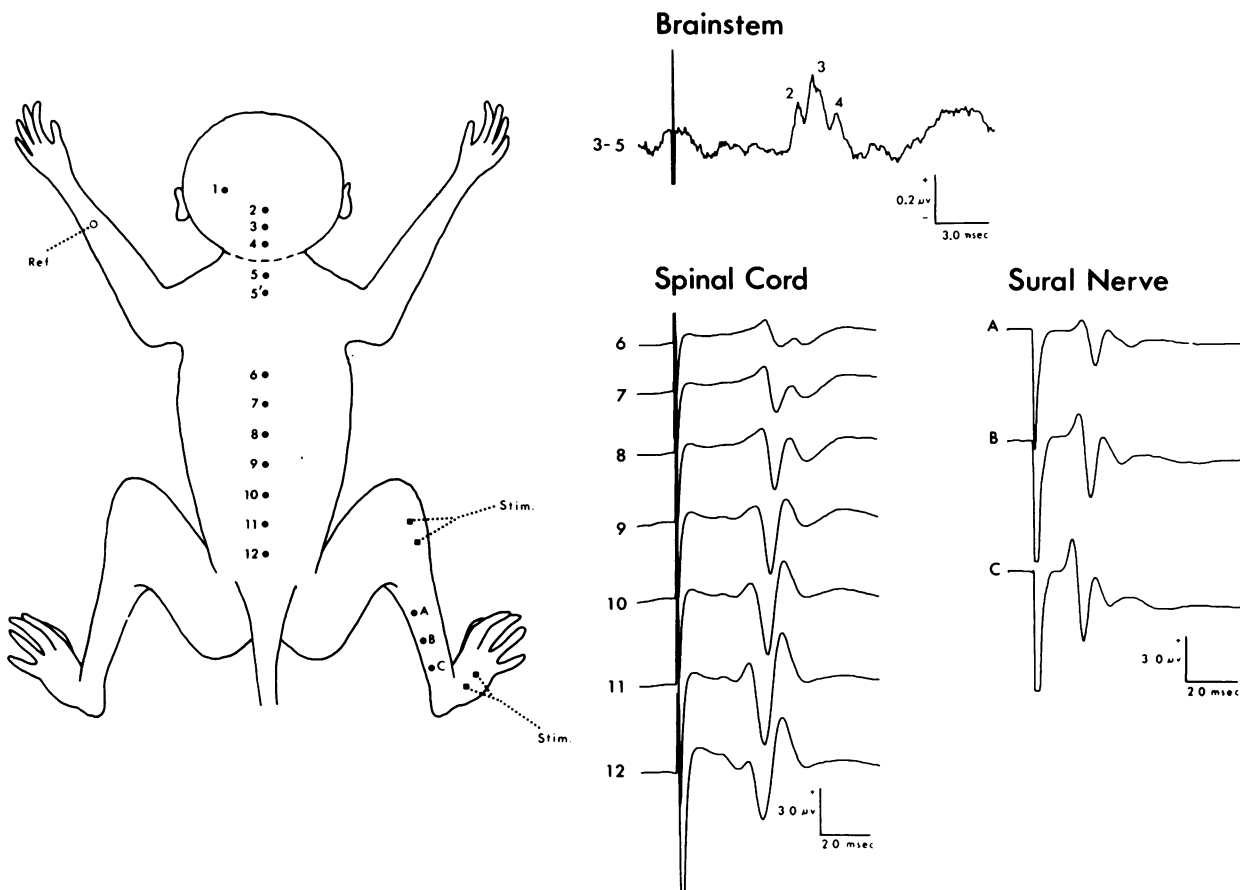


FIGURE 7. Averaged somatosensory evoked potentials recorded overlying sural nerve, cauda equina, spinal cord and brainstem. Activity was elicited by a suprathreshold electric shock delivered to the sural nerve.



acrylamide-induced distal axonopathy in the primate (12). Initial dysfunction appears at the distal extreme of the gracile component of the dorsal-column system. The change consists of a subtle latency shift (approximately 100  $\mu$ sec), precedes any behavioral alterations and appears coincident with the earliest detectable morphological change in this nucleus. The sensitivity of this measure appears established, and current studies are focusing on changes in the somatosensory-evoked potential following prolonged low-level acrylamide intoxication and on the ability of the CNS to recover from toxic distal axonopathy.

The authors thank Ms. Laurell Edwards and Ms. Linda Murphy for secretarial assistance and Jim Barna, Monica Bischoff and Kathy Ederle for preparing the illustrations.

This work was supported by MH 06723 and USPHS grants OH 00535, OH 00851, NS 00356, and ES 02168.

### REFERENCES

1. Spencer, P. S., and Schaumburg, H. H. An ultrastructural study of the normal feline Pacinian corpuscle. *J. Neurocytol.* 2: 217-235 (1973).
2. Spencer, P. S., and Schaumburg, H. H. Distal axonopathy—one common type of neurotoxic lesion. *Environ. Health Perspect.* 26: 97-105 (1978).
3. Spencer, P. S., and Schaumburg, H. H. Classification of neurotoxic diseases: A morphological approach. In: *Experimental and Clinical Neurotoxicology*, P. S. Spencer and H. H. Schaumburg, Eds., Williams and Wilkins, Baltimore, 1980, pp. 92-99.
4. Spencer, P. S., and Schaumburg, H. H. Central and peripheral distal axonopathy—the pathology of dying-back polyneuropathies. In: *Progress in Neuropathology*, H. M. Zimmerman, Eds., Grune and Stratton, New York, Vol. 3, 1977, pp. 253-295.
5. Schaumburg, H. H., Wisniewski, H., and Spencer, P. S. Ultrastructural studies of the dying-back process. I. Peripheral nerve terminal and axon degeneration in systemic acrylamide intoxication. *J. Neuropath. Exptl. Neurol.* 33: 260-284 (1974).
6. Serman, A. B., Schaumburg, H. H. and Asbury, A. K. The acute sensory neuronopathy syndrome: a distinct clinical entity. *Ann. Neurol.* 7: 354-358 (1979).
7. Towfighi, J. Hexachlorophene. In: *Experimental and Clinical Neurotoxicology*, P. S. Spencer and H. H. Schaumburg, Eds., Williams and Wilkins, Baltimore, 1980, pp. 440-455.
8. Spencer, P. S., Foster, G. V., Serman, A. B., and Horoupian, D. Acetyl ethyl tetramethyl tetralin. In: *Experimental and Clinical Neurotoxicology*, P. S. Spencer and H. H. Schaumburg, Eds., Williams and Wilkins, Baltimore, 1980, pp. 296-308.
9. Cho, E.-S., Spencer, P. S., and Jortner, B. S. Doxorubicin. In: *Experimental and Clinical Neurotoxicology*, P. S. Spencer and H. H. Schaumburg, Eds., Williams and Wilkins, Baltimore, 1980, pp. 430-439.
10. Arezzo, J. C., Legatt, A. D., and Vaughan, H. G., Jr. Topography and intracranial sources of somatosensory evoked potentials in the monkey. II. Cortical components. *Electroenceph. Clin. Neurophysiol.* 51: 1-18 (1981).
12. Arezzo, J. C., Vaughan, H. G., Jr., and Legatt, A. D. Topography and intracranial sources of somatosensory evoked potentials in the monkey. I. Early Components. *Electroenceph. Clin. Neurophysiol.* 46: 155-172 (1979).
13. Arezzo, J. C., Schaumburg, H. H., Spencer, P. S., and Vaughan, H. G., Jr. A novel approach in detecting toxic axonal neuropathies: The brainstem somatosensory evoked potential. *Ann. Neurol.* 8: 96-97 (1980).