

The penicillin was stopped after 23 days and a total dose of 460 megaunits. The next day the blood count showed white cells 2,300/mm³, with neutrophils 160 (7%) and platelets 40,000. Examination of bone marrow surprisingly showed hypercellularity with a myeloid-erythroid ratio of 3:1. The differential count (checked three different times on different slides) showed a pronounced and sudden shift towards mature cells in both the myeloid and erythroid series. There were more mature polymorphonuclear leucocytes and normoblasts than there were of their earlier forms. There were no cells of abnormal size and shape. The megakaryocytes and platelets were normal in number. Over the next two weeks the blood gradually returned to normal, and a reticulocytosis preceded a rise in haemoglobin to 13.4 g/100 ml.

Seventeen days after penicillin treatment had been stopped the patient was given a test dose of 1 megaunit of crystalline penicillin intravenously. No other new drug was given. Measures for resuscitation were available for immediate use. The only outward reaction was a mild, transient itching of the palms and soles. The most striking change in the peripheral blood count was a sharp drop in the neutrophil count from 6,500 to 840/m³ in 48 hours. In contrast, the total lymphocyte count dropped only slightly from 3,500 to 3,000/mm³. The counts of all other blood cells also fell slightly. Particularly interesting was a drop in reticulocyte count from 3.2 to 0.2%. Repeated direct and indirect Coombs tests were again negative. Three days after the test dose, when the neutrophil and reticulocyte counts were at their lowest, the bone marrow was hypercellular. Smears showed a myeloid-erythroid ratio of 4:1. Again the mature neutrophils and normoblasts outnumbered their earlier forms. The megakaryocytes appeared normal in number and shape. Within one week of the test injection white cells and platelets had returned to their previous levels and a reticulocytosis had begun. The patient was discharged on the 98th day after admission and has not been seen since.

Comment

In this case the relation between penicillin and the pancytopenia was proved by the challenge injection. The pathogenesis of the anaemia, however, was not the usual one of peripheral blood-cell destruction. The decrease in *all* the blood elements, including the reticulocytes (but not the lymphocytes), in the absence of detectable signs of haemolysis or leucocyte agglutination and lack of measurable levels of antipenicillin antibody point to involvement of the bone marrow. The paradox of a hypercellular bone marrow and peripheral blood pancytopenia can be explained in a number of ways.

Firstly, it might be due to a fortuitous sampling of an island of erythropoietic activity in an otherwise aplastic marrow (Movitt *et al.*, 1963). This is unlikely in our case in view of the rapid rise in the peripheral blood count after the discontinuance of therapy. A depleted marrow is unable to regenerate so promptly. Secondly, there might be intramedullary haemolysis with resultant pancytopenia, but a haemolytic process acting in the bone marrow and not in the peripheral circulation is difficult

to envisage. Furthermore, the marrow showed no signs of a haemolysis and contained no abnormally shaped cells or macrocytes. Thirdly, a so-called maturation arrest of marrow elements is easily excluded in the present patient because mature cells rather than earlier forms predominated in the marrow, and the drop in the peripheral blood count was too rapid for such a process (Cronkite and Fliedner, 1964).

Finally, the paradox might be explained by impaired release of normal mature cells from the marrow. Katz *et al.* (1966) described a chemical mediator for the release of granulocytes from the marrow. King-Smith and Morley (1967) in their study of a release mechanism predicted that a mild degree of bone marrow failure would deplete the storage pool, thus removing the damping effect of the feed-back mechanism on the release of mature granulocytes and resulting in wide oscillations in the peripheral neutrophil count. This prediction was continued by Morley and Stohlman (1970), who produced cyclic neutropenia in dogs treated with small daily doses of cyclophosphamide. Morley and Stohlman (1969) also showed oscillations in the reticulocyte count of normal dogs, which they believed to be due to the same feed-back mechanisms.

We believe that the pancytopenia in the present patient was due to a penicillin-induced blockade of the release of mature cells of perhaps all three blood elements from the bone marrow. The rise in the reticulocyte count after stopping treatment and its abrupt fall after the test injection can also be taken to imply arrested release from the bone marrow. Finally, the surfeit of mature elements in the bone marrow suggests a blockade of their release. To propose an entirely new mechanism for anaemia on the basis of one case and without any of the elegant methodology needed for the study of the kinetics of erythropoiesis is perhaps too presumptuous. Nevertheless, our case calls attention to the existence of release factors and the part they might play in certain cases of bone marrow failure.

We thank Dr. David Clement, Yale School of Medicine, and Professor Klaus Betke, University Children's Clinic, Munich, for reviewing the case and encouraging its presentation.

References

- Cronkite, E. P., and Fliedner, T. M. (1964). *New England Journal of Medicine*, 270, 1403.
- Katz, R., Gordon, A. S., and Lapin, D. M. (1966). *Journal of the Reticuloendothelial Society*, 3, 103.
- King-Smith, E. A., and Morley, A. A. (1967). In *Proceedings of the Twentieth Annual Conference on Engineering in Medicine and Biology*, vol. 9, section 19. New York, Institute of Electrical and Electronics Engineers.
- Morley, A., and Stohlman, F. jun. (1969). *Science*, 165, 1025.
- Morley, A., and Stohlman, F. jun. (1970). *New England Journal of Medicine*, 282, 643.
- Movitt, E. R., Mangum, J. F., and Porter, W. R. (1963). *American Journal of Medicine*, 34, 500.

Case of Cryptococcosis of Spine

P. BALASUBRAMANIAM, J. F. SILVA

British Medical Journal, 1973, 2, 27-28

Clinically cryptococcal infection of the spine has been mistaken for tuberculosis (Koshi, 1961; Morris and Wolinsky, 1965). We report a case because of the rarity of spinal involvement and of the difficulty in diagnosis. Cryptococcosis produces a sarcoid

reaction and when the organisms cannot be identified in tissue sections it may be mistaken for sarcoidosis.

A 34-year-old Indian woman with mitral stenosis due to rheumatic heart disease had a first episode of pulmonary oedema during the last trimester of her fourth pregnancy. She was managed conservatively and had a normal delivery at term. Seven months later she had a mitral valvotomy, during which hard glands were found under the aortic arch. These were diagnosed histologically as sarcoidosis. She was discharged from hospital after 24 days, but six days later was readmitted with pain in the left side of the chest and dyspnoea. She was then found to have a gibbus over the fifth thoracic spinous process and was transferred to the University Hospital.

She was in pain, even lying down. Both submandibular and tonsillar glands were palpable and tender. She had coarse crepitations in the mid-zone of the left lung. Liver and spleen were not palpable. There was a tender gibbus over the fifth thoracic spinous process, but no neurological signs. Radiological examination showed a collapse of the body of the fifth thoracic vertebra with erosion of its left pedicle and a

Department of Orthopaedic Surgery, University of Malaya, Kuala Lumpur, West Malaysia

P. BALASUBRAMANIAM, M.B., F.R.C.S., Associate Professor
J. FRANCIS SILVA, F.R.C.S., F.A.C.S., Professor and Head of Department

paraspinal mass (Fig. 1). The adjoining disc spaces were intact. Relevant results of other investigations were: E.S.R. (Westergren) 60 mm/1 hr; Mantoux test (1 : 1,000) negative; serum calcium concentrations, measured on six occasions over 19 days, 6.2, 5.7, 4.9, 5.8, 6.8, and 7.3 mEq/l. respectively; corresponding serum phosphate concentrations 2.3, 2.8, 2.8, 2.8, 2.8, and 2.5 mg/100 ml; total plasma

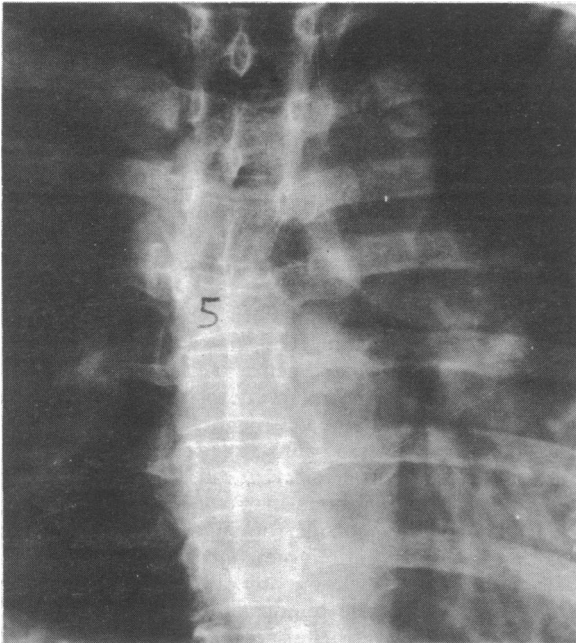


FIG. 1—Antero-posterior radiograph showing partial collapse of body of fifth thoracic vertebra, erosion of its left pedicle, and paraspinal abscess. Adjoining disc spaces intact.

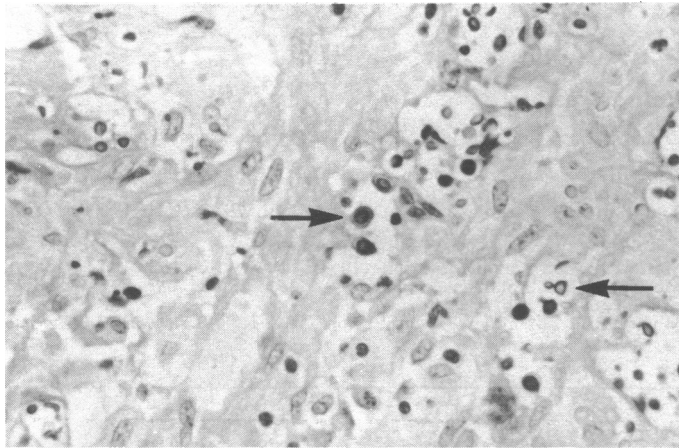


FIG. 2—Photomicrograph of biopsy material from body of fifth thoracic vertebra showing noncaseating granulomatous inflammation and cryptococci (arrowed). (PAS-Alcine Blue. $\times 428$.)

proteins 7.9 g/100 ml—albumin 3.53 g/100 ml, globulin 4.37 g/100 ml, albumin/globulin ratio 0.81.

Tuberculosis of the spine was provisionally diagnosed. The patient was immobilized in a plaster bed and given antituberculous chemotherapy. Her general condition improved after three weeks and an exploration of the spine was advocated because the provisional diagnosis was in doubt. The tuberculin test was negative even with a dilution of 1 : 1,000 and the radiological appearance of the thoracic spine with an intact disc space was not typical of tuberculosis. On exploration of the dorsal spine through an anterolateral approach (J.F.S.) the medial end of the fifth left rib was found to be eroded and there was a paraspinal abscess with thick, whitish pus. She was quite well immediately after operation but eight hours later she collapsed and died, probably from pulmonary embolism. Permission for necropsy was refused by the relatives.

Culture of pus from the paraspinal abscess grew cryptococcus. Histological examination of curetings of the fifth dorsal vertebra showed a granulomatous inflammation and cryptococci (Fig. 2).

Comment

The pathological and clinical features of tuberculosis and cryptococcosis are similar. The granulomatous inflammatory reaction produced by *Cryptococcus neoformans*, especially in the lymph nodes and in the bone, may contain typical non-caseating tubercles just as are seen in the "sarcoid reaction." When the organisms cannot be identified, as is often the case in tissue sections, it may be impossible to distinguish between the two diseases (Bernad and Owens, 1960). The sections of the aortic glands could not be obtained for review from the hospital where the mitral valvotomy had been performed. If cryptococcus organisms could have been shown in these by specific stains it would have disproved the diagnosis of sarcoidosis. Boeck's sarcoidosis and cryptococcosis seldom coexist (Collins, 1950; Allcock, 1961; Collins (1950) reported three cases but two of them were later shown to have had cryptococcosis alone.

Once torulosis has been provisionally diagnosed it must be diligently pursued through each of the necessary tests. The Indian ink preparations may be negative when there are only a few organisms. The culture may also be negative when too little material is available. In these cases intracerebral inoculation of the pus into mice is essential before torula infection can be ruled out (Cowen, 1969). A raised serum calcium level may be due to prolonged immobilization in bed (Winters *et al.*, 1966). The spine should be explored if necessary to clarify the diagnosis.

References

- Allcock, E. A. (1961). *Journal of Bone and Joint Surgery*, **43B**, 71.
 Bernad, L. A., and Owens, J. C. (1960). *Archives of Internal Medicine*, **106**, 101.
 Collins, V. P. (1950). *American Journal of Roentgenology*, **63**, 102.
 Cowen, N. J. (1969). *Clinical Orthopaedics and Related Research*, **66**, 174.
 Koshi, G. (1961). *Indian Journal of Pathology and Bacteriology*, **7**, 264.
 Morris, E., and Wolinsky, E. (1965). *Journal of Bone and Joint Surgery*, **47A**, 1029.
 Winters, J. L., Kleinschmidt, A. G., Frensilli, J. J., and Suttan, M. (1966). *Journal of Bone and Joint Surgery*, **48A**, 1182.