

infants, usually with poor outcome. This is very unlikely to be the cause of cycling CBFV as the majority of infants where this has been seen had no evidence of brain injury. Similarly seizures which can affect intracranial pressure and cerebral blood flow could theoretically cause such cycling, but no evidence of fits has been found in the babies studied. In our infant there was no history of asphyxia and clinically no evidence of convulsions.

The primitive phenomenon of an immature autoregulatory response suggested by Anthony *et al* remains the most likely mechanism.¹ Rhythmic changes in vessel tone occurring throughout both large and small arteries would result in the cycling in cerebral blood volume seen in our infant. It would be interesting, though technically very difficult, to use both Doppler and NIRS simultaneously to clarify

this further. The clinical significance of this cycling pattern remains unclear.

Finally, it is clear that NIRS can detect changes in cerebral blood volume giving an indication of changes in cerebral blood flow. It is thus a useful monitoring technique that may serve to improve understanding of the pathophysiology of neonatal brain injury.

- 1 Anthony MY, Evans DH, Levene MI. Cyclical variations in cerebral blood flow velocity. *Arch Dis Child* 1991;66:12-6.
- 2 Cowan F. Cerebral blood velocity in the sleeping normal newborn infant. Studies on the cerebral circulation of the newborn infant. Oslo: A/S Holstad-Trykk, 1987:107-31. (Thesis.)
- 3 Livera LN, Spencer SA, Thorniley MS, Wickramasinghe YABD, Rolfe P. The effects of hypoxaemia and bradycardia on neonatal cerebral haemodynamics. *Arch Dis Child* 1991;66:376-80.
- 4 Livera LN, Wickramasinghe YABD, Spencer SA, Rolfe P, Thorniley MS. Comparison of blood volume changes detected by near infra-red spectroscopy and venous occlusion plethysmography. *Early Hum Dev* 1991;25:53.

Neonatal renal candidal bezoar

V K Rehan, D C Davidson

Abstract

Renal candidal bezoar is uncommonly encountered in neonatal intensive care. An affected neonate who improved only after surgical removal of obstructive fungus from the renal pelvis and local irrigation with amphotericin B is described. The need for early consideration of surgical intervention is stressed.

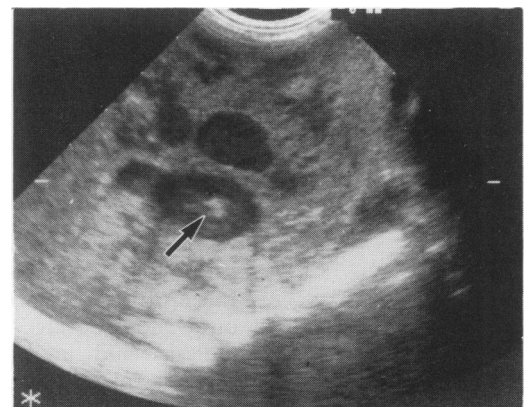
Candida albicans is ubiquitous in the neonatal environment. Although superficial candidal infections of skin and mucosa are common, disseminated candidiasis and specific visceral candidal involvement occur infrequently and fungal obstruction of the urinary tract poses a specific management problem.¹ Predisposing factors include prematurity, intravascular catheters, broad spectrum antibiotics, immunosuppression, and total parenteral nutrition.²

Case report

A boy weighing 900 g was delivered at 27 weeks' gestation. The Apgar scores were 7 and 8 at 1 and 5 minutes respectively. He was electively ventilated from 20 minutes of age and transferred to us, aged 7.5 hours. Ventilatory support was required for idiopathic respiratory distress. By 40 days of age he had been weaned from the ventilator. He required phototherapy, parenteral nutrition, and repeated courses of antibiotics for proved bacterial infections. He developed posthaemorrhagic hydrocephalus that arrested spontaneously. By 2 months of age he was feeding, thriving, and was discharged.

At the age of 10 weeks he was readmitted for elective cryotherapy for stage 3+ retinopathy of prematurity. He appeared unwell, was moderately jaundiced, had abdominal distension, hepatosplenomegaly, and a palpable left

kidney. An abdominal ultrasound scan showed bright echoes in the left renal pelvis compatible with a candidal bezoar (figure). *C. albicans* was repeatedly cultured from blood and urine. The plasma urea concentration rose from 3 to 19 mmol/l and the serum creatinine from 40 to 145 µmol/l. Amphotericin B was started as an intravenous infusion over six hours at 100 µg/kg/day and gradually increased to 500 µg/kg/day over five days. Flucytosine in a dose of 100 mg/kg/day in four divided doses as an intravenous infusion over 30 minutes was also given. Two weeks later, despite systemic antifungal treatment, there was neither clinical nor biochemical improvement and both urine and blood cultures remained positive. *C. albicans* was reported as sensitive to flucytosine and amphotericin B and serum concentrations were in excess of the minimum inhibitory concentration in vitro. An echocardiogram showed no evidence of valvular vegetations. A decision was made to use local antifungal treatment. A nephrostomy tube was placed percutaneously in



Ultrasound scan of left kidney in the long axis showing echobright lesion (bezoar) in renal pelvis.

Royal Liverpool
Children's Hospital,
Alder Hey,
Eaton Road,
Liverpool L12 2AP
V K Rehan
D C Davidson

Correspondence to:
Dr Rehan.

Accepted 10 July 1991
(*Arch Dis Child* 1992;67:63-4)

the left renal pelvis under ultrasound guidance and secured by a skin suture. Local renal irrigation was carried out with 10 ml of sterile water containing amphotericin B at a concentration of 50 µg/ml instilled six times a day through the nephrostomy tube.

This tube became dislodged at 48 hours and at open nephrostomy a fungal pelvic ball was identified, removed, and a further nephrostomy tube was secured in the renal pelvis. Multiple abscesses were present throughout the renal cortex.

Within 24 hours there was appreciable clinical improvement and the plasma urea and creatinine concentrations returned to normal within four days. Systemic antifungal treatment and local amphotericin B irrigation were continued for six weeks, that is, two weeks after the last positive urine culture. The ultrasound scan showed complete resolution and normal renal echogenicity.

At the age of 10 months there was a mild left sided hydronephrosis on ultrasound but the dimercaptosuccinic acid (DMSA) scan showed good renal function. A mercapto-acetyl-triglycine renogram showed partial obstruction of the left ureter but the micturating cystourethrogram showed normal bladder and urethra without vesicoureteric reflux. Blood and urine cultures have remained sterile.

Discussion

Although superficial candidal infections are well recognised, systemic and renal candidiasis is less commonly described. Recently there has been an increase in reported cases. This may merely reflect an improved clinical awareness or alternatively may indicate a true increase as a consequence both of the increasing complexities of neonatal intensive care and the availability of non-invasive renal imaging techniques. In adults serum precipitin antibodies to candidal antigens have been valuable in the diagnosis of visceral infections.³ In neonates the presence of intraleucocytic hyphae on buffy coat examination has proved useful in diagnosis of candidaemia (negative smear in our patient).⁴ There are no accepted standard diagnostic criteria for neonatal urinary candidiasis in terms of colony count. It is preferable to examine and culture urine obtained by suprapubic aspiration rather than by a bag collection.

Ultrasound appearances depend upon the extent of involvement. The findings of bright echoes in a dilated renal pelvis of a child who has positive fungal cultures either in urine or blood is highly suggestive of a renal mycotic bezoar.

WHAT IS THE MECHANISM OF RENAL CANDIDAL INFECTION AND BEZOAR FORMATION?

In animals, large doses of *C. albicans* injected intravenously have caused generalised candidiasis and multiple organ involvement, whereas smaller doses have produced transient candidaemia and only isolated renal involvement. These studies suggest that renal involvement starts as an acute pyelonephritis leading to

multiple cortical abscesses and scarring within nine to 11 days after inoculation. At that stage candidal mycelia can be identified within the tubular lumen of the renal medulla and local proliferation leads to papillary necrosis, bezoar formation, and obstructive uropathy.⁵ Alternatively it has been suggested that isolated renal involvement may represent an ascending infection. Additional predisposing factors include acidic and hypertonic urine, caliceal urinary stasis, and kidney anomalies.⁶

Therapeutic options for renal candidiasis include systemic antifungal drugs, local irrigation of renal pelvis via nephrostomy tube, and surgical removal of an obstructive candidal bezoar or nephrectomy. To our knowledge, there has been no report of a neonate with candidal septicaemia and renal candidal bezoar who has survived without surgical intervention.

Although parenteral antifungals are generally given for several weeks, as in our patient, we could find no therapeutic guidelines for renal pelvic irrigation in neonates. In adults, however, amphotericin B bladder irrigation has been used for six to 14 days in the treatment of non-invasive urinary candidiasis. In our patient we considered that local treatment should continue until blood, urine, and nephrostomy cultures were consistently negative and there was no longer ultrasound evidence of candidal bezoar. A six week course of irrigation was necessary and was well tolerated. Percutaneously placed nephrostomy tubes can become dislodged and their position should be checked after each instillation. A properly positioned nephrostomy tube will allow free backflow on aspiration and failure should be an indication to verify the tube position by ultrasound scan.

We feel that all neonates with systemic candidal infection must have an abdominal ultrasound scan to exclude renal candidal bezoar. Once recognised it should be managed by immediate percutaneous placement of a nephrostomy tube followed by local irrigation with amphotericin B in addition to systemic antifungal treatment. Treatment should be guided by clinical status and regular abdominal ultrasound scans. Open nephrostomy and surgical removal of the bezoar should be considered if: (i) clinical response is poor, (ii) renal function deteriorates, (iii) bezoar size fails to regress, and (iv) there are mechanical problems with amphotericin B irrigation.

Constant vigilance and early diagnosis of this insidious onset opportunistic infection managed as outlined above should improve the long term prognosis and preserve renal function.

- 1 Keller MA, Sellers BB, Melish ME, Kaplan GW, Miller KE, Mendoza SA. Systemic candidiasis in infants. *Am J Dis Child* 1977;131:1260-3.
- 2 Hoe HN, Tonkin ILD. Renal candidiasis in a neonate. *J Urol* 1981;127:517-9.
- 3 Wise GJ, Ray B, Kozinn PJ. The serodiagnosis of significant genitourinary candidiasis. *J Urol* 1972;107:1043.
- 4 Cattermole HEJ, Rivers RPA. Neonatal candida septicaemia: diagnosis on buffy smear. *Arch Dis Child* 1987;62:302-4.
- 5 Hurley R, Winner HI. Experimental renal moniliasis in a mouse. *Journal of Pathology and Bacteriology* 1963;86:75-82.
- 6 Pappu LD, Purohit DM, Bradford BF, Turner WR Jr, Levkoff AH. Primary renal candidiasis in two preterm neonates. *Am J Dis Child* 1984;138:923-6.