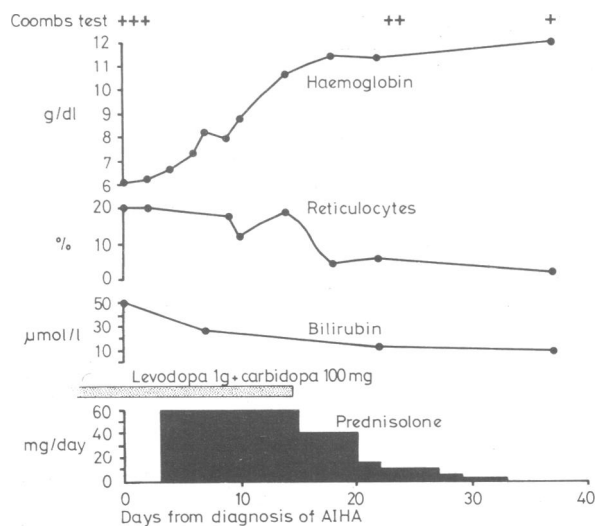


next year this was changed to combination chemotherapy with levodopa 1 g and carbidopa 100 mg daily (Sinemet). He remained well for a year but then became tired and pale. On admission to the Royal Free Hospital, London, he was anaemic and mildly jaundiced with no hepatosplenomegaly, no lymphadenopathy, and a clear chest radiograph. There was akinesia but no rigidity or tremor.

Results of investigations were: haemoglobin concentration 6.3 g/dl; reticulocytes 20%; nucleated red cells to white blood cells 5:100; white cell count  $9 \times 10^9/l$  ( $9000/mm^3$ ); platelet count  $310 \times 10^9/l$ ; serum bilirubin concentration, total 50  $\mu mol/l$  (2.9 mg/100 ml), conjugated 19  $\mu mol/l$  (1.1 mg/100 ml); liver enzymes normal; serum folate concentration 9  $\mu g/l$ ; antinuclear antibody titre 10; serology for syphilis negative; direct Coombs test strongly positive. The red cells reacted strongly with antihuman IgG. The eluate and serum showed anti-e specificity, titre 64, against rr cells at 37°C. There was also a cold antibody, titre 8, against adult and cord red cells at 18°C, unreactive above 30°C. Bone marrow aspirate showed increased erythropoiesis.

The haemolysis was controlled with prednisolone. Levodopa-carbidopa was stopped and the prednisolone tailed off without relapse (figure). The Coombs test became less strongly positive. Parkinsonian akinesia worsened, so bromocriptine was begun. The patient then returned to France, where some weeks later levodopa-carbidopa was reinstated. The direct Coombs test became strongly positive with the same specificity as before, and the haemolytic anaemia shortly recurred. Haemolysis was again suppressed with steroids but levodopa-carbidopa was continued and the Coombs test remained positive.



Resolution of haemolytic anaemia with initial steroid treatment and withdrawal of levodopa-carbidopa.

Conversion: SI to traditional units—Serum bilirubin: 1  $\mu mol/l \approx 0.06$  mg/100 ml.

## Comment

In this patient AIHA developed during treatment with levodopa-carbidopa and recurred on its reintroduction. The Coombs test was not performed before beginning treatment with levodopa. During the year that he was taking levodopa alone he had no clinical evidence of AIHA. The dopa-decarboxylase inhibitor reduces extracerebral breakdown of levodopa, so that lower dosage does not result in less exposure to the drug. While in one case<sup>3</sup> a similar regimen of combination chemotherapy reduced haemolysis, in the present patient severe haemolysis occurred.

I thank Dr C Symons for permission to report this case.

<sup>1</sup> Worledge, S M, Carstairs, K C, and Dacie, J V, *Lancet*, 1966, **2**, 135.

<sup>2</sup> Gabor, E P, and Goldberg, L S, *Scandinavian Journal of Haematology*, 1973, **11**, 201.

<sup>3</sup> Lindstrom, F D, Leiden, G, and Engstrom, S, *Annals of Internal Medicine*, 1977, **86**, 298.

<sup>4</sup> Barat, M, et al, *Nouvelle Presse Médicale*, 1977, **6**, 2442.

(Accepted 26 March 1979)

Department of Medicine, Royal Free Hospital, London NW3 2QG  
ROBERT M BERNSTEIN, MA, MRCP, medical registrar (present address:  
Department of Medicine, Hammersmith Hospital, London W12 0HS)

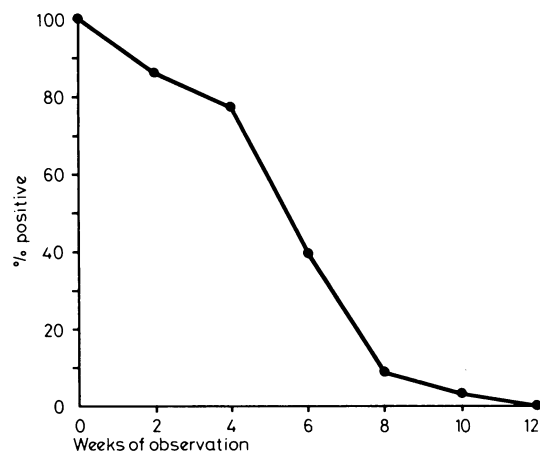
## Pharyngeal neisseria gonorrhoeae: coloniser or pathogen?

During the past decade there has been increasing awareness of the prevalence of gonococcal pharyngeal infection.<sup>1</sup> The natural history of the condition is not clear. Most cases are asymptomatic and it is difficult to show a significant correlation between symptoms in the throat and the presence of *Neisseria gonorrhoeae*.<sup>1</sup> Gonococcal pharyngeal infection has been implicated as a risk factor for disseminated disease, and treatment-failure rates are higher for pharyngeal infection than for anogenital infection.<sup>1</sup> We have seen several patients with pharyngeal cultures positive for *N gonorrhoeae* who were refractory to treatment and became culture-negative over several weeks without invasive or local complications. We therefore decided to conduct a prospective study to try to elucidate the natural history of asymptomatic gonococcal pharyngeal infection.

### Patients, methods, and results

During 1973-5, 12 men and six women were identified who had positive cultures of *N gonorrhoeae* from the pharynx and negative cultures from all other sites. All were asymptomatic, none had signs of pharyngitis, and none had taken antibiotics for 30 days. After giving informed consent the patients remained untreated and returned at two-week intervals for pharyngeal culture until negative cultures were obtained on two consecutive occasions. The patients were strongly advised against orogenital contact but mouth-to-mouth contact with their partners was not discouraged. The regular partners in nine cases returned with the study patient on each occasion for pharyngeal culture.

During the study period 17 of the 18 patients remained asymptomatic and free of complications. One patient developed pharyngitis after being followed up for seven weeks and a throat swab yielded  $\beta$ -haemolytic streptococci, group A, for which he was treated; *N gonorrhoeae* was not recovered. One patient was followed up for 10 weeks with positive cultures, but by the end of 12 weeks throat cultures from all 17 untreated patients were negative for *N gonorrhoeae* (see fig). Four patients had negative throat cultures at one visit then a positive culture two weeks later before their cultures became negative on two consecutive occasions. Pharyngeal cultures from the nine regular partners were repeatedly negative despite frequent mouth-to-mouth contact.



Proportion of 17 untreated patients with throat cultures positive for *N gonorrhoeae* during period of observation after initial positive culture.

### Comment

A commonly accepted practice is to treat all patients with *N gonorrhoeae* isolated from the pharynx to prevent transmission and the development of complications. Although mouth-to-mouth transfer of the gonococcus may be a mode of transmission, no evidence of this has been found. Our results suggest that mouth-to-mouth transmission is an unlikely mode of spread of the gonococcus.

The lack of complications in our untreated patients contrasts with reports that pharyngeal gonorrhoea is a risk factor for disseminated disease.<sup>1</sup> The magnitude of this risk, however, is unknown. Factors that lead to pharyngeal colonisation rather than invasion are not understood. The position with the gonococcus may be analogous to

the pathogenesis of meningococcal infections, where invasive disease correlates with the lack of meningococcal bactericidal activity<sup>2</sup> because of the presence of blocking antibody.<sup>3</sup> Evidence for a similar phenomenon in the case of the gonococcus is supported by the finding that serum resistance, a characteristic of *N gonorrhoeae* in disseminated disease,<sup>4</sup> is also related to the presence of blocking antibody.<sup>5</sup>

Our data suggest that the gonococcus may transiently colonise the pharynx without causing complications. Since we cannot distinguish between patients who will spontaneously become culture-negative and those who will develop sequelae, withholding routine treatment does not appear to be warranted. Further studies are needed to define the factors that play a determinant part in the host-gonococcal interaction.

Requests for reprints should be addressed to: Dr Johan Wallin,<sup>7</sup> Department of Dermatology and Venereology, University Hospital, S-75014, Uppsala 14, Sweden.

- <sup>1</sup> Wiesner, P J, *et al*, *New England Journal of Medicine*, 1973, **288**, 181.  
<sup>2</sup> Goldschneider, I, Gotschlich, E, and Artenstein, M S, *Journal of Experimental Medicine*, 1969, **129**, 1307.  
<sup>3</sup> McLeod Griffiss, J, and Bertram, M A, *Journal of Infectious Diseases*, 1977, **136**, 733.  
<sup>4</sup> Schoolnick, G K, Buchanan, T M, and Holmes, K K, *Journal of Clinical Investigation*, 1976, **58**, 1163.  
<sup>5</sup> McCutchan, J A, *et al*, in *Immunobiology of Neisseria gonorrhoeae*, ed F E Young, p 181. Washington, American Society for Microbiology, 1978.

(Accepted 28 March 1979)

**Department of Dermatology and Venereology, University Hospital, S-75014 Uppsala 14, Sweden**

J WALLIN, MD, associate professor in dermatology and venereology  
 M S SIEGEL, MD, senior fellow, Division of Infectious Diseases, Department of Medicine, University of Washington, Seattle, Washington, USA

## Enterotoxigenic *Escherichia coli* causing diarrhoea in travellers returning to the United Kingdom

During the past five years enterotoxigenic strains of *Escherichia coli* (ETEC) have been one of the most important causes of acute watery diarrhoea in areas of poor hygiene, notably in the tropics. Infants and young children are particularly at risk but adults may also be infected. Investigations in the United States of America and in Sweden suggest that ETEC are not important causes of sporadic diarrhoea in temperate areas of good hygiene. In a study of 61 children with acute diarrhoea in Boston, USA, no evidence was found of infection with ETEC,<sup>1</sup> and a study of 648 patients with diarrhoea in Sweden<sup>2</sup> concluded that ETEC were not important causes of diarrhoea. Nevertheless, ETEC are a significant cause of diarrhoea among visitors to tropical areas. Diarrhoea acquired after arrival in Mexico by students from the USA<sup>3</sup> was due in 72% of cases to ETEC, and ETEC were found in 11% of travellers who acquired diarrhoea while abroad or shortly after returning to Sweden.<sup>2</sup> Because of air transport travellers may return home while still in the acute stage of an infectious diarrhoea acquired abroad. We sought to determine the importance of ETEC as a cause of travellers' diarrhoea in patients returning to the United Kingdom.

### Methods, materials, and results

We studied 55 epidemiologically unrelated patients who developed diarrhoea during or shortly after travel abroad. Six were under 5 years old, two were between 5 and 14, and 47 were over 15. Fifteen patients had visited the Indian subcontinent, 11 had visited Spain or Portugal, and five had visited North Africa. In all, 21 different countries were represented. A further 50 patients with diarrhoea who had not recently been abroad were studied as a control group. Eleven were under 5 years old, six were between 5 and 14, and 33 were over 15. Sixty-two cultures were examined from each group of patients. All the cultures were identified as *E coli* by biochemical tests and were serotyped with antisera for O groups 1 to 164 and H antigens 1 to 56. The *E coli* strains were tested for the production of heat-stable enterotoxin (ST) by the infant mouse test, and for heat-labile enterotoxin (LT) by the CHO and Y1 tissue culture tests.<sup>4</sup>

ETEC were isolated from six (11%) patients who had recently travelled

abroad and from one (2%) patient with no history of recent travel. The seven ETEC strains belonged to seven different O groups. Three strains produced ST only, two produced LT only, and two produced ST and LT. Six of the patients with ETEC were adults and one was a 9-month-old baby (table).

### Serotypes of ETEC in sporadic diarrhoea in 55 travellers and 50 non-travellers in England and Wales

Serotype	Enterotoxin produced	Country visited	Age of patient
O6.H16	ST + LT	Sierra Leone	Adult
O7.H18	LT	India	Adult
O20.H11	ST	Not abroad	Adult
O89.H-	ST	Middle East	Adult
O128.H18	ST	India	9 months
O148.H28	ST + LT	Yugoslavia	Adult
O? H-	LT	France	Adult

### Comment

Although ETEC have caused hospital outbreaks of infantile diarrhoea in Scotland and England,<sup>5</sup> there is little information about their importance as a cause of sporadic diarrhoea in the community in the UK. Our findings suggest that ETEC are an uncommon cause of indigenous sporadic diarrhoea in the UK but confirm that they may be a significant cause of diarrhoea among travellers returning from abroad. These results closely agree with those of similar studies in Sweden. Laboratory workers investigating travellers' diarrhoea should be aware of the importance of ETEC. If salmonellae and shigellae are not isolated strains of *E coli* should be sent to the reference laboratory for serotyping and enterotoxin testing.

- <sup>1</sup> Echeverria, P, Blacklow, N R, and Smith, D H, *Lancet*, 1975, **2**, 1113.  
<sup>2</sup> Back, E, Blomberg, S, and Wadstrom, T, *Infection*, 1977, **5**, 2.  
<sup>3</sup> Gorbach, S L, *et al*, *New England Journal of Medicine*, 1975, **292**, 933.  
<sup>4</sup> Gross, R J, Scotland, S M, and Rowe, B, *Lancet*, 1978, **1**, 629.  
<sup>5</sup> Rowe, B, *et al*, *Journal of Clinical Pathology*, 1978, **31**, 217.

(Accepted 20 April 1979)

### Division of Enteric Pathogens, Central Public Health Laboratory, London NW9 5HT

R J GROSS, MA, principal microbiologist  
 SYLVIA M SCOTLAND, PHD, senior microbiologist  
 B ROWE, MB, MRCPATH, director

## Possible antigenic similarity between pulmonary carcinoma and cysts of *Echinococcus granulosus*

Antigenic similarity between parasites and some human carcinomas has been shown serologically.<sup>1</sup> The cystic intermediate stage of the cestode *Echinococcus granulosus* results in a chronic infection, known as hydatid disease. The test of choice for the immunodiagnosis of this disease has been the immunoelectrophoresis (IEP) test using as antigen concentrated *E granulosus* cyst fluid from sheep.<sup>2</sup> A test is considered positive when the patient's serum causes the precipitation of a band called arc 5, which is easily identified. In addition to this specific band, however, other bands may be precipitated by the sera of hydatidosis patients as well as by the sera of patients with other diseases.<sup>3</sup> When the serum from a patient suffering from pulmonary carcinoma was tested using *E granulosus* cyst fluid a broad and intense precipitin band resulted.

### Case report

A 42-year-old man, a farm worker all his life, was admitted to hospital in January 1978 complaining of tiredness, loss of appetite, persistent cough with occasional haemoptysis, and frequent night sweats. He had smoked 20-30 cigarettes a day for 25 years and had had an episode of renal colic in 1974. The results of clinical and laboratory investigations were normal except for a white cell count of  $24.3 \times 10^9/l$  ( $24\ 300/mm^3$ ) and an erythrocyte sedimentation rate of 113 mm in 1st h. The peripheral blood contained 86%