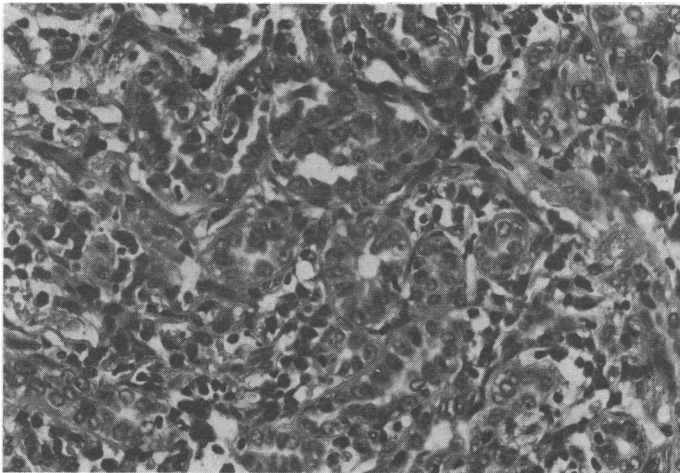


pattern was distorted. Type II cell hyperplasia was prominent. In the most cellular area (see figure) large cuboidal cells lined duct-like lumina. These cells were moderately pleomorphic, and, although mitoses were not seen and stains for mucin were negative, the appearances were interpreted as adenocarcinoma, probably metastatic rather than alveolar cell carcinoma. With hindsight the interpretation must be florid alveolar cell proliferation.

**Progress**—Despite the alarming histological appearances a trial of steroid treatment was started (prednisolone 60 mg/day) and the gold injections were stopped. After one month the chest radiograph had cleared and pulmonary function had improved: FEV<sub>1</sub> was 1.6 l, VC 1.7 l, T<sub>1</sub>CO 11.7 mmol/kPa/min (predicted 26.4 mmol/kPa/min) (34.9 ml/mm Hg/min (78.8 ml/mm Hg/min)). After four months' follow-up the patient was still breathless on exertion but there were no abnormal physical signs. The dose of prednisolone had been reduced to 5 mg. The chest radiograph showed a high diaphragm and minimal reticular opacities in the mid-zones. The pulmonary function tests showed the same restrictive defect.



Photomicrograph showing grossly hyperplastic type II alveolar cells with duct formation mimicking adenocarcinoma. (H and E.  $\times 270$ .)

### Comment

In 1948 Savilahti<sup>1</sup> described pulmonary complications associated with a total dose of 1.06 g of gold which were successfully treated with dimercaprol. In 1976 Winterbauer *et al*<sup>2</sup> reported two similar cases: one of these patients had osteoarthritis and the other rheumatoid arthritis. There is no association between osteoarthritis and lung disease. The patient with rheumatoid arthritis was mistakenly given gold again after treatment of the lung disease and the symptoms reappeared. Geddes and Brostoff<sup>3</sup> described a patient with rheumatoid arthritis who developed fibrosing alveolitis after gold treatment. Lung function improved when the gold was stopped but deteriorated when gold was restarted. Gould *et al*<sup>4</sup> reported three further cases. In all six recent cases the onset of symptoms occurred five to 16 weeks after starting gold and after total doses of 400 to 800 mg.

We believe that our patient has suffered from "gold lung." She was left with a pronounced restrictive lung disorder, and would probably have died if gold treatment had been continued. The histological appearances were more striking than those previously illustrated,<sup>2,4</sup> the type II alveolar pneumocytes having reacted so vigorously as to have resembled adenocarcinoma, for which radiotherapy or cytotoxic treatment might have been prescribed.

<sup>1</sup> Savilahti, M, *Annals of Internal Medicine Fenniae*, 1948, **37**, 263.

<sup>2</sup> Winterbauer, R H, Wilske, K R, and Wheelis, R F, *New England Journal of Medicine*, 1976, **294**, 919.

<sup>3</sup> Geddes, D M, and Brostoff, J, *British Medical Journal*, 1976, **2**, 1444.

<sup>4</sup> Gould, P W, McCormack, P L, and Palmer, D G, *Journal of Rheumatology*, 1977, **4**, 252.

(Accepted 2 February 1978)

King's College Hospital, London SE5 9RS

D W JAMES, MRCP, registrar, department of rheumatology and rehabilitation

W F WHIMSTER, MRCP, MRCPATH, honorary consultant, department of morbid anatomy

E B D HAMILTON, FRCP, consultant, department of rheumatology and rehabilitation

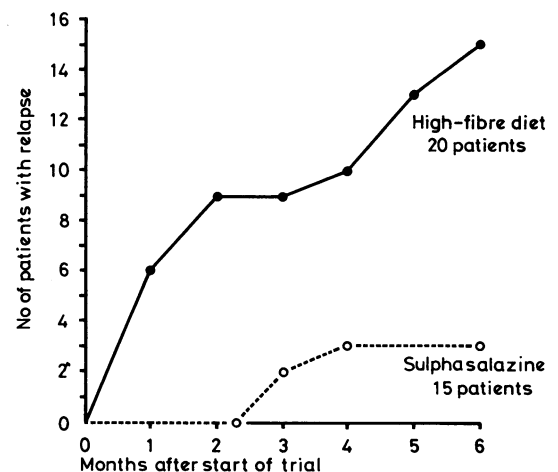
## Maintenance of remission in ulcerative colitis with sulphasalazine or a high-fibre diet: a clinical trial

A high-fibre diet and cellulose preparations appear of value in patients with ulcerative colitis who develop colonic obstruction with clinical relapse of the disease. In recent years several of our patients who have been in remission with colitis have taken a high-fibre diet and spontaneously discontinued sulphasalazine but remained in remission. We questioned whether the high-fibre diet might prevent relapse, and in a controlled trial have examined the effect of replacing sulphasalazine treatment with the diet. Sulphasalazine maintains clinical remission in ulcerative colitis<sup>1,2</sup> and its withdrawal leads to relapse in up to 70% of patients within six months.

### Methods and results

Thirty-nine patients in remission with colitis were divided into two similar groups; their mean age was 40, mean duration of disease 8.5 years, and mean interval since the last relapse 1.4 years. One group continued on sulphasalazine without a change in diet (15 patients) and the other (24 patients) increased their fibre intake by taking wholewheat bread, vegetables, and a supplement of 25 g of bran.\* Four patients were unable to tolerate the diet and were withdrawn early from the study; additional patients were included to compensate for withdrawals. Patients who tolerated the diet discontinued sulphasalazine after two weeks. All patients were reviewed after one, three, and six months, and also if they had a recurrence of symptoms lasting over 48 hours—these symptoms consisted of three or more loose stools daily, usually with blood loss. At each interview the diet was reviewed, bowel symptoms were noted, and sigmoidoscopy was carried out.

The analysis is based on 35 patients who remained in the trial. In the sulphasalazine group three of the 15 patients relapsed, one with severe and two with mild symptoms. Of 20 patients given a high-fibre diet, four could not discontinue sulphasalazine because symptoms recurred when the dose was reduced. Five patients relapsed within three months after sulphasalazine was discontinued and a further six between three and six months. Only five of these 20 patients remained free from symptoms during the six-month period. Eleven patients on the high-fibre diet had been in remission for over one year and six of these relapsed when the sulphasalazine was withdrawn; four had been in remission for over three years, two of whom relapsed. The overall relapse rates for the sulphasalazine and high-fibre groups were 20% and 75%, respectively (fig).



Clinical relapse in patients who continued to take sulphasalazine compared with those who discontinued the drug and took a high-fibre diet.

### Discussion

The high relapse rate in patients who discontinued or attempted to discontinue sulphasalazine is in keeping with other results, which have shown a relapse rate of 55 and 69% over six months<sup>1,2</sup>; relapses in the sulphasalazine group were also similar to those observed in these trials. The risk of relapse on withdrawal of sulphasalazine in our patients was independent of the duration of remission.<sup>1</sup> Our data lend

\*The bran supplement was given as either Kellogg's All Bran or Allinson's Bran Plus.

no support to the concept that a high-fibre diet is of value in maintaining clinical remission in patients with ulcerative colitis, although this does not exclude its value in patients who are particularly apt to develop colonic obstruction with recurrence of disease activity.

Most of our patients tolerated the diet and at the end of the study many said that they wished to continue with it in addition to sulphasalazine.

We thank Mrs J Habgood for dietetic help, and the Kellogg Company of Great Britain Limited and Allinson's, who supplied All Bran and Bran Plus, respectively.

<sup>1</sup> Dissanayake, A S, and Truelove, S C, *Gut*, 1973, **14**, 923.

<sup>2</sup> Misiewicz, J J, *et al*, *Lancet*, 1965, **1**, 185.

(Accepted 14 February 1978)

#### University Hospital of Wales, Cardiff

P S DAVIES, MB, MRCP, senior registrar in medicine  
J RHODES, MD, FRCP, consultant gastroenterologist

## Long remission after lymphoblastic transformation of chronic granulocytic leukaemia

Blastic transformation is common in chronic granulocytic leukaemia (CGL) and usually represents a terminal aspect of the disease owing to its resistance to chemotherapy, mean survival time being a few weeks or months. Attention has been focused on the different cell morphologies seen in transformation<sup>1,2</sup> and their possible relevance to the forms of chemotherapy employed and subsequent survival.<sup>3</sup> We therefore thought this case report was of interest.

### Case report

A 25-year-old woman presented in December 1970 with left hypochondrial pain and pronounced splenomegaly. Her haemoglobin concentration (Hb) was 11.9 g/dl; white cell count (WBC)  $125 \times 10^9/l$  ( $125\,000/mm^3$ ), composed predominantly of neutrophils but with numerous myelocytes and metamyelocytes; and platelet count  $785 \times 10^9/l$  ( $785\,000/mm^3$ ). Considerable granulocytic hyperplasia was found on bone marrow examination, cytogenetic analysis of which showed the Philadelphia chromosome in all mitoses examined. Leucocyte alkaline phosphatase (LAP) score was 5. CGL was diagnosed. The splenomegaly disappeared and the blood count returned to normal after a six-week course of busulphan. Over the subsequent two years two short courses of busulphan were required, after which maintenance was continued with hydroxyurea.

In July 1974 she suddenly developed fever, extensive purpura, and generalised lymphadenopathy and hepatomegaly. The spleen remained palpable. Hb was 8.4 g/dl; WBC  $20 \times 10^9/l$  ( $20\,000/mm^3$ ) with 14% neutrophils and 70% microblasts; and the platelet count  $80 \times 10^9/l$  ( $80\,000/mm^3$ ). The bone marrow was hyperplastic with a 70% infiltration of small peroxidase-negative blast cells of lymphoblastic morphology. LAP score was 180. No mitoses were obtained for cytogenetic analysis. Cerebrospinal fluid examination was normal. A conventional antilymphoblastic treatment regimen was initiated—namely, intravenous vincristine 2 mg weekly, intramuscular L-asparaginase 20 000 U twice weekly, and prednisone 60 mg daily by mouth. Full haematological remission was obtained after six weeks. Central nervous system prophylaxis was carried out six weeks after remission with cranial irradiation and intrathecal methotrexate.

Maintenance treatment with daily 6-mercaptopurine by mouth and twice-weekly intramuscular methotrexate was given until April 1977, when hydroxyurea was reinstated for a thrombocytosis of  $1000 \times 10^9/l$  ( $1\,000\,000/mm^3$ ). The blood count became normal and the patient remained well and asymptomatic 39 months after transformation, 82 months after the original presentation. All cytogenetic analyses performed since transformation have shown persistence of the Philadelphia chromosome.

### Comment

The clinical and laboratory features of CGL in this patient are unremarkable and little maintenance treatment was required in the chronic phase. Acute transformation was clinically unusual only in the absence of splenomegaly, and it was morphologically indistinguishable from a "de-novo" acute lymphoblastic leukaemia.

Subsequent remission induction and duration, however, contrast with results currently obtained in transformed CGL, although response to chemotherapy may be superior in "lymphoblastic" varieties, especially if anti-ALL regimens are employed.<sup>3,4</sup> That long remissions may be obtained, as exemplified by this young patient, underlines the importance of both recognising the morphological type of transformation and subsequently instituting appropriate treatment. This includes CNS prophylaxis, since CNS relapse often occurs during remissions obtained in lymphoblastic and myeloblastic transformations.<sup>5</sup>

<sup>1</sup> Rosenthal, S, *et al*, *Blood*, 1977, **49**, 705.

<sup>2</sup> Janossy, G, *et al*, *British Journal of Haematology*, 1976, **34**, 179.

<sup>3</sup> Peterson, L C, Bloomfield, C D, and Brunning, R D, *American Journal of Medicine*, 1976, **60**, 209.

<sup>4</sup> Hoerni-Simon, G, *et al*, *Nouvelle Presse Médicale*, 1976, **5**, 2885.

<sup>5</sup> Schwartz, J H, *et al*, *American Journal of Medicine*, 1975, **59**, 819.

(Accepted 15 February 1978)

#### Departement d'Hématologie, Clinique Médicale du CHU, Hôpital de Cimiez, 06031 Nice, France

M V JOYNER, MRCPATH, assistant

P DUJARDIN, MD, assistant

J-P CASSUTO, MD, assistant

P AUDOLY, MD, professor

Centre Antoine Lacassagne, 36 Avenue de la Voie Romaine, 06 Nice, France

M SCHNEIDER, MD, professor

## Heat stroke in a "run for fun"

Heat stroke may occur with strenuous exercise in hot humid environments and is not usually considered a risk in community sports in a temperate environment. A life-threatening emergency, it is characterised by three cardinal signs: severe disturbance of the central nervous system, hyperpyrexia, and hot dry skin.<sup>1</sup> It occurs with a high work rate in conditions preventing dissipation of heat by convection and radiation. We describe 16 severe cases occurring under temperature conditions where the risk is considered low.

### The event

Some 20 000 runners participated in an 11-km "run for fun" in Auckland, New Zealand, in late summer 1977. The run began at 10 am, when the temperature was 21.3°C, humidity 73%, and wind velocity 9 knots. The run was promoted as a community sporting event, and runners were encouraged to enter in social teams (63% of registered runners), though they could also enter individually. Certificates were given to those who completed the course in under 100 minutes.

The organisers gave advice to runners in a pamphlet that described appropriate preparation and training for the run. The need to drink adequate fluid before and during the run was emphasised. Runners were advised to stop if they became unwell or developed excessive breathlessness, dizziness, or chest pains. Ambulance personnel estimated that they treated 200 with heat illness of varying severity; 16 patients were admitted to local hospitals.

*Clinical observations*—The 16 severely affected were men aged 20-44; there were no heat-stroke casualties among older runners or women. All the patients were active in sports other than long-distance running and had trained for the event but in the cooler parts of the day. Subsequent interviews established that they were all highly motivated to finish, to improve on a previous performance, or from team loyalty. Only one patient (taking propantheline for symptoms of peptic ulceration) had been other than completely well before the run. The patients presented with varying degrees of dis-

Substance (and normal concentration)	Median	Range	No tested
CPK (5-115 IU/l)	418	59-2252	10
Bilirubin (5-22 μmol/l)	34	12-192	11
SGOT (10-55 IU/l)	690	165-5000	11
Alkaline phosphatase (30-95 IU/l)	98	65-140	11

Conversion: SI to traditional units—Bilirubin: 1 μmol/l ≈ 0.058 mg/100 ml.