

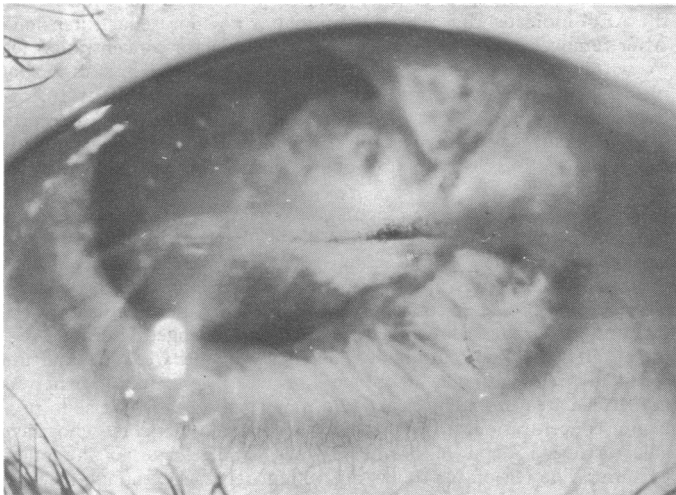
SHORT REPORTS

Swimming goggles causing severe eye injuries

In 1976 in this hospital, which serves a population of about 1.5 million, we have seen three cases of severe eye injuries caused by a popular type of swimming goggle. The children affected were pulling the goggles forward in order to clear them of steam, when they slipped out of their wet fingers.

Case reports

Case 1—A 13-year-old girl was hit in the right eye by a swimming goggle. On examination half an hour later the visual acuity of the injured eye was bare perception of light, but she was seeing 6.5 with the other eye. There was a penetrating corneoscleral injury, with some vitreous loss, iridodialysis, ruptured sphincter pupillae, flat anterior chamber, and dislocated lens. There was no view of the fundus because of hyphaema. The wound was sutured under general anaesthesia the same day. The eye was treated with a pad, and topical cycloplegics and antibiotics, and later steroids, but remained irritable for several weeks. Some 13 weeks after the injury the eye had settled well and the wound had healed (see figure). The visual acuity at this stage was counting fingers at one foot, owing to dense cataract. Future treatment may improve this result, but some visual loss will be permanent.



Case 1. The injured eye 13 weeks after the accident.

Case 2—A 13-year-old boy was hit in the right eye by a swimming goggle. On examination an hour later the visual acuity of this eye was 1/36 and in the left eye 6.5. There was a penetrating injury about 8 mm in length across the centre of the cornea; the anterior chamber was flat and contained a blood clot preventing a view of the fundus. The wound was sutured under anaesthesia the same day and the eye settled well on the same treatment as in Case 1, but a posterior subcapsular cataract developed. About six weeks after the injury the visual acuity in this eye was 6/36.

Case 3—A 14-year-old boy was hit in the right eye by a swimming goggle three days before he was examined, complaining of a "bloodshot" eye and blurred vision. On examination the visual acuity of the injured eye was 6/9 and of the left eye 6/5. There was 1/3 settled hyphaema present and slight traumatic mydriasis; and on examination of the fundus no abnormality was seen. Ten days later the eye had settled completely and the visual acuity was 6/5.

Comment

To my knowledge there have been no reports of similar injuries caused by swimming goggles, which are worn by many children. The goggles concerned were made by different manufacturers, but the design was roughly the same, and all had a strong elastic strap. It is

not possible to be certain which part of the goggle struck the eyes, and it may not always have been the same part. Because of the elasticity of the adjustable strap it is possible to pull the goggles 30–40 cm away from the face, and on release they spring back with considerable force. It would seem safer, although more inconvenient, to use a less elastic or non-elastic adjustable strap, or even a Velcro fastener if possible.

I am grateful to the surgeons of this hospital for permission to report these cases, and to Mr C Hood for photography.

(Accepted 22 December 1976)

Eye Department, Royal Infirmary Edinburgh, Edinburgh EH3 9HA
F JÖNASSON, CAND MED ET CHIR, DO, registrar

Raised mean cell volume and meningoencephalitis associated with *Mycoplasma pneumoniae* infection

Mycoplasma pneumoniae infections are not usually associated with disorders of the central nervous system (CNS). The organism, however, should be considered as a causative agent in all cases of acute neurological dysfunction, particularly in young patients.¹ In the following case the diagnosis was suspected owing to a raised mean cell volume (MCV) resulting from cold agglutination of the patient's cells in the Coulter counter.

Case report

A 30-year-old housewife was transferred to this hospital in April 1976. She had been admitted to Ashford Hospital, Middlesex, three days earlier with a two-week history of depression, diplopia, and hesitancy of micturition after a "flu-like" illness. Examination of the cerebrospinal fluid (CSF) at Ashford had shown $61 \cdot 10^6$ white cells (predominantly lymphocytes)/l ($61/\text{mm}^3$), protein 1.1 g/l, and sugar 3.1 mmol/l (56 mg/100 ml). Viral encephalitis was diagnosed. Her condition deteriorated alarmingly, however, and she was transferred.

On arrival in our intensive care unit the patient had a decorticate posture and responded only to painful stimuli. Rectal temperature was 38°C, generalised convulsions with tonic rotation of the neck were evident, there was pronounced cervical rigidity, and Kernig's sign was present. The optic discs looked normal. Respiratory function was depressed, and she required intubation and assisted ventilation. Lumbar puncture showed the CSF to contain $23 \cdot 10^6$ white cells (predominantly lymphocytes)/l, protein 1.15 g/l, and sugar 5.9 mmol/l (106 mg/100 ml) (blood sugar 8.1 mmol/l; 146 mg/100 ml). Further CSF studies showed Wassermann reaction negative, Lange curve 432222100, and no organisms, virus, or mycoplasmas. Haemoglobin was 11.9 g/dl, white cell count $14 \cdot 10^9/\text{l}$ ($14000/\text{mm}^3$) (90% neutrophils), MCV 110 fl (μm^3), erythrocyte sedimentation rate 90 mm in first hour, platelet count $490 \cdot 10^9/\text{l}$, and Paul-Bunnell reaction negative. Urea, electrolytes, liver function values, and plasma amylase were all within normal limits. Blood culture was sterile. Chest and skull x ray pictures and an EMI scan were normal. An electroencephalogram was devoid of normal activity and showed changes compatible with a severe encephalitic process.

In view of the severity of the illness and signs of generalised toxicity intravenous ampicillin was started. The raised MCV was found to be due to autoagglutination of the patient's cells in the Coulter counter. A spot test confirmed the presence of cold haemagglutinins. Tetracycline treatment by nasogastric tube was begun when *M pneumoniae* was suspected as the causative organism.

The patient gradually recovered and the endotracheal tube was removed 48 hours later. She was eventually discharged home two months after the onset of her illness with no residual neurological deficit. At outpatient follow-up she appeared to be well physically but still had some impairment of intellectual function and remained very depressed.