

SARCOMA OF THE STOMACH*

SAMUEL F. MARSHALL, M.D.,

FROM THE DEPARTMENT OF SURGERY, THE LAHEY CLINIC, BOSTON

AND

WILLIAM A. MEISSNER, M.D. (BY INVITATION)

FROM THE DEPARTMENT OF PATHOLOGY, NEW ENGLAND DEACONESS HOSPITAL, BOSTON, MASSACHUSETTS

SARCOMA OF THE STOMACH is not a common gastric neoplasm, but such tumors do occur often enough that the physician and surgeon should be aware of their frequency and of their distinctive character so that they may be considered in the differential diagnosis of tumors arising in the stomach, and in particular these tumors should be recognized at the operating table, by their gross appearance or by an immediate frozen section. While it is true that the majority of sarcomas of the stomach are not diagnosed before operation, it is of great importance to consider sarcoma in the differential diagnosis of gastric tumors because sarcomas may arise in a somewhat earlier age group, not infrequently present themselves as palpable tumors in the epigastrium and often are massive neoplasms involving a considerable part of the stomach. The presence of a large palpable abdominal mass may make the examiner consider these tumors to be inoperable carcinomas because of the extensive involvement of the stomach and because of their size. If certain characteristic features of these tumors are well recognized, however, surgical treatment may have much to offer in the way of relief of symptoms and even possible cure, since the prognosis is considerably better in sarcoma than in carcinoma. In this paper a clinical analysis is presented of 41 patients with sarcoma of the stomach seen in the Lahey Clinic between the years 1929 and 1949. During this time there were 1171 operations for malignant tumors of the stomach, making the ratio of sarcoma to carcinoma 1 to 28 or an incidence of 3.5 per cent. In this presentation we shall discuss also the pathologic features as well as the type of treatment employed and the results of follow-up studies in this group of cases.

The incidence of sarcoma of the stomach is given at variant figures by different writers on this subject.^{3, 4, 11, 12} Ewing estimated that sarcoma comprises about 1 per cent of all gastric neoplasms. Balfour and McCann found the average ratio of one case of sarcoma to 111 of carcinoma, and in a total group of 4159 malignant lesions of the stomach there were 47 sarcomas. Warren and Lulenski found 28 cases of solitary lymphoid tumors among 3132 malignant tumors of the gastro-intestinal tract, an incidence of 0.9 per cent of sarcomas of lymphoid origin. However, in this group there were 14 primary lymphoid tumors among 569 malignant lesions of the stomach, an incidence of 2.5 per cent. In 1914, Forni made a complete and detailed analysis, and col-

* Read before the Southern Surgical Association, Hot Springs, Virginia, December 7, 1949.

lected 200 cases of gastric sarcomas previously reported in the literature. D'Aunoy and Zoeller further reviewed the literature and found 335 cases of sarcoma recorded through 1929. Yarnis and Colp found 8 cases of lymphosarcoma in a series of 250 neoplasms of the stomach over a six-year period, an incidence of 3.2 per cent. Thus, while there is some slight difference in the incidence of sarcoma of the stomach as reported, it has varied relatively little. A survey of the literature conveys the impression that sarcoma of the stomach occurs fairly constantly and accounts for about 4 per cent of malignant gastric neoplasms and must, therefore, be considered in any differential diagnosis of tumors arising in the stomach.

PATHOLOGY

Sarcomas of the stomach may arise theoretically from any mesenchymal tissue component of the organ. Malignant tumors arising from fibrous tissue, fat and blood vessels are so rare that they are merely curiosities. For practical purposes, there are only two types of gastric sarcoma, those arising from

TABLE I.—*Classification and Incidence of Gastric Sarcoma (41 Cases).*

Leiomyosarcomas.....	9
Lymphoid tumors.....	32
Hodgkin's disease.....	10
Reticulum cell sarcoma.....	6
Lymphosarcoma.....	12
Malignant lymphoma.....	4
—	—
Total.....	41

smooth muscle and those arising from lymphoid tissue. The malignant lymphoid tumors may be further subdivided according to the criteria laid down by Warren and Lulenski. A classification of the tumors studied in this report is shown in Table I.

The malignant tumors of smooth muscle origin (Figs. 1, 2 and 3), the leiomyosarcomas, were located in various portions of the stomach but were more common in the pyloric third. There was no apparent predilection for greater over lesser curvature, or for anterior wall over posterior wall. The size varied from 2.5 cm. to 14 cm. in greatest diameter. The tumors, although sometimes lobulated, were in most instances well circumscribed. Usually they grew predominantly into the gastric lumen, but intramural or subserosal growth also occurred. The compressed and thinned overlying gastric mucosa in all but two instances showed one or more central ulcerations which were often quite deep, giving a punched-out appearance. Necrosis, either focally or involving the entire tumor, was common and resulted in softening the usual firm consistency. In all instances the tumor was thought to be completely excised locally; metastasis to lymph nodes was not found in any case.

Microscopically, the *leiomyosarcomas* arose from the gastric muscularis and were composed of spindle-shaped, relatively well-differentiated, smooth

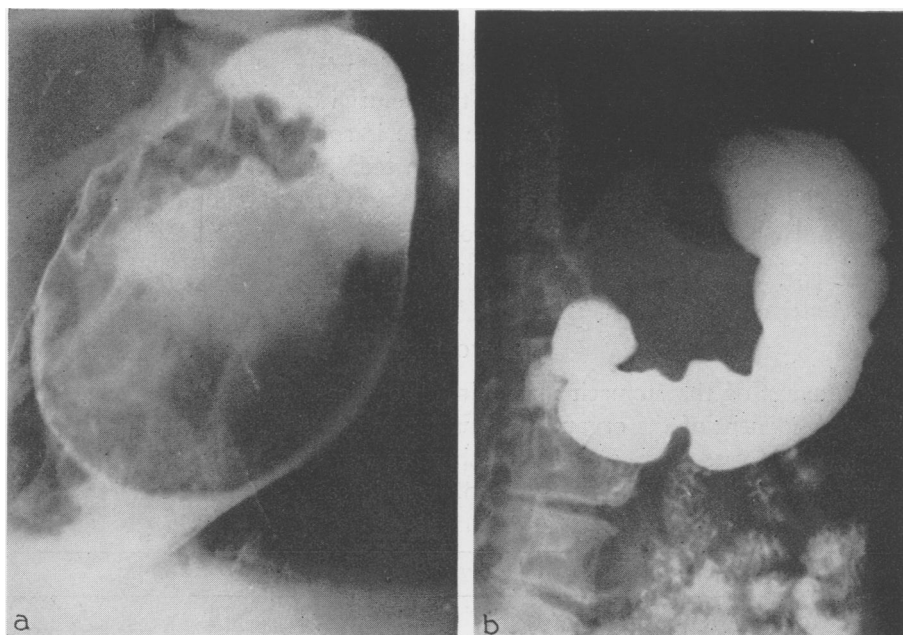


FIG. 1.—Leiomyosarcoma. (A) Intraluminal mass filling upper media and cardia; pedicle in upper cardia; transgastric excision performed. (B) Postoperative roentgenogram showing normal appearance.

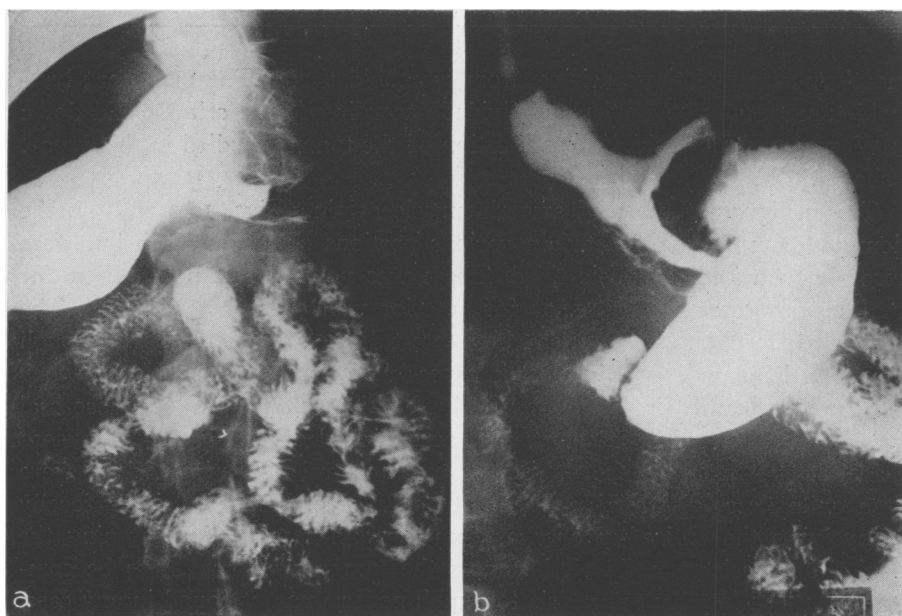


FIG. 2.—Leiomyosarcoma; the patient is well two years after operation.

SARCOMA OF THE STOMACH

muscle cells (Fig. 4). There was moderate pleomorphism of cells and nuclei. While scattered mitoses were present in each case, they were never numerous. The general impression was that of rather slow growth and low-grade malignancy. These tumors differed in microscopic appearance from benign leiomyomas, which they may grossly resemble, by showing invasion of normal

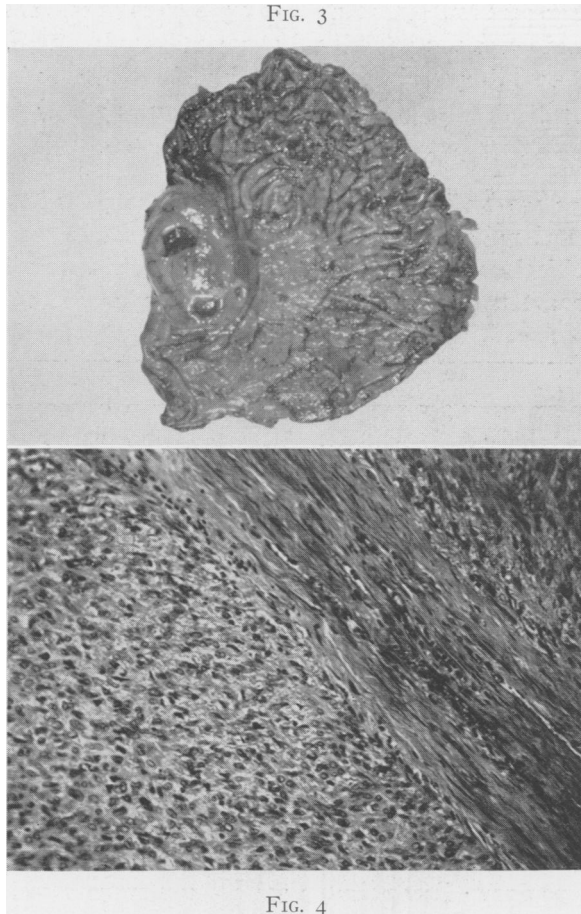


FIG. 3.—Leiomyosarcoma. The tumor is growing into lumen and shows multiple typical mucosal ulcerations.

FIG. 4.—Microscopic appearance of leiomyosarcoma. The tumor is growing on either side of normal strand of muscle (eosin-methylene blue stain, x 250).

tissue and evidence of more active growth. No invasion of blood vessels or lymphatic vessels was found.

The *lymphoid tumors* (Figs. 5-8), of which there were 32, like the leiomyosarcomas were located in various portions of the stomach and showed no predilection for either wall or either curvature. The majority of the tumors

FIG. 5

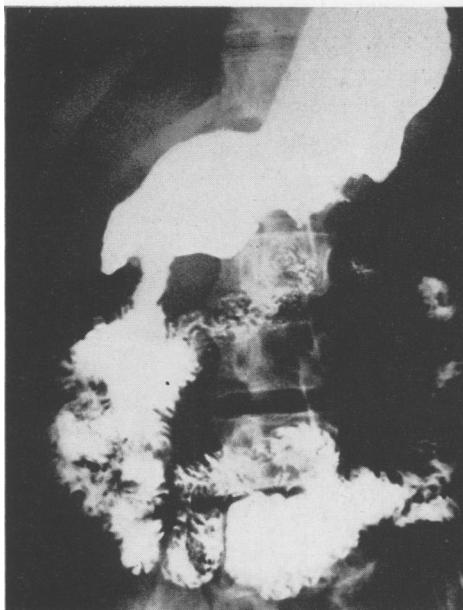

FIG. 6

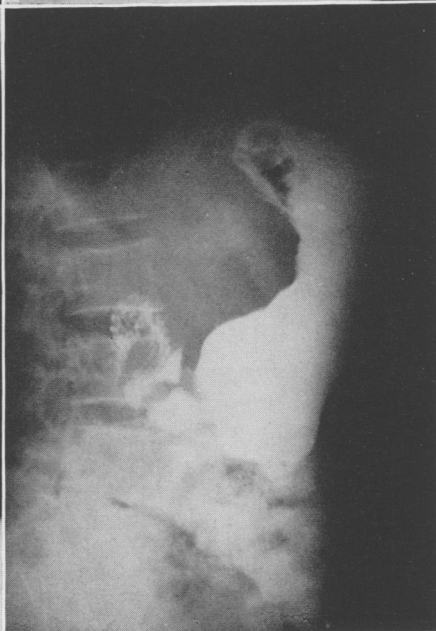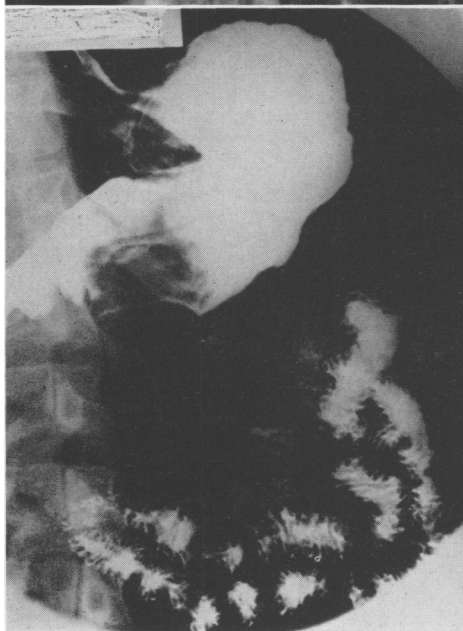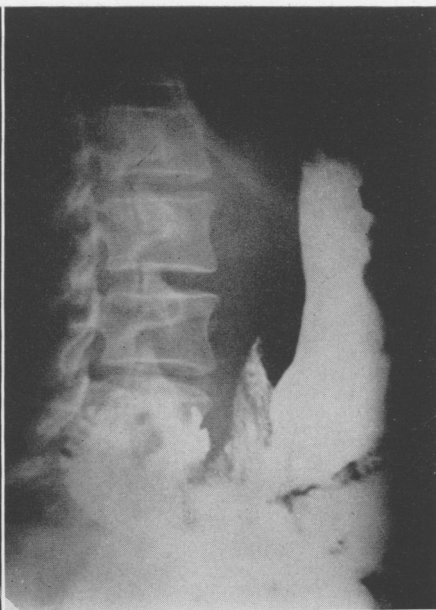


FIG. 7

FIG. 8

FIG. 5.—Hodgkin's disease of the stomach; ulcerating lesion of the greater curvature. Partial gastrectomy was performed. The patient is alive six and a half years after operation.

FIG. 6.—Malignant lymphocytoma. Infiltrating tumor involving cardia and
(*Legend continued on opposite page*)

were Hodgkin's disease or lymphosarcoma (Table I) but there was no apparent variation in gross appearance according to the subgroup of lymphoid tumor. These neoplasms, however, showed gross characteristics differing from leiomyosarcomas in that they were usually larger (smallest 2.0 cm.; largest 18 cm. in greatest diameter) and more likely to grow in the same plane as the gastric wall rather than into the lumen. As a result, the typical appearance was a large, flat mass, usually with extensive, shallow ulceration centrally. In some cases the tumor infiltrated under intact mucosa and smoothed it out or pushed it up into giant rugal folds. While the tumors were often partly necrotic, the non-necrotic portions typically were firm, fleshy and yellow-white. None was encapsulated; most were poorly or irregularly circumscribed. Thirteen of the 32 cases showed metastatic involvement of regional lymph nodes.

Microscopically, invasion of adjacent normal tissue and the usual criteria of malignant lymphoid tumor¹⁷ were present in each case (Figs. 9 and 10). The tumors looked similar to their prototypes arising in other parts of the body. There were no pathologic criteria by which one could specifically tell whether the tumor arose primarily in the stomach or whether the gastric involvement was part of a generalized process.

Distinguishing some undifferentiated carcinomas from lymphoid tumors may give considerable difficulty and it is quite likely that some tumors classified as carcinoma are actually of lymphoid origin. As a rule, examination of multiple sections will reveal areas in which the carcinoma shows some differentiation to allow it to be recognized as of epithelial origin. Another difficulty is in the recognition of malignant lymphoid tumor cells in regional lymph nodes. If the tumor cells are not invading and destroying the lymph node architecture, but are confined to the sinusoids, their recognition may be difficult or impossible.

PATHOGENESIS

The etiology of the sarcomas is unknown. Although the leiomyosarcomas of this series grossly resemble the 21 benign gastric leiomyomas removed during the same period, there is no proof that any of the malignant neoplasms arose from a pre-existing benign tumor. Small, symptomless leiomyomas of the stomach are extremely common findings at autopsy,¹³ and it must be conceded that malignant change in such a tumor is a possibility, but difficult to prove. Other than this single factor, there is nothing that can be pointed to as a possible precursor to sarcoma. The gastric mucosa in the uninvolved por-

media on greater curvature. Total gastrectomy was performed. Patient is alive ten years after operation.

FIG. 7.—Lymphosarcoma. Large infiltrating tumor involving greater curvature of proximal antrum. Partial gastrectomy was performed and roentgen therapy given. Patient is living and well one year and nine months after operation.

FIG. 8.—Lymphosarcoma. Infiltrating tumor involving greater curvature of media and antrum. Partial gastric resection was performed. Patient is alive and well seven years after operation.

FIG. 9

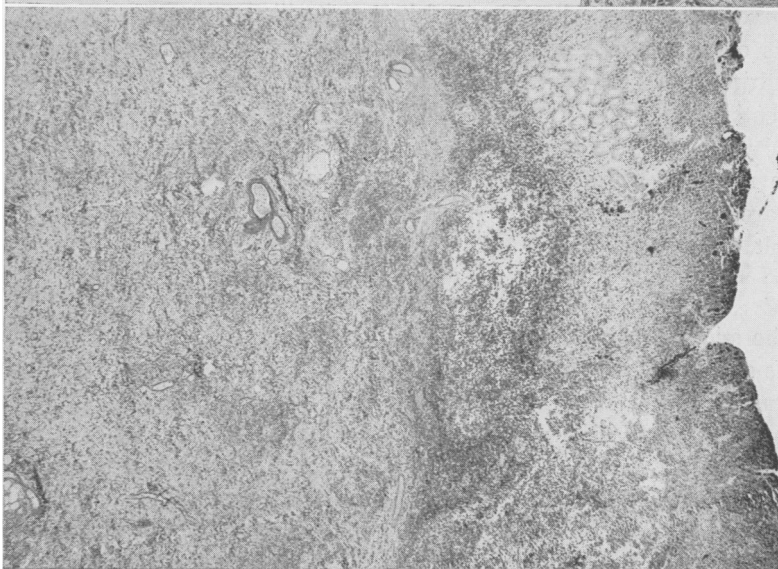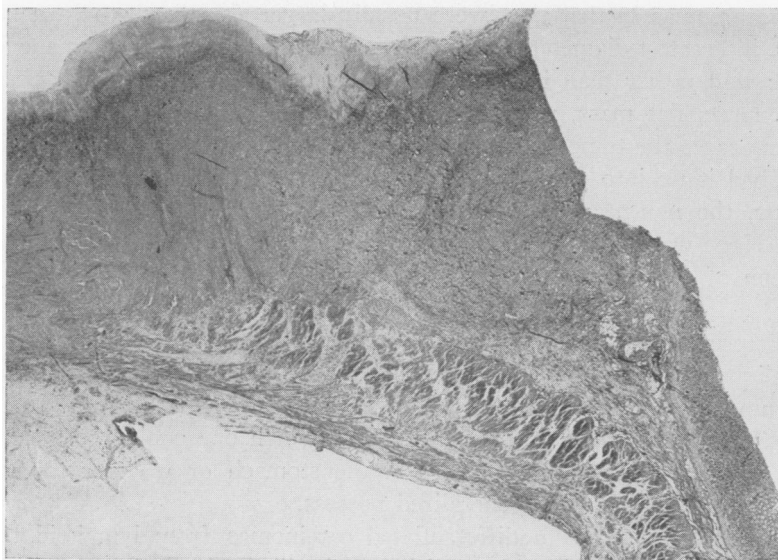


FIG. 10

FIG. 9.—Lymphosarcoma undermining and destroying mucosa. Invasion of underlying muscle (eosin-methylene blue stain, x 12).

FIG. 10.—Lymphosarcoma replacing normal mucosal glands and extensively invading submucosa (eosin-methylene blue stain, x 50).

SARCOMA OF THE STOMACH

tion showed no unusual gastritis or other remarkable changes. There was nothing to suggest a relationship between peptic ulcer and sarcoma.

SEX AND AGE DISTRIBUTION

In this series of cases of sarcoma there were 14 females and 27 males, a ratio of 1 to 1.9, which closely parallels the sex incidence in our group of carcinomas of the stomach—females to males 1 to 1.70. In the report of Balfour and McCann there were 13 females and 31 males. On the other hand, some reports indicate an even distribution between the sexes as reported by Cheever and by Douglas. D'Aunoy and Zoeller, in their review of 135 cases, found 43 females and 73 males, a ratio of 1 to 1.7.

It is stated in the literature that sarcoma of the stomach occurs earlier in life than does carcinoma. Balfour and McCann gave the average age for the whole group as 43 years. The average age in this group of 41 patients was 53 years, which is somewhat higher than that in most reports in the literature and very nearly approaches the average age of patients with cancer of the stomach,

TABLE II.—*Age Distribution in 41 Cases of Sarcoma.*

Years	Cases
0-20.....	0
21-30.....	3
31-40.....	5
41-50.....	8
51-60.....	13
61-70.....	7
71-80.....	5
	—
	41

which we found to be 61 years. The age groups in the series of 41 cases is given in Table II.

In our studies of patients with cancer of the stomach seen in this clinic, 73 per cent were 50 years or older. In this series of patients with sarcomas, 60 per cent were 50 years or older. We believe this tumor is so distributed in all age groups that it cannot be considered a disease of any especial age, although it may be true that large bulky tumors occurring in young people may often prove to be sarcomas. Certainly there are very few distinguishing features so far as sex and age are concerned. The youngest patient in this group was 28 and the oldest 78 years of age.

CLINICAL CHARACTERISTICS

Sarcoma of the stomach presented no characteristic clinical features, and in general the symptoms were similar to those accompanying gastric carcinoma. One feature may be significant, however, in that in general these patients were in good physical condition and did not show the cachexia or anemia so common in many cases of carcinoma of the stomach. In our histories, 33 out of the group of 41 were considered in good or fair condition and only 4 were in poor physical condition.

The average duration of symptoms in this group of cases was ten months,

although symptoms had been present for a period ranging from three weeks to four years. The presenting symptoms were chiefly epigastric pain or simple indigestion and anorexia. In many instances these patients had been treated for varying periods without roentgenologic examination and the presence of a neoplasm in the stomach was not recognized. Twenty-two of the 41 patients had had symptoms for periods of from three months to four years without a definite diagnosis being made. The most common symptoms encountered were vague abdominal distress or pain and anorexia. Pain was epigastric in character, was seldom associated with nausea or vomiting, and was noted in 31 patients. In many cases, food or alkali did give some relief and symptoms were often ulcerlike in character, and this was noted in 19 patients, but this distress was not entirely characteristic of ulcer in the majority either in its periodicity or relief obtained with alkali. Anorexia was also quite common and this was the initial complaint in 27 patients. It was associated with considerable weight loss, which varied from 8 pounds to as much as 60 pounds, and some weight loss was almost a constant finding in every case. Gross bleeding in the form of hematemesis or melena was not a common finding except in the leiomyosarcomas, and in the majority of these tumors it was the most prominent symptom. A history of vomiting blood was noted in 5 out of 9 cases of leiomyosarcoma, and 2 patients had gross blood in stools. Gross blood was noticed once in the stools of patients who had lymphosarcoma, but was usually present in all patients upon laboratory examinations of stools. Anemia was a fairly common finding in the leiomyosarcomas, and hemoglobin concentration varied from a low figure of 30 per cent to as high as 96 per cent. There were 5 cases with a hemoglobin of 75 per cent or less, and 3 with less than 50 per cent. On the other hand, only 5 patients out of 32 with tumors of lymphoid origin had hemoglobin concentrations less than 75 per cent. Determination of the gastric acids was made in 22 of the 41 cases and in 12 patients there was complete absence of free hydrochloric acid. Five patients had free hydrochloric acid of less than 20, and 4 had acid values ranging between 20 and 50.

The presence of high gastric acids does not rule out the presence of malignant tumor of the stomach, but the absence of free acid is particularly significant. Gastric neoplasm should be ruled out by every diagnostic means at our disposal when no free acid is demonstrated, and this appears to apply also to sarcoma.

DIAGNOSIS

Roentgenographic studies were made in all 41 cases of the group. In the group of 9 cases of leiomyosarcoma the diagnosis was leiomyoma in 4 cases; 2 cases were described as benign tumors and in 3 cases the diagnosis was carcinoma. The preoperative diagnosis of sarcoma of the stomach was made in only one case in which the tumor arose from lymphoid tissue, but was suspected in 2 cases. The roentgen diagnosis in 28 was carcinoma, and in one it was benign gastric ulcer.

The roentgenologic examination of tumors arising from lymphoid tissue presents no characteristic picture from which a diagnosis can be made with any degree of certainty. However, as Feldman points out, roentgenologic

examination may furnish valuable information which, together with the clinical data, may strongly suggest the possibility of a sarcoma in the stomach. Feldman emphasized that certain signs are observed in cases of lymphosarcoma which might be helpful, notably (1) a filling defect with smooth margins; (2) a localized type of tumor which is round and smooth; (3) in the diffuse type, involvement of large portions of stomach simulating linitis plastica; (4) relief pictures of the stomach often show mucosal rugae in thick folds; (5) the presence of palpable tumors in young individuals strongly suggests the possibility of sarcoma and (6) the presence of multiple ulcers suggests it. On the other hand, it is well to point out that the roentgen examination may not reveal evidence of any definite abnormality in the stomach, and this was true in two cases.

Holmes, Dresser and Camp, in a discussion of the roentgenologic characteristics, also stated that there is nothing diagnostic in the roentgen appearance of the stomach, although peristalsis is not interfered with as much as in most cases of carcinoma. Leiomyomas, however, may have a more characteristic roentgenologic appearance; they very often are diagnosed as benign polypoid tumors of the stomach, and present a circumscribed globular filling defect in the stomach which is fairly characteristic.

Gastroscopic examination may confirm the presence of tumor. Again there are no definite gross features upon visualization of the tumor which will establish the diagnosis of sarcoma, and in the majority of cases a definite diagnosis can be established only by laparotomy.

Gastroscopic examination, however, should be done in all cases in which gastric sarcoma is suspected and Schindler *et al.* stated that more experience in gastroscopy and better diagnostic methods might well reveal a higher incidence and a higher preoperative diagnosis. Taylor in a review of 152 cases in the literature stated that in those cases in which gastroscopy was done there was no characteristic diagnostic feature that could be recognized.

Palpable abdominal tumors were demonstrated in 11 patients, and again it is important to point out that this bore no direct relationship to resectability or to prognosis and unless there was evidence of widespread tumor, exploratory laparotomy should be carried out in all these cases. In this series all but 4 proved to be resectable either by partial or total gastrectomy.

TREATMENT

The only treatment of value in these cases of gastric sarcoma is radical surgery which, in the case of tumors arising on lymphoid tissue, should be followed by deep irradiation treatment. Inasmuch as the majority of these cases are not usually recognized until the time of surgical intervention it would be useless to employ deep irradiation preoperatively, since irradiation treatment would have no effect whatever on gastric carcinoma, and valuable time might be lost before surgical extirpation of a sarcoma could be carried out. Holmes *et al.* suggested resection whenever possible before irradiation. Irradiation of a hollow viscus containing large ulcerating tumor masses always entails danger of gross hemorrhage and perforation. It would also seem wise

in the surgical exploration of extensive tumors arising in the stomach, and which are considered nonresectable, that a biopsy specimen be obtained in every instance so that these infrequent cases of sarcoma could be recognized and irradiation treatment employed if radical surgery does not appear possible.

Only eight patients had postoperative treatment and in seven this was done because of recurrence of tumor; the eighth patient upon surgical exploration and biopsy proved to have Hodgkin's disease of the stomach which was too extensive to be resected. Following operation he was given roentgen therapy over the abdomen and is alive five and one half years after exploration but now has Hodgkin's disease involving the stomach, abdomen, mediastinum and cervical lymph nodes. After roentgen therapy he was able to eat well and remained in reasonably good health until recently.

TABLE III.—Operations for Sarcoma of the Stomach (41 Cases).

Operation	Leiomyosarcoma	Lymphoid Tumors
Exploration and biopsy	0	4
Excision	2	0
Partial gastrectomy	5	19
Total gastrectomy	2	9
Total cases	9	32

It is our impression that postoperative irradiation should be employed routinely in all lymphoid tumors and this might well increase the five-year survival rate and serve to prolong life. Whether irradiation prolonged life in the seven patients who had operation and postoperative irradiation is difficult to state with any degree of certainty; two lived six years, one lived two years and four lived one year, but roentgen treatment was used, as already stated, only in seven patients with recurrent tumor appearing after operation, except in the one case in which resection was not thought feasible.

No irradiation treatment was used in those patients operated on for leiomyosarcoma. Surgical treatment in the entire group of gastric sarcoma consisted of removal of the tumor by partial gastric resection, which was done in 24 cases, and total gastrectomy, which was done in 11 cases. In 4 patients the tumors were not resectable and exploration and biopsy was done. Two of the leiomyosarcomas were removed by excision only of the tumor mass (Table III). There were two postoperative deaths in 41 cases, an operative mortality of 4.9 per cent.

RESULTS OF TREATMENT

The follow-up results of the patients operated on for leiomyosarcoma are surprisingly good (Table IV). Eight of the nine patients are alive and well from one year to 20 years; six patients lived five years or longer, in other words, a 67 per cent five-year or more survival after operation. One patient is dead six years after partial resection, the cause of death unknown (Table IV).

Two patients with leiomyosarcoma had total gastrectomy and are alive and well 12 years and two years respectively. In two patients local excision of the tumor only was done because resection would have involved total gastrectomy.

SARCOMA OF THE STOMACH

Both patients are alive and without recurrence, one ten years (Fig. 1) and one two years (Fig. 2) after operation. It may be true that when wide local excision is possible this may be sufficient in view of the low grade malignancy of this tumor.

TABLE IV.—*Leiomyosarcoma—Nine Cases.*

No. of Years Living and Well	Operation	Cases
20	Partial gastrectomy.....	1
12	Total gastrectomy.....	1
10	Transgastric excision.....	1
10	Partial gastrectomy.....	1
6	Partial gastrectomy.....	1
5	Partial gastrectomy.....	1
2	Partial gastrectomy.....	1
2	Total gastrectomy.....	1

One patient is dead (cause unknown) more than six years after partial gastrectomy. No operative mortality.

Of those patients who had tumors developing from lymphoid tissue, two died immediately after operation and 12 lived an average period of 13 months (Table V), varying from six months to two and one half years. Of the 32 patients with tumors of lymphoid origin, 18 (56 per cent) are alive and well (Table VI). Twelve patients have lived five years or longer, five of whom had Hodgkin's disease; six patients are alive and well six months to two

TABLE V.—*Malignant Tumors of Lymphoid Origin (14 Dead).*

Length of Life After Operation	Hodgkin's Disease	Other Lymphoid Tumors
Operative death.....	1	1
6 months.....	1	3
1 year.....	2	2
1½ years.....	1	0
2 years.....	0	1
2½ years.....	0	2
Total.....	5	9

years. The prognosis on the whole is very much better than it is with carcinoma. It is surprising to note that five patients with localized Hodgkin's disease are alive five years or longer, whereas four patients with Hodgkin's disease died within the first year. Four patients with Hodgkin's disease lived five years or more and one patient is living and well ten years following resection. One patient with Hodgkin's disease has survived five years with roentgen therapy. Excluding the group of patients with Hodgkin's disease, seven of the 22 are living and well over five years, one each five, six, seven, eight years and three for nine years. Eighteen patients or 44 per cent of the group of 41 patients with sarcoma have survived five years or more, which represents a much higher five-year survival rate than in carcinoma of the stomach.

It is of interest to note that 11 patients had total gastrectomy for removal of their sarcoma; of this group, five (45 per cent) have survived five years or longer. Of a group of 26 patients whose tumors (except in 2 cases) were

removed by partial gastric resection, 12 lived five years or longer, a five-year survival of 46 per cent. If one excludes the leiomyosarcomas and considers only the more malignant lymphoid tumors the five-year survival following total gastrectomy was 33 per cent, whereas the five-year survival rate follow-

TABLE VI.—*Malignant Tumors of Lymphoid Origin; 17 Patients Alive and With No Recurrence**

Length of Life After Operation	Hodgkin's Disease	Other Lymphoid Tumors
6 months.....	0	2
1 year.....	0	2
1½ years.....	0	1
2 years.....	0	1
3 years.....	0	0
5 years.....	1	1
6 years.....	2	1
7 years.....	0	1
8 years.....	0	1
9 years.....	0	3
10 years.....	1	0
Total.....	4	13

* One patient with Hodgkin's disease was not operated on but was given irradiation treatment and is alive five and a half years later but has generalized Hodgkin's disease, making a total of 18 patients still alive.

ing partial resection was 42 per cent. It must be remembered, however, that total gastrectomy was done only for the more extensively involved cases.

It is not surprising that the survival rate following resection of leiomyosarcoma is high. The tumors appeared to be adequately excised locally and there were no demonstrable metastases at the time of surgery. Only one patient died and the cause of death in this case is not known.

The survival rate following resection of malignant lymphoid tumors of the stomach is also surprisingly high. This is in marked contrast to the low survival rate following resection for gastric cancer. The patients still alive had tumors which showed no apparent difference in regard to size, location, ulceration or metastases from the tumors in the patients now dead. Seven of the 17 patients still alive showed tumor in the regional lymph nodes in the resected specimen. One, for example, with Hodgkin's disease had a 10 cm. gastric tumor and metastases to each of 15 curvature lymph nodes, but the patient is alive and without evidence of recurrent disease six years following resection (Fig. 5). The remarkable survival rate in the lymphoma series does not, of course, necessarily mean a cure, for lymphoid tumors in other portions of the body may be present for a number of years before causing death. However, this is unusual and it is significant to note that Nathanson and Welch found that the median life expectancy for patients with generalized lymphoid tumors was two years.

SUMMARY

A clinical analysis is given of 41 patients with sarcoma of the stomach treated in the Lahey Clinic over a period of 20 years, an incidence of sarcoma

of the stomach of 3.7 per cent. The diagnosis of sarcoma is rarely made before surgical intervention and the clinical picture of this disease is very little different from that of carcinoma. The outstanding symptoms are anorexia, indigestion, epigastric pain and weight loss; cachexia is uncommon.

There were two types of gastric sarcoma in the series, those of smooth muscle origin, the leiomyosarcomas, and the malignant lymphoid tumors.

Roentgenologic examination presents no characteristic picture which permits recognition preoperatively except in the cases of leiomyosarcoma. Certain roentgenologic findings suggest its possibility, and sarcoma should always be considered in the diagnosis.

The prognosis is surprisingly good after surgical treatment; 18 patients or 44 per cent survived five years or longer.

Treatment of gastric sarcoma is radical surgery. Irradiation treatment should be used postoperatively for patients whose tumors arise from lymphoid tissue. There were two deaths following operation in 41 patients.

BIBLIOGRAPHY

- 1 Balfour, D. C., and J. C. McCann: Sarcoma of the Stomach. *Surg., Gynec. and Obst.*, **50**: 948, 1930.
- 2 Cheever, D.: Clinical Aspects and Treatment of Primary Lymphosarcoma of Stomach and Intestines. *Ann. Surg.*, **96**: 911, 1932.
- 3 Collins, F. K., and D. C. Collins: Surgical Significance of Gastric Leiomyomas. *West. J. Surg.*, **46**: 188, 1938.
- 4 Conley, R. H., and J. H. Olwin: Leiomyosarcoma of the Stomach. *Am. J. Clin. Path.*, **19**: 966, 1949.
- 5 D'Aunoy, R., and A. Zoeller: Sarcoma of the Stomach: Report of Four Cases and Review of the Literature. *Am. J. Surg.*, **9**: 444, 1930.
- 6 Douglas, J.: Sarcoma of the Stomach, with Report of Three Cases. *Ann. Surg.*, **71**: 628, 1920.
- 7 Ewing, J.: *Neoplastic Diseases*. Ed. 3, Philadelphia, W. B. Saunders Company, 1928.
- 8 Feldman, M.: *Clinical Roentgenology of the Digestive Tract*. Baltimore, Wm. Wood and Company, 1938.
- 9 Forni, G.: Contributo Allo Studio Del Sarcoma Primitivo Dello Stomaco. *Riforma med.*, **30**: 624, 1914.
- 10 Holmes, G. W., R. Dresser and J. D. Camp: Lymphoblastoma. *Radiol.*, **7**: 44, 1926.
- 11 Lahey, F. H., and B. P. Colcock: Diagnosis and Surgical Management of Leiomyomata and Leiomyosarcomata of the Stomach. *Ann. Surg.*, **112**: 671, 1940.
- 12 Madding, G. F., and W. Walters: Lymphosarcoma of the Stomach. *Arch. Surg.*, **40**: 120, 1940.
- 13 Meissner, W. A.: Leiomyoma of the Stomach. *Arch. Path.*, **38**: 207, 1944.
- 14 Nathanson, I. T., and C. E. Welch: Life Expectancy and Incidence of Malignant Disease; Malignant Lymphoma, Fibrosarcoma, Malignant Melanoma, and Osteogenic Sarcoma. *Am. J. Cancer*, **31**: 598, 1937.
- 15 Schindler, R., O. A. Blomquist, H. L. Thompson and A. M. Pettler: Leiomyosarcoma; Roentgenologic and Gastroscopic Diagnosis; Possible Relation to Pernicious Anemia. *Surg., Gynec. and Obst.*, **82**: 239, 1946.
- 16 Taylor, E. S.: Primary Lymphosarcoma of the Stomach. *Ann. Surg.*, **110**: 200, 1939.
- 17 Warren, S., and C. R. Lulenski: Primary, Solitary Lymphoid Tumors of the Gastrointestinal Tract. *Ann. Surg.*, **115**: 1, 1942.
- 18 Yarnis, H., and R. Colp: Lymphosarcoma of the Stomach. *Gastroenterol.*, **1**: 1022, 1943.