

VASCULAR INJURIES OF WARFARE*

LT. COL. DANIEL C. ELKIN, M.C., A.U.S.

FROM THE VASCULAR SURGERY CENTER, ASHFORD GENERAL HOSPITAL,
WHITE SULPHUR SPRINGS, WEST VIRGINIA.

ACCOUNTS OF INJURY to blood vessels in warfare have been recorded since the beginning of history, and the attention of surgeons has of necessity been primarily directed towards their treatment because of their often fatal nature. The arrest of hemorrhage and the preservation of an adequate arterial supply to the extremities have been, in fact, the main concern of military surgeons since the dawn of recorded medical history, and numerous papers concerning vascular injuries have appeared in medical literature following every war. The number of such injuries has increased steadily, probably due to the introduction of higher velocity projectiles of smaller caliber. In addition to the ordinary wounds caused by machine gun, rifle bullets and shrapnel, a great many multiple injuries are being produced by the fragmentation of land mines, grenades and aerial bombs. These latter may produce as many as one hundred small individual wounds scattered over the body without causing death, thus increasing the chance of trauma to blood vessels. It is, therefore, to be expected that the sequelae of these injuries will be encountered more numerous than ever before. Moreover, improved methods in the control of hemorrhage, shock, and infection have preserved more individuals for subsequent observation and study.

In order to bring about more highly specialized treatment of certain surgical conditions, the Surgeon-General has established centers for their treatment. In view of the fact that Ashford General Hospital is designated as one of two centers for vascular surgery, no doubt a larger proportion of this type of injury is seen at this institution.

For descriptive purposes, vascular injuries as result of war wounds may be divided as follows:

1. Those in which the blood vessel is completely severed or in which vasospasm exists to such an extent as to so impoverish the blood supply that death of the part or useless fibrosis results.

2. Activation of previously existing blood vessel disorders or tumors, such as congenital nevi and preexisting vascular injuries.

3. Partial severance of a vessel producing a false aneurysm or arterio-venous fistula.

Numerous instances of all these lesions in varying degree have been observed, and illustrative types of each are described here in detail.

I--ARTERIAL OCCLUSION

Arterial occlusion, either complete or partial, may result from several

* Read before The American Surgical Association, May 3-4, 1944, Chicago, Ill.

factors, all traumatic in nature. A vessel may be completely severed requiring ligation, and unless collateral flow is adequate, gangrene or a condition not unlike Volkmann's ischemic paralysis will result. Similarly, the vessels may be occluded by compression of a hematoma or some infringement upon its lumen by fractured bones, or by too tight splinting or prolonged and improper application of a tourniquet. While the factor of venous occlusion in producing this state cannot be overlooked, surely the clinical manifestations, generally described as Volkmann's paralysis, do occur following arterial occlusion, as will be shown in illustrative cases.

A vessel may, likewise, be completely or partially occluded by spasm. A number of factors may bring about a reflex vasospasm and produce the picture classically described by Leriche. This may occur where only the outer wall of an artery has been injured or even in cases of trauma to adjacent tissues without actual injury to the vessel itself. While vasospasm is a natural protective response to trauma, it may be so extensive in character that death of a part or its crippling may result. It may be segmental, involving only a small portion of a vessel, or it may reflexly involve other vessels of an extremity or even produce a vasomotor imbalance of more than one extremity or even the whole body. Where the whole arterial tree of an extremity undergoes such a change interference with collateral circulation is pronounced, and under such circumstances the limb is white, numb, cold, pulseless and paralyzed. If relaxation occurs within a few hours, either spontaneously or through operative measures, the limb may return to normal, but if constriction persists, thrombosis will occur and varying degrees of trophic changes will result—gangrene or fibrosis with atrophy, stiffness of the joints, and a fixation deformity. An excellent account of these matters has been published by Griffiths¹ (1940), and, more recently, by DeBakey² (1944).

Case 1.—Ischemic contracture with gangrene of right hand following severance of axillary artery; median and ulnar nerves. Thrombosis of distal brachial vessels. Suture of median and ulnar nerves. No improvement in nutrition of hand following physiotherapy.

This soldier was struck by a machine gun bullet in the upper inner aspect of the right arm May 6, 1943. The entire arm immediately felt numb, and he was unable to use it. He lost considerable blood. He was operated upon shortly afterwards, and it was found that the right brachial artery had been severed, but it was believed that the nerves were intact. Débridement of the wound was carried out. On the second day after the operation there was considerable swelling of the entire arm from the area of the wound to the finger tips. He developed blisters in the palm of his hand, and the tip of the right ring finger sloughed off. There was superficial sloughing in the palm. He entered Ashford General Hospital October 1, 1943. At that time the gangrenous areas were practically healed, but there was sensory and motor evidence of ulnar and median nerve paralysis. The arm, forearm, and hand were atrophic, and the latter was held in a fixed flexion contracture. On October 21, 1943 exploration of the lower axilla was done (Major Barnes Woodhall). It was found that the ulnar and median nerves were completely severed, and that the axillary artery had been divided and ligated. The divided nerves were sutured. The distal end of the divided

artery could not be found. Physiotherapy by means of whirlpool baths, massage and exercises has brought about no improvement, and the hand and forearm remain fixed and atrophic (Fig. 1).

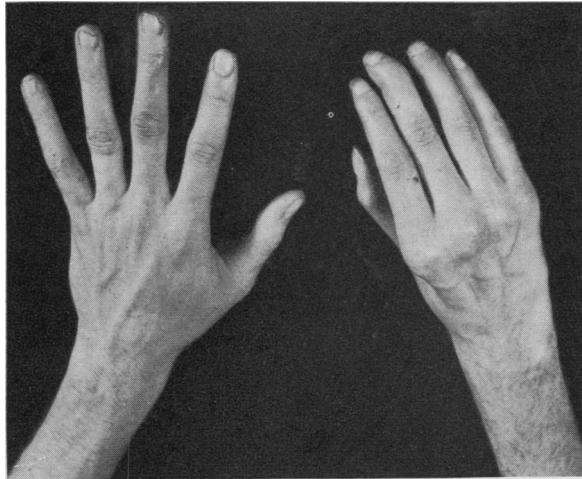


FIG. 1.—Case 1: Showing atrophy, fibrosis, and fixation of the right hand following severance of the brachial artery.

Case 2.—*Ischemic contracture following dislocation of left elbow. Probable spasm followed by thrombosis of left upper extremity vessels. Little improvement following physiotherapy.*

This soldier was injured in an airplane accident February 9, 1943, at which time he sustained a dislocation of the left elbow. Upon admission to a Station Hospital at that time no pulse could be felt in the left radial artery, but the hand was warm and slightly cyanotic. There was some anesthesia in the distribution of the ulnar nerve and no voluntary motion of the fingers was possible. The dislocation was reduced and an encasement applied which remained in place for six weeks. Two weeks later there was

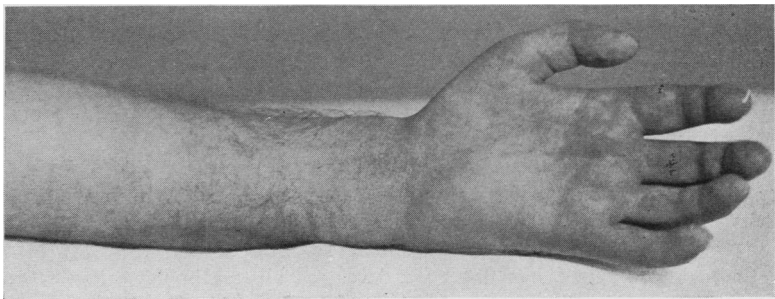


FIG. 2.—Case 2: Showing the "frozen-hand" characteristic of thrombosis of the brachial vessels.

return of normal sensation to the hand, but the patient was unable to use it. Examination at this hospital, September 9, 1943, showed an atrophy of all the muscles of the left arm, forearm, and hand. Motion of the shoulder girdle and elbow joint could be carried out but was weak. Flexion and extension of the wrist were limited to 30

degrees. The fingers were held in a slight flexion curvature and only a few degrees of motion could be carried out in them. The skin was red, slick, and atrophic (Fig. 2). No arterial pulsation could be felt in any of the vessels of the left upper extremity. Sensation was normal. Oscillometric determinations showed a "flicker" of pulsation in the midarm but none at the wrist. Physiotherapy in the form of heat, massage, and whirlpool baths has brought about little improvement.

Case 3.—*Multiple wounds of the right arm, chest, and left thigh on July 11, 1943. A-V aneurysms of left femoral and right brachial vessels. Compound fracture right elbow with ulnar, median, and radial nerve paralyses. Excision A-V fistula left femoral September 7, 1943. Rapid healing of elbow fracture under penicillin therapy. Necrosis of right forearm necessitating amputation. Excision of brachial A-V fistula.*

This 21-year-old officer sustained mortar, shrapnel and machine gun wounds of chest, extremities and back July 11, 1943. The first injury received was that of his right arm, and he immediately noticed that he was unable to move this extremity.




FIG. 3.—Case 3: Amputated arm showing necrosis of tendons and muscles.

Bleeding from a wound in the upper brachial region was profuse. About the same time he received a wound in the left thigh and shortly thereafter he was wounded in the right chest. Five minutes later he lost consciousness. He was immediately evacuated from the line of fire and his wounds were dressed, and he was given plasma. He regained consciousness 24 hours later. He was evacuated through hospitals to the Ashford General Hospital which he reached on September 26, 1943. The compound fracture of the right elbow was badly infected but cleared up rapidly under penicillin therapy. The arteriovenous fistula of the left thigh was successfully treated by excision on October 7, 1943. By October 19, 1943, the wounds of the elbow region were red and granulating, and a Thiersch graft was placed upon the two largest of them. Six days later the wound was dressed, and the grafts appeared to be viable. Penicillin was discontinued at this time. Three days later the temperature became elevated to 103° F. Examination at this time revealed that the entire musculature of the right forearm was necrotic, although the skin remained healthy in appearance with good arterial pulsations. Since the necrotic process appeared irrevocable, guillotine amputation was performed just above the elbow. Examination of the specimen showed that the muscles and tendons were necrotic throughout (Fig. 3). The arteriovenous fistula of the brachial vessels was excised on November 16, 1943. The stump of the amputated arm was later closed, and the patient recovered without further difficulty.

Case 4.—*Multiple wounds of back, left forearm and flank July 14, 1943. Excision of arterial aneurysms of left brachial and ulnar arteries September 6, 1943. Arterial spasm in left hand followed by vasomotor disequilibrium of all extremities, face, and trunk.*

This soldier was wounded July 14, 1943, at which time he received multiple small wounds of the left arm, left flank, and back. The larger of the wounds was débrided.

On September 6, 1943, two aneurysms, one of the lower brachial and the other of the ulnar artery, were excised on the left side. (Captain Kremer, 26th General Hospital.) One week later he began having intermittent attacks of arterial spasm in the left hand characterized by pain, cyanosis, and occasional blanching, particularly if he was exposed to cold. A week after this he noticed that the right hand became cyanotic, and this was soon followed by cyanosis of both feet, the color changes in all four extremities

'Y'

TEST SPINAL ANAESTHESIA DATE 24 February 1944

OSCILLOMETRY

<u>CONTROL</u>			<u>20 Minutes after Spinal</u>		
	<u>RIGHT</u>	<u>LEFT</u>		<u>RIGHT</u>	<u>LEFT</u>
Popliteal	7.5 at 100 mm	8.0 at 100 mm	Popliteal	7.0 at 110 mm	6.75 at 100 mm
Tibials	4.0 " 100 "	3.75 " 100 "	Tibials	6.0 " 80 "	6.0 " 80 "
Foot	0.5 " 90 "	0.5 " 90 "	Foot	2.5 " 60 "	2.5 " 60 "

SKIN TEMPERATURES
IN DEGREES FAHRENHEIT

ROOM TEMP. 76 °F.

<u>CONTROL</u>	<u>20 Minutes after Spinal</u>	
	<u>R</u>	<u>L</u>
1st Toe	87.5	84.5
2d "	87.0	84.0
3d "	88.5	87.0
4th "	86.0	82.0
5th "	84.0	81.0
Plantar	84.5	83.0
Dorsum	90.0	88.0
Ankle	86.5	88.0
Midleg	91.0	91.0
Knee	87.0	88.0
Thigh	90.5	90.5

	<u>20 Minutes after Spinal</u>	
	<u>R</u>	<u>L</u>
1st Toe	92.5	94.0
2d "	93.0	93.0
3d "	93.0	93.0
4th "	92.0	93.5
5th "	92.0	94.0
Plantar	93.0	93.5
Dorsum	94.0	94.0
Ankle	93.5	94.0
Midleg	93.0	93.5
Knee	93.5	95.0
Thigh	92.5	92.5

FIG. 4.—Case 4: Showing increase in oscillations and temperature of the feet following spinal anesthesia.

increasing but at times returning to normal. On September 27, 1943, a novocaine cervical sympathetic block was performed. This produced a warm dry hand lasting for three hours. A second block on October 13, 1943, produced a Horner's syndrome, with little change in his hand or arm. He was admitted to Ashford General Hospital December 3, 1943. *There was nothing in his history to indicate any vasomotor disturbances prior to being wounded on July 14, 1943, in spite of active duty in a cold climate.*

On examination, both hands to the wrists were markedly ruborous and cold. Perspiration was increased. Both feet assumed an ever-changing pattern of color beginning on dependency, with mottled areas of deep cyanosis alternating with blotches of deep rubor. The cyanosis was seen at the terminal digits over the phalangeal joints on the plantar surface of the toes and on the medial plantar side of the feet. The remainder of the feet was deep red in color. On complete dependency the plantar portion of the

feet and toes became so completely cyanosed as to resemble the dusky grayness of impending gangrene. There were no trophic changes.

The brachial blood pressure was 130/100. All pulses were present but were weak in both feet. On elevation of the feet palor of the toes was marked on the medial plantar surfaces. His face was intensely red especially over the malar prominences. The nose had areas of mottled cyanosis and redness, and the ears were intensely red in spite of being cool to palpation. Upon light scratching of both the chest and the intrascapular regions, a typical dermatographia was elicited with wheals and erythema. Oscillometric determinations and temperature readings before and after spinal anesthesia are shown on Figure 4. It will be noted that after elimination of constriction impulses the oscillations in the tibial regions almost doubled, and the readings in the feet increased five times. The readings under spinal anesthesia were practically twice that found in the normal individual. The skin temperatures rose from five to ten degrees in the toes and feet; about three to five degrees in the legs. The readings were above those seen in the normal individual.

DISCUSSION.—The treatment of vascular occlusion, either from severance of a vessel or traumatic vasospasm, presents a problem of unusual difficulty. The final result and the ultimate prognosis will depend in the main upon the original treatment received shortly after the injury. In the first place, a tourniquet should never be applied if bleeding can be controlled otherwise, and if applied it should be as near the wound as possible. An Esmarch bandage is preferable to a rubber tube.

Every effort should be made to preserve the continuity of an artery, and in lateral lacerations repair may be possible. If ligation should be necessary, it should *not* be done in continuity but should be sectioned completely, since the division prevents peripheral arteriospasm and secures the best collateral circulation. Section and ligation of companion veins should likewise be carried out. Repair should be attempted only when it appears to be the sole means of saving a limb. Vasodilatation by means of sympathetic procaine block frequently repeated, or by sympathectomy, should be performed if the integrity of the circulation appears in doubt.

Other procedures, such as the use of plasma or blood to obtain an adequate blood pressure, the use of heparin to prevent thrombosis, and the position of the limb for maximum circulatory balance, should be employed if conditions do not otherwise contraindicate their use. In large lacerated wounds and in those accompanied by damage to other tissues such as bones and nerves, splinting is essential, but immobilization should be discontinued at the earliest possible moment and early motion instituted in order to prevent joint fixation.

In cases of traumatic vasospasm, therapy is directed to the removal of reflex vasoconstrictor impulses. This may be brought about by removal of traumatized tissue, periarterial sympathectomy or better still by procaine sympathetic block or sympathectomy.

In the late stages where contracture deformity has taken place, as illustrated by Cases 1 and 2, any progress toward recovery will be slow and the eventual outlook poor. Physiotherapy in the form of heat, massage, and whirlpool baths is indicated as are splinting and occasional plastic procedure to correct deformity.

Where vasomotor imbalance follows arterial injury, as in Case 4, the interruption of vasoconstrictor fibers by sympathectomy to one or more extremities may restore a proper balance and in any event should be tried provided there is temporary improvement following procaine block.

II—PREEXISTING VASCULAR LESIONS

It is the belief of many who have studied the subject that cirroid aneurysms, pulsating angiomas, and arteriovenous aneurysms are essentially the same condition, all being a form of abnormal communication between arteries and veins in varying degree. It is well known that vascular nevi, congenital telangiectases, or angiomas, in which the intermediary incidence of trauma has occurred, may be the starting point of disfiguring and disabling vascular tumors. Moreover, vascular injuries, apparently dormant or inactive, may, likewise, become activated by further trauma. It is to be expected, therefore, that war injuries, either as result of direct trauma or following long continued irritation, will give rise to such conditions in increasing numbers. That twelve instances of this nature have been seen at Ashford General Hospital in the past year bear out this assumption. Four of them are cited below in detail as examples. The seriousness of this lesion as a potential hazard must not be overlooked, for an apparently innocent lesion may be the source of a disabling defect requiring major surgical procedures, including amputation. Although trauma plays the major rôle in their inception, there are probably other factors as yet unexplained which have a part in their development. When contributing arteries and outgoing veins succeed in forming diffuse anastomosis through a cavernous bed, the lesion becomes nothing more than a diffuse arteriovenous fistula. While the existence of a congenital lesion can usually be elicited from the history, this abnormality need not always be present. A wound, particularly if inflicted upon superficial vessels, such as those of the scalp, face, fingers or toes, will often give rise to these diffuse tumors, and additional trauma such as bruising or prolonged irritation may contribute further to their development. In any outspoken example of this condition the clinical picture is such a striking one that the case is likely to be reported, and there is an extensive literature on the subject. (Elkin,³ Reid,⁴ and Pemberton⁵.)

Case 5.—*A small, bluish, pigmented mass in right axilla, present since childhood. Ten months trauma from rifle recoil, with marked increase in size. Complete excision and skin graft.*

This soldier is known to have a small bluish discoloration in his right axilla since childhood which had given him no trouble and which had increased only slightly in size. During ten months Army service the mass was subjected to the trauma caused by recoil of a rifle, and during that time the mass had markedly increased in size until it extended throughout the whole right axilla. Large dilated veins, easily compressible, covered an area about six inches in diameter (Fig. 5). There was no bruit and no thrill. Numerous small venules were present in the skin of this region. On December 17, 1943 skin incisions were outlined which extended beyond the dilated blood vessels. The skin of this area was completely excised as were the subcutaneous tissues, down to and including the pectoral and axillary fascia. Numerous dilated veins communicated

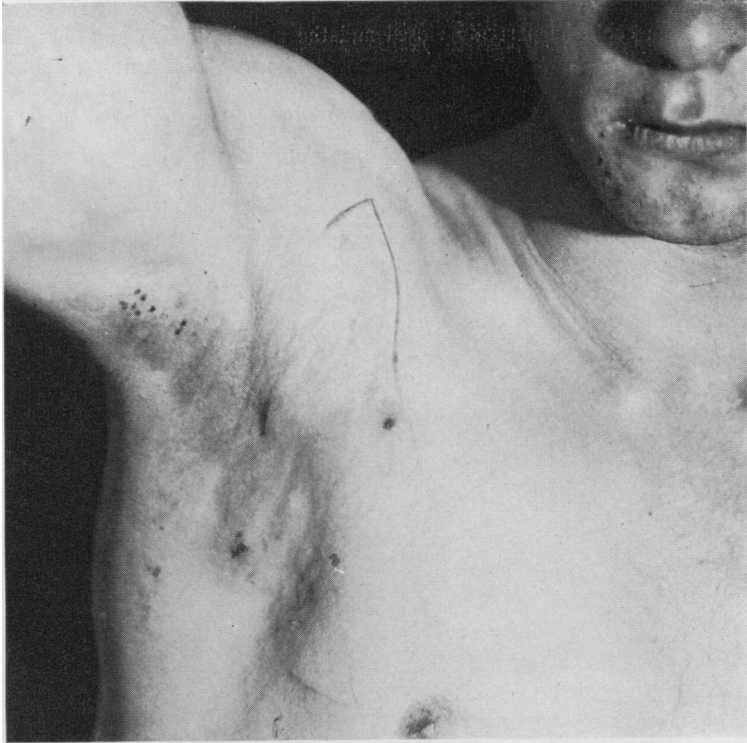

FIG. 5.—Case 5: Appearance of hemangioma of axilla.

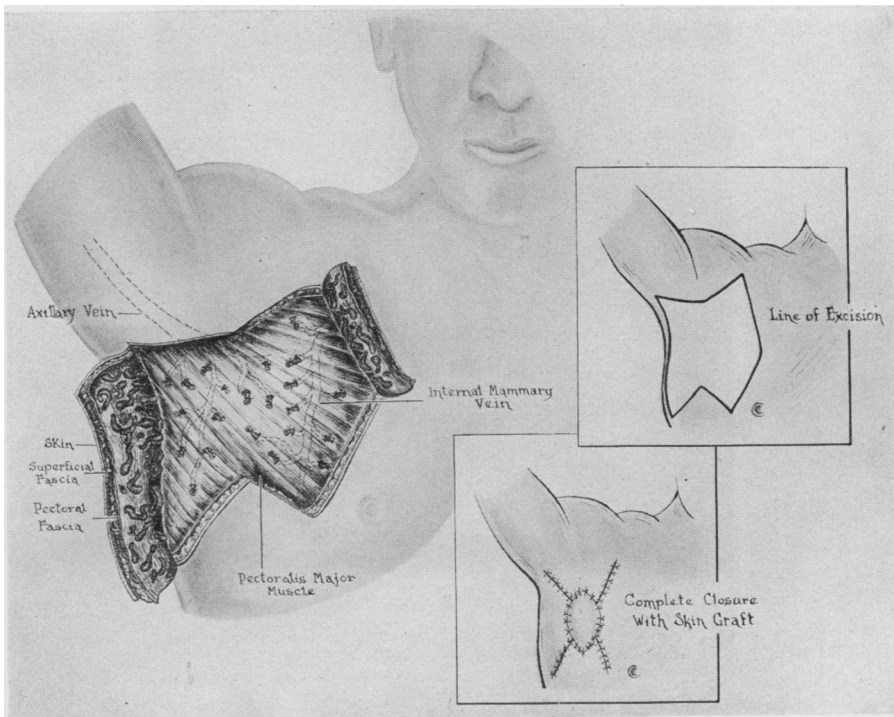


FIG. 6.—Case 5: Hemangioma of axilla showing line of excision and method of closure.

with this area and entered, for the most part, the cephalic and axillary veins. After excision the skin could be partially closed and the remainder was covered with a skin graft (Fig. 6). There has been complete recovery with no evidence of recurrence.

Case 6.—*Childhood injury, sole of left foot, by glass. Diffuse arteriovenous fistula, sole of left foot involving plantar vessels noticed 30 years after original injury following excessive marching. Complete excision of fistula after preliminary ligation of posterior tibial and dorsalis pedis vessels.*

This 37-year-old Dental Officer stepped on a piece of glass in 1914, causing a one-inch laceration in the midplantar region of the left foot. Bleeding was profuse, but healing was uneventful. In 1938 he noticed the appearance of large blood vessels over the left foot and leg. He entered the Army in December 1943 with a "waiver for varicose veins." After three weeks of basic training, at which time he underwent

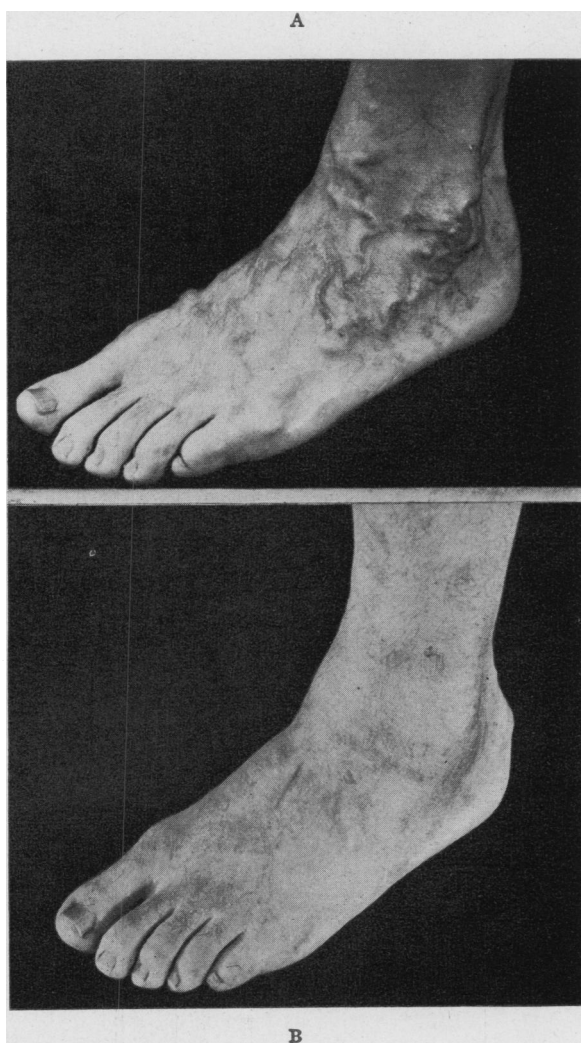


FIG. 7.—Case 6: A. Diffuse arteriovenous aneurysm, sole of foot, showing marked enlargement of veins.
B. Showing appearance of the foot, one month after excision of the aneurysm.

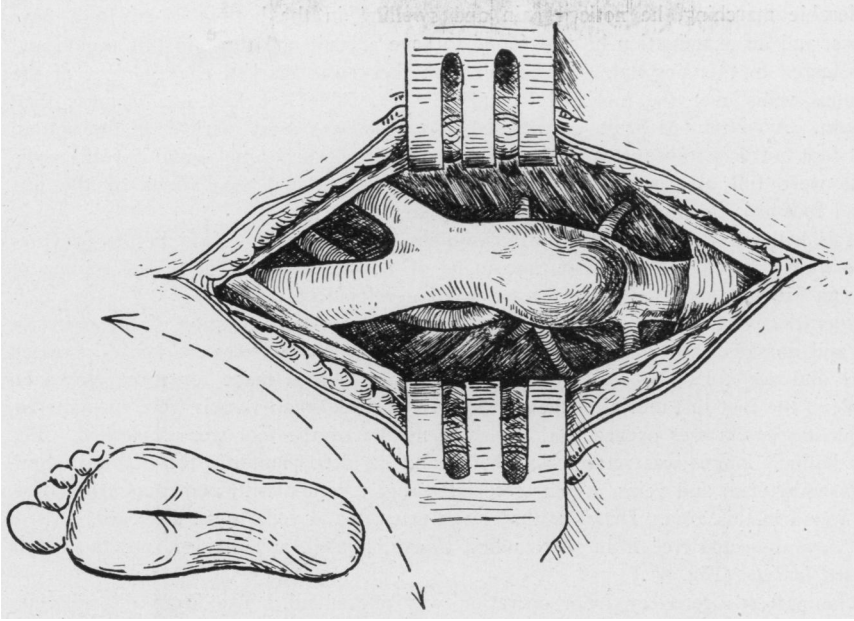


FIG. 9.—Case 6: Showing appearance of the aneurysm in the sole of the foot.

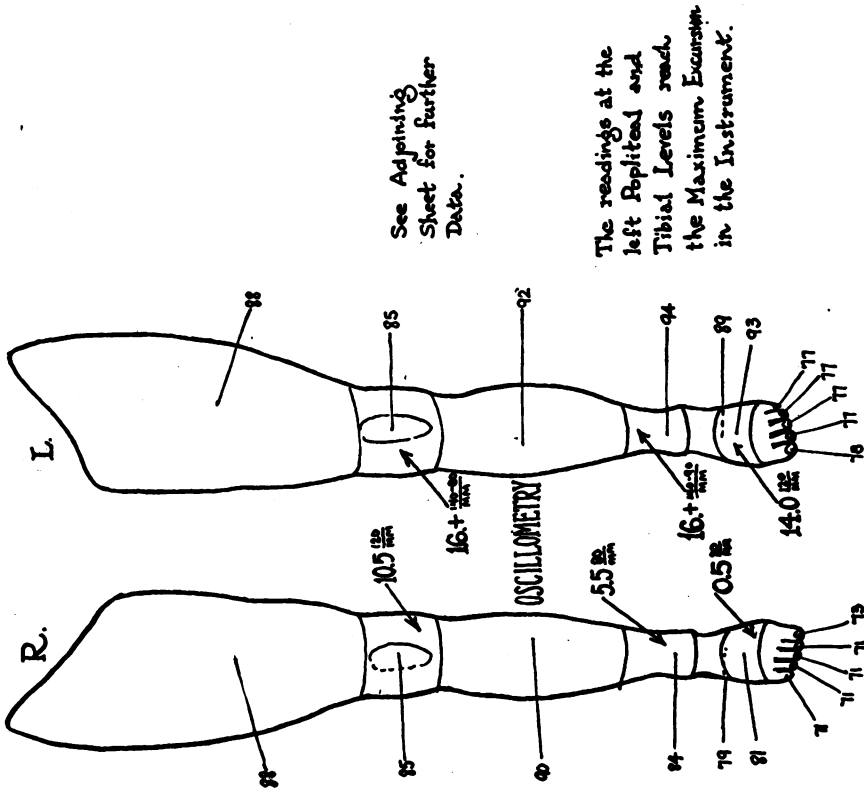


FIG. 8.—Case 6: Showing increased oscillations and temperature of left leg and foot in case of diffuse arteriovenous aneurysm of foot.

considerable marching, he noticed pain and swelling in the bottom of his foot near the toes, and on examination he was found to have a bruit and thrill in this region and was referred to this hospital. On examination there was marked engorgement of the saphenous veins over the foot and leg (Fig. 7 A). The left foot was warmer than the right. A continuous bruit, accentuated in systole, was most marked on the bottom of the foot but was transmitted to the whole leg. The posterior tibial and dorsalis pedis vessels were full and bounding. Increased temperature and oscillations of the left leg and foot are shown in the accompanying chart (Fig. 8).

It is believed that this diffuse arteriovenous fistula had its origin in the previous injury which was thought at that time to be of trivial nature. The added trauma of marching brought about a rapid increase in its development.

Operation was performed February 15, 1944. Preliminary ligation of the posterior tibial and dorsalis pedis arteries was done. The former vessel was markedly increased in size and was tortuous. A longitudinal incision was then made for three inches on the sole of the foot just medial to the old scar. Numerous small vessels were encountered. The plantar fascia was opened, and the short flexors of the foot were separated. The flexor hallucis longus was retracted medially, and the deep plantar space exposed. Several large arteries and veins, which were pulsating, together with numerous tributaries, were found in this area. Distal to this, large arteries and veins were disclosed. All of these were dissected free from surrounding tissues, ligated, and divided, and the fistula removed *in toto* (Fig. 9).

The patient's recovery from operation was uneventful. The large dilated veins previously noted disappeared in a period of about three weeks (Fig. 7 B). There has been no return of bruit and thrill, and he returned to duty May 1, 1944.

Case 7.—*Crushing injury to the left foot in 1937. No fracture. Recovery in eight months. Diffuse arteriovenous fistula, sole of left foot involving plantar vessels, noticed 1941 following marching. Complete excision of fistula after preliminary ligation of posterior tibial and three dorsal vessels.*

This 23-year-old soldier sustained a crushing injury to the left foot in civilian life in 1937. No fractures were found, and the foot was strapped. There was considerable swelling and pain for about eight months. In November, 1941, after one year in the Army, he first noticed a "humming" in his foot, with pain and swelling. He had been subjected to the strenuous activities of a soldier on Guadalcanal, and the symptoms all increased and became aggravated by marching. He entered Ashford General Hospital February 29, 1944. Examination was normal except for the left foot and leg. The left foot was slightly swollen. The superficial veins were dilated and tortuous, and a thrill could be felt over the dorsal and plantar regions, most marked on the plantar surface (Fig. 10 A). There was a loud continuous bruit with systolic accentuation over the entire foot which was transmitted up the leg to the midcalf posteriorly. The thrill and murmur could be obliterated by pressure over the posterior tibial artery. There were several pulsating vessels on the dorsum of the foot. The left foot showed increased warmth and increased oscillations (Fig. 11).

Operation was performed March 4, 1944. The posterior tibial vessels were exposed behind the medial malleolus and ligated and cut. The dorsalis pedis artery was treated in a similar manner. A longitudinal incision was made in the sole of the foot about four inches long over the region of the fourth metatarsal bone. The plantar fascia was divided longitudinally, and the small muscles of the foot were separated until the plantar vessels were reached. Large posterior tibial arteries were found entering this region and communicated with a dilated venous sac. Distal vessels, both arteries and veins, as well as lateral communications were also encountered. All of these were pulsating in spite of the previous ligations. Since they appeared to communicate with abnormal dorsal vessels, two additional incisions were made on the dorsum of the foot, and vessels in this region were ligated there. The sac, with its communicating arteries and veins, was then excised and removed after ligating and cutting all communicating branches (Fig. 12).

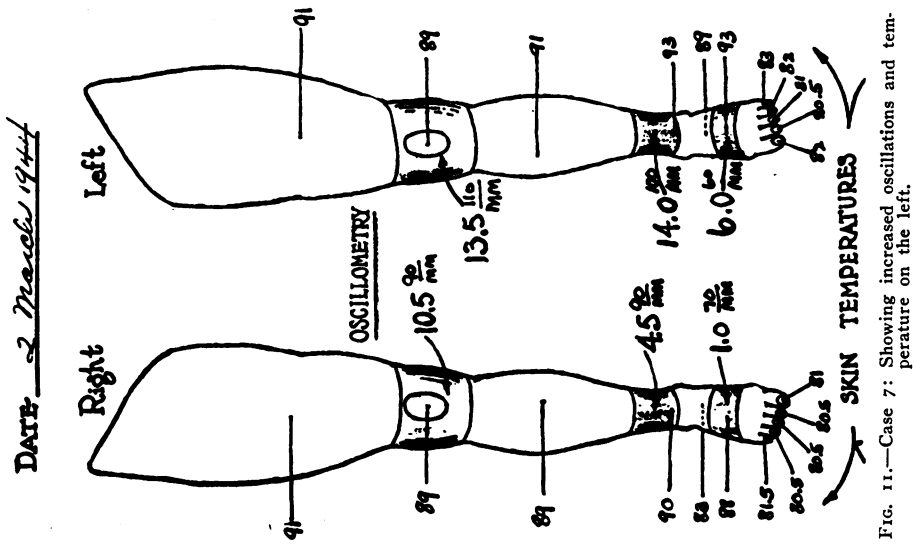


FIG. 11.—Case 7: Showing increased oscillations and temperature on the left.

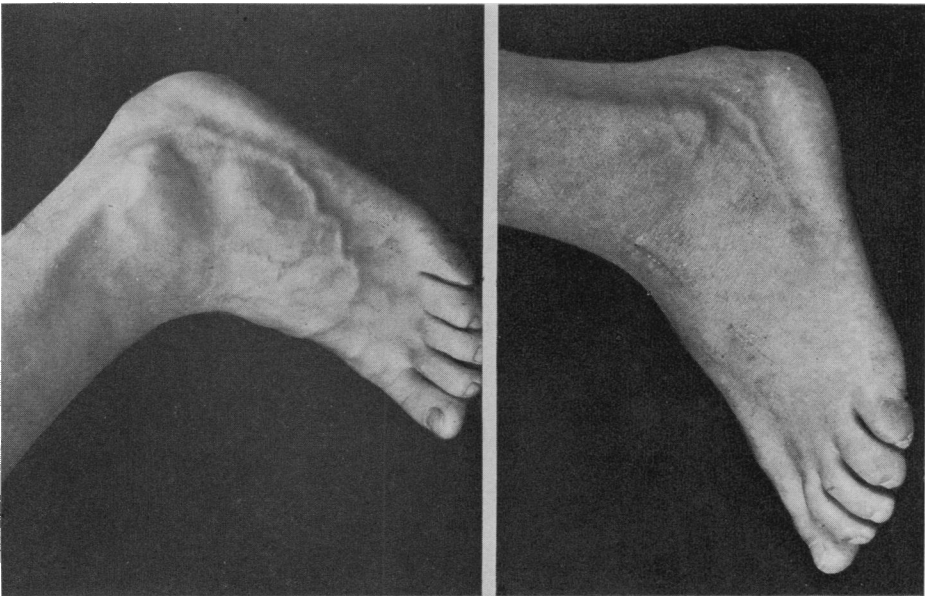


FIG. 10.—Case 7: A. Showing engorgement of veins of foot. B. Showing appearance of foot after excision of the aneurysm.

All wounds were closed with silk. At the end of operation there was no evidence of a bruit or thrill, and the toes were warm and pink. There has been no return of the bruit and thrill, and the dilated veins about the foot have disappeared (Fig. 10 B).

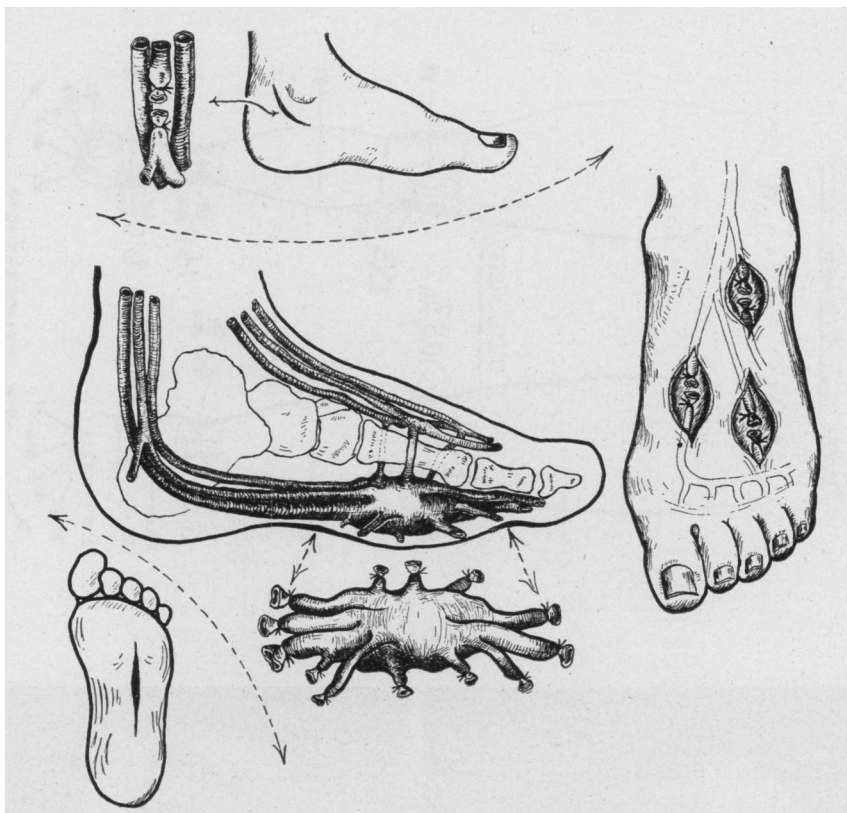


FIG. 12.—Case 7: Showing, schematically, the preliminary ligation of vessels and complete excision of the lesion.

Case 8.—*Small hemangioma, sole of right foot since childhood. In July, 1943, the foot injured by jumping into a fox hole, followed by gradual increase in size of tumor. Unsuccessful attempt to excise tumor. Severe hemorrhage necessitating amputation.*

In infancy it was noted that patient had a mass on the plantar surface of the right foot. It caused no discomfort and did not limit his activity. At age 12, it was noticed that the right leg was slightly longer than the left. Six years before entrance into this hospital he noticed prominence of the veins of the left foot and ankle. On July 25, 1943, in action in Sicily, he struck the plantar surface of his foot when he jumped into a fox hole. Following this there was pain and gradual increase of the swelling on the plantar surface of the foot. On August 10, 1943, an unsuccessful attempt was made to remove the tumor, and the posterior tibial artery was ligated.

On examination at Ashford General Hospital there was an expansile, pulsating, compressible mass involving the whole sole of the right foot, extending from the heel to the toes (Fig. 13 A). There was a continuous thrill and bruit over this area accentuated in systole. The veins of the right leg were dilated. The right foot was warmer than the left, and the right leg was 6 cm. longer than the left. There were marked increased oscillations on the right side.

VASCULAR INJURIES OF WARFARE

On December 20, 1943, an attempt was made to excise the aneurysm after ligation of the posterior tibial and dorsalis pedis vessels. The whole plantar surface was a mass of dilated venous and arterial sinuses. Hemorrhage from them could only be controlled with a tourniquet and, after a three-hour attempt to ligate them individually and *en masse*, it was felt that any procedure other than amputation might prove fatal. Amputation was accordingly performed.

Injection of the arterial tree of the amputated foot is shown in Figure 13 B. Even after ligation of a large number of vessels, numerous dilated sinuses are still present.

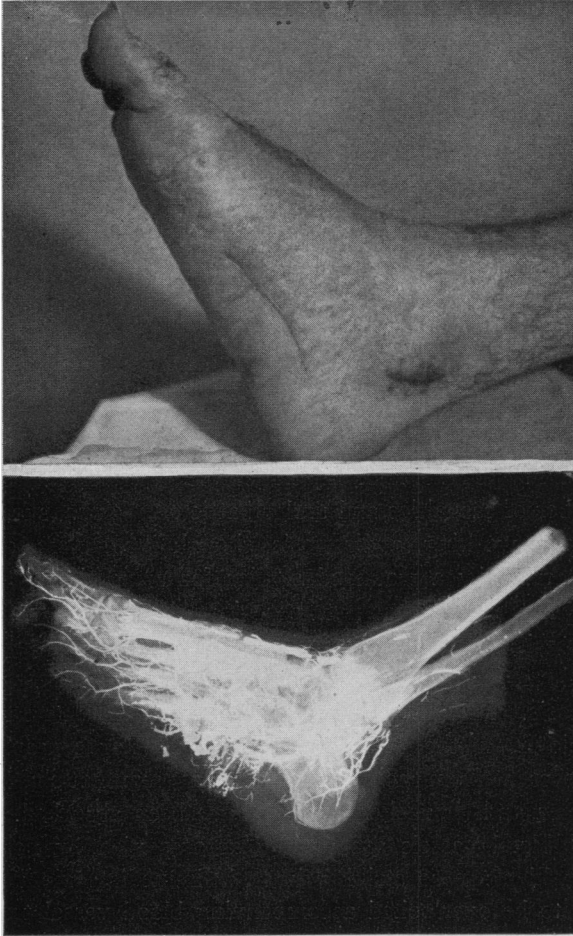


FIG. 13.—Case 8: A. Appearance of the foot before final operation. The posterior tibial artery has been ligated and unsuccessful attempt made to extirpate the lesion.
B. Arteries of the amputated limb injected with mercury. Note numerous collaterals about the points of ligation and the increased vascularity of the whole foot.

DISCUSSION.—A variety of operative procedures has been employed in the treatment of these conditions—ligation of the main blood supply; multiple circumferential sutures; obliteration of the lesion with the cautery; or injection of thrombosing or scar-forming sclerotics. The only universally suc-

successful method is complete extirpation, since recurrence notoriously follows halfway measures. Moreover, operation should be carried out in the early stages of the development of the lesion. Otherwise the rapidity of its growth and the extent of involvement may place its removal outside the domain of surgery or else require sacrifice of a part, as illustrated in Case 8. Under any circumstances, the operator is confronted with a problem requiring not only meticulous skill and care in its performance, but one demanding the courage to attempt an ordeal which may be fatal because of hemorrhage, or which may require amputation.

III—ANEURYSMS

It is not the purpose of this paper to discuss in detail the diagnosis and treatment of aneurysms or arteriovenous fistulae. Openings in blood vessels produced by small missiles may for a time present no symptoms and no physical signs other than a bruit. For that reason these lesions are frequently overlooked, particularly if more striking or extensive injuries are present. The value of auscultation as a means of determining the presence of these lesions cannot be too strongly stressed. In the inception of any vascular injury, external or internal bleeding may be severe, and the immediate care quite correctly is directed to the control of hemorrhage. On the other hand, bleeding may be slight, even though a major vessel is involved, and in the absence of severe laceration it may be controlled by pressure of the soft tissues and thus a pulsating hematoma or false aneurysm be formed. In the presence of a large number of casualties and under battle conditions, such as front line hospitals are now working, a diagnosis, though incomplete, or even incorrect, may be carried by a wounded soldier for some time. This does not imply that proper treatment has not been given, but it does entail upon those who are working in the Zone of Interior or in general hospitals distant from the battle field the necessity of careful examination uninfluenced by any previous diagnosis. Moreover, it is a well known fact that a vascular lesion may develop slowly to the point of recognition. For example, an arteriovenous fistula present from the onset of an injury may not show characteristic signs until edema and tissue hemorrhage have been absorbed. It is well to remember that blood vessels are usually accompanied by nerves, and that nerve lesions, which are so striking in their immediate manifestations, may mask or cause to be overlooked accompanying blood vessel trauma. Inconspicuous wounds may, likewise, involve blood vessels and are frequently overlooked through failure of the examining surgeon to suspect their presence, or because his attention has been directed elsewhere to a seemingly more important lesion. Aneurysms of various types will be overlooked unless *every* wound is carefully examined, particularly by auscultation.

The differentiation of a false arterial aneurysm and an arteriovenous fistula is of extreme importance since the sequelae, the general and local effects, as well as the treatment of the two conditions, differ greatly. The differential diagnosis is not always easy but as a rule an arteriovenous com-

munication is characterized by a *continuous* thrill and a *continuous* machine-like bruit accentuated in systole, whereas, in the false aneurysm there is a slight but distinct pause between the systolic and diastolic phases, or the bruit may be heard only in systole. In the case of a fistula the swelling is usually less pronounced although some fistulae communicating through a false sac may give rise to a tumor of considerable size.

The dilatation of veins about and distal to a fistula, the slowing of the pulse following its obliteration, and the trophic changes resulting from an impoverished blood supply distal to it are further differentiating points. In large fistulae or in those close to the heart, cardiac dilatation with subsequent failure is likely to follow. While time should be allowed for the development of collateral circulation, operation should not be delayed until cardiac failure has supervened. The enlargement of the heart and its rapid return to normal size following excision of this lesion are strikingly shown in Figures 14 and 16.

Case 9.—*Femoral A-V fistula, resulting from rifle bullet on September 21, 1943. Cardiac enlargement with beginning failure. Excision of fistula. Rapid return of heart to normal size.*

This 21-year-old soldier was struck by a through-and-through rifle bullet in the right thigh September 21, 1943. There was very little bleeding. The wound was dressed shortly afterwards, and healing took place in about ten days. About one month afterwards he noticed fullness and swelling in this region, and about that time the presence of an aneurysm was noted.

He entered Ashford General Hospital February 5, 1944. There was some swelling of the right thigh, particularly on the inner medial aspect. In this region a distinct continuous thrill could be felt. He complained of fullness in the right thigh, swelling of the right lower extremity, pain in the right leg on walking, and dyspnea on exertion. The swelling of his thigh was most marked on the inner and middle aspects. The whole leg was swollen, and there was pitting edema of the right ankle. The veins of this leg were enlarged. A distinct thrill could be felt over the whole inner aspect of the thigh. A bruit, most marked in this region, was transmitted up to the groin and downward to the midleg. It was continuous but accentuated in systole. Obliteration of the femoral artery by pressure reduced the pulse rate from seventy-eight to forty-eight. Roentgenogram of the heart showed left ventricular enlargement (Fig. 14).

On February 9, 1944, quadruple ligation and excision of the fistula were done. The proximal artery was greatly dilated as were all the veins in the region of the fistula. The distal artery was small. Numerous collateral vessels were found in the region of the fistula. All vessels in this region were tied and cut, and the fistula was completely excised (Fig. 15). Postoperative course was uneventful. Roentgenogram of the heart made one week after the operation showed that the heart had returned to normal size (Fig. 14).

Case 10.—*A-V aneurysm, right posterior tibial vessels with communication through interosseous membrane. Ligation of all communicating vessels. Obliteration of fistula by multiple mattress sutures. Recovery.*

This soldier sustained a bullet wound of the right leg on March 31, 1943. The missile entered the posterolateral aspect of the leg five inches below the knee and made its exit on the inner lateral aspect. Bleeding was profuse but was controlled by a pressure bandage. On April 2, 1943, an incision was made on the anterior surface of the leg, and he was told that an artery was ligated. There was a partial paralysis of the peroneal nerve which had largely disappeared by October, 1943. In November, 1943,

the presence of an arteriovenous fistula was noted, presumably of the posterior tibial vessels, and he entered Ashford General Hospital December 1, 1943. Examination on admission was negative except for the right leg. The leg was swollen from the knee downward, and there was pitting edema of the ankle. An expansile pulsation was present in the area just below the popliteal space and in the line of an old incision on the anterior surface between the tibia and fibula six inches below the knee. In both areas there was a continuous thrill and a loud continuous bruit accentuated in systole. The bruit was transmitted over the whole leg, foot, and thigh. Obliteration of the

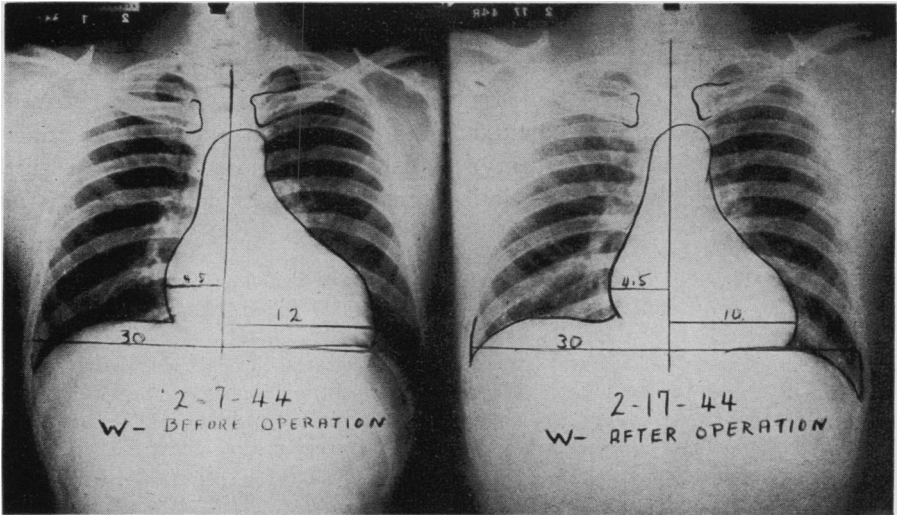


FIG. 14.—Case 9: Showing enlargement of the heart and rapid return to normal following excision of arteriovenous fistula.

popliteal artery by pressure reduced the pulse from 94 to 80. Neurologic examination was negative except for slight weakness of the extensor hallucis longus, the tibialis anticus, and hypesthesia over the lateral aspect of the foot. Oscillations were markedly increased in the whole right lower extremity. Examination of the heart showed moderate left ventricular enlargement (Fig. 16). Operation was performed December 15, 1943. Incision was made in the popliteal space and continued downward to the midcalf. The popliteal artery and vein were identified and temporarily occluded with a ligature. Both vessels were markedly enlarged. Another incision was made over the course of the anterior tibial vessels overlying the interosseous membrane at its upper end, and a large pulsating sac was uncovered in this region which apparently communicated through the membrane with the main sac on the posterior surface of the leg. The posterior incision was then dissected further, and a large sac into which numerous communicating arteries and veins entered was found. All of these vessels were separately ligated and cut, as were the proximal vessels previously identified. In an attempt to remove the sac in its entirety severe bleeding was encountered, evidently arising from other communications. This bleeding could not be controlled by individual ligation of vessels, and the whole sac was, therefore, obliterated and infolded by a number of heavy mattress sutures. This controlled the bleeding and obliterated the bruit and thrill. The wound was closed with silk. The patient's recovery was uneventful, and he returned to duty April 1, 1944. Enlargement of the heart previously noted returned to normal (Fig. 16).

Case 11.—*Left brachial aneurysm following gunshot wound. Paralysis of median, radial, and median cutaneous nerves from pressure. Complete division of ulnar nerve. Excision of aneurysm. Suture of ulnar nerve.*

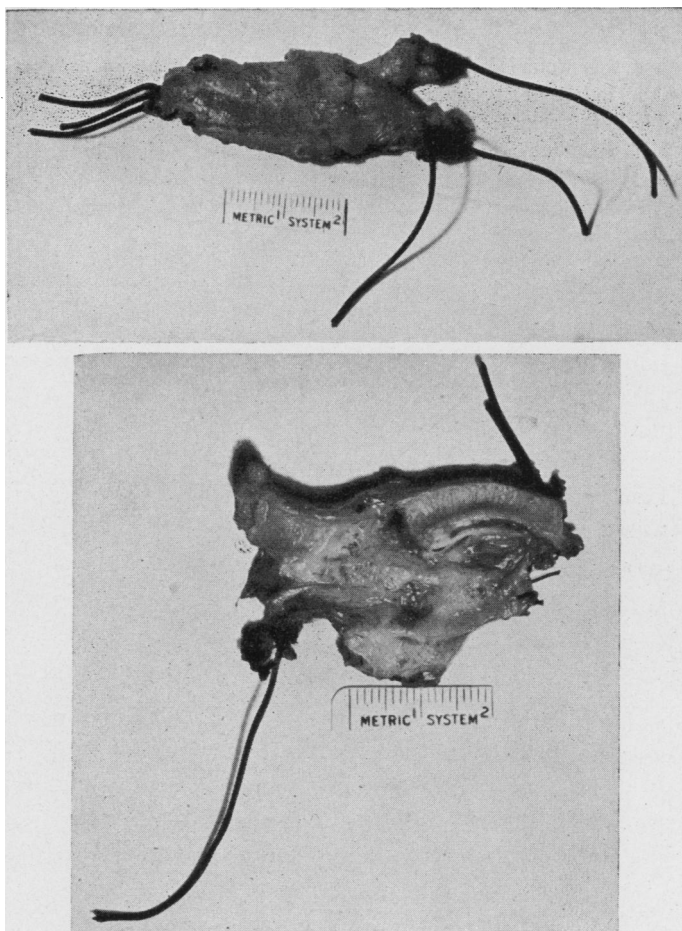


FIG. 15.—Case 9: A. Arteriovenous fistula excised. B. The fistula opened showing the artery (above) communicating with the vein through a common sac.

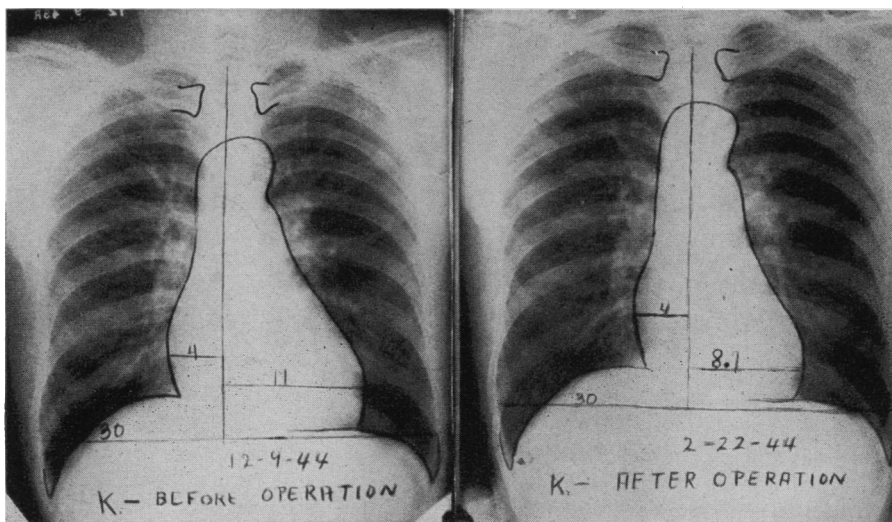


FIG. 16.—Case 10: Showing enlargement of the heart and return to normal size following excision of an arteriovenous aneurysm.

This patient was wounded, November 19, 1943, by fragments of artillery shell. He received wounds in the left shoulder, left arm, and left hand and face. There was considerable bleeding from the wound in the left arm which was situated just below the axilla. He immediately noticed numbness of the hand and inability to use it. He was evacuated from the line of fire, and his wound were débrided and an encasement applied. He was eventually evacuated through hospitals to Ashford General Hospital where he arrived March 9, 1944.

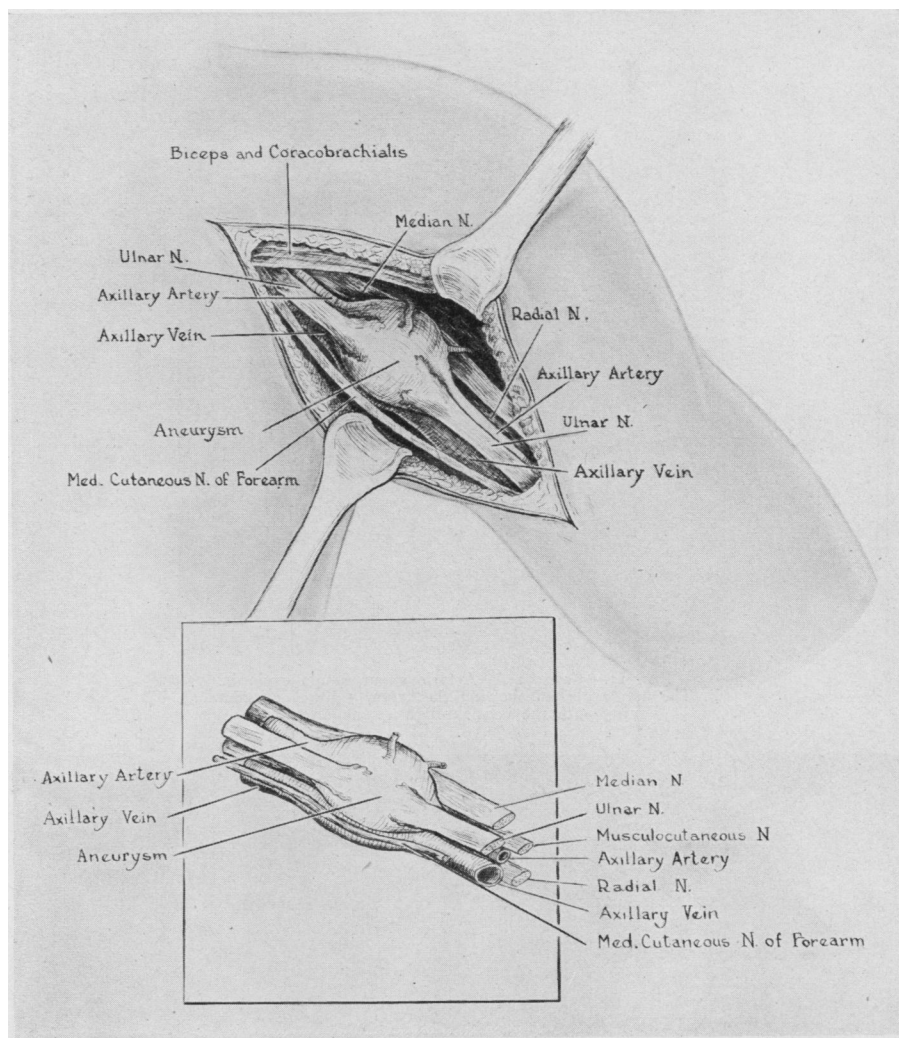


FIG. 17.—Case 11: Showing aneurysm of brachial artery with severance of the ulnar nerve and pressure paralysis of other nerves in this region.

At the time of admission all the wounds were healed. Aside from the left upper extremity, examination was unimportant. In brief, examination showed complete paralysis of the median and ulnar nerves and a partial paralysis of the musculocutaneous and radial nerves. Along the medial aspect of the upper third of the left arm was a scarred wound measuring 8 cm. in length. In the left axilla near the anterior axillary

fold was a pulsating mass 3 cm. in diameter. There was no thrill, but a systolic bruit could be heard over it. The radial pulse was weak.

Operation was performed on March 17, 1944. An incision was made along the anterior border of the axilla, and the pectoralis major muscle was exposed and retracted upward. The vessels and nerves of the arm just below the axilla were exposed, and the proximal and distal brachial arteries connecting with the aneurysm were isolated and temporarily occluded with ligatures. The nerves in this region were firmly adherent to the aneurysm, stretched over it, and subjected to its pulsation. They were dissected

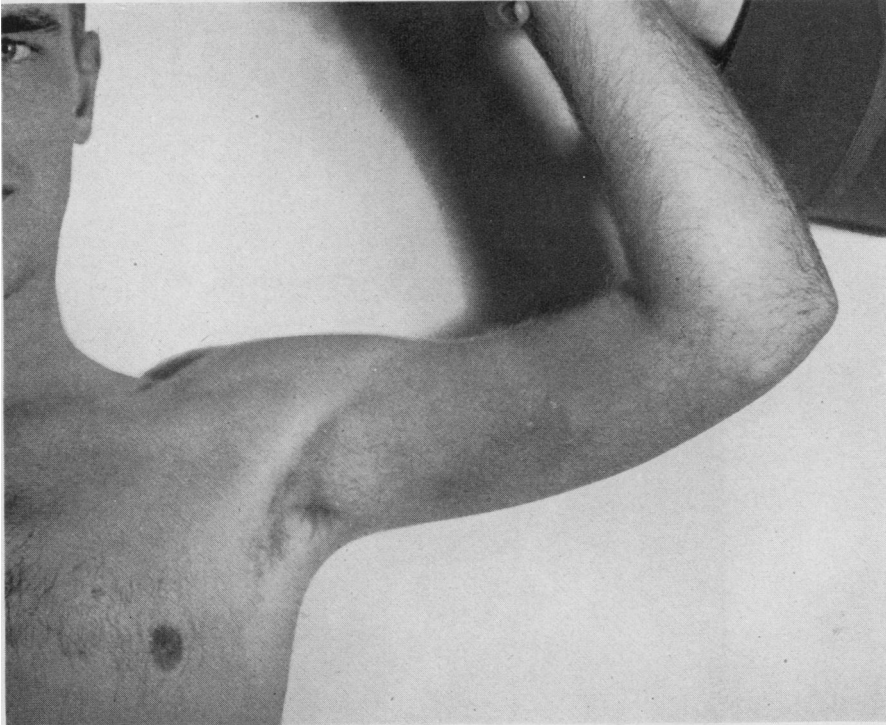


FIG. 18.—Case 12: Arterial aneurysm of axillary artery with paralysis of nerves from pressure.

free from it with considerable difficulty. It was discovered that the ulnar nerve was completely severed at the medial side of the aneurysm and that the hiatus between the severed ends was filled with scar tissue (Fig. 17). After isolation of the ulnar, median, radial, and median cutaneous nerves, the aneurysm was ligated proximally and distally and removed. The ends of the divided ulnar nerve were freshened and sutured with silk and tantalum. (Major George L. Maltby.)

Case 12.—*False aneurysm, axillary artery, following shrapnel wound. Pressure paralysis of medial, radial and ulnar nerves. Excision of aneurysm. Neurolysis. Sensory and motor improvement.*

On September 23, 1943, this officer was struck with multiple shrapnel fragments on the anterior chest wall, left elbow and left axilla. There was immediate loss of motor power of the hand and loss of sensation proximal to the elbow. There was very little bleeding, but there was considerable swelling in the axilla. There was some return of sensation in the hand and arm shortly after the injury. His wounds healed without difficulty.

He entered Ashford General Hospital December 1, 1943. Examination was essentially negative except for the left upper extremity. In the left axilla there was an oval

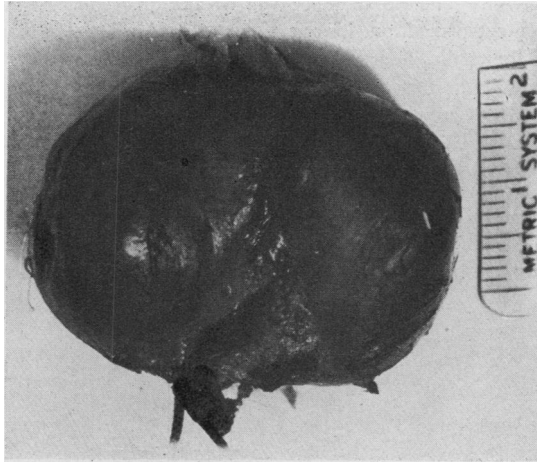


FIG. 19.—Case 12: Appearance of the axillary aneurysm after excision. Note groove made by median nerve.

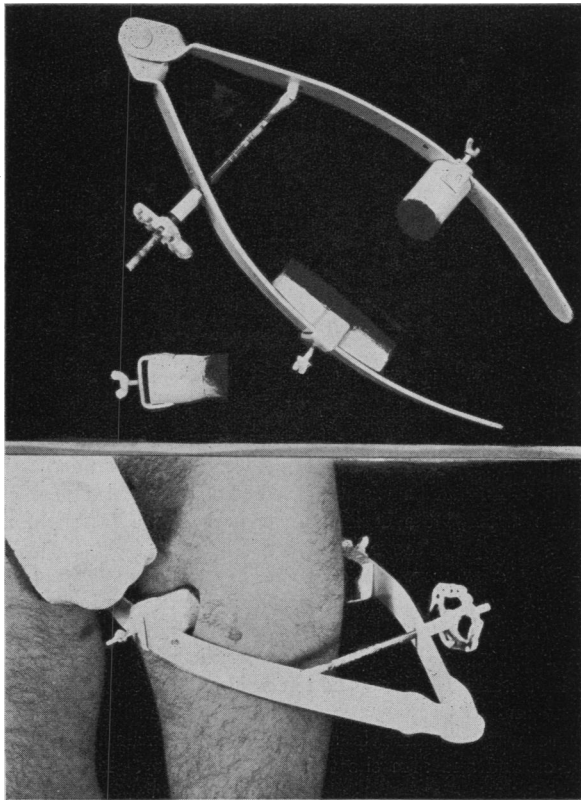


FIG. 20.—A. The Matas compressor. This is an inexpensive and easily constructed instrument.
B. The compressor in place on the femoral artery.

mass, 5 x 3 cm., which pulsated with systole (Fig. 18). There was no thrill, but a harsh systolic bruit could be heard over it. With pressure on the axillary artery above the mass the pulsation and bruit could be partially diminished. Upon tapping the mass paresthesia developed over the entire hand. The radial pulse was weak. There was hypalgesia and scattered areas of anesthesia over the peripheral distribution of the ulnar, median, radial, and medial cutaneous nerves of the forearm. Motor power of the muscles of the hand and arm was weak, and there was considerable stiffness of the joints. It was apparent that the axillary artery had been injured and was the seat of aneurysm. Neurologic examination indicated multiple nerve injuries, but of a type suggesting pressure rather than actual severance.

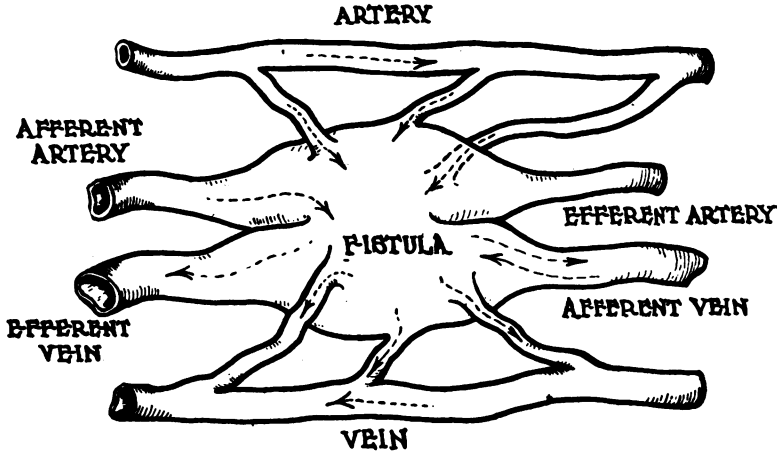


FIG. 21.—Schematic drawing to show communications of arteriovenous fistula and necessity of not only quadruple ligation but complete excision with all branches.

Operation was performed December 14, 1943. An incision was made along the anterior border of the axilla and extended down the arm about three inches. The axillary fascia was opened, and the axillary artery exposed above and below the aneurysm, and temporary ligatures were placed about the vessel. The median nerve ran directly over the aneurysm and grooved it (Fig. 19). Except for flattening and some fibrosis the nerve was normal. The ulnar nerve was adherent to the aneurysm on its medial surface and the radial nerve posteriorly. These nerves were freed from the aneurysm which was then ligated both proximally and distally and removed. Patient returned to duty as a staff officer six weeks later, and he reports that there has been a gradual improvement in the motor and sensory function of the arm and hand.

DISCUSSION.—Certain basic principles must be observed in the treatment of these conditions. Such a lesion is never a matter of emergency unless it is rapidly progressing in size, or has ruptured, or unless heart failure is impending. Time should be allowed for the development of collateral circulation about an arteriovenous fistula, usually a matter of three or four months. In an arterial aneurysm the use of artificial means to develop collaterals, usually proximal compression of vessels either manually or with the compressor devised by Matas, should be employed (Fig. 20). Where nerve lesions accompany aneurysms, complete excision of the lesion, together with neurolysis and nerve suture, should be carried out in a single operative procedure. Where *large* arterial aneurysms exist without accompanying

nerve damage the obliterative endo-aneurysmorrhaphy of Matas is the operation of choice. This type, however, is usually the result of arteriosclerosis or syphilis, and is, therefore, less often encountered in young soldiers.

The effect on the heart, the general circulation, and the part affected, demand that arteriovenous fistulae be completely eliminated. The manner of its obliteration is of importance because if the operation is incompletely performed recurrence is apt to take place. On theoretic grounds it would seem best to repair the opening in both artery and vein, but this is technically difficult and may result in secondary hemorrhage, thrombosis, or recurrence. Since collateral circulation is usually abundant, complete excision with ligation of all communicating vessels is the method of choice. Ligation without excision usually results in the recurrence since the fistula will be established rapidly through collaterals (Fig. 21). If excision is impossible because of the anatomical location as in Case 10, or because of uncontrollable hemorrhage, recourse may be made to infolding the fistula with heavy mattress sutures. The operation should be carried out with the greatest care because of the number of vessels involved and because their thinness and friability may lead to uncontrollable hemorrhage. The operation is best performed without the use of a tourniquet since individual blood vessels can be better isolated and complete excision more thoroughly accomplished. Moreover, since the operation is frequently a prolonged one a tourniquet would have to be released during the course of the procedure. Continuous spinal anesthesia has been generally employed in operations upon the lower extremity, or intravenous sodium pentothal or ether in procedures in other locations.

SUMMARY

Illustrative cases are presented showing three main types of arterial injury, namely:

1. Arterial occlusion from severance of vasospasm.
2. Blood vessel tumors and injuries activated by trauma.
3. Aneurysms and arteriovenous fistulae.

Diagnosis and treatment of these conditions are discussed.

Illustrative drawings were made by Captain J. W. Kahn, M.C., and Corporal Vincent Destro. Photography was done by Captain Floyd B. Hall, M.A.C.

REFERENCES

- ¹ Griffiths, D.Le.: Volkmann's Ischaemic Contracture. Hunterian Lecture to the Royal College of Surgeons of England, February 2, 1940.
- ² DeBakey, Michael E.: Traumatic Vasospasm. The Bulletin of the U. S. Army Med. Dept., No. 73, 1944.
- ³ Elkin, Daniel C.: Cirroid Aneurism of the Scalp. ANNALS OF SURGERY, **80**, 332, 1924.
- ⁴ Reid, Mont R.: Studies on Abnormal Arteriovenous Communications, Acquired and Congenital. Arch. Surg., **10**, 601, 1925.
- ⁵ Pemberton, John J., and Saint, James H.: Congenital Arteriovenous Communications. Surg., Gynec. & Obst., **46**, 470, 1928.