

ANNALS OF SURGERY

VOL. 122

OCTOBER, 1945

No. 4



A request to Director Byrnes that the American Surgical Association be allowed to hold its meeting in May was politely but firmly refused. The Council has decided that the papers prepared for this meeting be published as a unit, without discussion, as proceedings of the Association.

*William Darrach
President*

THE PROBLEM OF PORTAL HYPERTENSION IN RELATION TO THE HEPATOSPLENOPATHIES*

ALLEN O. WHIPPLE, M.D.

NEW YORK, N. Y.

FROM THE DEPARTMENT OF SURGERY, COLUMBIA-PRESBYTERIAN MEDICAL CENTER, NEW YORK, N. Y.

IT MAY BE PERTINENT, in introducing the topic of this discussion, to say a few words about our interest and experience in the study of portal hypertension. Some 17 years ago, when the College of Physicians and Surgeons of Columbia University and the Presbyterian Hospital moved to their new common site, a group of physicians, surgeons and pathologists organized one of the several combined clinics. This soon acquired the name of the Spleen Clinic. Its purpose is to study patients with splenopathies before, during and after whatever treatment is decided upon by agreement of the group. The essential feature of this combined clinic is the laboratory, where all the blood studies and other tests are done by the same expert technicians on the patients, whether as out-patients, in-patients, or in follow-up visits. These patients are referred to the Spleen Clinic from the Vanderbilt Clinic, the Out-patient Department of the Columbia-Presbyterian Medical Center, and by other physicians; and after study and treatment they are returned to the referring physician with the request to have the patients return to the Spleen Clinic for indefinite follow-up studies¹ (Fig. 1).

As a result, there have been studied not only patients with splenopathies but many with disorders of the hematopoietic system and combined diseases of the liver and spleen. Table I is a summary of the splenopathies and the hepatosplenopathies that have been studied and followed in this Clinic to March 15, 1945.

No one can work for any length of time in a clinic of this kind, with

* The E. Starr Judd Lecture. Read at The Medical School, University of Minnesota, April 10, 1945.

This paper was to have been presented before the Annual Meeting of the American Surgical Association, May, 1945.

physicians, surgeons and pathologists having a common purpose, without acquiring valuable experience and developing an interest in the diagnosis, treatment and end-results of these lesions. A common language is spoken and there are no miracles among friends. Again, I would emphasize the importance of having the accurate hematologic and other laboratory studies done by the same group of experts throughout the study of these patients, before, during and after treatment.

THE PORTAL SYSTEM

There are many marked differences between the portal and systemic venous systems, both anatomically and physiologically. The portal venous

ORGANIZATION SPLEEN CLINIC
COLUMBIA-PRESBYTERIAN MEDICAL CENTER N.Y.C.

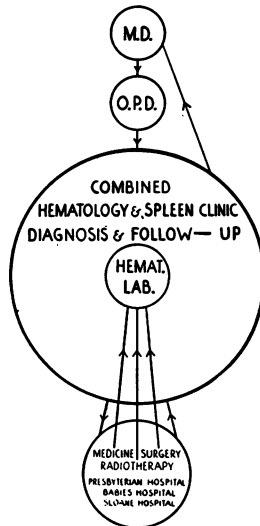


FIG. 1

system is interposed between two capillary beds. It drains the capillaries of the gastro-intestinal tract, the pancreas and the gallbladder, and the venous sinuses of the spleen; and empties into the capillary network, or sinusoids, of the liver. It has no valves. The portal vein carries about 75 per cent of the blood emptying into the liver. In this blood it carries nutrient material from the gastro-intestinal tract, and insulin from the pancreas, to be altered, detoxified and utilized by the liver, but it carries very little oxygen. For this the liver is dependent upon the hepatic artery which conveys the remaining 25 per cent of the blood entering the liver.

To understand the pathogenesis, the pathology, the diagnosis and the treatment of portal hypertension it is essential to review certain points in the anatomy and physiology of the circulation of the liver and the spleen. Unfortunately, there is still considerable controversy regarding some of these points; an endeavor is made to present as much of the new and accepted data as possible.

THE LIVER LOBULE IN RELATION
TO THE PORTAL AND HEPATIC CIRCULATION

The mammalian liver is made up of small polygonal masses, each of which represents the architectural unit, or lobule, 0.7 to 2 mm. in diameter. In some mammals, as the pig, each lobule is completely surrounded by a layer of connective tissue, but in man these connective tissue partitions are poorly developed, resulting in less well-defined lobules. Furthermore, the liver lobule is determined by the arrangement of the blood vessels rather than by the duct system. The lobule is a polygonal prism, with five, six or seven sides, with the vertical diameter several times greater than the transverse. Running through the center of the lobule, in its long axis, is the central vein, while at the periphery are the branches of the portal vein with a lymphatic network, the branches of the hepatic artery and the interlobular bile ducts. The latter structures are enclosed in the connective tissue of Glisson's capsule.

Separating the central vein and the vessels in Glisson's capsule are the hepatic cells, arranged in cords with the sinusoids or capillaries running between the cords of cells and connecting the portal vein radicals and hepatic arterial terminals with the central vein. These central veins unite as intercalated veins to empty into collecting veins which, in turn, end in the hepatic veins to join the vena cava (Fig. 2).

THE RELATIONS OF THE BLOOD FLOW OF
THE HEPATIC ARTERY AND THE PORTAL VEIN

One of the earliest and most significant studies on these two circulations was made by Gad² in 1873, who wrote a dissertation based on experimental work, in which he concluded that the arterial circulation in the liver performed the dual function of bringing oxygenated blood to the liver and of mechanically controlling the portal flow. He also suggested an aspirating action of the arterial on the portal current as the former passed by the openings of the latter, joining with them at an acute angle. He demonstrated that a current through the arteries with increased pressure retarded the portal flow.

In 1907, Herrick³ published his studies on the causes of increased portal pressure in portal cirrhosis. He perfused normal livers and cirrhotic livers through the hepatic artery and the portal vein, noting the effect of the volume flow, one on the other, at increasing pressures. He pointed out that in the normal liver there is:

1. In the portal vein a large volume circulation with a low pressure.
2. In the hepatic artery a small volume circulation with a high pressure.
3. A common channel of exit, the hepatic vein, for fluid entering by these two circulations.
4. A freely expansible tissue framework.
5. Two methods by which the entering circulations may influence each other, *i.e.*, by direct communication or by lateral pressure.
6. A vasomotor mechanism to both sets of vessels.

7. An equalization of these pressures at the junction of the interlobular and intralobular venules of the liver lobules which takes place through the communications between the veins coming from the capillaries, bringing arterial blood and the portal venues.

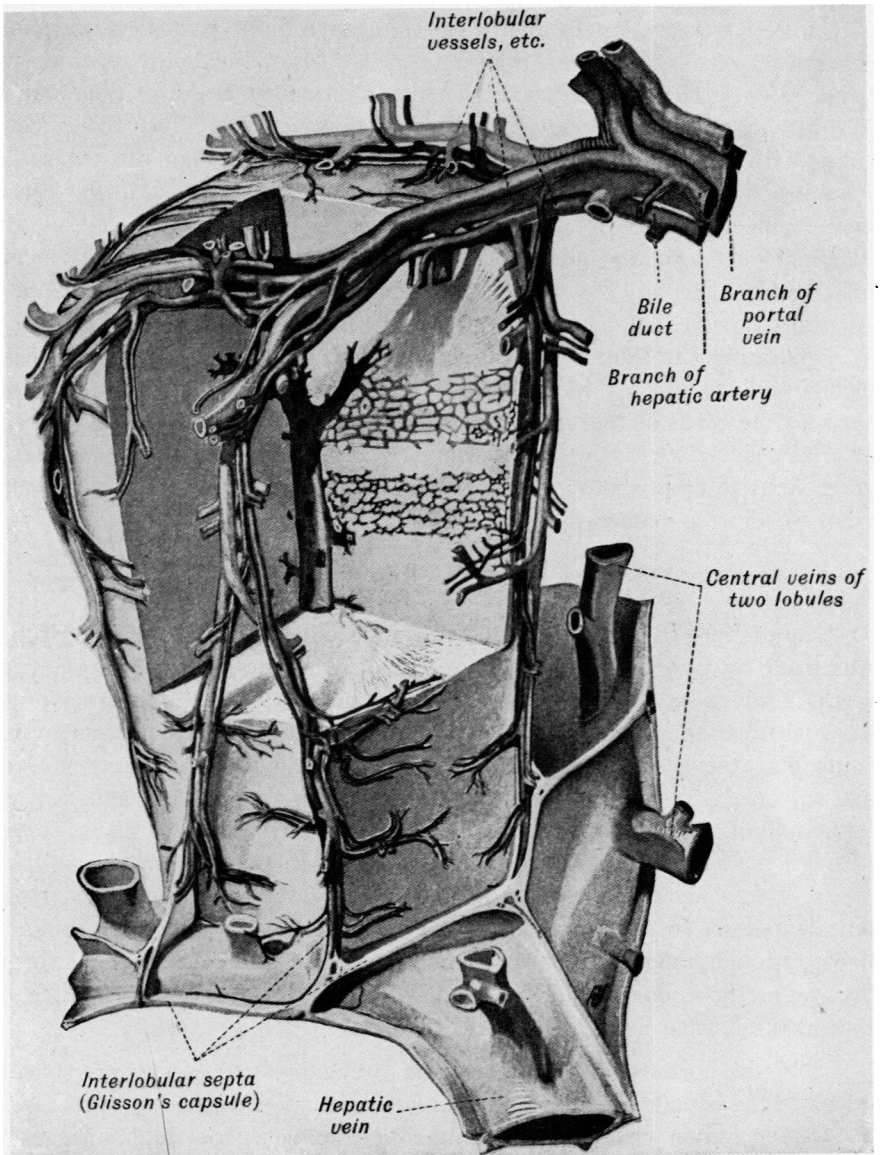


FIG. 2.—Lobule of the liver of a pig. Wax reconstruction by Vierling. A portion of the lobule is cut away to show the bile capillaries and sinusoids. $\times 400$. After Braus. (From Maximow's "Textbook of Histology," 4th edition. Philadelphia, W. B. Saunders Co.)

In the normal liver Herrick found that the rise in portal pressure was 1 mm. for every 40 mm. of arterial pressure; whereas in the cirrhotic liver it was 1 mm. for every 6 mm. of arterial pressure. It was found that arterial

rise in pressure did not affect the portal pressure in normal livers until it had passed the 100 mm. mark. In cirrhotic livers the effect on the portal pressure was evident at 30 mm. of arterial pressure.

McIndoe,¹⁵ in his studies of the vascular bed of cirrhotic livers, found that a large part of the fluid perfused through the portal vein escaped through the collaterals, and that 13 per cent was the largest amount recovered from the hepatic vein, as compared to 100 per cent in the normal liver. On the other hand, he found that a much greater proportion of fluid, perfused through the hepatic artery, in a cirrhotic liver, passes out through the hepatic vein. He was unable to duplicate Herrick's observations that the high pressure in the hepatic artery was responsible for increasing the portal pressure.

In advanced cases of portal cirrhosis with the portal blood passing through established collaterals the shunt is able to carry a certain load, but with increased portal pressure rupture of the collaterals may take place. In such cases the hepatic artery is conveying most of the portal blood to the parenchyma of the liver.

As the combination of increasing interlobular fibrosis with degeneration and regeneration of liver cells slowly progresses, there is a gradual shutting off of portal blood from the hepatic cells. When the fibrosis increases to the point of shutting off the arterial supply parenchymal insufficiency develops. McIndoe points out that the duration of the period from the time of complete diversion of portal blood into collateral channels to the obliteration of the persisting arterial supply to the remaining liver cells is longer or shorter according to the rate of sclerosis of the intrahepatic vascular bed and the varying degree of involvement of the two circuits. This explains the variable periods of hemorrhage and of survival in cirrhotic patients.

McIndoe's analysis of the obstructive factor in cirrhotic livers questions the conclusions of Herrick in his perfusion experiments and throws new light on the rôle of the collateral channels in intrahepatic portal bed block. This is an important field for further investigation with new methods of study in the living animal with experimentally produced cirrhosis.

THE VASCULAR BED OF THE SPLEEN

The following discussion is abstracted from studies made in our laboratory^{4, 5}:

Following Malpighi's⁶ classic description of the anatomy of the mammalian spleen, in 1666, there has been a recurrent controversy among anatomists regarding the histology of the vascular bed of that organ. Proponents of an open circulation claimed that there was no continuity between the terminal arterioles and the venous sinuses, but that the splenic pulp spaces provide the only link between the arterial and venous radicals. Equally emphatic in their opposing claims have been those who maintained that the arterioles emptied directly into the venous sinuses and that the vascular bed was a closed system. Modern opinion rather favors a combined type of circulation

in the mammalian spleen, that is, an open component in the vascular bed which permits the flooding of the splenic pulp spaces with whole blood but with additional pathways available, by means of which the extravascular detour of the pulp spaces may be short-circuited by direct communications between the arterioles and the venous sinuses. Whether these arteriovenous connections of which it is composed are structurally intact vascular tubes or whether their appearance may be accounted for on a purely functional basis, such as an alteration in the porosity of the pulp caused by contraction of the splenic musculature, is considered to be an open question.

The reasons for this three-sided debate have been the difficulty of interpreting the intricate patterns of the spleen as seen in microscopic sections stained by different methods, and the varying results obtained by the several technics of injecting the vascular bed of the spleen both by artery and by vein.

In 1931, McNee⁷ reported that "in the direct observations of the thin edge of a mouse's spleen, examined with a dissecting microscope and very powerful light, erythrocytes could be seen lying stationary in the pulp while blood was pumping freely through the adjacent arterioles into sinuses and then emerging by the veins." No one made use of this valuable suggestion in method until Knisely,⁸ in 1934 and 1936, working in the Hull Laboratory, in the University of Chicago, published his studies on transilluminated living spleens. He described the finest structural and functional details of the vascular bed; and his account of them was expressed in no uncertain terms. His conclusion that the "unstimulated splenic vascular system of mice, rats and cats consists of a system of preformed, interconnected lined channels," normally intact and permitting the egress of only the fluid content of the blood, presented the most convincing argument in favor of the hypothesis of the closed circulatory mechanism in the spleen. He maintained that trauma incidental to manipulation, injection and fixation of the spleen had been responsible for the antagonistic studies of histologists in this field.

Knisely's positive description of the visualized functioning circulation in the spleen and his graphic schematic drawings of the venous sinuses in what he termed the three phases of filling, concentrating and emptying of red blood cells, with sphincters at the entrance and exit of the sinuses, were so convincing that several writers on the subject of splenic circulation have recently accepted his claims without question. Von Herrath,⁹ in his paper published in 1938, speaks of the "hematocrit function" of the venous sinuses as demonstrated by Knisely. But no one, until we began this study, had repeated Knisely's observations or corroborated or questioned his conclusions.

Because many of the problems in the pathology and clinical manifestations of the splenopathies depend upon a knowledge of the exact mechanism of the circulation in the spleen, the members of the Spleen Clinic at the Columbia-Presbyterian Medical Center were especially interested in Knisely's papers.⁸ We visited the Hull Laboratory on two occasions and later sent one of our Surgical Residents, Dr. David W. MacKenzie, Jr., for a period of

four months to study with Dr. Knisely. He most kindly gave Dr. MacKenzie every opportunity, and on his return to our laboratory the apparatus and method were set-up for studying the transilluminated spleen.

Before studying abnormal spleens it was essential for us to become thoroughly familiar with the circulation in the normal spleen. It had become apparent to Doctor MacKenzie that two fundamental faults in Knisely's technic made a continuous uninterrupted study of vascular fields impossible: The first, and most misleading, was the constantly moving visual field caused by the respiratory movements transmitted to the spleen under the microscope;

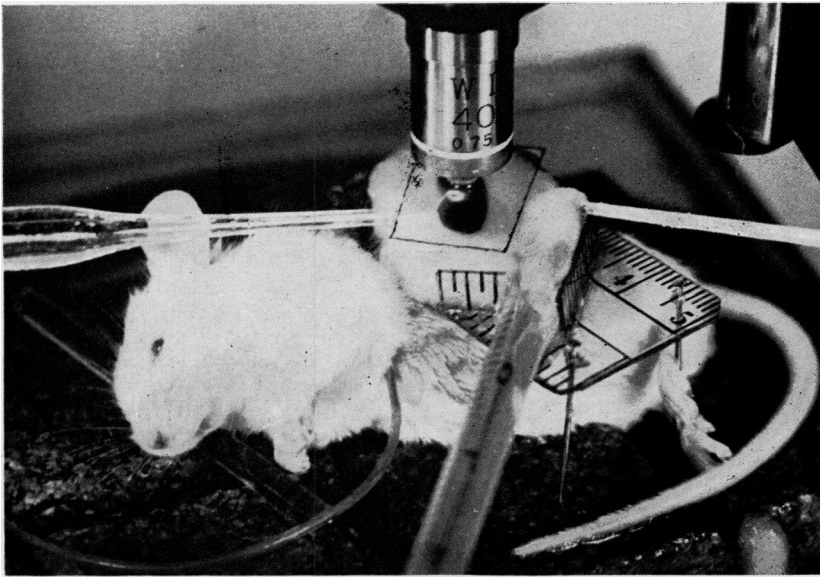


FIG. 3.—Transillumination apparatus arranged for observation of an exteriorized mouse spleen.

Hollow-tipped, fused quartz, illuminating rod enters chamber from left; immersion fluid delivery tube from right; and thermometer from foreground. Anesthesia fluid is being conveyed to this animal's left pectoral region. Lift from illuminator tip is directed upward, through spleen substance, into water-immersion objective.

(From MacKenzie, D. W., Jr., Whipple, A. O. and Wintersteiner, M. P.: Studies on the Microscopic Anatomy and Physiology of Living Transilluminated Mammalian Spleens. *Amer. Jr. Anat.*, v. 68, No. 3, May, 1941.)

and the second was the frequent displacement of the spleen with the movements of the animal when the sodium amytal anesthesia was repeated by hypodermic injection. By devising a celluloid supporting table for the spleen and by using a continuous clysis of sodium amytal solution these two causes of a shifting microscopic field were eliminated, and it became possible, for the first time, to observe areas of the vascular bed in the immobilized organ without any shift in the visual field over uninterrupted periods of several hours. Before this was done, the necessity of filling in gaps between the views of the vascular bed we feel was the cause of fundamentally wrong observations and conclusions (Fig. 3).

We regret, therefore, that we were unable to corroborate many of Knisely's findings and were compelled, as a result of a year of study, to differ

positively from him in his conclusions that the circulation is a closed circulation and in the three phasic functions he attributes to the venous sinuses. Our observations were made by at least three, and sometimes more, members of the Spleen Clinic and the anatomic components or structures of the vascular bed have been recorded by camera lucida drawings of the functioning fields studied by us over periods of one or more hours in the living transilluminated spleen of mice, rats, kittens and guinea-pigs.

I wish to say that by far the major part of this study of the vascular bed of the spleen, the improved method and technics, the continuous observations and the drawings, both free hand and camera lucida, were made by Doctor MacKenzie and by his able assistant, Mrs. Wintersteiner. The detailed report of this study by MacKenzie, Whipple and Wintersteiner⁴ appeared in the *American Journal of Anatomy*, **68**, No. 3, 397-454, 1941.

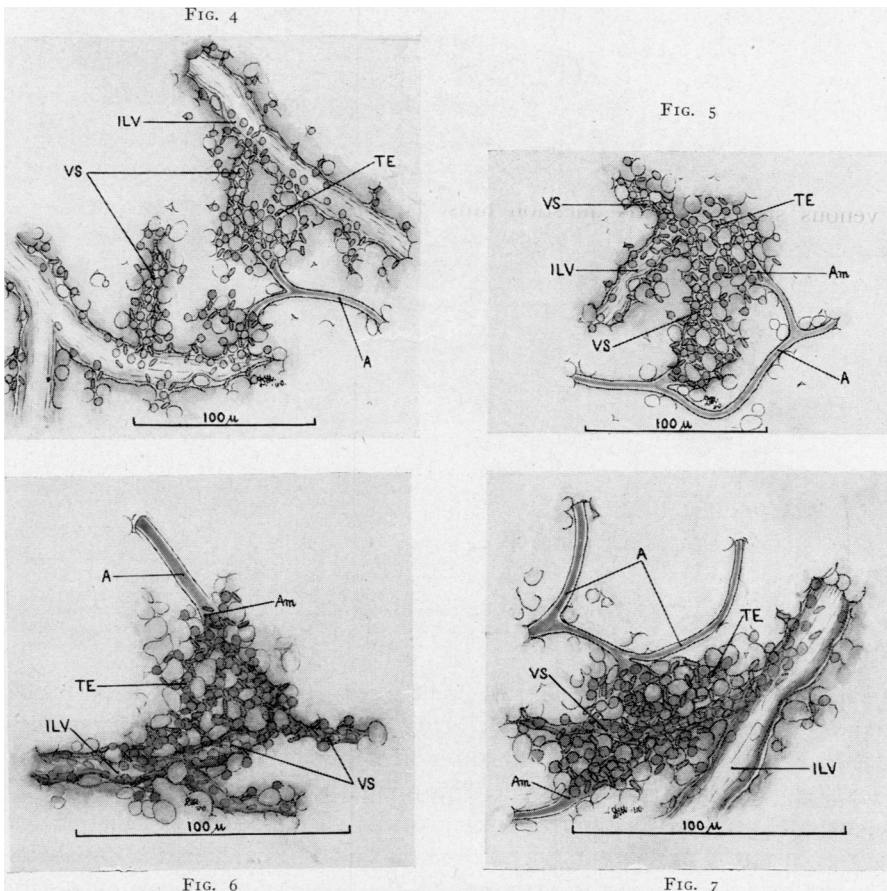
The storm center in the controversy over open or closed circulation in the spleen has had to do with the question as to whether the arterial capillary terminates freely in the reticular meshes of the pulp spaces or directly into the venous sinuses. This question must be answered positively if certain essential points regarding the pathogenesis of many of the splenopathies are to be settled.

It is our definite conviction from our studies in the living spleen, which are in agreement with the conclusions of Mall,¹⁰ Robinson,¹¹ Foot,¹² and Klemperer,¹³ among others, from injected spleens and from microscopic sections, that the splenic pulp spaces provide the one and only link between the arterial and venous systems in the mammalian spleen. Individual pulp spaces are the most variable structures that we have observed in the spleen. For the most part they are tortuous, utterly irregular and inconstant channels, lined by fixed and wandering cells and by reticulum. They constitute a plexiform, three dimensional system of channels intimately connected with one another by actual or potential passages, fully adequate to transmit the cells as well as the fluid of the blood. The average width of the pulp spaces in the normal relaxed spleen of the mouse is six microns, but the diameter of a dilated pulp space has been measured to 16 microns. A collapsed or compressed space may have no visible lumen. On the arterial side of this fibrocellular sponge the pulp spaces communicate with the arterial capillary ampullae, or ampullae of Thoma. On the venous side, the spaces converge upon the stigmata, or free openings, of the venous sinuses and intralobular veins. Camera lucida drawings of this intermediary zone and of the pulp connections with arterial and venous systems are shown in Figures 4-7, and are in agreement with the semidiagrammatic drawing of the intermediary circulation in the human spleen (Fig. 8), as represented by Klemperer.¹³

Bear in mind this anatomy of the intermediary circulation in considering the pathology of chronic portal bed obstruction. The most characteristic feature in the microscopic sections of these splenomegalies is the widening and distention of the venous sinuses with a widening of the stomata resulting in a compression of the splenic pulp spaces. In addition, there is an hyperplasia

of the cytoplasmic reticulum. The back pressure in the venous sinuses, transmitted by the hypertension in the veins, causes the distention of the venous sinuses and the narrowing of the pulp spaces. This makes it more difficult for the blood to pass from the arterial capillaries into the pulp spaces. This results in hemorrhages about the trabecular arteries and at the periphery of the follicles, with a later development of nodular areas of fibrosis—the typical fibro-adenia described by Banti.

This partial exclusion of the splenic pulp from active circulation results in a gradual atrophy of the reticulum with connective tissue replacement and a fibrous spleen.



FIGS. 4-7.—Intermediary circulation in transilluminated mouse spleens. Arterial capillaries, A, are shown to communicate via ampullary dilatations, Am, with swamp-like pulp zones, through which erythrocytes trickle onward, TE, into venous sinuses, VS, and intralobular veins, ILV.

Camera-lucida drawings. Lens magnification of Figures 4 and 5, 400; of Figures 6 and 7, 600. (From MacKenzie, D. W., Jr., Whipple, A. O. and Wintersteiner, M. P.: Studies on the Microscopic Anatomy and Physiology of Living Transilluminated Mammalian Spleens. *Amer. Jr. Anat.* v. 68, No. 3, May, 1941.)

OBSTRUCTIVE FACTORS

The amount of portal bed obstruction, the type and the site of obstruction, are all variable factors in individual patients with portal hypertension.

It is the discovery in the individual patient of these factors and their analysis that very largely determines the diagnosis, treatment and prognosis.

These patients with portal hypertension may be divided into two main groups: Group I. those having intrahepatic portal block; and Group II. those having extrahepatic portal block.

In the first group the cirrhososes, especially of the portal or Laennec type;

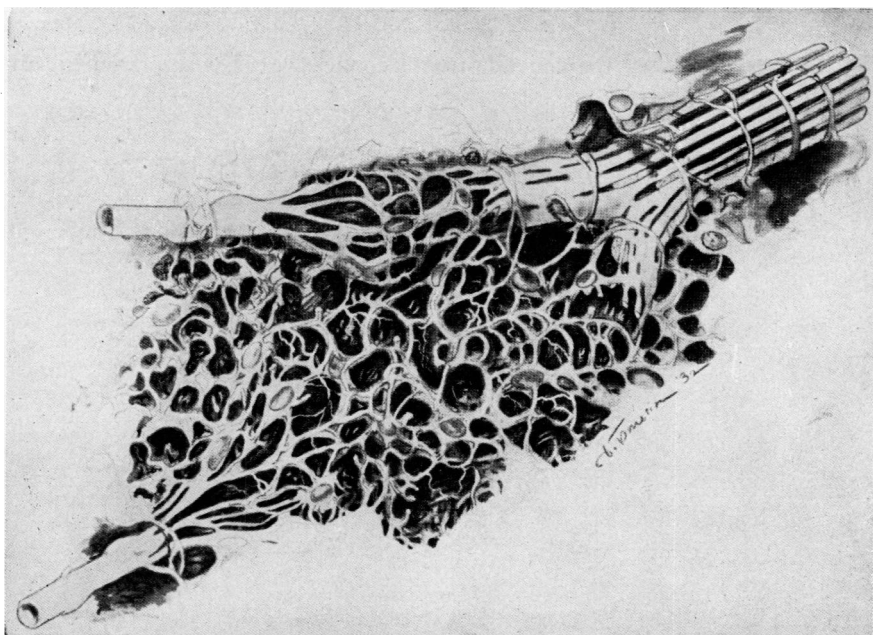


FIG. 8.—Semidiagrammatic drawing of intermediary circulation of human spleen.

This drawing represents author's concept of architecture of reticulum and its relation to finest blood channels. Although it is not an actual reconstruction of serial sections, all structural details which are depicted in three dimensions have been observed histologically. For technical reasons, reticular fibers have not been drawn in different color but as ridges upon cytoplasmic syncytium.

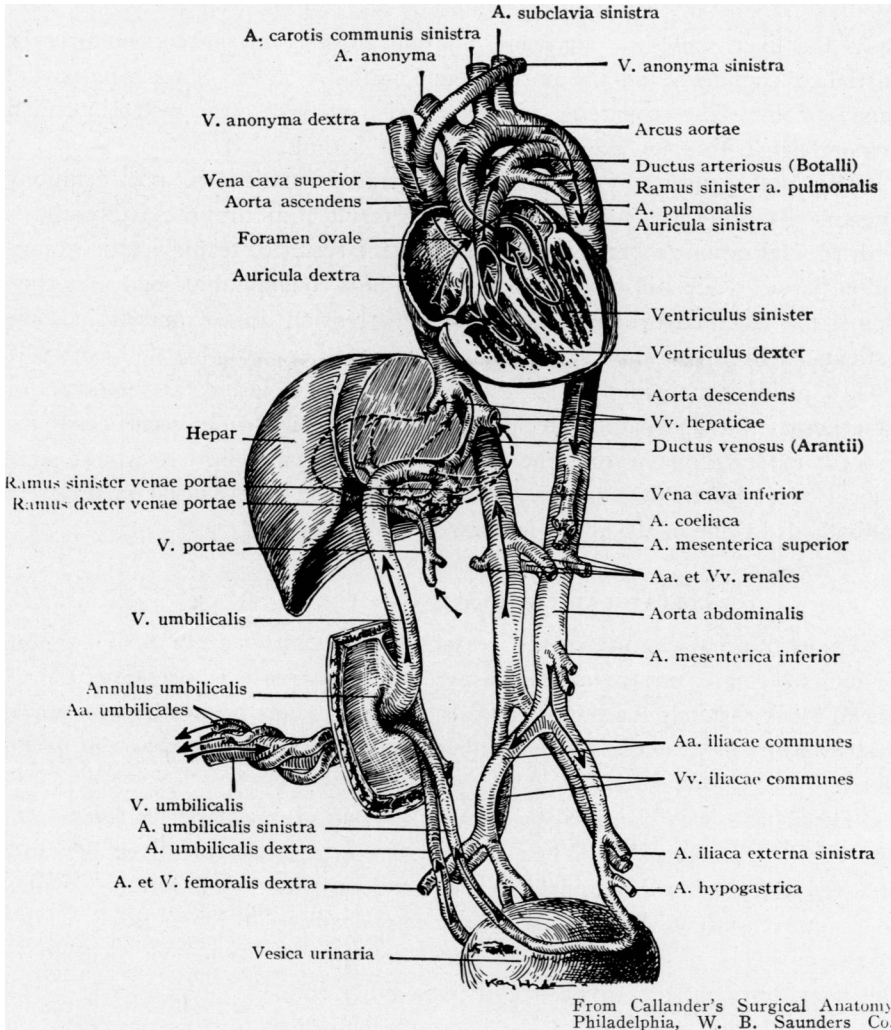
(From Klemperer, P.: Chapter on the spleen in Downey's "Handbook of Hematology." Paul B. Hoeber, New York, 1938, p. 1633. This figure is reproduced by kind permission of the publisher, Mr. Paul B. Hoeber.)

are associated with portal block. As pointed out by Herrick³ in his perfusion studies, there is a great difference between the ratios of the increase in portal vein and hepatic artery pressures of normal and cirrhotic livers, *i.e.*, 1 mm./40 mm., and 1 mm./6 mm. This mutual influence between the portal and arterial pressures within the liver provides an important explanation for the rise of portal pressure in portal cirrhosis and also explains the variability of portal hypertension in the cirrhososes and the presence or absence of gastrointestinal hemorrhage, as a measure of portal hypertension.

The degree of portal hypertension varies in the different types of cirrhosis and in the patients with the same type of cirrhosis and varies in the same individual with cirrhosis at different times. Thus, we find some patients with portal cirrhosis without a history of gastro-intestinal hemorrhage and with no splenomegaly, others have repeated hematemeses and enlarged spleens with marked engorgement of collateral veins.

PORTAL HYPERTENSION

Group II. *Extrahepatic Portal Block.*—There are two types of obstruction seen in chronic occlusion of the portal vein and its main tributaries. The first is a replacement of the vein or its main tributaries with fibrous tissue or scar tissue with little or no canalization. The second is a transformation of the portal vein or its main tributaries or the enveloping tissue into a



From Callander's Surgical Anatomy Philadelphia, W. B. Saunders Co.

FIG. 9.—Diagram of the fetal circulation about the time of birth.

cavernomatous mass of small tortuous vessels, a process spoken of as cavernomatous transformation of the portal vein.

In the first type of fibrous replacement there are two causative factors. The most common is an organization into scar tissue of a thrombosis of the portal vein or of a main tributary. The thrombosis may be the result of inflammation, trauma, or pressure from without by inflammatory or

neoplastic tissue. The second causative factor is an extension into the left portal vein or proximal to it into the main portal vein of the obliterative fibrotic process that takes place at birth in the umbilical vein and ductus venosus as they empty into the left portal vein (Fig. 9). This type of obstruction is fortunately rare but is seen in young children that begin at an early age to show portal block with splenomegaly and a Banti syndrome. In these cases the liver shows no cirrhosis, but the portal vein obstruction may be partial or complete, and the portal vein may show either fibrosis or partial canalization. The collateral circulation is marked and gastro-intestinal hemorrhage with splenomegaly is a common finding.

The pathogenesis of cavernomatous transformation is not definitely known. By some it is considered to be the result of an organized thrombosis with recanalization; others consider it to be the result of telangiectatic granulation tissue; while still others consider it to be a congenital anomaly (against this is the fact that evidences of portal hypertension do not appear in some patients with this lesion until adult life). Other pathologists, especially Pick,¹⁴ argue convincingly that this is a neoplastic lesion, an angioma or cavernoma of the hepatoduodenal ligament, inasmuch as in some cases the process extends far beyond the limits of the portal vein. It would seem logical that the etiology of this lesion is a variable one, caused in different individuals by one of the above factors.

COLLATERAL CIRCULATION IN PORTAL BLOCK

Under normal conditions the portal pressure varies from 8 to 13 mm. of mercury, or 60 to 104 mm. of water. With increase in pressure, and as portal block distends the portal radicals, potential veins connecting the portal system with the systemic begin to appear and enlarge to by-pass the portal blood.

These have been classified by Pick¹⁴ into two groups—the “*hepatopetale*” and the “*hepatofugale*”. When the circulation through the liver is unobstructed and the block is limited to the portal vein the blood may be shunted to a limited extent through the *hepatopetale* collateral veins, the so-called accessory veins of Sappey, which pass through the peritoneal covering of the liver, or from the stomach and pass either into the stem of the portal vein or into the substance of the liver, the so-called deep cystic veins, the epiploic veins of the gastrohepatic omentum, the hepatocolic and the hepatorenal veins, the diaphragmatic veins and the veins of the suspensory ligament of the liver.

In lesions causing intrahepatic block the “*hepatofugale*” circulation shunts a variable amount of the blood from the gastro-intestinal tract and spleen around the liver. McIndoe¹⁵ has classified the various parts of the “*hepatofugale*” collateral circulation into three groups on an embryologic basis:

A. The veins located at the two sites of the gastro-intestinal tract where glandular epithelium unites with squamous epithelium, *i.e.*, at the cardia and at the anus. The veins at the cardia provide an outlet to the superior cava by way of the esophageal veins to the azygos system. The veins at the anus furnish an outlet to the inferior cava by way of the middle hemorrhoidal veins.

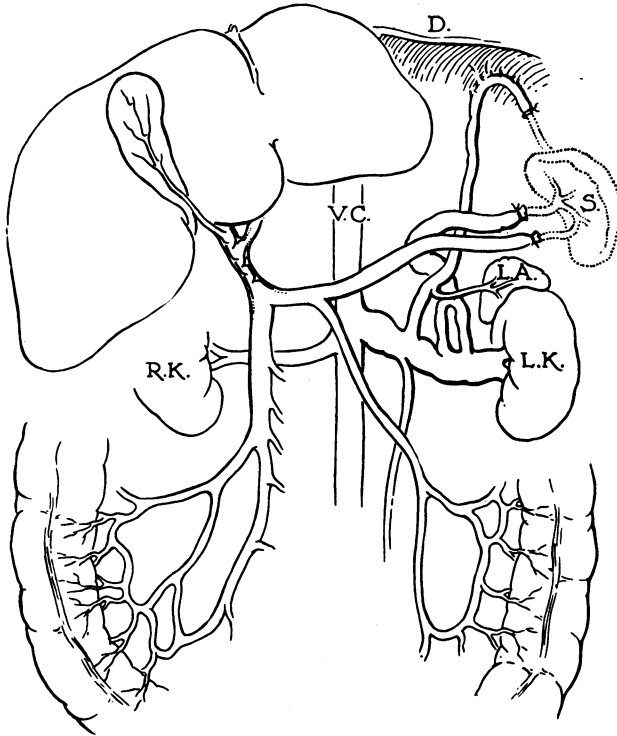


FIG. 10.—Diagram of the collateral circulation. The spleen(S) and the adjacent portions of the veins removed at operation are indicated by dotted lines. L.K. indicates left kidney; R.K., right kidney; V.C., vena cava inferior, and L.A., left adrenal gland. (From Simonds, *Archives of Surg.*, v. 33, 1936.)

B. The veins at the site of the obliterated fetal circulation, the para-umbilical veins in the round ligament of the liver.

C. The veins found at the sites within the abdomen where the gastro-intestinal tract and its appendages, or the organs developed from it, become retroperitoneal developmentally, or adherent to the abdominal walls as a result of some pathologic process. These are sometimes spoken of as the veins of Retzius, and are well shown in the case reported by Simonds¹⁶ (Fig. 10).

EXPERIMENTAL PRODUCTION OF CHRONIC PORTAL BLOCK

This can be done successfully only by a gradual process of obstruction. A sudden closure of the portal vein, or one of its main tributaries, such as

the splenic, results in acute engorgement with either death of the organ, or organs, drained by the portal or an atrophy of the part drained by the obstruction.

Chronic intrahepatic block has been successfully done in our laboratory by Rousselot and Thompson¹⁷ by the repeated injection of finely divided particles of silica into the splenic or portal veins. This, in a period of 12 to 18 months, results in a lesion almost identical with the severe portal

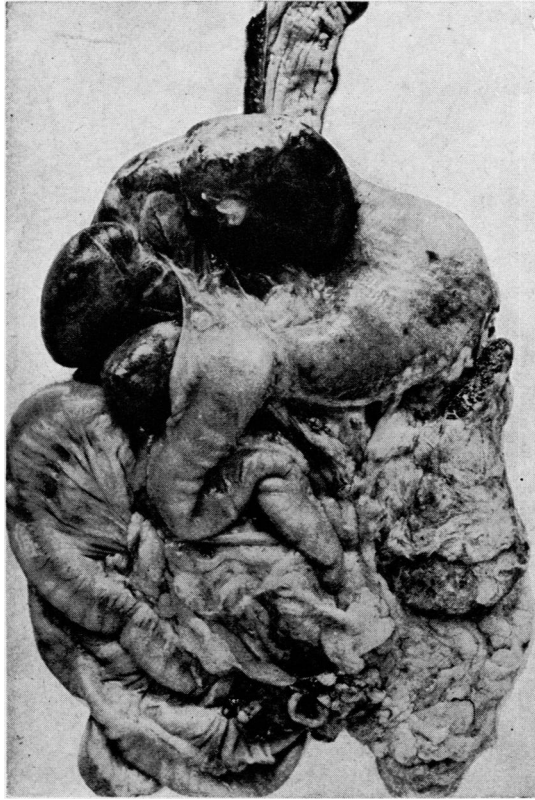


FIG. 11.—Gross specimen of experimental schistosomii cirrhosis with splenomegaly. Note size of the spleen to the left and dilated gastro-epiploic veins.

cirrhosis, splenomegaly and compensatory collateral circulation that is seen in victims of infestation with *Schistosoma mansoni*; for the fragmented ova of this parasite, passing from the portal tributaries to the liver produce the same kind of cirrhosis as do the particulate silica. Figure 11 is taken from an autopsy specimen in one of the dogs in Rousselot's and Thompson's experiments. These animals developed a typical Banti syndrome. Portal vein pressures in the animals showing cirrhosis and splenomegaly were recorded as high as 470 mm. of water. If allowed to live, some of these animals developed a massive ascites and showed tremendous esophageal varices.

Extrahepatic portal block is more difficult to produce experimentally.

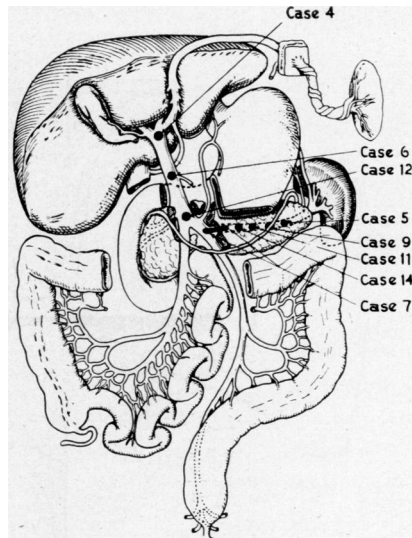
The most successful chronic extrahepatic obstruction in our laboratory was accomplished by Rousselot and Rennie,¹⁸ using cellophane bands placed around the portal or splenic veins, without shutting off the flow of the vein. The gradual production of dense scar tissue around the cellophane bands resulted in a chronic portal obstruction in about half of the animals.

THE SYNDROME OF PORTAL BED BLOCK

In many of the patients, and in experimental animals, portal bed block produces a fairly typical syndrome. Certainly, this is true of the cases showing a splenomegaly whether the block is intra- or extrahepatic. This syndrome consists of a variable secondary anemia, a leukopenia, a thrombocytopenia, a splenomegaly and a tendency to repeated severe gastrointestinal hemorrhage, most frequently associated with ruptured esophageal varices. The liver may be cirrhotic or may be normal, depending upon the site of the portal bed obstruction (Fig. 12). This syndrome is frequently spoken of as Banti's syndrome.

Banti,¹⁹ in 1883, first called attention to this syndrome, and subsequently published a number of papers on the subject, maintaining that the hepatosplenopathy was caused by some unknown toxic agent that first caused the splenic enlargement and later produced a cirrhosis. He described this as a disease running a chronic course, progressing in three stages: (1) The anemic phase, with splenomegaly, asthenia and occasional gastro-intestinal hemorrhage; (2) the transitional stage, with oliguria, urobilinuria, hepatomegaly, brown discoloration of the skin and increasing gastro-intestinal bleeding; and (3) an ascitic stage, with atrophy of the liver, subicteric sclerae, hemorrhages from the mucous membranes and death from hemorrhage or liver insufficiency. He noted some of the hematologic findings, and described the pathology as present chiefly in the spleen and the liver, with almost constant findings in the splenic and portal veins. The pathognomonic lesion he described as a conspicuous thickening of the fibrillar reticulum around the central arteries of the malpighian corpuscles. "The fibro-adenic alterations in the follicle distinguish *morbus* Banti. Their absence rules out the disease."

In fairness to Banti, it must be said that the term Banti's syndrome has not been confined to the entity as described by him. On the other hand, so few cases of hepatosplenomegaly with the anemia, leukopenia and gastro-



Schematic drawing (after F. Paitre - H. Lacaze - S. Dupret), indicating the sites of the obstructive factor in the cases designated

FIG. 12.—Sites of obstruction noted in cases from our clinic reported by Rousselot.

intestinal hemorrhages, as described by Banti, show the three-stage process of the disease that the term Banti's syndrome has replaced to a large extent the term Banti's disease. Inasmuch as Banti insisted that the fibro-adenia of the follicles was the one pathologic finding in the spleen essential to the diagnosis of *morbis* Banti, the finding of this fibro-adenia in cases of splenomegaly, not fulfilling the clinical criteria of the disease described by him, and in cases with normal liver histology but with portal bed obstruction, invalidates the term Banti's disease.

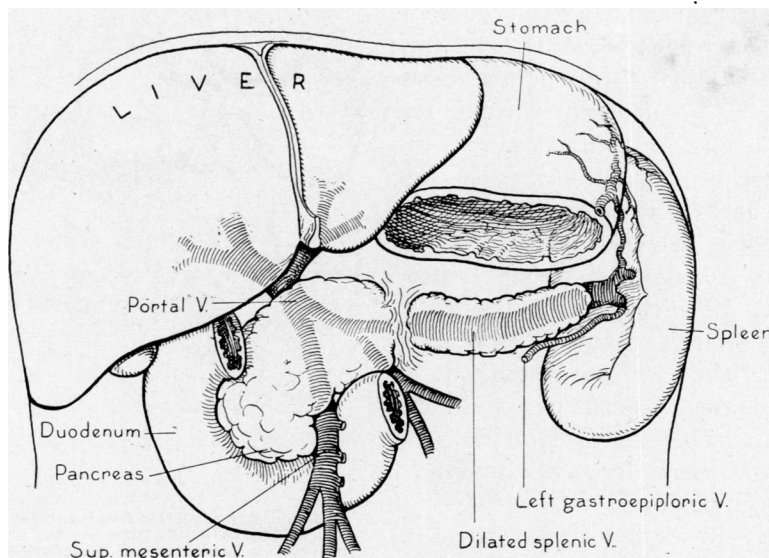


FIG. 13.—Findings in a case of splenomegaly following traumatic rupture of pancreas with splenic vein block.

Klemperer,¹³ among others, advises that the term Banti's disease be abandoned. But the term Banti's syndrome, describing, in general, the syndrome met with in portal bed block is in the literature to stay, although its use too often implies an acceptance of Banti's disease as an entity.

The members of our Spleen Clinic at the Columbia-Presbyterian Hospital have, for a number of years, been especially interested in this syndrome of splenomegaly with anemia, leukopenia and thrombocytopenia, associated with the development of increased collateral circulation between the portal and peripheral venous systems and characteristic histologic changes in the spleen. The patient who first demonstrated to us this syndrome in complete conflict with Banti's hypothesis was a young, vigorous policeman giving the following history: In 1928, in attempting to stop a runaway team he was pinned between an elevator pillar and the tongue of the wagon. This resulted in a rupture of the pancreas, for which he was operated upon at the Post-Graduate Hospital by Dr. John Erdman. A few months later he developed a pancreatic cyst which Doctor Erdman drained. At this time his spleen was not enlarged and his blood picture was normal. During the next three years

he gradually developed a splenomegaly and an anemia with a leukopenia and thrombocytopenia, and had two severe hematemeses. The clinical picture and diagnosis of Banti's syndrome was evident. In 1932 I removed his spleen, finding, at that operation, a very large spleen with an enormously dilated splenic vein, which entered dense scar tissue at the site of the injury to the pancreas, resulting in splenic vein obstruction and diffuse collateral circulation between the splenic vein and branches of the left gastric and left gastro-epiploic veins. The liver appeared normal in every respect. This

TABLE I
SPLEEN CLINIC—PRESBYTERIAN HOSPITAL
Cases to March 15, 1945

	Cases With Splenectomy	Cases Without Splenectomy	Total No of Cases
Abdominal Buerger's disease.....	1	8	9
Anemia:			
Aplastic.....	2	84	86
Cooley's.....	9	17	26
Sickle cell.....	2	22	24
Banti—Extrahepatic:			
Cavernomatous transformation.....	4	2	6
Compression.....	2	3	5
Sclerosis of portal veins.....	5	1	6
Thrombosis.....	3	3	6
Stenosis of portal veins.....	3	1	4
Banti—Intrahepatic:			
Cirrhosis.....	36	59	95
Cirrhosis schistosomal.....	14	3	17
Banti—Obstructive factor undetermined.....	26	9	35
Boeck's sarcoid.....	2	6	8
Cyst of spleen.....	1	..	1
Gaucher's disease.....	10	3	13
Hemolytic jaundice:			
Atypical.....	10	11	21
Typical.....	53	20	73
Hodgkin's disease.....	2	172	174
Leukemia—Chronic myeloid.....	1	152	153
Normal splenectomies.....	42	..	42
Osteosclerotic myelofibrosis.....	3	14	17
Polycythemia.....	1	108	109
Purpura:			
Atypical.....	10	82	92
Idiopathic thrombocytopenic.....	52	26	78
Sarcoma of spleen.....	10	7	17
Splenomegaly—Undetermined origin.....	12	60	72
Total.....	316	873	1,189

patient made an uneventful recovery and his blood values promptly returned to normal and remained so for the next nine years of his follow-up. He had no recurrence of hematemesis.

This finding of a normal liver on the right and a splenomegaly on the left with an obstructive factor between and the picture of Banti's syndrome initiated certain studies which have clarified our ideas regarding the pathogenesis of what we agree with Larrabee²⁰ should be called congestive splenomegaly.

Our Spleen Clinic studies on splenic vein pressures made at the time of splenectomy and compared with peripheral venous pressures were reported by the Spleen Clinic in 1937.²¹ These showed an increase of two to five times splenic vein pressure over peripheral venous pressure in cases presenting Banti's syndrome. Table II shows the comparative readings in the different types of splenomegaly. It is our present concept that Banti's syndrome is

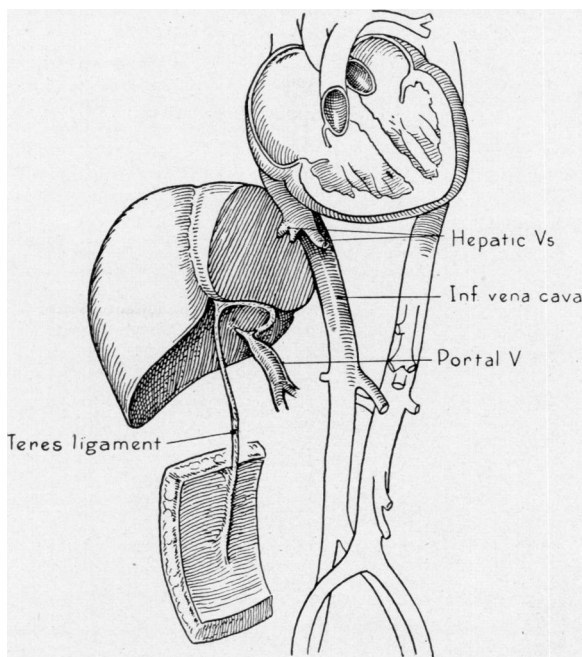


FIG. 14.—Autopsy findings in case of extrahepatic portal block following extension of obliterative process from the umbilical vein into the portal vein.

the result of mechanical obstruction to the flow of blood within the portal bed.

In the cirrheses there is a variable amount of portal hypertension, determined by the amount of scar tissue in Glisson's capsule, the relation of the pressure in the hepatic artery to that in the portal vein and the extent of the hepato-fugal collateral circulation. For these reasons splenomegaly, gastrointestinal hemorrhage, leukopenia and thrombocytopenia are not always found in the cirrheses. This syndrome is not characteristic of the biliary and cardiac cirrheses.

On the other hand, in our experience, if the extrahepatic portal block, from whatever cause, is sufficient to produce a splenomegaly, Banti's syndrome is nearly always present, and a normal liver is usually found even in the cases of long standing, some of which we have followed for 10 to 20 years, and that because of recurrent esophageal hemorrhage have provided us with autopsy studies.

PORTAL HYPERTENSION

H. J. Ward: G-W. First admission: March 17, 1926-May 27, 1926. Twenty-third and final admission: July 22, 1939. Died: July 26, 1939.

Autopsy Report—Final Note: A young man, age 18, who had been in the hospital 23 times for repeated hematemeses, which first occurred at the age of 2.5 years. A diagnosis of Banti's disease was made at the age of five, and was followed by splenectomy. He developed extensive esophageal varices and these were cauterized several times, but

TABLE II

SPLenic VEIN PRESSURE IN THREE CASES OF BANTI'S SYNDROME
ASSOCIATED WITH CHRONIC SCHISTOSOMIASIS

Case No.	Splenic Vein Pressure Mm. H ₂ O	Simultaneous Arm Venous Pressure Mm. H ₂ O
1. P. R.....	250	50
2. A. E.....	335	105
3. G. P.....	500	70

SPLenic VEIN PRESSURE IN FIVE CASES OF BANTI'S SYNDROME
ASSOCIATED WITH LAENNEC'S CIRRHOSIS

Case No.	Splenic Vein Pressure Mm. H ₂ O	Simultaneous Arm Venous Pressure Mm. H ₂ O
4. C. M.....	275	12
5. G. M.....	325	85
6. D. P.....	450	125
7. L. DeR.....	275	105
8. N. A.....	470	140

SPLenic VEIN PRESSURE IN THREE CASES OF TYPICAL HEMOLYTIC
JAUNDICE

Case No.	Splenic Vein Pressure Mm. H ₂ O	Simultaneous Arm Venous Pressure Mm. H ₂ O
9. R. B.....	105	80
10. N. B.....	125	130
11. W. U.....	120	85

intermittent bleeding persisted throughout his life. During the final few months a loud systolic murmur developed and the question of rheumatic endocarditis was raised. Terminally, his blood platelets fell sharply and he developed an hemiplegia which was thought possibly due to the formation of platelet thrombi.

Autopsy shows the cause for the splenomegaly and varices to reside in a greatly narrowed, trabeculated portal vein. Many collateral channels have been established. In some of these about the splenic vein as well as in the latter, and in the portal vein there is considerable phlebosclerosis. Hyaline thrombi are found in veins of the myocardium, kidneys, and rectum, and the right posterior cerebral artery is obstructed by a similar thrombus. The mitral valve bears large organizing vegetations, probably rheumatic in origin. The kidneys show what is probably an early intercapillary glomerulonephritis. There are also small foci of necrosis of tubular epithelium and beginning regeneration, the cause of which is unknown. Sections of the liver appear normal. There is no evidence of cirrhosis.

The pathogenesis of the portal vein lesion is open to discussion. It suggests cavernomatous transformation of a relatively simple type. An early, perhaps congenital, development of the lesion is indicated by the early onset of symptoms, and Doctor

Thompson suggests that the normal postnatal obliteration of the umbilical vein might conceivably extend into the portal trunk. The extensiveness of the collateral circulation, and the enlargement of the hepatic artery, are evidences of compensation in a growing individual.

THE DIAGNOSIS OF PORTAL HYPERTENSION

Patients with a portal hypertension great enough to cause an enlarged spleen usually present the leukopenia and thrombocytopenia and secondary anemia of Banti's syndrome. There may be no history of gross gastrointestinal hemorrhage. The differential diagnosis from other splenomegalies is largely determined by accurate hematologic studies.

The site of the portal block, as to whether it is intrahepatic or extrahepatic can usually be determined by certain liver function tests. If there is a high retention of bromsulphalein in the blood 30 minutes after intravenous injection, if the hippuric acid test is positive, if there is a reversal of the albumin-globulin ratio or if the cephalin flocculation test is positive, the presence of a cirrhosis with intrahepatic portal block is fairly certain. On the other hand, if these tests are negative it is safe to assume that the block is extrahepatic. But this does not necessarily determine the site of the extrahepatic block. In patients with normal liver function if there is a history of an antecedent pancreatitis or a severe trauma to the epigastrium the diagnosis of a splenic vein thrombosis is a valid one. In a young child with normal liver function tests, giving a history of hematemesis at an early age the diagnosis of portal vein occlusion as a result of continuation of the obliterative process in the umbilical vein and ductus venosus is a probable one.²² The final determination of the site of the extrahepatic block in many patients can be made only at the autopsy table, for the dissection necessary to demonstrate such a block is neither safe nor feasible in the great majority of patients on the operating table. We have been unable to determine the site of the extrahepatic block at the time of splenectomy in more than half of our patients, although in our more recent operations we have demonstrated the block by diodrast venograms taken at the time of determining portal vein pressures with roentgenograms at the operating table.

THE TREATMENT OF PORTAL BED BLOCK

The therapy of the cirrhoses not associated with portal hypertension does not come within the scope of our topic. It is the portal bed block, both intra- or extrahepatic, associated with Banti's syndrome that poses the problem to be considered in this discussion.

Three factors, the site of the block (Fig. 12), the degree of portal hypertension and the extent and competency of the collateral circulation determine the size of the spleen and the incidence of gastro-intestinal bleeding. The two latter components of the syndrome are the usual indications for attempted surgical therapy. In the past, three lines of surgical attack have been fol-

lowed—by splenectomy; by the establishment of collateral circulation with intra- or extraperitoneal omentopexy; and by ligation of the tributaries to esophageal varices. These will be considered separately.

The spleen carries a very large load of the portal blood, estimated at 40 per cent of the total. Splenectomy, especially if the spleen is as large as it usually is with Banti's syndrome, removes not only a large area of the portal bed, but shuts off many of the large collateral veins in the gastrolial ligament that feed into the varices around the diaphragm, the cardia and the esophagus.

If the portal block is in the splenic vein the removal of the spleen results in a permanent cure, with the disappearance of the Banti syndrome. Unfortunately, this site, in the splenic vein, for portal bed block is not a common one. We have had only five such cases, but they were all cured, with no recurrence of hematemesis. But even with the block in the main portal vein splenectomy provides relief for a variable time because of the removal of a large area of portal bed and until the portal hypertension builds up again.

The establishment of an adequate collateral circulation by omentopexy: whether by the Talma-Morison procedure of placing the omentum in contact with an abraded or irritated surface of the liver or by suturing the omentum in contact with the split rectus muscle, the efficacy of omentopexy is questionable. In our experience, if the operation is done in the presence of a well-established collateral venous circulation in the abdominal wall, as evidenced by dilated superficial veins, or as shown by infra-red photographs, the results in a few cases are encouraging, but probably due to Nature's efforts rather than to the surgeon's.

Attempts to ligate the tributaries feeding into the veins of the cardia and esophageal varices have been very disappointing. Nor have the injection and coagulation methods to obliterate the esophageal varices been any better. At best, these procedures shut off one of the chief collaterals between the portal and systemic circuits and increase the portal hypertension. The large number of patients with portal vein block and Banti's syndrome whose spleens we have removed, but who continued to have recurrent gastro-intestinal hemorrhage, challenged the members of our Spleen Clinic to seek a more effective and permanent therapy.

Our efforts to anastomose branches of the mesenteric veins to the spermatic, the ovarian and the inferior cava by suture technic had failed. These suture anastomoses dealing with small veins are technically difficult and even with anticoagulants usually close by thrombosis. Attempts to make such shunts in the past have been reported by Gunn²³—right ovarian to the portal; Villard and Tavernier²⁴—ovarian to the superior mesenteric; and Meursing²⁵—spermatic vein to the splenic, without success. Bogorts²⁶ anastomosed the superior mesenteric to the inferior cava and reported a good result. One

month later the spleen had decreased in size and ascites had disappeared. There was no later follow-up note.

We had discussed the more extensive procedures for portacaval shunt based on the principle of the Eck fistula, but because of the difficulties of dealing with the engorged portal tributaries and the disadvantages of suture anastomosis, with the threat of thrombosis, we made no attempts to carry out such procedures until Blakemore, of our Surgical Staff, developed his endothelial-lined vitallium tube nonsuture technic for bridging large vessel defects. Blakemore and Lord²⁷ have recently described this technic, and have made a major contribution to vascular surgery. Before describing this technic as applied to the problem of portacaval shunting operations, it is pertinent to discuss the history of portacaval anastomosis both in experimental animals and in human cases.

Nikolai Vladimirovich Eck was a Russian physiologist, born in 1847. In 1877, he published his report on "The Ligature of the Portal Vein."²⁸ He developed the Eck fistula for the experimental study of diseases of the liver and the relation of the liver to metabolism. Eck suggested that a portacaval fistula might be used to sidetrack obstruction in the portal vein, but the procedure found no trial for many years, until Tansini,²⁹ in 1902, advocated it on the basis of his animal experiments.

Vidal,³⁰ of Angers, claimed to have done this operation for the first time upon a patient with portal obstruction in 1903. This patient lived 14 weeks, and died of a septic endophlebitis. De Martel³¹ reported a patient upon whom he had done an Eck fistula in 1910. The patient succumbed shortly with anuria. Lenoir,³² according to Rosenstein, carried out an end of portal to side of cava anastomosis, but the patient died of anuria. Rosenstein³³ presented a 60-year-old woman, before the 41st Congress of German Surgeons, upon whom he had done an Eck fistula for cirrhosis and ascites in 1911. She had been tapped repeatedly, and five months after the Eck fistula operation this patient required only an occasional paracentesis with much less ascites.

The Eck fistula has been carried out in experimental animals very many times. Probably no one has had so much experience with constructive analysis in the study of Eck fistula dogs as George H. Whipple. His recent report³⁴ on his study of Eck fistula animals is an amazing example of carefully analyzed data on the metabolism of hemoglobin and protein in normal and in depleted Eck fistula dogs. He has observed some of these animals for periods as long as eight years, maintained in apparent state of health. They appear normal in all respects, activity, appetite, digestion and weight, but occasionally they may show increased thirst, diuresis, a trace of jaundice or lack of appetite and vague intoxication, evidences of disturbed protein metabolism.

In a letter,³⁵ written to me recently, Dr. Whipple says that the Eck fistula in dogs consists of a large opening between the portal vein and vena cava, usually 12 mm. in long diameter. The portal vein is ligated and crushed

just as it enters the liver. All operations are checked at autopsy to show that the fistula actually was present during the period between operation and death. Unless the portal vein is ligated the side-to-side opening will promptly close. In this series, Dr. Whipple says the hepatic artery is adequate to support relatively normal clinical activity for many years. He states that he has no knowledge of observations on human Eck fistulae, and considers the operation in cases with portal hypertension an extraordinarily interesting field for protein metabolism studies. He predicts that, as in experimental animals, they will have periods of good and periods of poor protein production.

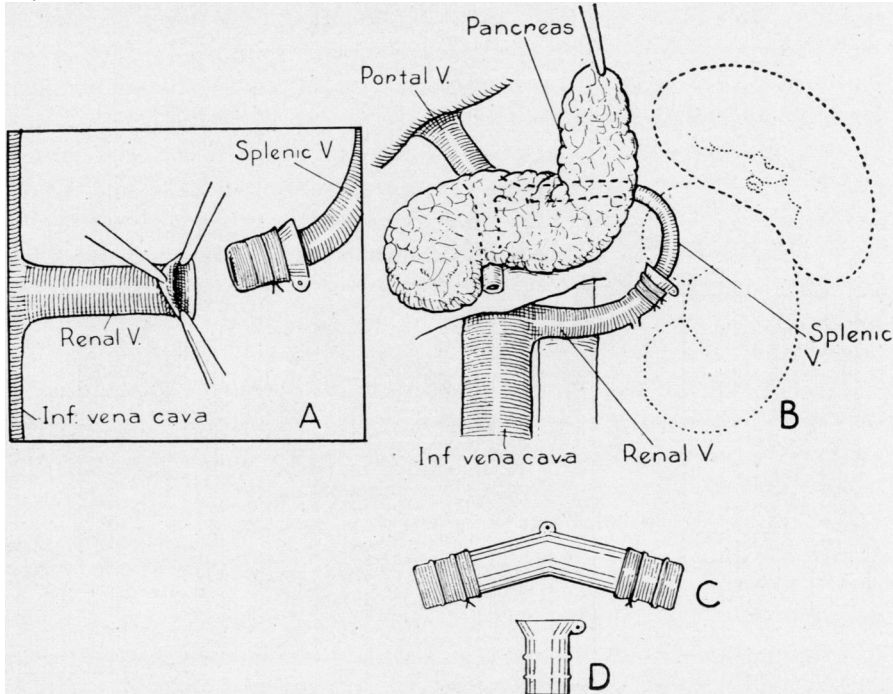


FIG. 15.—Showing technic employed in use of vitallium tubes in portacaval shunts.*

Quierolo,³⁶ in 1893, carried out a procedure for an Eck fistula in 16 dogs which was never given adequate recognition. He everted the cut-end of the portal vein over a glass tube and introduced this into an opening in the inferior vena cava, below the renals, taking care not to have the ligature tying the everted portal enter the cava. Two of these animals lived six months after operation. We were not aware of Quierolo's work until we had completed portacaval shunts in six of our patients.

Blakemore had demonstrated, in a large number of animal experiments and in several clinical cases, that arteriovenous anastomosis, arterio-arterial anastomosis and vein graft anastomosis could be done successfully by his nonsuture method in blood vessels of the extremities. By everting the end

* For details of this procedure see Figure 2 in article by Blakemore and Lord on page 479 of this issue of the ANNALS OF SURGERY,

of a vein or artery over the end of a short funnel-shaped vitallium tube, the endothelial surface can be introduced into the open end of another vein or artery to maintain blood flow, with avoidance of thrombosis because of intact endothelial lining. Or by using such tubes at either end of a vein graft vascular defects in arteries or veins can be effectually bridged (Figs. 15-16). Using this principle, Dr. Blakemore and I have carried out ten of these major procedures, five consisting of uniting the splenic vein and left renal veins, after

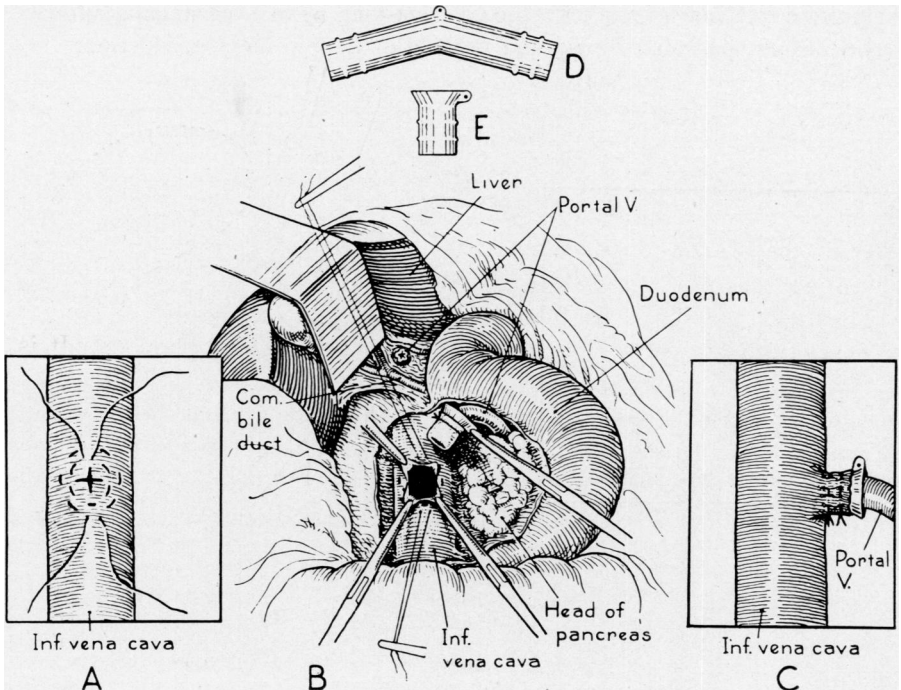


FIG. 16.—Showing technic employed in use of vitallium tubes in portacaval shunts.*

removing the spleen and left kidney. In our last five patients we have anastomosed the portal vein to the inferior cava, end-to-side. All these patients have survived their operations.

These procedures are as yet purely experimental. They have been carried out in patients that had had repeated severe hemorrhages, and for whom conservative measures offered no hope. The results in five of these patients have shown such a marked improvement in their liver function tests and disappearance of ascites or hemorrhage that we have been encouraged to continue, with improved technic, our efforts to provide an adequate short-circuiting of portal blood by the nonsuture technic. These are difficult, trying operations in the presence of engorged portal radicals, and require the teamwork of surgeons experienced in upper abdominal and in the basic principles of blood vessel surgery. Present-day methods for preventing and com-

* For details of this procedure see Figure 3 in article by Blakemore and Lord on page 481 of this issue of the ANNALS OF SURGERY.

bating shock; for improving compromised blood clotting mechanism and hypoproteinemia; together with the Blakemore nonsuture technic account for the fact that all ten of these patients survived the critical operative and post-operative period. It will require a follow-up period of three years, or more, to determine the value of these portacaval short-circuiting procedures. At least they represent a bold attempt to deal with the problem of portal hypertension in its life-threatening forms.

Four other splenorenal vein anastomoses for portal hypertension have recently been performed by Dr. Alfred Blalock,³⁷ who writes me that two of these patients have had a disappearance of ascites and are remarkably improved. On the other hand, he says his enthusiasm is somewhat curbed because the other two patients have died since operation from recurrent bleeding from esophageal varices. He thinks this may be due to occlusion of the anastomosis as a result of the attendant trauma at time of the operation.

With the present improved measures of preventing parenchymal liver damage with high protein-carbohydrate diets, high vitamin therapy, the lives of patients with cirrhosis are prolonged, but many of these patients go on to the development of portal hypertension and gastro-intestinal bleeding. It is also evident that the large number of men in the armed forces invalidated by damaged livers, the result of infectious hepatitis, will become an increasing problem with the development of portal cirrhosis. The problem of therapy for hemorrhage in cirrhosis will continue to be a serious one. Doctors Blakemore and Lord are publishing a detailed report on the technic of portacaval anastomosis in this number of the ANNALS OF SURGERY.

BIBLIOGRAPHY

- ¹ Thompson, W. P., Rousselot, L. M., Elliott, R. H. E., and Whipple, A. O.: The Medical-Surgical Splenopathies. *Bull. N. Y. Acad. Med.*, **15**, No. 3, 174-210, 1939.
- ² Gad: Dissertation, Berlin, 1873.
- ³ Herrick, F. C.: An Experimental Study into the Cause of the Increased Portal Pressure in Portal Cirrhosis. *Jr. Exp. Med.*, **9**, 93-104, 1907.
- ⁴ MacKenzie, D. W., Jr., Whipple, A. O., and Wintersteiner, M. P.: Studies on the Microscopic Anatomy and Physiology of Living Transilluminated Mammalian Spleens. *Am. Jr. Anat.*, **68**, No. 3, 397-454, 1941.
- ⁵ Whipple, A. O.: Recent Studies in the Circulation of the Portal Bed and of the Spleen in Relation to Splenomegaly (The Mütter Lecture). *Transactions and Studies of the College of Physicians, Philadelphia*, 4 Ser., Vol. 8, No. 4, February, 1941.
- ⁶ Malpighi, Marcello: *De Viscerum Structura*. Bononiae, 1666.
- ⁷ McNee, J. W.: The Spleen: Its Structure, Functions and Diseases. (Lettsomian Lectures, 1931). *Lancet*, **1**, 951, 1009 and 1063, 1931.
- ⁸ Knisely, M. H.: Microscopic Observations on the Circulatory Systems of Living Transilluminated Mammalian Spleens and Parturient Uteri. *Proc. Soc. Exp. Biol. and Med.*, **32**, 212-214, 1934; *idem*: Spleen Studies. *Anat. Rec.*, **65**, 23, 131, 1936.
- ⁹ Von Herrath, E.: Zur vergleichenden Anatomie der Saugermilz und ihrer Speicher. und Abwehrrant. gaben. *Med. Klin.*, **34**, 1355-1359, 1938.

- ¹⁰ Mall, F. P.: On the Circulation Through the Pulp of the Dog's Spleen. *Am. J. Anat.*, **2**, 315-332, 1902.
- ¹¹ Robinson, W. L.: The Venous Drainage of the Cat Spleen. *Am. J. Path.*, **6**, 19-26, 1930.
- ¹² Foot, N. C.: The Reticulum of the Human Spleen. *Anat. Rec.*, **36**, 79-90, 1927; *idem, ibid*: On the Endothelium of the Venous Sinuses of the Human Spleen. **36**, 91-102, 1927.
- ¹³ Klemperer, P.: The Chapter on the Spleen in Downey's Handbook of Hematology. Paul B. Hoeber, Inc., New York, 1938.
- ¹⁴ Pick, L.: Über totale hämangiomatöse Obliteration des Pfortaderstammes und Über hepatopetale Kollateralbahnen. *Virch. Arch. f. path. Anat.*, **197**, 490-530, 1909.
- ¹⁵ McIndoe, A. H.: Vascular Lesions of Portal Cirrhosis. *Arch. Path.*, **5**, 23-42, 1928.
- ¹⁶ Simonds, J. P.: Chronic Occlusion of the Portal Vein. *Arch. Surg.*, **33**, 395-424, 1936.
- ¹⁷ Rousselot, L. M., and Thompson, W. P.: Experimental Production of Congestive Splenomegaly. *Proc. Soc. Exper. Biol. and Med.*, **40**, 705, 1939.
- ¹⁸ Rousselot, L. M., and Rennie, J. W. R.: Unpublished experiments.
- ¹⁹ Banti, G.: La Splenomegalia con cirrosi hepatica. *Lo Sperimentale, Sez. biologica fasc.*, V-VI, 1894; *idem*: Splenomegali mit Lever cirrhose. *Beitr. z. path. Anat.*, **24**, 21-33, 1898; *idem*: Über Morbus Banti. *Folia Hematol.*, **10**, 33-74, 1910.
- ²⁰ Larrabee, R. C.: Chronic Congestive Splenomegaly and its Relation to Banti's Disease. *Am. J. Med. Sci.*, **188**, 745, 1934.
- ²¹ Thompson, W. B., Caughey, J. L., Whipple, A. O., and Rousselot, L. M.: Splenic Vein Pressure in Congestive Splenomegaly (Banti's Syndrome). *Jr. Clin. Invest.*, **16**, 571, 1937.
- ²² Rousselot, L. M.: The Late Phase of Congestive Splenomegaly with Hematemesis but Without Cirrhosis of the Liver. *Surgery*, **8**, No. 1, 34-42, 1940.
- ²³ Gunn, K. E. L. G.: *Royal Acad. of Ireland*, **8**, 12, 1911.
- ²⁴ Villard and Tavernier. Reference not given by Ederlen, Hotz and Magnus-Alsleben: *Zeitschr. f. d. gesernte Exper. Med.*, **3**, 265, 1914.
- ²⁵ Meursing, F.: *Deutsch. med. Wochenschr.*, **49**, 1912.
- ²⁶ Bogorts: Über die Überpflanzung der Vena mesenterica superior in die Vena cava inferior bei Leber cirrhose. *Russki Wratsch.*, **2**, 1913. Reference in *Munch. med. Wochenschr.*, **29**, 1913.
- ²⁷ Blakemore, A. H., and Lord, J. W., Jr.: A Nonsuture Method of Blood Vessel Anastomosis. *J. A. M. A.*, **127**, No. 12, 685-691, 1945; *idem, ibid*: No. 13, 748-753, 1945.
- Blakemore, A. H., Lord, J. W., Jr., and Stefko, P. L.: The Severed Primary Artery in the War Wounded: A Nonsuture Method of Bridging Arterial Defects. *Surgery*, **12**, 488-508, September, 1942; Restoration of Blood Flow in Damaged Arteries. *idem*: Further Studies on a Nonsuture Method of Blood Vessel Anastomosis. *ANNALS OF SURGERY*, **117**, 481-497, April, 1943; *idem*: Effect of Sulfathiazole Administered Orally and Sulfanilamide Implanted Locally in Contaminated Wounds: Experimental Study. *Arch. Surg.*, **47**, 352-358, October, 1943.
- ²⁸ Eck, N. V.: The Ligature of the Portal Vein. *Voyeno Med. Jr.*, 1877.
- ²⁹ Tansini: Reference not given. Mentioned by Ederlen, Hotz and Magnus-Alsleben. *Zeitschr. f. d. gesamte exper. Med.*, **3**, 261, 1914.
- ³⁰ Vidal, M. E.: Discussion of de Martel's Case. *Rev. de Chirurgie*, **42**, 1181, 1910; *idem*: *Presse Medical*, **2**, No. 85, 747, October 24, 1903.
- ³¹ De Martel, M. F.: Report of an Eck Fistula in a Woman. *Rev. de Chirurgie*, **42**, 1181, 1910.
- ³² Lenoir: Reference not given. Mentioned in Ederlen, Hotz and Magnus-Alsleben: *Zeitschr. f. d. gesamte Exper. Med.*, **3**, 263, 1914.

- ³³ Rosenstein, P.: Über die Behandlung der Leber cirrhose durch Aulegung einer Eck'schen Fistel. Arch. f. Klin. Chirurgie, **98**, 1082-1092, 1912.
- ³⁴ Whipple, G. H., Robscheit-Robbins, F. S., and Hawkins, W. B.: Eck Fistula Liver Subnormal in Producing Hemoglobin and Plasma Proteins on Diets Rich in Liver and Iron. Jr. Exp. Med., **81**, No. 2, 171-191, 1945.
- ³⁵ Whipple, G. H.: Personal communication.
- ³⁶ Quierolo, G. B.: Eine neue Methode zur Vereinigung der Venen. Untersuch. zur Naturlehre des Menschen und der Thiere. Moleschott, **15**, 233, 1893-1895.
- ³⁷ Blalock, A.: Personal communication.