

## Section of Comparative Medicine

President F R Bell FRCVS

Meeting March 15 1972

### Animal Models of Human Diseases

**Dr H M Pirie and Dr I E Selman**

(University of Glasgow Veterinary School,  
Bearsden Road, Bearsden,  
Glasgow)

#### A Bovine Pulmonary Disease Resembling Human Diffuse Fibrosing Alveolitis

Respiratory diseases are very common in cattle of all ages and they include some of the most important problems with which veterinary clinicians and pathologists have to deal. These conditions, particularly those associated with high morbidity, have been the subject of numerous papers. However, the general consensus of knowledge about the problem is contained in the reports and reviews of Jarrett (1956), Jarrett, Jennings, McIntyre, Mulligan & Urquhart (1957), Jarrett, McIntyre & Urquhart (1957), Mackenzie (1966), Omar (1966), Darbyshire & Roberts (1968), Gourlay & Thomas (1970), Pirie, Dawson, Breeze, Selman & Wiseman (1971), Pirie, Dawson, Breeze, Wiseman & Hamilton (1971), Pirie, Doyle, McIntyre & Armour (1971).

Recently we have obtained 12 cases of a bovine respiratory disease which does not conform to those described in the papers referred to above and which appears to have several features in common with human diffuse fibrosing alveolitis (Scadding & Hinson 1967, Crofton & Douglas 1969). This condition, thought to have been described originally by Hamman & Rich (1944), is sometimes still described as the Hamman-Rich lung (Spencer 1968) and in the reports of two large series of cases was also referred to as diffuse interstitial pulmonary fibrosis (Livingstone *et al.* 1964) and idiopathic diffuse interstitial lung disease (Stack *et al.* 1965).

This paper is concerned with the clinical and pathological features of the disease in the bovine species.

#### Clinical Findings

The 12 cases were provisionally divided into two groups. Group 1 consisted of 9 adult beef cows all over 6 years of age. Although admitted to the veterinary hospital in autumn or winter, most cases presented in October. Generally they were thin but bright and, except for 2 in congestive cardiac failure, all were eating well. The case history, when it could be obtained, was usually of chronic respiratory disease varying from a few weeks to two years duration. The affected animal was the only one in its group on the farm to show clinical signs of respiratory disease. One cow had had three episodes of 'acute pneumonia' during the last year of life. Prior to admission to the veterinary school there was often a sudden deterioration. In 2 cows this was due to the development of cor pulmonale and congestive heart failure.

All the cows had an increased respiratory rate, 40–60/min (normal <30/min). There was marked hyperpnoea and a nonproductive cough. A significant finding in every animal was loud rhonchi widespread over both lung fields, and in many cases there were also crepitant rales over the ventral areas of the lungs. There was a marked worsening of the respiratory state after mild exercise, with respiratory distress. The animals were not febrile.

Most of the cows had a marked eosinophilia on at least one occasion during their stay in the hospital, although the total white cell count was never elevated. Five of the 9 were tested for precipitins against *Micropolyspora faeni*, by double diffusion in agar gel, and all were negative. Four had clinical or biochemical evidence of renal disease and 2 had congestive heart failure with distended jugular veins and subcutaneous oedema.

Group 2 consisted of the remaining 3 cows. They were also admitted during autumn and winter but were dairy cows with poor appetites

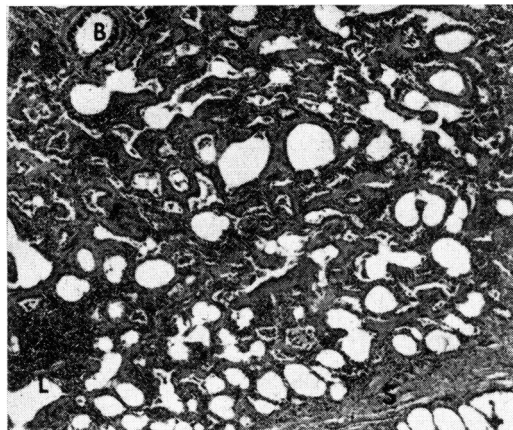


Fig 1 Diffuse thickening of alveolar walls by cellular infiltration and fibrosis, showing an aggregate of lymphocytes (L), a normal bronchiole (B) and a slightly thickened interlobular septum (S). Picro Mallory.  $\times 67$

and appeared dull. All were over 5 years of age. One had had respiratory signs for three to four months with a recent deterioration and a second had recently developed congestive cardiac failure. The clinical signs were essentially similar to the other cases but 2 had marked respiratory distress even at rest. One had a mild eosinophilia (7.5%). Two were tested for precipitins against *M. faeni* and both were positive. All 3 had some evidence of renal disease.

No treatment was given to any of the 12 animals and all were eventually slaughtered, in some cases as long as four weeks after admission.

#### *Pathological Findings*

The gross changes in the lungs of the 12 animals were essentially similar. They were exceptionally pale, almost white in places, firm and extremely heavy, weighing 8.0–9.5 kg (normal weight 4.0–5.0 kg). There was generalized involvement of all the lobes and in most cases one or more lobes contained a few grey lobules which exuded copious oedema fluid when sectioned. In addition small grey spots less than 1.0 mm in diameter could be seen in the pale pulmonary tissue of some animals. The interlobular septa tended to be greyish and in places slightly thickened. Infrequently lobules were found, mostly in the diaphragmatic lobes, with multiple small cystic areas.

A slight to moderate amount of grey or greyish-green mucus, in the form of globules or tenacious strands, was present in the bronchial tree in 10 cases. The bronchial and mediastinal lymph nodes were enlarged.

When blocks of tissue from the lungs were examined microscopically lesions were found in all lobes. They were characterized by thickening of

the alveolar septa due to a cellular infiltrate or fibrosis (Fig 1), accumulations of large mononuclear cells within the alveoli which were like alveolar macrophages (Fig 2), and aggregates of lymphocytes in the respiratory tissue, pleura and interlobular septa. Hyperplasia and metaplasia of the alveolar surface epithelium were also present.

Plasma cells usually predominated in the cell population in the alveolar septa but lymphocytes, mononuclear cells and occasional eosinophils could also be found. There was an increased amount of reticulin in the septa and extensive fibrosis (Fig 3). Alveoli containing oedema fluid were found and others contained large numbers of alveolar macrophages.

Some alveoli were lined by cuboidal epithelium but a more striking change in the surface epithelium of the respiratory acini was the presence of columnar cells which either had cilia or were mucus-secreting (Fig 4). This was a focal change and, although often present near bronchioles, sometimes appeared to occur at the periphery of the lung. Metaplasia of the alveolar epithelium was occasionally seen in areas where alveolar septa were not thickened. In some animals the alveolar duct muscle appeared to be increased in amount. The areas with a cystic appearance macroscopically had dilated air spaces with fibrosed walls lined by cuboidal epithelium. Fibrous thickening of the intima was found in branches of the pulmonary arteries.

The bronchi in most cases had globule leukocytes in the epithelium, plasma cells in the lamina propria and occasionally a marked infiltrate of eosinophils. The bronchial glands were hyperplastic in some animals.

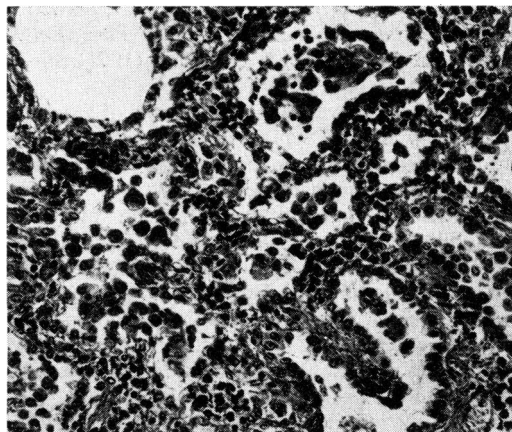


Fig 2 Plasma cells in the septa of several alveoli and cells resembling alveolar macrophage in the airspaces. Hyperplasia of the alveolar surface epithelium is also present. Picro Mallory.  $\times 110$

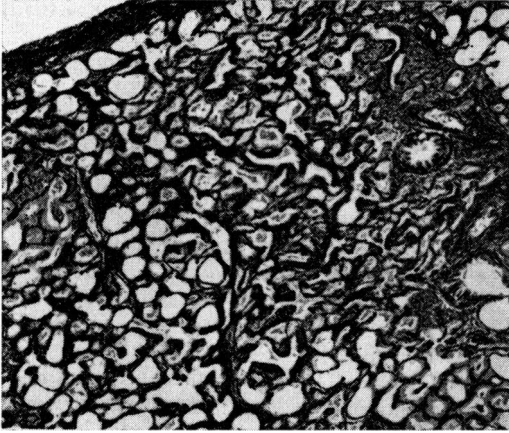


Fig 3 Increased amounts of reticulin in the interstitium of the lung of a cow with diffuse fibrosing alveolitis. Gordon & Sweet.  $\times 55$

The cattle in Group 2 had essentially similar lesions to those in Group 1 but the cellular infiltrate into the respiratory tissue seemed more intense and they had also bronchiolitis obliterans.

In addition to the changes in the lungs, 4 cows had evidence of cor pulmonale and 3 had changes of frank congestive heart failure. Seven animals had renal lesions which varied from chronic interstitial nephritis, chronic pyelonephritis, and glomerulonephritis to renal amyloidosis. Eight animals had chronic fascioliasis and in one of these the liver lesions were classified as cirrhosis.

#### Discussion

Diffuse fibrosing alveolitis in the bovine species is a distinct clinical and pathological entity. Clinically these cases can be readily detected because, although the animals are usually bright, they have a persistently high respiratory rate, widespread adventitious sounds over both lung fields, and a cough. At rest hyperpnoea is obvious and even mild exercise is not readily tolerated.

Although they appear to eat readily they are thin and there is a tendency to develop congestive cardiac failure. When the lungs are seen at post-mortem they may appear to be almost normal until inspected closely. This feature is particularly striking when the degree of clinical respiratory abnormality is known. The lesions seen microscopically are distributed widely in all the lobes of the lung and the fibrosis is characteristically within the interstitium of the respiratory acinus.

The cellular thickening and fibrosis of the alveolar septa conform to one of the criteria suggested by Scadding & Hinson (1967) for diffuse fibrosing alveolitis. Their second criterion of large mononuclear cells in the alveolar space was also fulfilled although in most cows in Group 1 the interstitial reaction predominated.

Hyperplasia and metaplasia of the alveolar epithelium was not considered an essential feature of the disease in man but it was present in many of our cases. These changes were referred to by Livingstone *et al.* (1964) who commented on the possible association between this interstitial type of fibrosis and peripheral lung tumours, citing a case described by Scadding (1960) which resembled alveolar cell carcinoma. Stack *et al.* (1965) also referred to this association and remarked on the overgrowth of epithelial cells which developed in the tissue cultures of lung from one of their cases.

Although the predominant changes in the lungs were in the alveoli, there was also a reaction in the bronchial tree. The commonest cause of bronchitis in cattle is the lungworm *Dictyocaulus viviparus* but none were found in these animals and the lesions did not conform to the usual bronchitis associated with a primary *D. viviparus* infection (Jarrett, McIntyre & Urquhart 1957). They may be a hypersensitivity type of reaction to *D. viviparus* but whether they are related to the changes in the respiratory portion of the lung or are coincidental is not clear.

Scadding (1970) has suggested that one form of human fibrosing alveolitis could be due to farmer's lung and it is possible that a similar pathogenesis is responsible for the disease in the cows with precipitins against *M. feni*, although there are some differences between the changes in these lungs and those in bovine farmer's lung (Pirie, Dawson, Breeze, Wiseman & Hamilton 1971). A chronic interstitial pneumonia of cattle kept indoors in Switzerland (Fankhauser & Luginbuhl 1960) has been attributed recently to bovine farmer's lung.

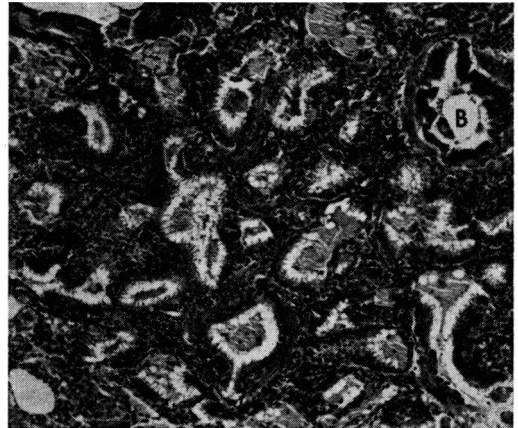


Fig 4 A group of alveoli, adjacent to a bronchiole (B), lined by columnar epithelium containing ciliated cells. Mucoïd material is in the lumina of the alveoli and there is a plasma cell and lymphocyte infiltrate in the alveolar septa. H & E.  $\times 83$

Diffuse fibrosing alveolitis has been described in humans with chronic liver disease (Turner-Warwick 1968) but it is impossible at present to assess the significance of the liver lesions in the cattle described here, since chronic fascioliasis is very prevalent in animals of this age group. Excluding *M. fæni*, it is unlikely that diffuse fibrosing alveolitis in cattle is caused by the same etiological factor as in man, but it is likely that the mechanisms which lead to the cellular infiltration, fibrosis and changes in the alveolar epithelium are similar.

#### REFERENCES

- Crofton J & Douglas A (1969) *Respiratory Diseases*. Blackwell, Oxford & Edinburgh  
 Darbyshire J H & Roberts D H (1968) *Journal of Clinical Pathology*, 21, Suppl. 2, p 61  
 Fankhauser R & Luginbuhl H (1960) *Schweizer Archiv für Tierheilkunde* 102, 47  
 Gourlay R N & Thomas L H (1970) *Journal of Comparative Pathology and Therapeutics* 80, 585  
 Hamman L & Rich A R (1944) *Bulletin of the Johns Hopkins Hospital* 74, 177  
 Jarrett W F H (1956) *British Veterinary Journal* 112, 431  
 Jarrett W F H, Jennings F W, McIntyre W I M, Mulligan W & Urquhart G M (1957) *Veterinary Record* 69, 1329  
 Jarrett W F H, McIntyre W I M & Urquhart G M (1957) *Journal of Pathology and Bacteriology* 73, 183  
 Livingstone J L, Lewis J G, Reid L & Jefferson K E (1964) *Quarterly Journal of Medicine* 33, 71  
 Mackenzie A (1966) *Proceedings of the Royal Society of Medicine* 59, 1008  
 Omar A R (1966) *Veterinary Bulletin* 36, 259  
 Pirie H M, Dawson C O, Breeze R G, Selman I E & Wiseman A (1971) *Research in Veterinary Science* 12, 586  
 Pirie H M, Dawson C O, Breeze R G, Wiseman A & Hamilton J (1971) *Veterinary Record* 88, 346  
 Pirie H M, Doyle J, McIntyre W I M & Armour J (1971) *Pathology of Parasitic Diseases*. Purdue University Studies, Lafayette, Indiana; p 91  
 Scadding J G (1960) *British Medical Journal* i, 443  
 (1970) *British Medical Journal* ii, 557  
 Scadding J G & Hinson K F W (1967) *Thorax* 22, 291  
 Spencer H (1968) *Pathology of the Lung (Excluding Pulmonary Tuberculosis)*. Pergamon, London  
 Stack B H R, Grant I W B, Irvine W J & Moffat M A J (1965) *American Review of Respiratory Diseases* 92, 939  
 Turner-Warwick M (1968) *Quarterly Journal of Medicine* 37, 133

Dr J E T Jones<sup>1</sup>

(Department of Medicine,  
 Royal Veterinary College, London)

#### Experimental Bacterial Endocarditis in the Pig

Bacterial endocarditis has been investigated extensively for over a century, yet many aspects of its pathogenesis remain unresolved. In particular, the events following blood stream infection leading to the inception of the valvular lesion are inadequately understood. Numerous methods have been employed in attempts to produce endocarditis and the diverse experimental procedures

adopted testify to the difficulties of consistently reproducing the disease by simple methods such as a single intravenous inoculation of bacteria into a normal animal.

The earliest experimental production of endocarditis is usually attributed to Ribbert (1886), who injected rabbits intravenously with a mixture of staphylococci and potato particles. In his successful experiments the rabbits died within 60 hours and small nodules were found on the edges of the mitral and tricuspid valves. He considered that the coccus became implanted in the valve surface, causing damage which allowed the formation of thrombotic nodules.

Wysokowitsch (1886) and Orth (1886) utilized a technique designed to damage the heart valves prior to the systemic introduction of a bacterial pathogen. They damaged the aortic valves of rabbits by introducing a sharp instrument into the aorta via the carotid artery. Following the injection of streptococci into such prepared animals, endocarditis developed; lesions did not develop in rabbits if their aortic valves had not been damaged, even though the dose of infecting organisms was increased tenfold.

Dreschfeld (1888*a, b*) communicated the results of an important experiment to the Pathological Society of Manchester in October 1887 and again to the Lancashire Veterinary Medical Association in December 1887. He reported isolating a streptococcus from vegetative lesions superimposed on the damaged mitral valve of a woman with rheumatic endocarditis, and injecting a beef-tea suspension of the organism intravenously into a rabbit; the rabbit developed extensive heart valve lesions and renal infarction. The streptococci were recovered from the experimentally produced lesion and injected into another rabbit, with similar results. Dreschfeld's experiment is of historical importance because it is the first instance of endocarditis being produced by the simple intravenous injection of a bacterial pathogen without resorting to prior mechanical trauma of the valves or to the injection of foreign substances.

The experimental methods employed by these early investigators, namely (1) the injection of foreign substances, (2) preliminary trauma of the valves and (3) simple injection of a bacterial pathogen, set a trend that was to be followed for many years.

#### Experimental Methods

Two general systems of experimentation have evolved. In the first, normal animals are used; in the second, the animals are subjected to some procedure intended to render their heart valves more susceptible to bacterial attack. The bacteria used most frequently have been those isolated from man, usually from endocardial lesions, but

<sup>1</sup> Present address: Department of Animal Husbandry, Royal Veterinary College, Boltons Park, Potters Bar, Hertfordshire