

necrosis. Collins, Stahlman, and Scott (1953) described this complication following hypothermia for cardiac surgery. The body temperature of a 5-month-old infant was reduced to 28 °C (82.5 °F) for 2.3 hours; 2 weeks later fat necrosis appeared in the abdominal wall, trunk, buttocks, and thighs. Blake *et al.* (1955) described a similar case in a 20-month male infant following hypothermia for cardiac surgery for tetralogy of Fallot. Extensive areas of fat necrosis in the trunk and buttocks occurred 16 days later.

Duhn, Schoen, and Siu (1968) described 2 infants who developed extensive fat necrosis with calcification after induced hypothermia for the treatment of asphyxia after birth. This treatment was based on the belief, held by some at that time, that hypothermia would reduce the oxygen requirements of the brain. Hypothermia was induced by immersion of the body below the neck in ice water baths. One infant was immersed for 28 minutes and the other for 5 minutes; both were removed when breathing started. The rectal temperature of the first infant was 32.2 °C (90 °F) 45 minutes after birth, and of the second infant 33.4 °C (92 °F) 1½ hours after birth. During the first few weeks of life both infants developed extensive fat necrosis with calcification, involving the subcutaneous tissue below the head. X-rays confirmed the extensive calcification and a biopsy was done in the second case giving added confirmation. There was no evidence of a disturbance in calcium metabolism. In both cases the lesions gradually resolved before the age of 6 months, without any atrophy of the subcutaneous fat being seen.

Fat necrosis due to hypothermia appears to be a complication peculiar to infants, probably due to the low level of oleic acid in the adipose tissue of newborn infants compared with the adult (King *et al.*, 1971). Oleic acid is a long chained fatty acid and has a much lower melting point (13 °C) than palmitic acid (62.85 °C), so that the low oleic acid content of adipose tissue of the newborn makes it more prone to solidify as a result of hypothermia.

In this case hypothermia and trauma could have been responsible for extensive fat necrosis with subsequent calcification. The subsequent atrophy of the subcutaneous tissue in the right leg is of interest and this may be related to the severity of the initial trauma. The ultimate recovery was however complete.

Summary

A case of calcification of subcutaneous tissue following trauma and hypothermia is described.

Resorption of calcium salts was followed by atrophy of the subcutaneous tissues of the leg. Full recovery occurred after several years.

I am grateful to Mr. Ireland, Dr. Hall, and Dr. Jones for help and criticism.

REFERENCES

- Collins, H. A., Stahlman, M., and Scott, H. W., Jr. (1953). The occurrence of subcutaneous fat necrosis in an infant following induced hypothermia used as an adjuvant in cardiac surgery. *Annals of Surgery*, **138**, 880.
- Blake, H. A., Goyette, E. M., Lyter, C. S., and Swan, H. (1955). Subcutaneous fat necrosis complicating hypothermia. *Journal of Pediatrics*, **46**, 78.
- Duhn, R., Schoen, E. J., and Siu, M. (1968). Subcutaneous fat necrosis with extensive calcification after hypothermia in two newborn infants. *Pediatrics*, **41**, 661.
- King, K., Adam, P., Laskowski, D. E., and Schwartz, R. (1971). Sources of fatty acids in the newborn. *Pediatrics*, **47**, 192.

A. E. MCCANDLESS

Alder Hey Children's Hospital, Eaton Road, Liverpool L12 2AP.

Congenital Epulis: Its Natural History

The congenital epulis was first described in 1871 since when reports of these lesions have appeared at infrequent intervals so that by 1955 Campbell noted that only 29 examples had been published. He did observe that with an increased awareness of the condition, its occurrence may be less rare than was previously supposed. This observation is borne out by the fact that now, 100 years after the original description, some 70 such cases have been described. The same author has remarked however that no idea of the natural history of the congenital epulis can be obtained from reported series. Two further reports are presented here, and from these we can make some observations on the natural behaviour of the congenital epulis.

Case Reports

Case 1. (This has been briefly described by Jones in 1965.) Boy born in 1959, with a large pedunculated tumour attached to the lower alveolar ridge as seen in Fig. 1. At operation under local anaesthetic this was removed 3 hours after birth. Examination of the mouth at this stage revealed a second tumour. This was present in the upper right area of the mouth, was very much smaller than the main mass, and had a sessile attachment to the gum. On inspection and palpation it was otherwise similar to the larger tumour. This was not removed. On follow-up check 13 months later this lesion had resolved and tooth eruption was proceeding normally.

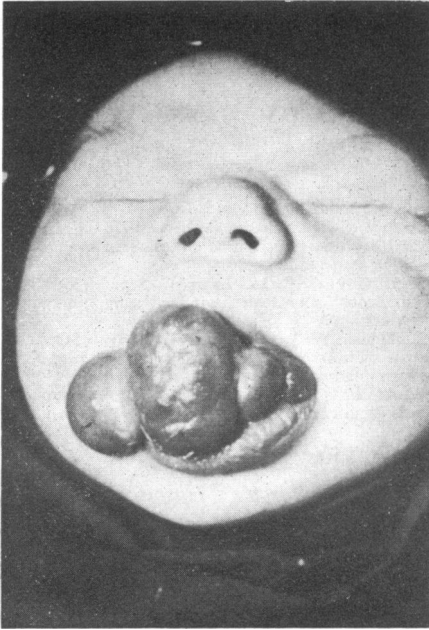

FIG. 1.—Case 1: clinical appearance 3 hours after birth.

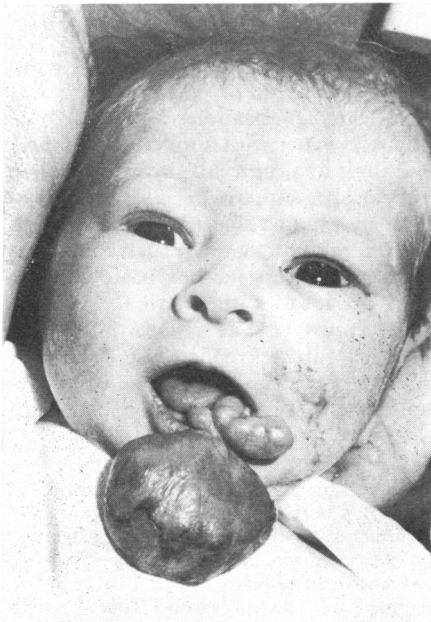


FIG. 2.—Case 2: clinical appearance one day after birth.

Case 2. Girl, born in 1969, at term after an uneventful pregnancy, presented with a pedunculated mass 35 × 30 mm protruding from the mouth and attached to the lower anterior alveolus. Three other similar

but smaller masses were attached to the same pedicle (Fig. 2). A further tumour of smaller but similar appearance had a sessile attachment to the gum in the posterior region of the left mandible, having no connexion with the main lesion and between which the gum appeared normal in all respects. At operation under endotracheal anaesthesia the central tumour was removed two days after birth, while the smaller tumour was not touched. Five weeks after operation healing was well advanced in the central area while the mass in the posterior mandible had disappeared and the gum in this area was normal and has remained so one year later.

Pathological findings. Histological examination in each case confirmed the diagnosis of congenital epulis, and it was noted that the typical granular cells extended to the limit of resection, and indeed the pedicle in Case 2.

Discussion

In their classic account of the congenital epulis Custer and Fust (1952) are unwilling to regard the lesions as true neoplasms and tend to regard them as a form of embryonal hamartoma, arising from the tooth bud. However, in both our cases dentition is normal to date. It is of interest that no case report has ever noted an increase in size after first observation, which suggests that active growth of the lesion stops at birth. From our experience we further suggest that spontaneous regression may take place after birth, as happened in the smaller lesion in both our cases. There is also the fact that at histology the granular cells extended to limits of excision and there was no evidence of recurrence. Such behaviour we feel suggests that the natural history of the congenital epulis is to undergo resolution in the absence of superimposed trauma or infection. This can be accepted as further evidence against a neoplastic nature of the lesion.

Summary

The clinical features of two infants with congenital epulis are described, and the presence of a smaller secondary lesion in each case allowed the observation of the natural history of the condition.

REFERENCES

- Campbell, J. A. H. (1955). Congenital epulis. *Journal of Pathology and Bacteriology*, **70**, 233.
 Custer, R. P., and Fust, J. A. (1952). Congenital epulis. *American Journal of Clinical Pathology*, **22**, 1044.
 Jones, J. H. (1965). Non-odontogenic oral tumours in children. *British Dental Journal*, **119**, 439.

F. V. O'BRIEN and W. D. PIELOU

Department of Pathology, The Queen's University of Belfast and Department of Child Dentistry, Royal Victoria Hospital, Belfast, N. Ireland.