

Transitional Cell Carcinoma of the Urinary Bladder in a Beluga Whale (*Delphinapterus leucas*)

D. MARTINEAU, A. LAGACÉ, R. MASSÉ, M. MORIN AND P. BÉLAND

Département de pathologie et microbiologie, Faculté de Médecine vétérinaire, Université de Montréal, Saint-Hyacinthe, Québec J2S 7C6 (Martineau, Lagacé, Morin), Université de Québec, Institut national de la recherche scientifique, Pavillon Gamelin, 7401, rue Hochelaga, Montréal, Québec J1N 3M5 (Massé) and Centre de recherches en écologie des pêches, Rimouski, Québec, Pêches et Océans Canada (Béland)

ABSTRACT

A transitional cell carcinoma of the urinary bladder was found in a beluga whale stranded in the St. Lawrence middle estuary. Various organs of this animal were submitted to high resolution gas chromatography coupled with mass spectrometry analysis. High frequency of urinary bladder cancer in the human population of the same area and the presence of carcinogenic compounds in the marine environment of this animal are discussed.

Concurrent isolation of *Edwardsiella tarda* from various organs of this whale is also reported.

Key words: Cetaceans, urinary bladder, transitional cell carcinoma, carcinogens, polycyclic aromatic hydrocarbons, *Edwardsiella tarda*.

RÉSUMÉ

Épithélioma des cellules de l'épithélium de transition de la vessie, chez un béluga (*Delphinapterus leucas*)

Un épithélioma des cellules transitionnelles de la vessie est décrit chez un béluga de l'estuaire moyen du fleuve Saint-Laurent. Divers tissus de cet animal furent analysés par la chromatographie en phase gazeuse couplée avec la spectrométrie de masse.

Les auteurs signalent que la population humaine de cette région est affectée par un taux élevé de cancer de la vessie et rapportent la présence de produits cancérigènes dans l'environnement de ces animaux.

Edwardsiella tarda fut isolée de plusieurs organes de cet animal.

Mots clés: cétacés, vessie, épithélioma des cellules transitionnelles; carcinogènes, hydrocarbures polycycliques aromatiques, *Edwardsiella tarda*.

INTRODUCTION

Neoplasms have been rarely reported in cetaceans: only 36 have been described histologically (1). Of these, five were malignant and only one occurred in the urinary tract (a renal adenoma in an Atlantic bottle-nosed dolphin (*Tursiops truncatus* (2)). In the present paper, a carcinoma of the bladder found in a beluga whale, stranded in the St. Lawrence River middle estuary, is reported. This area, centered around the Saguenay river mouth is inhabited by a small indigenous population of this species composed of approximately 500 individuals (3).

The possible role of carcinogenic pollutants in the etiology of marine mammal neoplasms was discussed by Howard (1) and Landy (4). The presence of high levels of polycyclic aromatic hydrocarbons (PAH) which are strong carcinogenic compounds (5) has been reported in the marine environment of this beluga (6).

MATERIALS AND METHODS

A male beluga whale was found dead, stranded in the Matane area, Province of Quebec, approximately 420 km northeast of Quebec city, on the St. Lawrence south shore on November

30, 1983. It was 3.57 m long and its dorsal blubber was 8.5 cm thick. The presence of 33 concentric dentine layers indicated that it was a young adult animal (7). The carcass was examined at the College of Veterinary Medicine of Saint-Hyacinthe, 600 km southwestward.

Tissues from selected organs were fixed in buffered 10% formalin for histological examination. They were stained with a hematoxylin-phloxinsaffron stain and the lungs with Von Kossa, PAS, Verhoeff, Alcian blue, Mayer's Mucicarmin and Masson's Trichrome. Various tissues were cultured on blood agar, incubated at 37°C in a 10% CO₂ atmosphere and examined after 48 hours. Identification was done with an Analytical Profile Index diagnostic kit (Analytab products, Ayerst Laboratories, Plainview, New York).

Blubber, kidney, liver and lung samples were wrapped in aluminium paper previously rinsed with acetone, placed in plastic bags and kept on ice for two hours. Then, they were frozen at -20°C until analyzed.

Analyses were carried out to determine the presence of 2,2-bis (p-chlorophenyl) -1, 1-dichloroethylene (p, p' - DDE), polychlorinated biphenyls (PCB's) and benzo[a]pyrene (B[a]P). These tissues were homogenized in methanol and 10 mL KOH 10 N were added. The resulting mixture was saponified at 100°C for two hours and extracted three times with 75 mL of hexane. The organic phases

This work was supported by: le Centre de recherches en écologie des pêches, Rimouski, Pêches et Océans, Canada, the Canadian Wildlife Federation, le fonds FCAC, le ministère de l'Éducation du Québec and the Natural Sciences and Engineering Research Council of Canada.

were combined and evaporated at 40°C under reduced pressure.

Extracts were then eluted on an activated alumina column (1 x 17 cm) at ambient temperature with hexane-dichloromethane (5:1 v/v) at a flow rate of 1 mL/min. Ten mL fractions were collected. The chromatographic retentions of the compounds of interest were determined using Aroclor 1254, p. p' — DDE, benzo[a]pyrene (B[a]P) as reference compounds. The chlorinated compounds and B[a]P eluted in the first and the second fractions respectively.

The quantitative determinations were performed on a Perkin Elmer Sigma 2 gas chromatograph equipped with a 30 m DB-5 fused silica capillary column and a flame ionization detector. The identity and the degree of chlorination of the compounds were verified by gas chromatography-mass spectrometry analysis (GC/MS) on a Kratos MS-25 instrument.

Operating conditions for identification and quantitation of PCB's and DDE were as follows: for GC and GC/MS analysis, column temperature was programmed from 60°C at 10°C/min to 140°C and up to 315°C at 2°C/min. Masses 50 to 500 were scanned in the electron impact mode at 1 sec per decade.

The compounds were measured by digital integration of peak areas. The PCB's were estimated by comparing total area of the peaks with those of Aroclor 1254a and 1260 (Monsanto Co., St. Louis, Missouri). The DDE concentrations were determined by reference of p.p' — DDE peak areas to a standard curve obtained by plotting the peak areas of p.p' — DDE vs its concentration.

RESULTS

At postmortem examination multiple slit-like invaginations of epidermis, 1 to 5 cm long and 1 to 2 cm deep were found on the dorsolateral aspects of the body. Gross evidence of inflammation did not accompany these lesions.

The right ventricle of the heart was compressed by a large ovoid mass weighing 660 g. The lungs had numerous nodular foci, 1 to 8 mm long (Figure 1), throughout the parenchyma: these foci were white, with a shiny surface and a firm consistency. Many less well demarcated pale areas, with

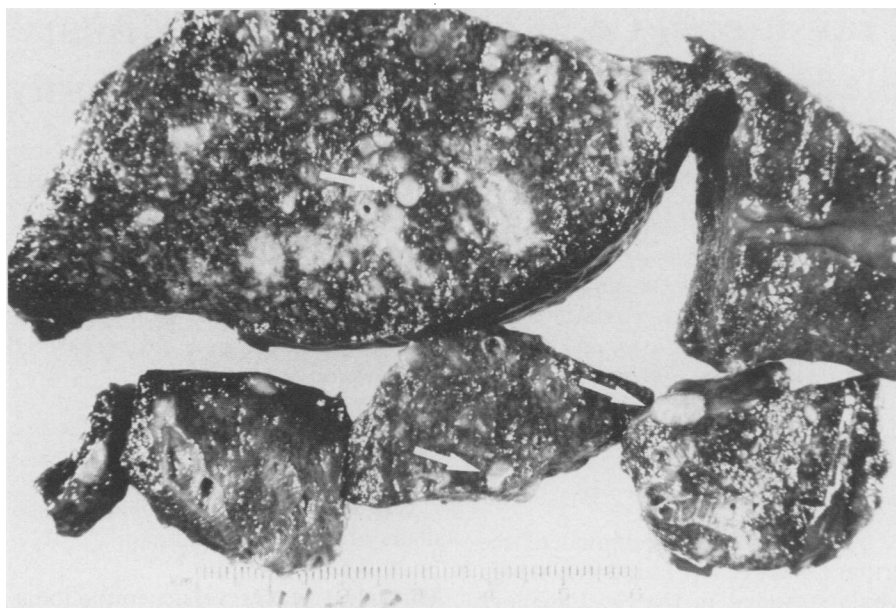


FIGURE 1. Lungs. White, shiny nodules are scattered throughout the parenchyma (arrows). The less well demarcated and pale areas represent fibrosis.

irregular shape and size were also scattered in the pulmonary tissue. Some nematodes about 3 cm long were found in the bronchioles.

Many white circular patches were seen on the aortic intima, at the level of the origin of the renal arteries. A mesenteric artery branch was nearly

occluded by an intimal proliferation showing three firm yellow nodules upon incision. The gastric compartments were empty. A circular ulcer, 1.5 cm in diameter and 1 mm deep was observed in the second gastric compartment halfway between the orifices leading to the first and third compart-

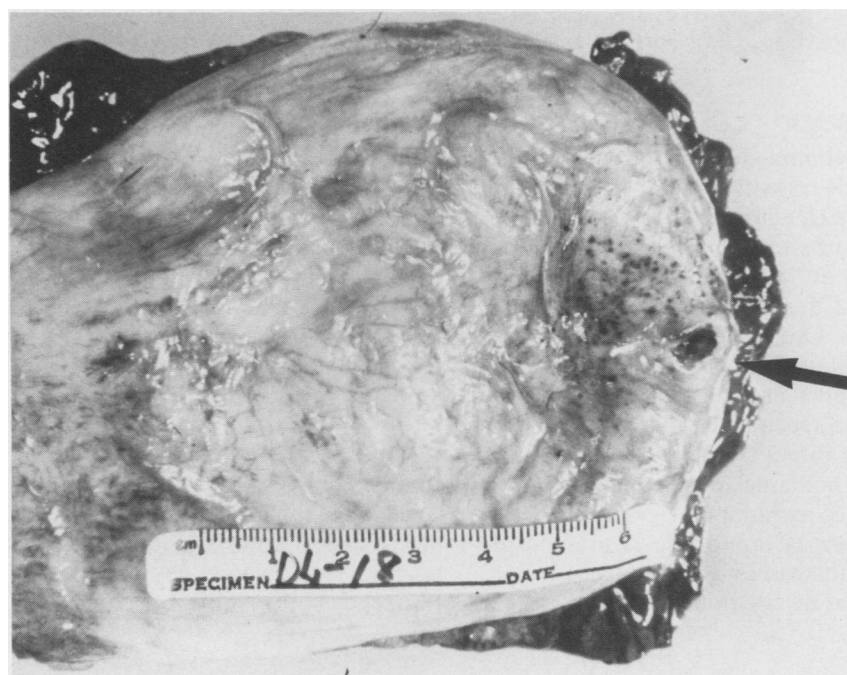

FIGURE 2. Urinary bladder. An ulcer, surrounded by petechial hemorrhages is seen at apex (arrow).

ments. The duodenal ampulla contained about fifty trematodes two to six centimeters long. An oval mass, 2 by 1 mm, composed of a thin capsule surrounding a white caseous center was observed on the serosal surface of the proximal intestine.

A circular ulcer, 2 mm in diameter with a hemorrhagic center and surrounded by petechial hemorrhages was observed at the apex of the urinary bladder on a slightly elevated mucosal patch (Figure 2). A 5 mm long nodule protruding from the left ureteral wall was located in the middle of a shallow, longitudinally oriented, dark red 2 cm long furrow.

About forty and ninety nematodes were found in the peribullar spaces of the left and right middle ears, respectively. The cranial end of the left zygomatic process of the temporal bone was partly replaced by an abundant yellow caseous material.

A dorsoventral radiograph of the head showed that the left supraorbital process of the frontal bone and the zygomatic process of the temporal bone were affected by a predominantly lytic reaction with multiple irregularly defined areas of increased bone density resulting in a granular appearance.

Microscopically, the skin invaginations consisted of crypts formed by the dermis and epidermis and evidence of inflammation was not observed. Autolysis prevented identification of the mass compressing the heart. Many foci of dense mature fibrous tissue were scattered in the lungs. The pulmonary nodules observed macroscopically were made of many conglomerates of cancerous cells. These cells had an acidophilic and finely granular cytoplasm with an irregular outline. Their large vesicular and pleomorphic nuclei had clumped and often margined chromatin. They showed one or two prominent acidophilic nucleoli. A few multinucleated giant cells were also seen (Figure 4). Occasional mitotic figures were observed.

Most of the nodules were surrounded by a thick fibrous capsule. The largest nodules seemed to be concentrated in the subpleural space and their centers were often necrotic. Atelectasis and thickened interalveolar septa were seen in the surrounding tissue (Figure 3). Moderate lymphocytic infiltration was seen in the

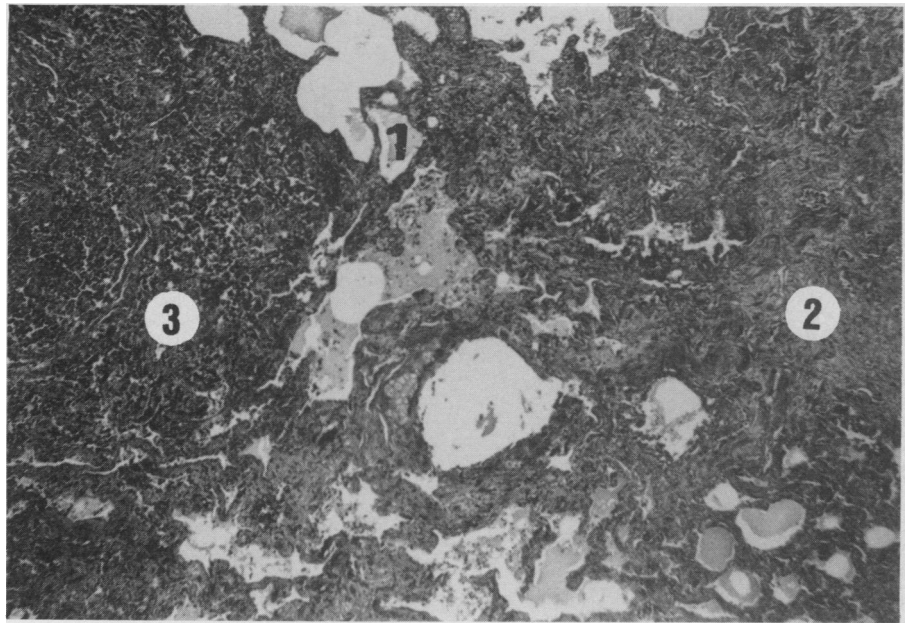


FIGURE 3. Lungs. Low magnification. A moderate quantity of acidophilic and homogeneous liquid is seen in the alveolar spaces (1). An area of dense mature and poorly vascularized fibrous tissue replaces the normal pulmonary architecture (2). A highly cellular metastasis is seen on the left (3). Masson's trichrome. X90.

nodules and in the pulmonary parenchyma.

The cancerous cells had invaded the walls of a few medium-sized vessels partly occluded by well organized thrombi containing the same pleomorphic cells (Figure 5). The presence

of adult female nematodes filled with larvae, and identified as *Pharurus pallasii* (8), elicited mild focal mononuclear cell infiltrations. Intimal proliferative fibrosis was seen in many small arterioles and extended into the medium-sized pulmonary arteries

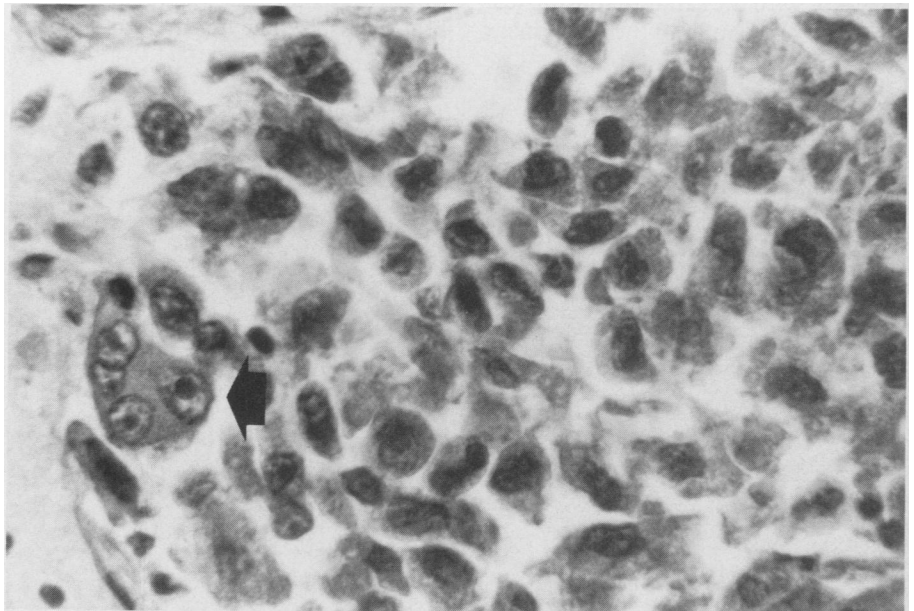


FIGURE 4. Lungs. Highly pleomorphic and poorly differentiated cells and giant multinucleated cells are seen in a metastatic focus (arrow). Note the prominent nucleoli in the giant cell nuclei. HPS. X900.

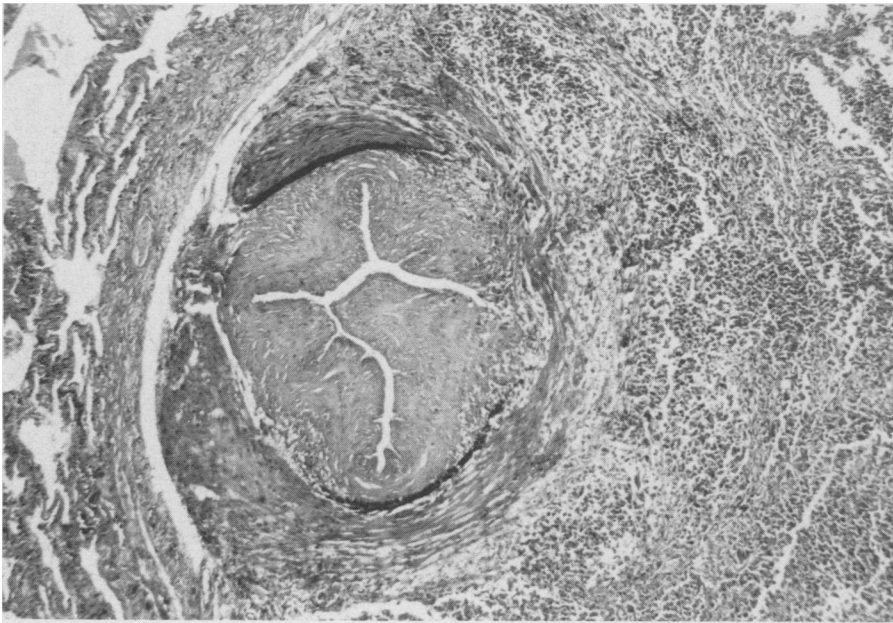


FIGURE 5. Lungs. Well organized and recanalized thrombus filling the lumen of a medium sized pulmonary artery. The wall is partly destroyed by a metastatic invasion. HPS. X90.

(200-500 μm in total diameter). The intimal proliferation was often papilliform.

The urinary bladder ulcer extended deep into the muscularis where it radiated smaller branches; these branches were surrounded by a thick capsule of dense connective tissue (Figure 6a). In the walls of the crypt and of its branches, there were nests of densely packed and highly pleomorphic cells with the same anaplastic features as those found in the pulmonary

nodules (Figure 6b). In addition, many goblet-type cells with unique, irregularly sized vacuoles containing a few large mucicarmine positive granules were seen. Occasional mitotic figures were also observed in the cellular nests of the crypt.

The ureteral nodule was in the lamina propria and in the muscularis. It was sharply demarcated from the surrounding tissues and subdivided by a fine fibrous stroma supporting small blood vessels. The nodule was slightly

infiltrated by lymphocytes and histiocytes and had essentially the same cellular composition as the pulmonary nodules (Figure 7). The subserosal nodule seen on the intestine had the same structure and composition as that of the ureteral one.

Mature, dense and well vascularized fibrous tissue composed the atheromatous plaque lying in the aortic intima. The underlying elastic lamellae were fragmented.

In the kidney, diffuse and slight thickening of the glomerular Bowman's capsule was seen. A few glomerular tufts were replaced or compressed by dense clumps of anaplastic cells (Figures 8a and 8b). Autolysis prevented interpretation of the mesenteric artery branch lesions and unfortunately, loss of the skull also prevented further histopathological diagnosis of the osseous lesions. The epithelium lining the peribullar space of the middle ear showed a dense mononuclear predominantly plasmocytic cellular infiltration.

The gastric ulcer consisted of an area of coagulation necrosis showing no evidence of inflammation.

Edwardsiella tarda was isolated in pure culture from the skull lesion and in large colonies from the spleen, mesenteric lymph node, urinary bladder and intestine. It was isolated in smaller colonies from kidneys, brain and gingiva.

Polychlorinated biphenyls and p.p' — DDE were found in the tissues

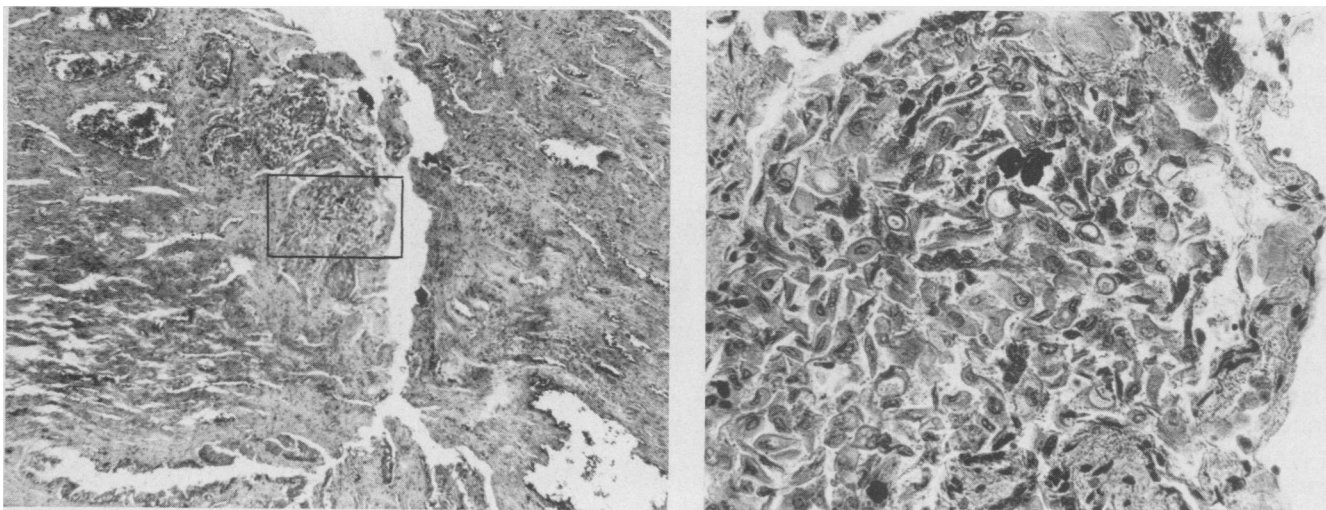


FIGURE 6. Bladder a) A crypt extends down into the muscularis. Solid nests of highly pleomorphic and poorly differentiated cells are lodged in the walls of the crypt. HPS. X90. b) Higher magnification of the framed area in a): solid nest of anaplastic cells. HPS. X571.

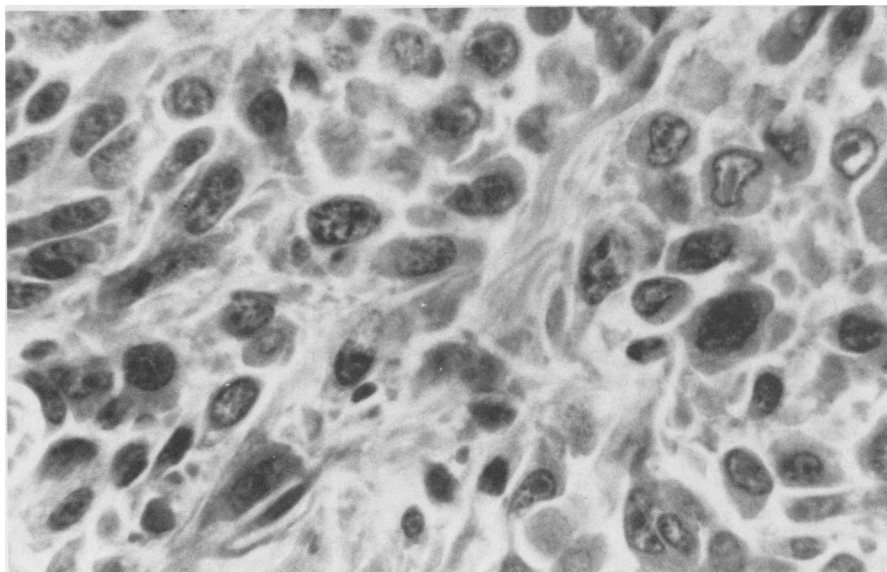

FIGURE 7. Ureteral metastasis. Note nuclear and cytoplasmic pleomorphism, prominent nucleoli and high nucleus:cytoplasm ratio. HPS. X900.

submitted to analysis. The results will be discussed in another paper. The research for B[a]P gave negative results.

DISCUSSION

Grossly this bladder tumor was non-papillary, infiltrating and had metastasized extensively. Histologically, it showed severe cellular anaplasia. According to Pamukcu's classification of urothelial tumors (9), this tumor was designated as a transitional cell carcinoma grade III. Tumors of the urinary bladder are rare in animals (9).

For instance, they account for less than 0.5% of dog tumors (10). However they are frequent in cattle, in different parts of the world, where they are attributed to the ingestion of bracken fern (*Pteridium aquilinum*). In the bovine species, which are phylogenetically related to cetaceans (11), epithelial tumors are the most common of all bladder tumors and transitional cell carcinomas occur most frequently. Infiltrating transitional cell carcinomas account for 21% of all primary carcinomas of the bladder in cattle (9).

An epidemiological study done by

Theriault *et al* (12) showed that the unusually high incidence of bladder neoplasm, seen in humans in the Chicoutimi area, at the origin of the Saguenay river, was associated with employment in an aluminium reduction plant. In a further study by the same workers (13) they concluded that exposure to polycyclic aromatic hydrocarbons estimated by the environmental benzo[a]pyrene concentrations seemed to be the causative factor.

On the other hand, Picard-Bérubé *et al* (6) found that blue oysters (*Mytilus edulis* L.) transplanted into the Saguenay river from a nonpolluted area had a posttransplantation tissular B[a]P concentration 200 times higher than their pretransplantation concentration.

Palmork *et al* (14) estimated that the European production of aluminium (3 millions tons a year) releases 150 tons of benzopyrene into the environment. Based on this estimation and on the annual production of aluminium of the Saguenay, Lac St-Jean area aluminium plants, Picard-Bérubé *et al* estimated the annual discharge of benzopyrene into this environment by these plants to be 20 tons (6). The total amount of anthropogenic PAH deposited in the sediments of the Saguenay river inner basin was estimated at 36 metric tons by Cossa (15, D. Cossa, personal communication, Institut français pour l'exploitation de la mer, B.P. 1049, rue de l'Île d'Yeu, 44037 Nantes Cedex, France). These figures were confirmed in a recent work (16) in which sediments of the Saguenay river were sampled at different depths and

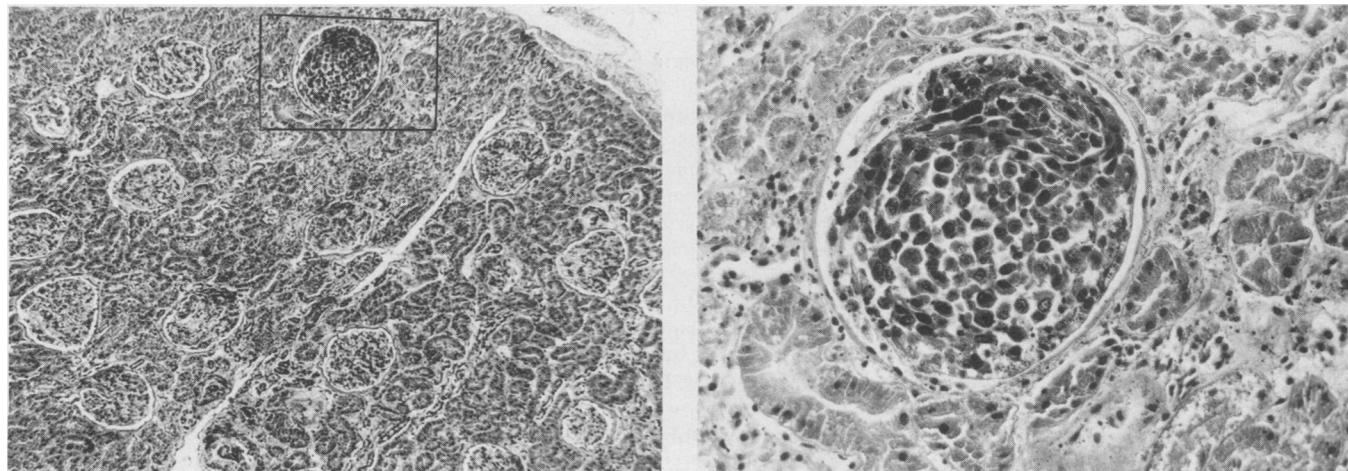


FIGURE 8. Kidney a) A glomerular tuft is replaced by metastatic cells. HPS. X143. b) Higher magnification of the affected glomerulus. HPS. X571.

locations and analysed for PAH: they revealed an increasing gradient of PAH concentrations towards the plants and an approximative annual deposition of PAH since 1940 (year the aluminium production started) of 0.5 to 1.5 tons, depending on the year.

Belugas feed partly on bottom invertebrates (17) and dive comfortably down to 400 meters (18). Consequently, PAH contamination is inevitable. However no PAH were found in various tissues of this beluga whale by mass spectrometry analysis and the failure to detect B[a]P can be rationalized on the basis of metabolic considerations: PAH have the capacity to induce the activity of the microsomal monooxygenase enzymes, namely hydrocarbon hydroxylase (19). Polycyclic aromatic hydrocarbons are also extensively metabolized by bacteria, fungi and algae (20). Their metabolic patterns in marine organisms are very similar to those reported in terrestrial species (21). Polycyclic aromatic hydrocarbons are relatively inert compounds which are activated by microsomal enzymes to carcinogenic and very short lived metabolites (22). So their rapid transformation into unstable metabolites by activated (or nonactivated) enzymes and postmortem bacterial proliferation and consecutive bacterial metabolism could explain our failure to detect PAH in the tissues of this whale.

Benzo[a]pyrene exposure has been consistently associated with higher risk of cancer in humans based on epidemiological studies and environmental contamination (23). The very few studies which determined tissular concentrations (24) required sophisticated technology such as high pressure liquid chromatography equipped with fluorescence detector since the detected amounts were extremely low (11 to 32 parts per trillion). The technique we used (GC/MS) would not have detected such minute amounts.

We cannot establish any relation between the high frequency of urinary bladder carcinoma in the human population of that area and this isolated case: more cases and an accurate determination of tissular PAH metabolites will be needed to attempt any conclusion. Even with determination of PAH levels, no comparison of such levels will be possible since B[a]P con-

centrations in humans of that area have not been determined.

Edwardsiella tarda causes enteritis in aquatic birds and hemorrhagic disease in fishes (25). It has been isolated also in healthy (26) and diseased (27) marine mammals where it was considered as an opportunistic invader. We believe this was the case in the present animal judging by the presence of a highly malignant transitional cell carcinoma.

ACKNOWLEDGMENTS

We wish to thank Dr. R. Higgins and his staff for the microbiological analysis and Miss G. Clément for typing the manuscript.

REFERENCES

1. HOWARD EB. Pathobiology of marine mammals disease. Vol 2. Boca Raton, Florida: CRC Press, 1983.
2. MIGAKI G, WOODARD JC, GOLDSTON RT. Renal adenoma in an Atlantic bottle-nosed dolphin (*Tursiops truncatus*). Am J Vet Res 1978; 39: 1920-1921.
3. SERGEANT DE, BRODIE PF. Identity, abundance and present status of populations of white whales, *Delphinapterus leucas*, in North America. J Fish Res Board Can 1975; 32: 1047-1054.
4. LANDY RB. A review of neoplasia in marine mammals (Pinnipedia and Cetacea). In: The comparative pathology of zoo animals. Washington: Smithsonian Institution Press, 1980: 579-584.
5. CHEVILLE NF. Cell Pathology, 2nd ed. Ames, Iowa: The Iowa State University Press, 1983.
6. PICARD-BERUBE M, COSSA D. Teneurs en Benzo 3.4 Pyrène chez *Mytilus edulis* L. de l'estuaire et du Golfe du Saint-Laurent. Marine Environ Res 1983; 10: 63-71.
7. SERGEANT DE. Biology of White Whales (*Delphinapterus leucas*) in Western Hudson Bay. J Fish Res Board Can 1973; 30: 1065-1090.
8. ARNOLD PW, GASKIN DE. Lungworms (Metastrongyloidea: Pseudaliidae) of harbor porpoise *Phocoena phocoena* (L. 1758). Can J Zool 1975; 53: 713-735.
9. PAMUKCU AM. Tumours of the urinary bladder. In: Bulletin of the world health organization, International histological classification of tumours of domestic animals. WHO Genève, 1974; 43-52.
10. CONZELMAN GM JR, MOULTON JE. Dose-response relationship of bladder tumorigen 2-naphtylamine: a study in Beagle dogs. J Natl Cancer Inst 1972; 49: 193-205.
11. SLIPPER EJ. Evolution and external appearance. In: Whales. Ithaca, New York: Cornell University Press, 1979: 58-92.
12. THERIAULT G, DE GUIRE L, CORDIER S. Reducing aluminium: An occupation possibly associated with bladder cancer. Can Med Assoc J 1981; 124: 419-425.
13. THERIAULT G, TREMBLAY C, CORDIER S, GINGRAS S. Bladder cancer in the aluminium industry. Lancet 1984; 1: 947-950.
14. PALMORK KH, WILHELMSSEN S, NEPPELBERG T. The contribution from various industries of polynuclear aromatic hydrocarbons to marine environment. Intern Council Expl Sea. Fisheries Improvement Commission, 1973; E:33.
15. COSSA D, MOINET A, PICARD M, PIUZE J, MICHEL P. Polycyclic aromatic hydrocarbons in the sediments of the Saguenay Fjord, Canada. In: Proceedings of the Joint Oceanographic Assembly, Dalhousie University Halifax, N.S., 1982.
16. MARTEL L. Analyse spatio-temporelle des hydrocarbures polycycliques aromatiques (HPA) dans les sédiments du fjord du Saguenay, Québec. Thesis. Université du Québec à Chicoutimi. Chicoutimi, Québec, Canada, 1985.
17. VLADYKOV VD. Chasse et biologie du marsouin blanc. Fisheries Department, Province of Quebec, 1944.
18. RIDGWAY SH, BOWERS CA, MILLER D, SCHULTZ ML, JACOBS CA, DOOLEY CA. Diving and blood oxygen in the white whale. Can J Zool 1984; 62: 2349-2351.
19. PARKINSON A, SAFE S. Aryl hydrocarbon hydroxylase induction and its relationship to the toxicity of halogenated aryl hydrocarbons. Toxicol Environ Chem Rev 1981; 4: 1-46.
20. CERNIGLIA CE. Aromatic hydrocarbons: metabolism by bacteria, fungi and algae. Rev Biochem Toxicol 1982; 3: 321-361.
21. STEGEMAN JJ. Polynuclear aromatic hydrocarbons and their metabolism in the marine environment. In: Polycyclic hydrocarbons and cancer. Vol 3. New York: Academic Press, 1981: 1-60.
22. LEVIN W, WOOD A, CHANG R *et al*. Oxidative metabolism of polycyclic aromatic hydrocarbons to ultimate carcinogens. Drug Metab Rev 1982; 13: 555-580.
23. LINDSTEDT G, SOLLENBERG J. Polycyclic aromatic hydrocarbons in the occupational environment. Scand J Work Environ Health 1982; 8: 1-19.
24. OBANA H, HORI S, KASHIMOTO T, KUNITA N. Polycyclic aromatic hydrocarbons in human fat and liver. Bull Environ Contam Toxicol 1981; 27: 23-27.
25. WHITE FH, SIMPSON CF. Isolation of *Edwardsiella tarda* from aquatic animal species and surface waters in Florida. J Wildl Dis 1973; 9: 204-207.
26. JOHNSTON DG, FUNG J. Bacterial flora of wild porpoises, seals and sea lions of Pacific coastal waters. Proc. 7th Conf on Biological Sonar and Diving Mammals, 1970.
27. COLES BM, STROUD RK, SHEGGEYS S. Isolation of *Edwardsiella tarda* from three Oregon sea mammals. J Wildl Dis 1978; 14: 339-341.