

Cosegregation of Elastin-associated Microfibrillar Abnormalities with the Marfan Phenotype in Families

Maurice Godfrey,^{*,†,1} Victor Menashe,[‡] Richard G. Weleber,^{§,||} Robert D. Koler,^{||}
Robert H. Bigley,^{||,#} Everett Lovrien,^{||} Jonathan Zonana,^{||} and David W. Hollister^{*,†,#,2}

*Portland Unit, Shriners Hospitals for Crippled Children, and Departments of †Biochemistry and Molecular Biology, ‡Pediatrics, §Ophthalmology, ||Medical Genetics, and #Medicine, Oregon Health Sciences University, Portland

Summary

The Marfan syndrome is a serious heritable connective-tissue disorder characterized primarily by ocular, cardiovascular, and musculoskeletal abnormalities but also involving multiple other tissues and organs of the body. Inherited as an autosomal dominant disorder, the etiology and pathogenesis of the Marfan syndrome are presently unknown. We have documented consistent apparent deficient content of elastin-associated microfibrillar fibers by indirect immunofluorescent (IF) studies of Marfan skin, as well as deficient accumulation of related fibrous materials in cultures of Marfan fibroblasts as compared with normal controls and patients with other heritable disorders of connective tissue. These data have suggested that abnormalities in the microfibrillar component of elastic-fiber systems may have a role in the etiology and pathogenesis of the Marfan syndrome. In the present study, we have analyzed the IF staining patterns of skin and fibroblast cultures from Marfan syndrome patients and normal first-degree relatives in nine Marfan kindreds. Three of these families had at least one affected individual in each of 2 generations, permitting intergenerational comparison of IF patterns. Six kindreds had one or more affected individuals in a single generation, making comparisons between siblings and/or parent-child possible. In all cases, IF abnormalities cosegregated with the Marfan phenotype and all nonaffected family members were normal. Within family groups containing more than one affected individual, the IF staining patterns were similar between affected patients. These data provide further confirmation of consistent and relatively specific deficiency of microfibrillar fibers in Marfan syndrome.

Introduction

The Marfan syndrome is a dominantly inherited pleiotropic connective-tissue disorder with nearly complete penetrance but variable expressivity in affected individuals. In the absence of specific diagnostic laboratory findings, recognition of the Marfan syndrome has been based on characteristic phenotypic features, the

results of ophthalmologic and echocardiographic evaluations, and family history (Beighton et al. 1988). For the "classic" case of the Marfan syndrome, the ocular manifestations include subluxation of the lens (ectopia lentis), myopia, and, occasionally, retinal detachment. The musculoskeletal findings include tall stature, long thin extremities (dolichostenomelia), arachnodactyly, joint laxity, chest and spine deformities, and, occasionally, congenital contractures. The cardiovascular manifestations consist principally of progressive dilatation of the aortic root and ascending aorta and mitral valve prolapse leading to aortic regurgitation, aneurysms, dissections, and mitral regurgitation. About 85% of patients succumb to cardiovascular complications of their disease, and median life span is between one-half and two-thirds of normal. Additional findings in the Marfan syndrome include striae distensae, inguinal hernia,

Received September 28, 1989; revision received December 1, 1989.

1. Present address and address for correspondence and reprints: Munroe Center for Human Genetics/Meyer Rehabilitation Institute, Departments of Pediatrics and Pathology, University of Nebraska Medical Center, 444-44th Street, Omaha, NE 68131-3795.

2. Present address: Munroe Center for Human Genetics/Meyer Rehabilitation Institute, Departments of Pediatrics and Pathology, University of Nebraska Medical Center, Omaha.

© 1990 by The American Society of Human Genetics. All rights reserved.
0002-9297/90/4604-0004\$02.00

spontaneous pneumothorax, and dural ectasia (McKusick 1972; Pyeritz and McKusick 1979; Maumenee 1981; Pyeritz 1983, 1986; Pyeritz et al. 1988).

The cause(s) of Marfan syndrome remains obscure despite research extending over decades. Pathologic studies, in general, have implicated abnormalities of the elastin-fiber systems in blood vessels (Saruk and Eisenstein 1977; Perejda et al. 1985; Takebayashi et al. 1988) and skin (Tsuiji 1986), but it has been unclear whether these morphologic abnormalities are primary or secondary. Major components of connective tissue, such as the collagens and elastin, have been studied in the Marfan syndrome. Candidate-gene-linkage approaches for the major fibrillar collagens (types I–III) (Tsipouras et al. 1986; Dalgleish et al. 1987; Ogilvie et al. 1987; Francomano et al. 1988) have effectively eliminated linked regulatory or primary structural defects of these proteins as a major cause of Marfan syndrome, and more limited studies for elastin have also been negative to date (Rosenbloom 1984; Huttunen et al. 1989). The significance of reported defects in the Marfan syndrome, such as increased synthesis of hyaluronic acid from fibroblasts (Lamberg and Dorfman 1973; Appel et al. 1979) or decreased collagen cross-linking (Boucek et al. 1981), is presently unclear.

We have examined the microfibrillar fibers accumulating in Marfan skin and produced by cultured Marfan syndrome fibroblasts by indirect immunofluorescence (IF) using several monoclonal antibodies against fibrillin, a major structural protein of microfibrils (Hollister et al. 1985; Sakai et al. 1986). In both Marfan skin and fibroblast cultures, deficient accumulation, and/or production and assembly of immunoreactive fibrous components has been consistently observed. In a large *single-blind* study performed without knowledge of clinical findings, 24 of 27 patients with classical features of the Marfan syndrome were correctly identified, whereas 13 of 13 normal controls and 19 of 25 patients with other heritable disorders of connective tissue were identified as non-Marfan by these assays (Hollister et al., submitted). An unusual patient with unilateral manifestations of the Marfan syndrome (Burgio et al. 1988) has also been studied; remarkably, skin and derived fibroblasts from the clinically affected side of the body were dramatically deficient in microfibrillar antigen as compared with the clinically nonaffected side (Godfrey et al. 1990). No evidence for antigenic masking was observed in these studies using various enzymatic digestions to “unmask” potentially blocked epitopes and two different monoclonal antibodies directed at different domains of the fibrillin molecule.

Given the role of microfibrillar fibers in the ontogeny of elastic-fiber systems, their presumed structural role(s) with or without amorphous elastic fibers, and, particularly, the codistribution of microfibrils within those tissues affected in Marfan syndrome, these data suggest a plausible hypothesis that functional incompetence of microfibrillar fibers may be important in the pathogenesis of this disease. If this is the case, both cosegregation of microfibrillar fiber abnormalities with the Marfan phenotype and a relatively uniform expression of microfibrillar fiber abnormalities within families is expected. In the present communication, we provide evidence for such cosegregation and uniformity.

Material and Methods

Patient Materials

Patients and families were indexed through and examined in the Genetics Clinic of the Child Development and Rehabilitation Center of the Oregon Health Sciences University, and ophthalmologic and echocardiographic evaluations were obtained. After informed consent was obtained, 5–6-mm skin-punch biopsies were obtained from the inner aspect of the arm and were divided for fibroblast explant (culture media) or indirect IF studies (samples frozen in -20°C hexanes).

Fibroblast Studies

Fibroblasts derived from patients, relatives, and controls were maintained in Dulbecco's modified Eagle medium (DMEM) supplemented with 10% FCS and 1% penicillin/streptomycin (all from Gibco). To visualize the prominent fibrous meshwork of immunoreactive materials which assemble during cell culture, confluent monolayers were fixed and then incubated with monoclonal antibody to the microfibrillar protein, fibrillin (Hollister et al. 1985; Sakai et al. 1986), and bound antibody was detected with goat anti-mouse IgG antisera conjugated with phycoerythrin (Biomed, Foster City, CA). Cell nuclei were visualized with propidium iodide. These methods are detailed in the accompanying paper (Godfrey et al. 1990). Controls included monolayers incubated with hybridoma culture media lacking primary antibody or with PBS lacking secondary antibody. Fluorescence was viewed on a Zeiss Photoscope III using an FITC filter set and barrier filter passing wavelengths >520 nm, and photographs were obtained using high-speed Ektachrome film (Kodak) with 15-s exposures. The E_{max} of phycoerythrin is 575 nm (yellow-gold), and that of propidium io-

dide is 639 nm (pink-red); both fluors may be visualized simultaneously.

Skin Studies

To visualize the prominent meshwork of microfibrillar fibers in papillary and reticular dermis, hexane-stored skin biopsies were thawed, oriented, and refrozen in Tissue Tek mounting media (Miles Laboratories), and 15-micron cryo-sections were obtained on a Leitz 1720 Kryostat. Sections were air-dried on poly-L-lysine-coated slides and were fixed, stained, and photographed as noted above and more fully described in the accompanying paper (Godfrey et al. 1990).

Results

Clinical information and the results of skin and fibroblast assays for apparent content of immunoreactive microfibrillar fiber components are summarized for three families, in table 1. In each family, at least one individual in each of 2 generations meets the established criteria for Marfan syndrome (Beighton et al. 1988). In family 1, the mother and three of four children (one deceased with an aortic dissection) had the Marfan syn-

drome. These individuals, but not the nonaffected father and nonaffected child, demonstrate apparent decreased content of immunoreactive microfibrillar fibers accumulating in skin and produced and/or assembled by cultured fibroblasts. Figure 1 depicts the observed cell-culture indirect-IF patterns found in individuals from this family. It is apparent that there is a strikingly deficient accumulation of reactive fibrous materials in those individuals with the clinical diagnosis of the Marfan syndrome (patients I-2, II-2, and II-3), whereas the nonaffected kindred members (I-1 and II-4) exhibit substantial production and accumulation of fibrous materials. Relative cell number, an important determinant of microfibrillar accumulation in cell culture, is approximately equal, as determined by visualization of nuclei with propidium iodide. These IF cell-culture results are highly reproducible in multiple independent assays.

In contrast to family 1, the affected individuals in family 2 exhibit only decreased cell-culture production and/or assembly of microfibrillar fibers; the apparent content of such fibers in skin was not significantly different from that in normal controls (data not shown). These findings are consistent with previous studies (Hol-

Table 1

Clinical Features and IF Results in Three Marfan Kindreds with Affected Individuals in 2 Generations

INDIVIDUAL	AGE (years)	SEX	DIAGNOSIS ^a	CLINICAL MANIFESTATION ^b				MICROFIBRILS ^c	
				Skeletal	Aortic Dilatation	Mitral Valve Prolapse	Ectopia Lentis	Culture	Skin
Family 1:									
Father	65	M	NL	-	ND	ND	ND	WNL	WNL
Mother	52	F	MS	+	+	+	-	DEC	DEC
Child 1	21	F	MS	-	+	+	-	Deceased ^d	
Child 2	21	M	MS	+	+	-	+	DEC	DEC
Child 3	20	M	MS	+	+	+	+	DEC	DEC
Child 4	18	F	NL	-	-	-	-	WNL	WNL
Family 2:									
Father	38	M	MS	+	+	-	+	DEC	WNL
Mother	33	F	NL	-	ND	ND	ND	WNL	WNL
Child 1	9	M	MS	-	+	-	+	DEC	WNL
Child 2	7	M	MS	-	+	+	+ / -	DEC	WNL
Child 3	2	F	MS	-	-	+	ND	DEC	WNL
Family 3:									
Father	36	M	MS	+	+	-	+	DEC	DEC
Mother	38	F	NL	-	ND	ND	ND	WNL	WNL
Child 1	4	F	MS	+	+	-	+	DEC	DEC

^a MS = Marfan syndrome; NL = clinically normal.
^b ND = not determined.
^c DEC = decreased; WNL = within normal limits.
^d Aortic dissection.

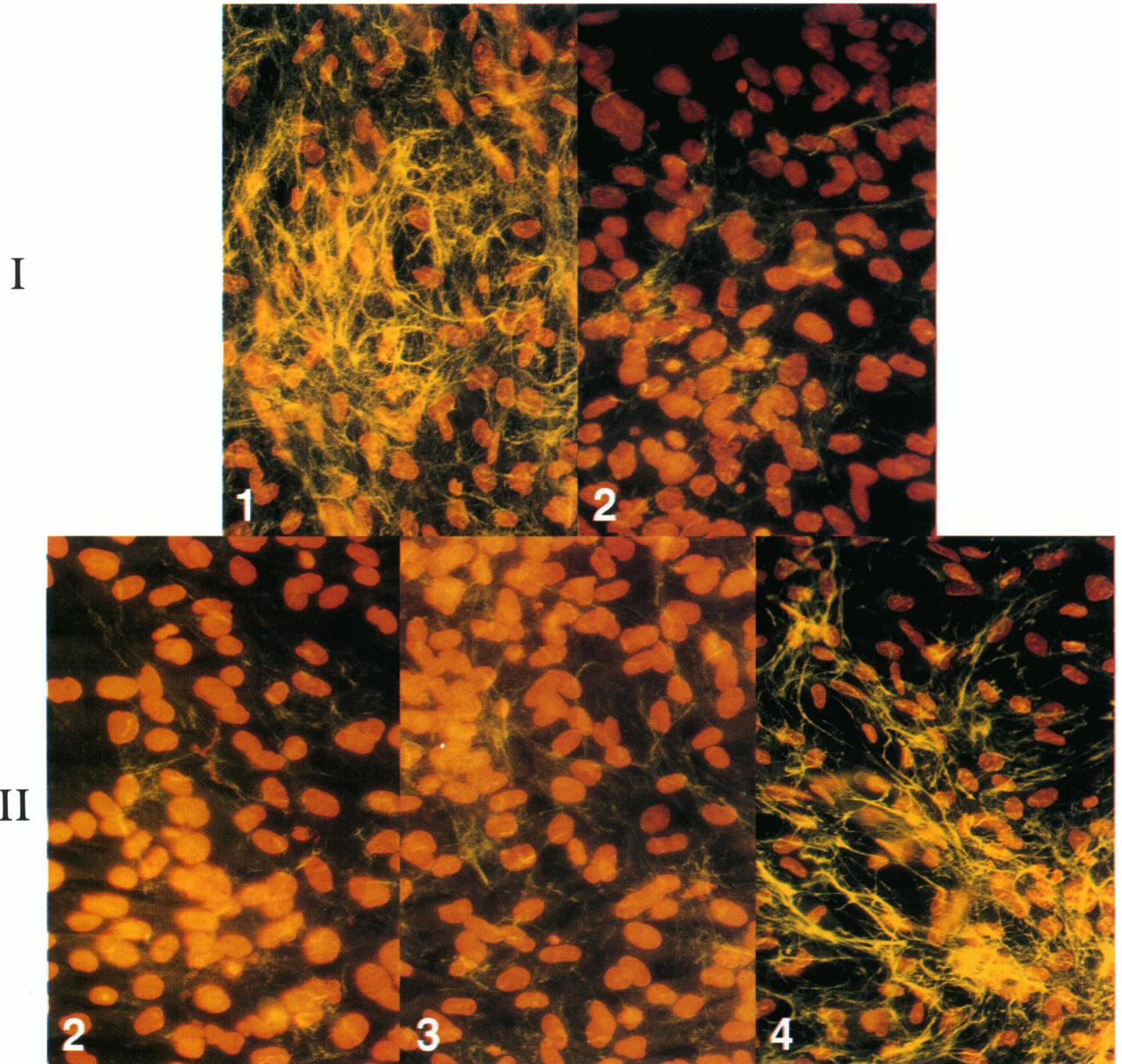
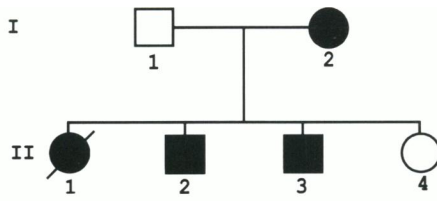


Figure 1 Pedigree and IF analysis of microfibril fibers accumulating in hyperconfluent fibroblast cultures from individuals in family 1. The photomicrographs are arranged in correspondence with the pedigree above. The unaffected father (I-1) and daughter (II-4) exhibit normal deposition of immunostainable fibrous material, whereas the Marfan syndrome-affected mother (I-2) and sons (II-2 and II-3) display markedly reduced accumulation of microfibrillar fibers. Fibroblast nuclei are counterstained with propidium iodide. ($\times 113$)

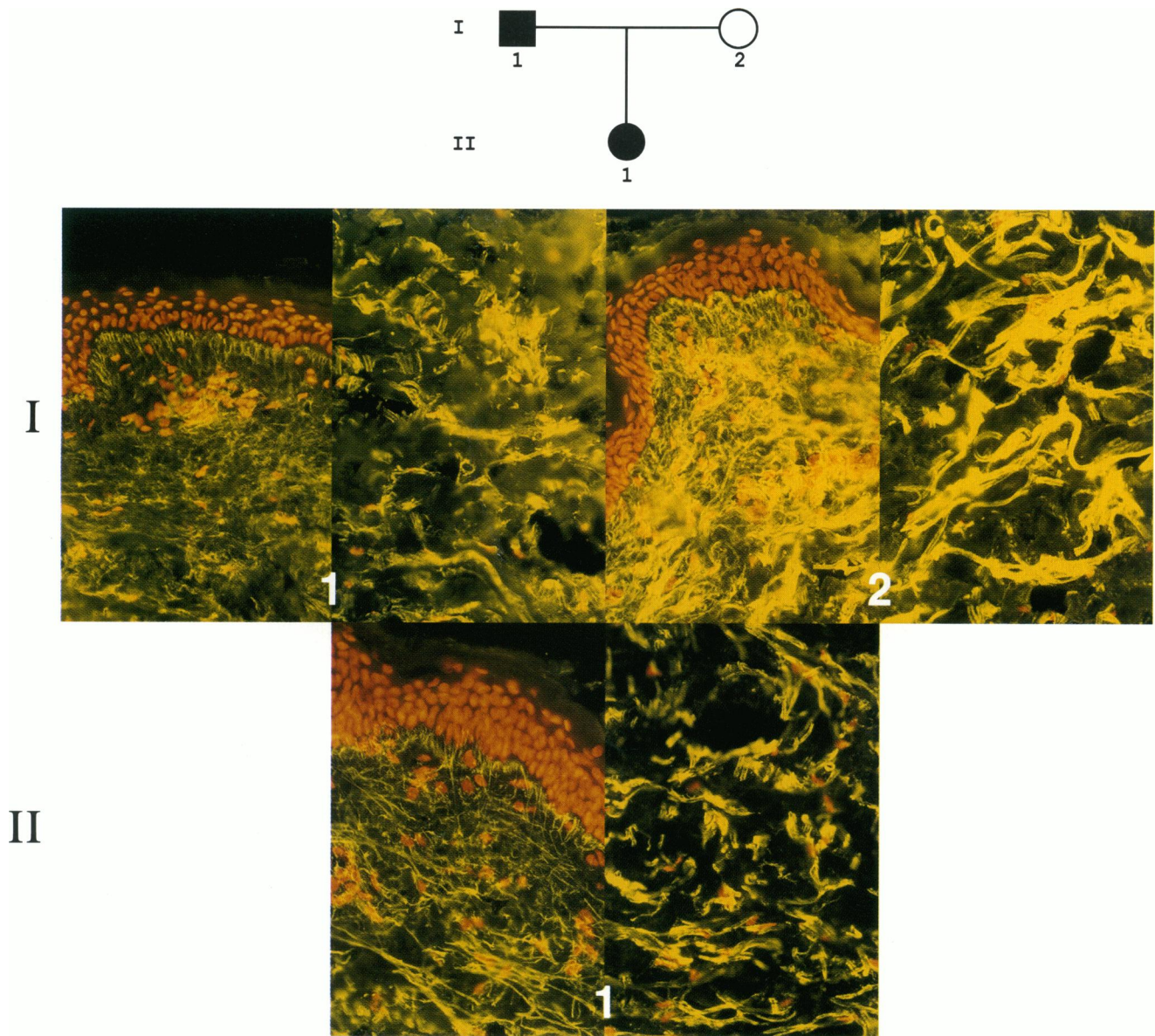


Figure 2 Pedigree and dermal IF analysis of skin from individuals in family 3. For each individual, the papillary (*left*) and reticular (*right*) dermis are shown. The affected father (I-1) and daughter (II-1) display apparent diminished staining at the dermal/epidermal junction, in the papillary dermis, and associated with elastin fibers in the reticular dermis. The unaffected mother (I-2) displays a normal pattern of reactivity with the antibody. Fibroblast nuclei are counterstained with propidium iodide. ($\times 109$)

lister et al., submitted), in which approximately 30% of individuals with classic features of the Marfan syndrome exhibited equivocal or normal skin IF patterns despite clearly reduced cell-culture production and accumulation of immunoreactive materials.

Family 3, like family 1, exhibits deficient microfibrillar fibers in both culture and skin assays. Figure 2 illustrates the observed microfibrillar fibers in papillary and

reticular dermis for these individuals. In comparison with the nonaffected mother, both the father and daughter have apparent decreased contents of microfibrillar fibers in both papillary and reticular dermis.

To complement and extend these studies, IF studies of affected and nonaffected family members were performed in six kindreds in which intergenerational comparisons of Marfan syndrome-affected individuals were

not possible. These comparisons included siblings, siblings plus one or both parents, and parent-child pairs. Table 2 lists the clinical features and results of IF studies of these 16 additional patients. In all cases, clinically normal individuals (i.e., without stigmata of the Marfan syndrome) yielded normal results in both skin and fibroblast assays. Three Marfan patients exhibited decreased IF patterns in both assays, two patients had decreased production and/or assembly of microfibrillar fibers in fibroblast culture but normal skin findings, and one patient demonstrated the converse.

Discussion

Three distinct patterns of apparent deficiency of microfibrillar fibers have been observed in skin and dermal fibroblasts derived from patients with the Marfan syndrome. The most prevalent of these patterns, occurring in approximately 70% of patients with classic features of the Marfan syndrome, is diminished apparent content of immunostainable fibers in papillary and reticular dermis and decreased production and/or as-

sembly of related fibrous materials by cultured fibroblasts (Hollister et al., submitted). In the present study, nine (56%) of 16 Marfan patients exhibited this pattern. In a significant fraction (approximately 30%) of patients, the apparent content of microfibrillar fibers in skin is either equivocal or within the normal range, whereas fibroblast studies demonstrate clearly decreased accumulations of fibrous materials (Hollister et al., submitted). This pattern was observed in six (38%) of 16 Marfan patients in the present study. Rarely, the converse is true, namely, deficient apparent content of microfibrillar fibers in skin while fibroblast studies appear normal. One such unusual individual (a 5-year-old girl) with this latter pattern was identified in the large single-blind study of 27 Marfan syndrome patients, and an additional individual (a 56-year-old male) has been encountered in the present study; altogether, two (5%) of 44 Marfan syndrome patients studied to date have exhibited this unusual pattern. We have observed only one patient with classic features of the Marfan syndrome whose skin and fibroblast assays were normal; it is interesting that this patient's fibroblasts

Table 2

Clinical Features and IF Results in Six Partial Marfan Kindreds with Affected Individuals in a Single Generation

INDIVIDUAL	AGE (years)	SEX	DIAGNOSIS	FAMILY HISTORY	CLINICAL MANIFESTATION				MICROFIBRILS		
					Skeletal	Aortic Dilatation	Mitral Valve Prolapse	Ectopia Lentis	Culture	Skin	
Family 4:											
Sibling 1	49	F	MS	+	+	+	+	+	DEC	DEC	
Sibling 2	46	F	MS	+	+	ND	ND	+	DEC	DEC	
Family 5:											
Mother	41	F	NL	-	-	ND	ND	ND	WNL	WNL	
Father	45	M	NL	-	-	ND	ND	ND	WNL	WNL	
Child 1	21	F	MS	-	+	+	+/-	+	DEC	WNL	
Child 2	19	F	NL	+	-	ND	ND	ND	WNL	WNL	
Child 3	14	F	NL	+	-	-	-	-	WNL	WNL	
Family 6:											
Sibling 1	17	M	NL	+	-	-	-	-	WNL	WNL	
Sibling 2	15	M	MS	+	+	+	+	+	DEC	DEC	
Sibling 3	12	M	NL	+	-	-	-	-	WNL	WNL	
Family 7:											
Mother	59	F	NL	-	-	ND	ND	-	WNL	WNL	
Child 1	23	F	MS	+	+	+	-	+	DEC	WNL	
Family 8:											
Father	56	M	MS	+	-	+	-	-	WNL	DEC	
Child 1	27	F	NL	+	-	-	-	-	WNL	WNL	
Family 9:											
Mother	57	F	MS	-	+	+	-	+	DEC	ND	
Child 1	13	M	NL	+	-	-	-	-	WNL	WNL	

NOTE.—Abbreviations are as in table 1.

produced an abnormally slowly migrating pro α 2(I) and α 2(I) chain of type I collagen (D. W. Hollister, V. H. Rao, and M. Godfrey, unpublished data) quite similar to that previously observed for an atypical Marfan patient (Byers et al. 1981).

In the present study, all 16 Marfan patients had typical abnormalities by skin and/or fibroblast assay, and, in the previous single-blind study, 24 of 25 Marfan patients also exhibited diminished IF in one or both assays (when two patients studied by skin assay alone and found to be normal are excluded). These data demonstrate that, for the vast majority of typical Marfan patients, deficiency of *in vivo* accumulation—and/or deficiency of *in vitro* production and/or assembly of microfibrillar fibers—is a consistent and specific immunohistologic feature. The varying patterns of IF observed in skin and fibroblast assays presumably reflect an underlying molecular heterogeneity in the Marfan syndrome.

Significantly, 13 of 13 nonaffected (normal) relatives of patients with the Marfan syndrome were found to be normal by both skin and fibroblast assays, and therefore these assays serve to distinguish affected from nonaffected first-degree relatives. These data are consonant with the previous single-blind study, in which 13 of 13 normal volunteers with no stigmata of connective-tissue disease were found to be normal in all assays performed (Hollister et al., submitted).

The data presented here document complete and specific cosegregation of IF abnormalities of skin, cultured fibroblasts, or both with the Marfan phenotype within families. Moreover, the data indicate that the specific pattern of IF abnormality also segregates within families; for example, there may be either abnormalities of both assays or abnormalities of fibroblast assay but normal skin assay (compare kindreds in table 1 and siblings in table 2).

Microfibrillar fibers are composed of bundles of 10–12-nm, slender, slightly beaded microfibrils originally identified by association with amorphous elastin (Low 1962). The molecular composition of such microfibrils is presently unclear but appears to include several other structural glycoproteins in addition to fibrillin (Serafini-Fracassini 1981; Streeten et al. 1983; Gibson et al. 1986; Colombatti et al. 1988; Mecham et al. 1988).

Microfibrillar fibers are widely distributed in human tissues, including those tissues manifesting pathologic alterations in the Marfan syndrome such as ciliary zonules (suspensory ligaments) of the lens, aorta, major blood vessels, pleura, dura, skin, perichondrium, and

periosteum. The fibers form a variety of structures including rod-like cylinders, sheets or lamellae, and branching meshworks. Substantial evidence indicates that these fibers serve as the scaffolding for elastin deposition during embryonic elastogenesis (for reviews, see Cleary and Gibson 1983; Cleary 1987). Thus, in many tissues, microfibrillar fibers, in whole or in part, are enveloped in amorphous elastin and become integral components of recognizable elastic structures. Examples include the aorta, in which concentric lamellae of fibers become completely invested with elastin, and the skin, in which only the deeper portions of the continuous fibrous meshwork become invested with elastin (producing dermal elastic fibers). Microfibrillar fibers are more extensively distributed than ultrastructurally recognizable amorphous elastic elements, and they may exist with little or no associated elastin (Sakai et al. 1986; Cleary 1987). For example, the rod-like microfibrillar fibers which compose the ciliary zonules of the lens do not contain recognizable elastin (Raviola 1971).

In addition to serving possible structural and organizing roles within elastic tissues, microfibrillar fibers interconnect elastic elements with other connective-tissue structures (e.g., basement membrane) (Cotta-Pereira et al. 1976) and, in some tissues (e.g., ciliary zonules), appear to have a primary structural role independent of elastin. The biophysical properties of microfibrillar fibers are unknown, but clinical observations indicate that ciliary zonular fibers exhibit moderate elastic recoil after stretching (Steeten 1986). Both elongated or stretched and broken ciliary zonular fibers are consistently found in the ectopia lentis of the Marfan syndrome (Maumenee 1981), an observation which argues that these microfibrillar fibers are functionally incompetent to resist normal stress; some patients develop ectopia lentis over time, suggesting that progressive elongation and eventual breakage of microfibrillar fibers occurs. This model provides a plausible explanation for the pleiotropic manifestations of the Marfan syndrome, e.g., progressive dilatation of the proximal aorta with disruption of elastic lamellae of the tunica media, striae distensae of skin, dural ectasia, and so forth. Skeletal overgrowth may be the result of diminished forces generated by Marfan periosteal and perichondreal membranes opposing bone growth (see McKusick 1972). Presumably, such functional incompetence could result from deficiency of microfibrillar fibers, biomechanical incompetence of deposited fibers, and/or alterations in other role(s) of microfibrils, such as orientation of elastin for polymerization.

The data recorded here and elsewhere (Godfrey et

al. 1990; Hollister et al., submitted) imply that structural microfibrillar glycoproteins are potential candidates for the defective gene product(s) underlying the Marfan syndrome.

Acknowledgments

We thank Donna Gaudette for invaluable technical support and Carmen Weber and the clinical staff of the Genetics Clinic, Child Development and Rehabilitation Center, for skilled clinical support. We thank Dr. Lynn Sakai for provision of monoclonal antibodies to fibrillin. We are grateful to Biomedica Corporation, Foster City, CA, for the gift of phycoerythrin-conjugated antisera. This work was supported by a Shriners Hospitals of North America grant to D.W.H.

References

- Appel A, Horwitz AL, Dorfman A (1979) Cell-free synthesis of hyaluronic acid in Marfan syndrome. *J Biol Chem* 254:12199-12203
- Beighton P, DePaepe A, Danks D, Finidori G, Gedde-Dahl T, Goodman R, Hall JG, et al (1988) International nosology of heritable disorders of connective tissue, Berlin, 1986. *Am J Med Genet* 29:581-594
- Boucek RJ, Noble NL, Gunja-Smith Z, Butler WT (1981) The Marfan syndrome: a deficiency in chemically stable collagen cross-links. *N Engl J Med* 305:988-991
- Burgio RG, Martini A, Cetta G, Zanaboni G, Vitellaro L, Danesino C (1988) Asymmetric Marfan syndrome. *Am J Med Genet* 30:905-909
- Byers PH, Siegel RC, Peterson KE, Rowe DW, Holbrook KA, Smith LT, Chang Y-H, et al (1981) Marfan syndrome: abnormal $\alpha 2$ chain in type I collagen. *Proc Natl Acad Sci USA* 78:7745-7749
- Cleary EG (1987) The microfibrillar component of the elastic fibers: morphology and biochemistry. In: Uitto J, Perejda AJ (eds) *Connective tissue disease: molecular pathology of the extracellular matrix*. Marcel Dekker, New York, pp 55-81
- Cleary EG, Gibson MA (1983) Elastin-associated microfibrils and microfibrillar proteins. *Int Rev Connect Tissue Res* 10:97-209
- Colombatti A, Bonaldo P, Volpin D, Bressan GM (1988) The elastin-associated glycoprotein gp115. *J Biol Chem* 263:17534-17540
- Cotta-Pereira G, Rodrigo FG, Bittencourt-Sampaio S (1976) Oxytalan, elaunin, and elastic fibers in the human skin. *J Invest Dermatol* 66:143-148
- Dalgleish R, Hawkins JR, Keston M (1987) Exclusion of the alpha 2(I) and alpha 1(III) collagen genes as the mutant loci in a Marfan syndrome family. *J Med Genet* 24:148-151
- Francomano CA, Streeten EA, Meyers DA, Pyeritz RE (1988) Marfan syndrome: exclusion of genetic linkage to three major collagen genes. *Am J Med Genet* 29:457-462
- Gibson MA, Hughes JL, Fanning JD, Cleary EG (1986) The major antigen of elastin-associated microfibrils is a 31-kDa glycoprotein. *J Biol Chem* 261:11429-11436
- Godfrey M, Olson S, Burgio RG, Martini A, Valli M, Cetta G, Hori H, et al (1990) Unilateral microfibrillar abnormalities in a case of asymmetric Marfan syndrome. *Am J Hum Genet* 46:661-671
- Hollister DW, Godfrey M, Sakai LY, Pyeritz RE. Marfan syndrome: immunohistochemical abnormalities of the microfibrillar fiber system (submitted)
- Hollister DW, Sakai LY, Burgeson RE (1985) Identification of novel human basement membrane zone components by monoclonal antibodies. In: Fleischmajer R, Olsen BR, and Kuhn K (eds) *Biology, chemistry, and pathology of collagen*. Annals of the New York Academy of Sciences, New York, pp 449-452
- Huttunen K, Kaitila I, Savolainen A, Palotie A, Peltonen L (1989) The linkage analysis with RFLP markers of elastin and type III collagen genes in Finnish Marfan families. *Am J Med Genet* 32:244
- Lamberg SI, Dorfman A (1973) Synthesis and degradation of hyaluronic acid in the cultured fibroblasts of Marfan's disease. *J Clin Invest* 52:2428-2433
- Low FN (1962) Microfibrils: fine filamentous components of the tissue space. *Anat Rec* 142:131-137
- McKusick VA (1972) *Heritable disorders of connective tissue*, 4th ed. Mosby, Saint Louis
- Maumenee IH (1981) The eye in the Marfan syndrome. *Trans Am Ophthalmol Soc* 79:684-733
- Mecham RP, Hinek A, Cleary EG, Kucich U, Lee SJ, Rosenbloom J (1988) Development of immunoreagents to ciliary zonules that react with protein components of elastic fiber microfibrils and with elastin-producing cells. *Biochem Biophys Res Commun* 151:822-826
- Ogilvie DJ, Wordsworth BP, Priestley LM, Dalgleish R, Schmidtke J, Zoll B, Sykes BC (1987) Segregation of all four major fibrillar collagen genes in the Marfan syndrome. *Am J Hum Genet* 41:1071-1082
- Perejda AJ, Abraham PA, Carnes WH, Coulson WF, Uitto J (1985) Marfan's syndrome: structural, biochemical, and mechanical studies of the aortic media. *J Lab Clin Med* 106:376-383
- Pyeritz RE 1983. Marfan syndrome. In: Emery AEH, Rimoin DL (eds) *Principles and practice of medical genetics*. Churchill Livingstone, Edinburgh, pp 820-835
- 1986 The Marfan syndrome. *Am Fam Physician* 34:83-94
- Pyeritz RE, Fishman EK, Bernhardt BA, Siegelman SS (1988) Dural ectasia is a common feature of the Marfan syndrome. *Am J Hum Genet* 43:726-732
- Pyeritz RE, McKusick VA (1979) The Marfan syndrome—diagnosis and management. *N Engl J Med* 300:772-777
- Raviola G (1971) The fine structure of the ciliary zonule and ciliary epithelium. *Invest Ophthalmol* 10:851-869
- Rosenbloom J (1984) Biology of disease: elastin: relation of protein and gene structure to disease. *Lab Invest* 51:605-623

- Sakai LY, Keene DR, Engvall E (1986) Fibrillin, a new 350kD glycoprotein, is a component of extracellular microfibrils. *J Cell Biol* 103:2499–2509
- Saruk M, Eisenstein R (1977) Aortic lesion in Marfan syndrome. *Arch Pathol Lab Med* 101:74–77
- Serafini-Fracassini A, Ventrella G, Field M, Hinnie J, Onyezili NI, Griffiths R (1981) Characterization of a structural glycoprotein from bovine ligamentum nuchae exhibiting dual amine oxidase activity. *Biochemistry* 20:5424–5429
- Streeten BW (1987) Zonular apparatus. In: Duane TD, Jaeger EA (eds) *Biomedical foundations of ophthalmology*. Vol 1. Harper & Row, Philadelphia, pp 1–23
- Streeten BW, Swann DA, Licari PA, Robinson MR, Gibson SA, Marsh NJ, Vergnes J-P, et al. (1983) The protein composition of the ocular zonules. *Invest Ophthalmol Vis Sci* 24:119–123
- Takebayashi S, Taguchi T, Kawamura K, Sakata N (1988) Osmiophilic elastolysis of peripheral organ arteries in patients with Marfan's syndrome. *Acta Pathol Jpn* 38:1433–1443
- Tsipouras P, Borresen A-L, Bamforth S, Harper PS, Berg K (1986) Marfan syndrome: exclusion of genetic linkage to the COL1A2 gene. *Clin Genet* 30:428–432
- Tsuji T (1986) Marfan syndrome: demonstration of abnormal elastic fibers in skin. *J Cutan Pathol* 13:144–153