

# XY gonadal dysgenesis and tetralogy of Fallot in an Angus calf

Jonathan E. Hare, John D. Baird, Padraig Duignan, Jennifer Saunders, Rosemarie Floetenmeyer, Parvathi K. Basrur

A 10-month-old, purebred Angus calf was presented to the Veterinary Teaching Hospital (VTH) for evaluation of poor growth since birth and abnormal external genitalia. The animal's dam was a 23-month-old first calf heifer at the time of parturition. Its sire had previously sired six calves on the farm with no discernible abnormalities. The calf was a singleton and had not experienced any other significant medical problems since birth.

On physical examination, the calf was thin and poorly grown [108 kg body weight (BW)], and appeared depressed. It had poor exercise tolerance and became profoundly dyspneic following light exertion. The calf was phenotypically female; however, the anovaginal distance was 17 cm and the vulva was small. On digital examination, the vagina was found to be a blind canal ending 8 cm cranial to the vulvar folds. A rudimentary penis, 10 mm long and 5 mm in diameter, was visible within the vulvar folds. The calf had a long rough hair coat, was infested with biting lice (*Damalinia bovis*), and had a bilateral serous nasal discharge. Jugular filling was present bilaterally, and a jugular pulse could be elicited. Rectal temperature, pulse and respiratory rates were 40.2°C, 120/min, and 100/min respectively. A grade IV to V/VI, holosystolic, crescendo-decrescendo murmur was auscultable and palpable with the point of maximal intensity over the pulmonary valve area. The murmur was auscultable as grade I to II/VI over the right heart. Rumen motility was poor. Rectal examination was difficult to perform but revealed the presence of a cervix and bicornuate uterus of normal size for an animal of this age.

The initial diagnosis was of an intersex condition with a concomitant congenital cardiac anomaly. A poor prognosis for salvage was given to the owner, and the animal was donated to the VTH for further diagnostics and clinical teaching.

Twenty-four hours postadmission, the calf's rectal temperature and pulse and respiratory rates had stabilized at 39.2°C, 100/min, and 70/min, respectively. A complete blood count, serum biochemical profile, and plasma fibrinogen assay were performed and all were unremarkable. Arterial blood-gas analysis revealed the calf to be hypoxemic (PaO<sub>2</sub>, 68.9 mmHg) and normocarbic (PaCO<sub>2</sub>, 39.8 mmHg). Lateral thoracic radiographs revealed a mild generalized increase in the density of the diaphragmatic lobes of the lung and equivocal signs of car-

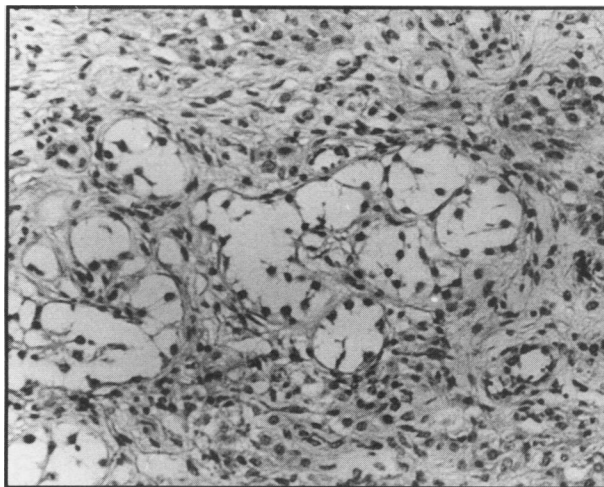


Figure 1. A representative section showing remnants of the "undifferentiated" right gonad in a 10-month-old Angus calf with XY gonadal dysgenesis. Hematoxylin and eosin. Bar represents 60 µm.

diac enlargement. Electrocardiography was performed using a bipolar lead (Hewlett Packard 1500B electrocardiograph, Hewlett Packard Medical Electronics Division, Waltham, Massachusetts, USA) and was unremarkable except for an elevated heart rate of 88/min.

Echocardiography was performed using a 2.4 MHz transducer (Toshiba SSH-40A, Toshiba Medical Systems, Scarborough, Ontario). Due to the animal's conformation, it was difficult to obtain an adequate echocardiographic window, and although a ventricular septal defect (VSD) with an over-riding aorta could be identified, it was not possible to assess the size of the defect or to perform Doppler echocardiography in order to determine flow characteristics. Time motion mode measurement of cardiac indices could not be reliably performed, precluding an assessment of valve mechanics.

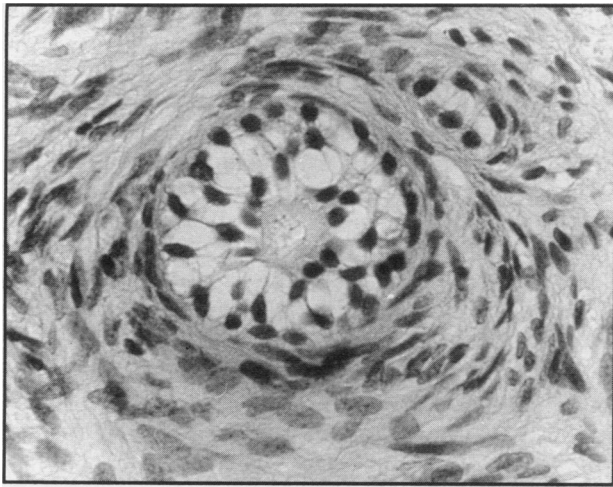
Blood samples, collected in heparinized vacutainers (Monoject blood collection tube, Sherwood Medical, St. Louis, Missouri, USA) were used for lymphocyte culture (1) and karyotype analysis. Fifty metaphase spreads were examined and all were of a 60,XY chromosome constitution indicative of a karyotypic male.

Plasma testosterone levels were estimated by radioimmunoassay at rest and one hour after intramuscular administration of 500 µg gonadorelin hydrochloride (Factrel, Ayerst Laboratories, Montreal, Quebec). In both instances, these values were found to be less than 0.07 nmol/L (0.02 ng/mL), which was considerably lower than the normal value of 10.1 nmol/L (2.9 ng/mL) reported for normal male Angus calves of this age (2).

The calf was maintained in the VTH for a 25-day period, during which time it was used for clinical teaching of undergraduate veterinary students. On the 16th day of hospitalization, standing right heart catheterization was

Can Vet J 1994; 35: 510-512

Department of Clinical Studies (Hare, Baird, Saunders, Floetenmeyer), Department of Pathology (Duignan), and Department of Biomedical Sciences (Basrur), Ontario Veterinary College, University of Guelph, Guelph, Ontario N1G 2W1. Present address of Dr. J.E. Hare: Department of Biomedical Sciences, Ontario Veterinary College.



**Figure 2.** A higher magnification of the right gonad showing a structure resembling an "undifferentiated" follicle. The presumptive germ cell in the center shows chromatin granules. Hematoxylin and eosin. Bar represents 25 µm.

performed. Prior to the procedure, the animal was given 15 mg/kg BW of trimethoprim-sulfadoxine (Trivetrin, Cooper's Agropharm Inc., Ajax, Ontario) intramuscularly (IM). The right jugular vein was surgically prepared, and under local anesthesia, a 10 gauge teflon catheter (Angiocath, Becton Dickinson and Company, Sandy, Utah, USA) was inserted, and 16 gauge sterile polyethylene tubing was inserted to the level of the right ventricle and pulmonary artery. Catheter placement was confirmed by monitoring pressure tracings generated by a physiological analyzer (Physio-control VSM 1, Physio-control Corporation, Redmond, Washington, USA) attached to the tubing by a pressure transducer (DTX pressure transducer system, Viggo Spectramedical, Oxnard, California, USA). Heparinized blood was obtained from the right atrium, right ventricle, and pulmonary artery. Heparinized arterial blood was obtained by direct puncture of the carotid artery. All samples were collected anaerobically and stored on ice until processing by a blood gas analyzer (Radiometer ABL3, Radiometer, Copenhagen, Denmark) and determination of oxygen saturation. The pulmonary flow to systemic flow ratio (QP/QS) was determined as follows:

$$QP/QS = (SAO_2 - MvO_2)/(SAO_2 - PAO_2)$$

Where  $SAO_2$  was the arterial blood oxygen content,  $MvO_2$  was the mixed venous blood oxygen saturation and  $PAO_2$  was the pulmonary artery blood oxygen saturation. The resulting value for QP/QS was 1.55, which confirmed a left-to-right component of the shunt and indicated that about 35% of the pulmonary arterial flow was from the left heart.

Right ventricular pressures (120/30 mmHg) and pulmonary artery pressures (80/40 mmHg) were markedly elevated in this animal compared to normal values reported for cattle (3). The elevated pulmonary arterial pressures indicated significant pulmonary hypertension in the calf. Additionally, the drop in systolic pressure across the pulmonic valve was strongly suggestive of either pulmonic stenosis or right ventricular out-flow obstruction and was supportive of a diagnosis of tetralogy of Fallot (ToF).

On the 18th day of hospitalization, the calf appeared dull and exhibited moderate orthopnea. Thoracic radiography revealed an diffuse interstitial pattern and pulmonary edema was suspected as the cause. Furosemide (Lasix, Hoechst Canada Inc., Montreal, Quebec) was administered at 2 mg/kg BW, IM, q12h for the remainder of the period of hospitalization. The calf's condition remained poor, and 25 days postadmission, the calf was euthanized.

On postmortem examination, the heart was globose and had a high ventricular septal defect, 2 cm in diameter; an overriding aorta; and thickened pulmonary semilunar valves with pulmonary stenosis and dilatation of the pulmonary artery distal to the pulmonary valves. The right ventricular free wall was markedly hypertrophied. The genital tract was composed of a vagina and bicornuate uterus of normal histological structure. The left gonad (20 mm x 10 mm x 7 mm) had a rudimentary epididymis and pampiniform plexus, and was invested in a membranous ligament. Histological sections of this hypoplastic gonad revealed a parenchyma sparsely distributed with tubular and sac-like structures lined by Sertoli-like cells. The basement membrane of the tubular structures was thick and hyalinized, and peritubular connective tissue was abundant. Large numbers of phosphotungstic acid hematoxylin-positive interstitial cells were present. The right gonad was nodular (15 mm x 7 mm x 5 mm), attached to fimbriae, and had an oviduct. Histological features were more typical of an ovary although with a vascular medulla and a thin cortex composed of dense collagenous stroma. The final diagnosis on the calf was that it was a case of XY gonadal dysgenesis, similar to the Swyer syndrome (11), with concomitant tetralogy of Fallot.

Intersex conditions are those in which the phenotypic, genotypic, and karyotypic sex of the individual are equivocal. Four such conditions have been reported in cattle including freemartinism (4), true hermaphroditism (5), testicular feminization (6,7), and XY gonadal dysgenesis (8-10). In gonadal dysgenesis, the affected individuals display a female phenotype, possess a female reproductive tract, hypoplastic gonads architecturally resembling ovaries with undifferentiated gonadal parenchyma, and are 60,XY in all tissues examined. The disorder in man has been attributed to an X-linked recessive or a male-limited autosomal dominant gene (11). The pathophysiology of the condition is poorly understood; however, it has been speculated that the condition arises due to the inability of the testis-determining gene on the Y chromosome to steer the gonadal and gonad-dependent differentiations in the male direction, thus resulting in a condition analogous to Turner's syndrome (XO) in humans (11).

Antemortem examination allowed us to rule-out the other possible causes of intersexuality in this animal. The absence of chimerism and the exclusive presence of 60,XY cells in the blood cultures ruled out freemartinism, while the absence of follicles or clear-cut seminiferous tubules in the gonads ruled out true hermaphroditism (4,5). The plasma testosterone levels, which were low and did not respond to gonadorelin hydrochloride challenge, helped to differentiate this case from testicular feminization in which circulating androgen levels are normal to high (6).

Of particular interest was that this case presented a complex cardiac defect, whereas the vast majority of cases of gonadal dysgenesis in the human and veterinary literature occur without similar anomalies. Congenital cardiac defects have been estimated to occur in 0.17% of cattle reaching slaughter (12). Tetralogy of Fallot, characterized by the presence of a VSD, an over-riding aorta, pulmonic stenosis, and right ventricular hypertrophy, is regarded as a common congenital cardiac defect leading to cyanosis. The degree of cardiovascular compromise in this animal was less severe than in many cases reported in the literature, in that the PaO<sub>2</sub> was only moderately depressed. Part of the reason for this may have been the mild stenosis of the pulmonary valve, which afforded the animal a significant degree of pulmonary circulation and more efficient oxygenation. Although it was not possible to assess the degree of pulmonic stenosis on echocardiography, evidence for a mild degree of stenosis was provided by the relatively easy access into the pulmonary artery by the cardiac catheter and the right ventricular to pulmonary artery pressure gradient of only 40 mmHg. A relative lack of pulmonary stenosis in this individual compared to other calves with ToF may also be the reason that this animal had a left to right shunt in contrast to the right to left shunt more commonly seen in ToF.

The occurrence of two such widely disparate and relatively rare congenital anomalies in the same animal raises speculation as to the existence of a common developmental defect. Similar defects were not reported in previous cases of XY gonadal dysgenesis in the bovine (8–10), and the consistent problem reported in cases of human XY gonadal dysgenesis has been gonadoblastomas or dysgerminomas (11). While gonadal dysgenesis in the present case could have been due to a mutation or a submicroscopic deletion of the testis-determining segment, similar to the human sex-determining region Y gene, on the Y chromosome (13), the chromosomal origin of the mutation for ToF is more obscure. Furthermore, it is unclear as to whether or not ToF is inherited in cattle. In man, conotruncal defects, including ToF, appear to be familial and may be inherited on a monogenic basis (14). It is conceivable that the present case represents a chance occurrence of the two mutations in an XY conceptus.

Alternatively, the cardiac defects encountered in this calf could be the secondary effects of gonadal dysgenesis and the resultant absence of gonadal steroids due to the premature involution of the gonads in this syndrome. In this regard, it is worth noting that a majority of human conceptuses with streak gonads die during the

first trimester and that congenital cardiopulmonary defects, including cardiomyopathy and coarctation of the aorta, are frequently encountered in cases of Turner's syndrome or the Noonan syndrome (11). Since all cases of XY gonadal dysgenesis and intersex conditions are not subjected to postmortem examination to check for cardiac defects, it is possible that heart problems are prevalent in some of these cases. Regardless of their association in affected calves, the present case exhibits some features of the human Swyer syndrome and Noonan syndrome (11), both of which tend to be karyotypic males with abnormal gonads.

## Acknowledgments

The assistance of Dr. Rob Foster in reviewing the histology of the gonadal tissue and Mr. Ed Reyes in performing the lymphocyte culture and karyotype analysis is greatly appreciated. CVJ

## References

1. Basur PK, Gilman JPW. Blood culture method for the study of bovine chromosomes. *Nature* 1964; 204: 1335–1337.
2. Lunstra DD, Ford JJ, Echterkamp SE. Puberty in beef bulls: hormone concentrations, growth, testicular development, sperm production and sexual aggressiveness in bulls of different breeds. *J Anim Sci* 1978; 46: 1054–1062.
3. Doyle JT, Patterson JL, Warren JV. Observations on the circulation of domestic cattle. *Circ Res* 1960; 8: 4–15.
4. Short RV. An introduction to some of the problems of intersexuality. *J Reprod Fertil [suppl]* 1969; 7: 1–8.
5. Dunn HO, Kenney RM, Lein DH. XX/XY chimerism in a bovine true hermaphrodite: an insight into the understanding of freemartinism. *Cytogenetics* 1968; 7: 390–402.
6. Long SE, David JSE. Testicular feminisation in an Ayrshire cow. *Vet Rec* 1981; 109: 116–118.
7. Peter AT, Scheidt AB, Campbell JW, Hahn KA. Male pseudohermaphroditism of the testicular feminization type in a heifer. *Can Vet J* 1993; 34: 304–305.
8. Henricson B, Akesson A. Two heifers with chromosomal dysgenesis and the sex chromosomal constitution XY. *Acta Vet Scand* 1967; 8: 262–272.
9. Chapman HM, Bruere AN, Jaine PM. XY gonadal dysgenesis in a Charolais heifer. *Animal Reprod Sci* 1978; 1: 9–18.
10. Sharma AK, Vijaykumar NK, Khar SK, Verma SK, Nigam JM. XY gonadal dysgenesis in a heifer. *Vet Record* 1980; 107: 328–330.
11. McKusick VA. *Mendelian inheritance in man*. 9th ed. Baltimore: Johns Hopkins University Press, 1990: 1613–1615.
12. Van Nie CJ. Congenital malformations of the heart in cattle and swine: a survey of a collection. *Acta Morphol Neerl Scand* 1966; 6: 387–393.
13. Harley VR, Jackson DI, Hextall PJ, Hawkins JR, Berkovitz GD, Sockanathan S, Lovell-Badge R, Goodfellow PN. DNA binding activity of recombinant SRY from normal males and XY females. *Science* 1992; 255: 453–456.
14. Miller ME, Smith DW. Conotruncal malformation complex: examples of possible monogenic inheritance. *Pediatrics* 1979; 63: 890–893.