

INFECTIOUS THROMBOEMBOLIC MENINGOENCEPHALITIS
IN ONTARIO FEEDLOT CATTLE

A. A. van Dreumel, R. A. Curtis and H. L. Ruhnke*

REPORTS of infectious thromboembolic meningoencephalitis (ITEME) have appeared with increasing frequency in the American veterinary literature (1-10). In 1956 this condition was reported in 36 cattle in Colorado (5). The disease was characterized by random dissemination of bacterial emboli in cerebral and meningeal vessels resulting in areas of liquefactive necrosis and foci of inflammation in the brain parenchyma. The authors felt that the brain lesions were secondary to other diseases which primarily affected the digestive and respiratory systems. The etiology of the disease was not determined, although gram-positive cocci were the most frequently encountered organism in sections of brain. In 1960 ITEMÉ was reported in feedlot cattle in California (7). These workers isolated an organism from a variety of tissues of affected animals which was tentatively identified as *Haemophilus*-like, on the basis of morphological, cultural and biochemical characteristics. The incidence of encephalitic problems in 90,000 cattle in feedlots in Kansas was reviewed and ITEMÉ was encountered most often (10). Streptococci and Staphylococci were repeatedly isolated from the brains of affected calves but their significance was unknown. Attempts to isolate *Haemophilus* type organisms from brain lesions were unsuccessful. Several cases of ITEMÉ were reported from Illinois in 1965 (3). A *Haemophilus*-like organism similar to the one previously described (7) was isolated from the brain and other internal organs of one animal. Bailie *et al.* (1) isolated a small gram-negative rod which was classified as an *Actinobacillus actinoides*-like organism, from approximately 25% of 78 feedlot cattle with ITEMÉ in Kansas. In a subsequent thesis (2), ITEMÉ was found to be the most prevalent encephalitic condition in cattle in Kansas, accounting for 60.5% of

the cases in which a diagnosis of encephalitic disease was made. Polioencephalomalacia was the second most prevalent condition and accounted for 16.9% of the cases. The only organism which consistently was isolated from cases of ITEMÉ was a new species of *Haemophilus* identified as *Haemophilus somnus*. Recently a septicemia of cattle caused by a *Haemophilus*-like organism in feedlot cattle and cattle on winter wheat pasture was described in Oklahoma (9). Clinically, the disease was divided into peracute (neurologic), acute (respiratory), and chronic (arthritic) forms, with frequent overlap of these syndromes. Grossly, the lesions were characterized by multifocal hemorrhagic areas of necrosis in the brain, meningitis, polyarthritis, polyserositis and pseudomembranous or ulcerative laryngitis. Histologically, vasculitis, thrombosis, infarction and purulent exudate were prominent findings in sections of brain, serosal and synovial membranes, laryngeal mucosa and myocardium.

This report records the occurrence of ITEMÉ in Ontario and isolation of the *Haemophilus*-like organism from the brain of one of the affected animals.

HISTORY

The cases occurred in a feedlot containing 500 steers and heifers. The cattle were self-fed on corn silage to which a protein supplement was added. The two affected steers were 18 months of age and had been in the feedlot for six months. They had not been sick during this period and were in excellent body condition at the time of their illness. Both animals had been noticed eating the day before they died.

CLINICAL FINDINGS

The two steers presented similar clinical pictures. The condition was characterized by acute onset and rapid progression to death.

*Ontario Veterinary College, University of Guelph, Guelph, Ontario.

The first abnormality noticed was knuckling at the rear fetlocks. The animal was incoordinated and seemed moderately depressed, but would still move about the pen. Two hours later the steer was down in lateral recumbency and appeared unconscious or comatose. It could not sit up or hold its head up, and paralysis was complete. The pupillary light reflex and eye preservation reflex were absent. There were no signs of irritation of the central nervous system and no convulsions were noted. The rectal temperature was 107° F with a heart rate of 100 per minute and a respiratory rate of 48 per minute. There were no nasal, oral or ocular lesions. The rumen was full but static, and normal feces were being passed.

Supportive fluid therapy and broad spectrum antibiotics were given intravenously, but death occurred within six hours of the onset of clinical signs.

POST-MORTEM

Gross Lesions

The pertinent gross lesions were confined to the joints in one and the brain in the other animal. The stifle, carpal and tarsal joints contained an excessive amount of cloudy, yellow fluid, with numerous fibrinous tags. The brain lesions were characterized by flattening of the cerebral gyri and a few small (0.5–1.0 cm in diameter), dark red, soft, depressed areas on the dorsal surface of the cerebral hemispheres. Similar lesions were observed on the cut surface in all areas of the brain. However, these lesions were most obvious at the junction of the gray and white matter of the cerebral cortex (Figure 1). The lesions were bilateral but not necessarily symmetrical in distribution.

Microscopic Lesions

The lesions in both animals were basically similar. In the brain, the lesions were characterized by extensive thrombosis of meningeal veins and parenchymal capillaries which resulted in a fibrinopurulent meningoencephalitis. Hemorrhage, malacia and a marked neutrophilic infiltration were evident in areas surrounding the thrombosed vessels. (Figures 2, 3, 4). These lesions were most extensive in sections of cerebral gray and white matter but smaller lesions were also present in sections of hippocampus, hypothalamus, pons and medulla oblongata. There were no significant lesions in sections of semilunar ganglia.

Thrombosis was also evident in pulmonary veins and capillaries and an embolic pneumonia was often associated with the vascular lesions.

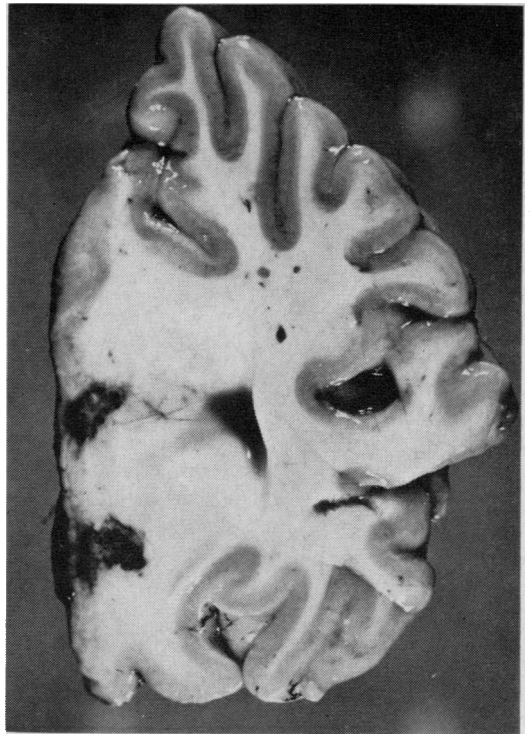


FIGURE 1. Dark red, soft, necrotic areas in the medial side of the occipital lobe of the cerebral cortex (left side of picture).

Renal lesions which consisted of hyaline thrombi and bacterial emboli in capillaries of glomerular tufts and interstitial vessels at the cortico-medullary junction, were observed in one of the animals. Focal areas of tubular necrosis with a neutrophilic and mononuclear cell reaction at the periphery were evident around thrombosed capillaries at the cortico-medullary junction.

Bacteriology

Sections of brain were stored at –20° C for approximately one month before cultures were attempted. Small sections of tissue were minced with scissors using aseptic technique and were cultured on five percent citrated bovine blood in trypticase soy agar¹ base and on chocolate agar. Cultures were incubated for 48 hours at 37° C both aerobically and in an atmosphere of 5–10% CO₂. A pure culture was recovered on plates incubated in CO₂. The colonies on blood agar were small, 0.5 to 1.0 mm, shiny, convex, translucent and entire, and produced a small zone of alpha-hemolysis. After incubation for a further 48 hours, the

¹Baltimore Biological Laboratories, Baltimore, Maryland.

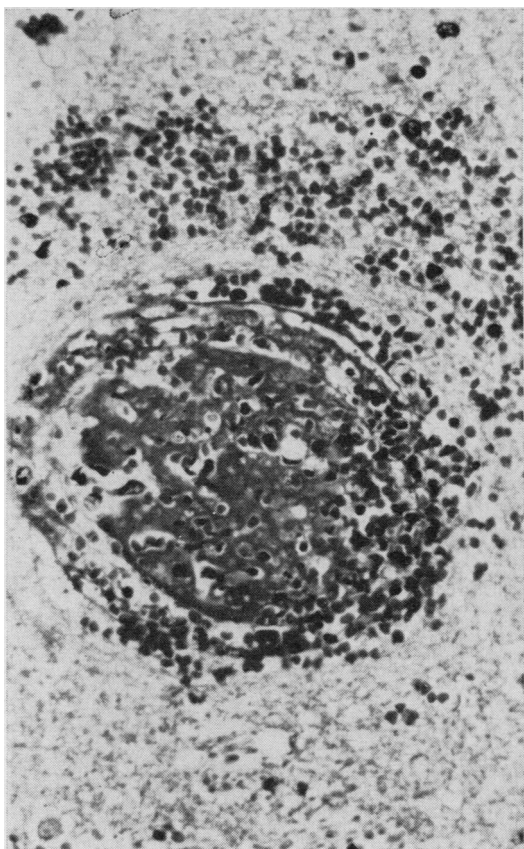


FIGURE 2. Thrombosis and degeneration of a small vessel in the hypothalamus with marked perivascular hemorrhage. $\times 300$.

colonies became umbonate with a flattened, irregular periphery and were only slightly larger than at 48 hours. Slightly larger colonies were obtained on chocolate agar. When the colonies were massed with a loop, a definite lemon yellow color was observed. Gram-stained smears of these colonies showed small, gram-negative coccobacilli, some showing bipolar staining. No growth was observed on primary cultures incubated aerobically. No organisms were seen in gram-stained smears made directly from the brain tissue.

Aerobic incubation of early subcultures on bovine blood agar were negative; however, a scant growth was observed on some later passages. No satellitism was exhibited when the organism was subcultured to blood agar with a staphylococcus streak. There was no growth on nutrient agar with a staphylococcus streak. Nutrient broth, MacConkey agar, Simon's citrate agar and Christensen's urea agar failed to support growth.

Carbohydrate reactions were determined in

phenol red broth base² containing 0.5% of the respective carbohydrate and enriched with two drops of fresh defibrinated calf blood (7).

After aerobic incubation at 37° C for 10 days, acid but no gas was produced from glucose, arabinose, maltose, mannitol, sorbitol and xylose. Dulcitol, inositol, lactose, raffinose, rhamnose, sucrose, were negative.

A small amount of H₂S was produced on lead acetate paper over a triple-sugar-iron slant with bovine serum added, but there was insufficient H₂S to blacken the agar. The organism was indol positive, oxidase positive, catalase negative.

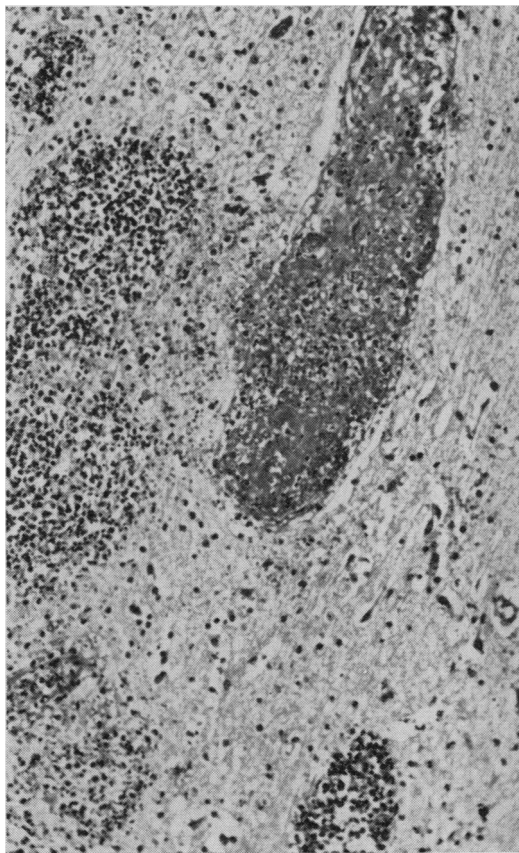


FIGURE 3. Marked inflammatory cell reaction in areas adjacent to thrombosed vessel in cerebral white matter. $\times 75$.

The organism was sensitive to low concentration discs³ of penicillin, chloramphenicol, tetracycline, erythromycin, polymyxin B, but resistant to neomycin, streptomycin and bacitracin.

Results of preliminary tests indicate that

²Difco Laboratories, Detroit, Michigan.

³BBL sensi discs.

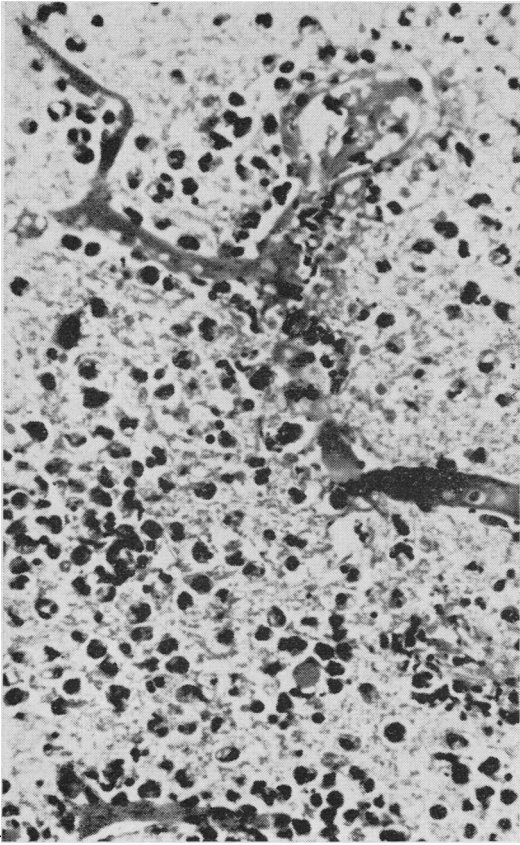


FIGURE 4. Capillary thrombosis with marked inflammatory cell reaction consisting predominantly of neutrophils in medulla oblongata. $\times 445$.

the morphological and biochemical characteristics of this isolate are similar to the organism isolated by Kennedy *et al.* (7).

CLINICAL DIFFERENTIAL DIAGNOSIS

The clinical differential diagnosis in ITEME should include polioencephalomalacia, listeriosis and any poisoning which can cause sudden death, such as heavy metals, chlorinated hydrocarbons, organophosphates and urea.

Cattle with polioencephalomalacia do not have highly elevated temperatures. The course of the condition is usually longer and most animals will show hyperesthesia, nystagmus, opisthotonus, and convulsions before death.

Listeriosis may be difficult to differentiate clinically from ITEME in those cases which do not show localizing signs. Generally, the course of the condition is not as acute and elevated body temperatures do not persist after the first few days of illness.

The most common heavy metal poisonings in cattle are from lead and inorganic arsenic,

but these are usually not available under feedlot conditions. They commonly produce the clinical signs of a gastroenteritis along with involvement of the central nervous system. The rectal temperatures of animals affected with these poisonings are not elevated to the extent that occurs in ITEME.

Chlorinated hydrocarbons produce clinical signs in cattle of severe irritation to the central nervous system. Excitement is marked in early cases along with muscular tremors and severe convulsions just before death.

Organophosphate toxicity is characterized by stimulation of the parasympathetic nervous system through inactivation of cholinesterase. Clinical signs are increased salivation, dyspnea, diarrhea, muscular stiffness and impairment of vision because of constriction of pupils.

Urea toxicity is manifested by the sudden onset of severe muscular tremors, with evidence of severe abdominal pain and violent convulsions usually terminating in death of the animal.

It should be emphasized that ITEME is most likely to be confused clinically with polioencephalomalacia. An additional aid to the differential diagnosis is found by examination of the cerebrospinal fluid (CSF). The collection of CSF in cattle is not difficult and techniques for collection have been described (6). In ITEME, the fluid may be clear or grossly turbid, but a direct smear invariably discloses an increased number of cells in which the neutrophils predominate (8). The total protein may be greater than 200 mg/100 ml (8). There is rarely as great a number of cells in polioencephalomalacia and neutrophils never dominate the cell population (8).

DISCUSSION

The clinical and pathological findings in these two cases are quite similar to other reports of the disease (1-10). The outstanding feature of the condition is the sudden onset of profound central nervous system depression. No explanation can be offered for the very low morbidity compared to a morbidity of up to 5% reported by other workers (7). Mortality rates have been reported to be over 95% in untreated cases (7). In our experience, the condition was so acute that early detection and treatment would have been difficult. Not only has early treatment with high levels of broad spectrum antibiotics and corticosteroids been reported to reduce the mortality, it is the only control measure which has been offered (1).

Several additional cases of ITEME have

been recently diagnosed at the Ontario Veterinary College and additional clinical signs not noted in the first outbreak have been observed.

The disease has been most prominent in 400–500 lb calves in the first month they were in the feedlot. Concurrent pasteurellosis (shipping fever) and infectious bovine rhinotracheitis have been found in the same feedlot but without evidence of a respiratory form of ITEMÉ as reported by Panciera *et al.* (9). Knuckling at the fetlock, extension or elevation of the head, anorexia and a high body temperature have been the earliest clinical signs. Prompt treatment with penicillin-streptomycin or broad spectrum antibiotics, before the animals go down, usually has provided a complete recovery. Once the animals go down, treatment has been of little benefit and the mortality rate of such animals has approached 100%.

Blindness has been a common finding in ITEMÉ in cattle in Ontario, in contrast to the findings in Minnesota where blindness was not usual (8). Blindness caused by cerebral infarcts undoubtedly occurs, but severe retinal damage due to thrombi has been noted in some cattle (4).

Feedlots which have excellent facilities and close observation of cattle have been able to control outbreaks by individual treatment. Mass medication of the drinking water with oxytetracycline or sulfamethazine may be necessary when cattle are not watched closely or when the morbidity is particularly high.

The incidence of this condition appears to have increased to a level where it should be considered in the differential diagnosis of any CNS disease in feedlot cattle in Ontario. A *Haemophilus*-like organism has also been isolated from some of the more recent cases.

SUMMARY

Infectious thromboembolic meningoencephalitis was diagnosed in feedlot cattle in Ontario. Clinically, the disease was characterized by sudden onset of profound central nervous system depression, fever up to 107° F and death within six hours of the onset of clinical signs. Characteristic gross lesions consisted of multiple dark red, soft, depressed areas (0.5–1.0 cm in diameter) in the brain. Histologically these lesions were characterized by extensive thrombosis of meningeal veins and parenchymal capillaries which resulted in a fibrinopurulent meningoencephalitis. Embolic pneumonia, nephritis and fibrinous polyarthritides were occasionally seen.

A *Haemophilus*-like organism was isolated from the brain of one of the affected animals

and also from subsequent cases. The disease was similar to the condition reported in feedlot cattle in the midwestern states and California.

The incidence of this condition has now reached a level where it should be considered in the differential diagnosis of any CNS disease in feedlot cattle in Ontario.

RÉSUMÉ

On a diagnostiqué une méningo-encéphalite infectieuse thromboembolique chez du bétail à l'engrais, en Ontario. La maladie se traduit cliniquement par l'apparition brusque d'une profonde dépression du système nerveux central, une augmentation de la température pouvant atteindre 107° F et la mort survient dans les six heures qui suivent l'apparition des symptômes. Les lésions caractéristiques macroscopiques consistaient en de multiples zones déprimées et ramollies de 0.5 à 1.0 cm de diamètre, de couleur rouge foncé, à la surface du cerveau. À l'examen histologique, les lésions se caractérisaient par une thrombose étendue des veines méningées et des capillaires parenchymateux, résultant en une méningo-encéphalite fibrino-purulente. On observait éventuellement de la pneumonie embolique, de la néphrite et de la polyarthrite fibrineuse.

On isola du cerveau d'animaux malades un micro-organisme du type *haemophilus*. Cette maladie ressemble à une affection décrite chez le bétail d'engrais des Etats du Midwest et de la Californie.

La fréquence de cette maladie a atteint un tel point qu'il faudrait y penser, en Ontario, lorsqu'on pose un diagnostic différentiel d'affections du système nerveux central chez des bestiaux à l'engrais.

REFERENCES

1. BAILIE, W. E., H. D. ANTHONY and K. D. WEIDE. Infectious thromboembolic meningoencephalomyelitis (Sleeper Syndrome) in feedlot cattle. *J. Am. vet. med. Ass.* 148: 162. 1966.
2. BAILIE, W. E. Characterization of *Hemophilus somnus* (new species), a micro-organism isolated from infectious thromboembolic meningoencephalomyelitis of cattle. Ph.D. Thesis. Kansas State University. 1969.
3. CASE, M. T., W. G. RAUDATAUGH and J. H. FINNELL. Report of embolic meningo-encephalitis in Illinois. *Illinois Vet.* 8: 31. 1965.
4. T. W. DUKES. Personal communication. Ontario Veterinary College.
5. GRUNER, L. A., R. JENSEN and W. W. BROWN.

- Infectious embolic meningoencephalitis in cattle. *J. Am. vet. med. Ass.* 129: 417. 1956.
6. HOWARD, J. A. and K. FAWCETT. Practical differential diagnosis of polioencephalomalacia and thromboembolic meningoencephalitis. *Iowa State University Vet.* 28: 101. 1966.
 7. KENNEDY, P. C., L. BIBERSTEIN, J. A. HOWARTH, L. M. FRASIER and D. L. DUNGWORTH. Infectious meningoencephalitis in cattle caused by a *Haemophilus*-like organism. *Am. J. vet. Res.* 21: 403. 1960.
 8. LITTLE, P. B. and D. K. SORENSON. Bovine polioencephalomalacia, infectious embolic meningoencephalitis and acute lead poisoning in feedlot cattle. *J. Am. vet. med. Ass.* 155: 1892. 1969.
 9. PANCIERA, R. J., R. R. DAHLGREN and H. B. RINKER. Observations on a septicemia of cattle caused by a *Haemophilus* like organism. *Pathologia vet.* 5: 212. 1968.
 10. WEIDE, K. D., C. M. HIBBS and H. D. ANTHONY. Diagnosis of bovine feedlot encephalitis. *Proc. U.S. Livestock Sanit. Ass.* 68: 469. 1964.

ABSTRACTS

Adams, D. H. & Field, E. J. (1968). The infective process in scrapie.—*Lancet*, Sept. 28th, 714–716 (Demyelinating Dis. Res. Unit, Royal Victoria Infirmary, Newcastle upon Tyne 2).

Previously reported work (See V.B. 38, abst. 4566) indicated the presence in the soluble cell-sap fraction of mouse brain and spleen of a substance which incorporated labelled thymidine and polysaccharide precursors. The specific activity of the tissues containing this material was shown to be doubled in mice with scrapie. This article discusses the hypothesis that the substance is a sub-unit of the scrapie virus, present in some clinically normal mice, which only becomes infective in the presence of a "linkage substance" transmitted from a fully infected donor.

Reprinted from "*The Veterinary Bulletin*", Vol. 39, No. 2, February 1969.

Richardson, A. & Smith, P. J. (1968). Herd fertility and *Corynebacterium haemolyticum* in bovine semen.—*Vet. Rec.* 83, 156–157 (Vet. Investigation Centre, Merrythought, Calthwaite, Penrith, Cumberland).

A profuse pure growth of *Corynebacterium haemolyticum* was isolated from a semen sample of an 18-month-old bull, whose general health and fertility appeared normal. It seems unlikely that *C. haemolyticum* was of any pathological significance.

Reprinted from "*The Veterinary Bulletin*", Vol. 39, No. 1, January 1969.

Carriere, J., Wallace, R., Barrett, B. & Diena, B. B. (1968). Mycobacterial antibody response in experimentally infected animals.—*Can. J. Microbiol.* 14, 923–925 (Anim. Path. Divn, Dep. Agric., Hull, Que.).

Rabbits infected with BCG, Runyon IV, and human and bovine TB strains showed circulating antibodies after a week and for the ensuing 6–7 weeks. The antibody titres generally reflected the intensity of the infection; highest titres occurred in animals with tuberculous involvement. I/p infection of g.pigs with human, bovine, avian, Runyon IV, and paratuberculosis strains resulted both in lesions and good bentonite titres. The proliferation of acidfast organisms in the host plays a role in the establishment of circulating antibodies.

Reprinted from "*The Veterinary Bulletin*", Vol. 39, No. 2, February 1969.

Summers, W. A. (1968). Preservation of infectivity of *Anaplasma marginale*.—*Am. J. vet. Res.* 29, 1489–1490 (Dep. Microbiol., Indiana Univ., Indianapolis 46202).

Anaplasma marginale, glycerinated and frozen in whole heparinized bovine blood, proved to be infective for two calves after a period of storage of nearly 2½ years at -70°C . The development of initial parasitaemia was equivalent in time to that observed earlier, but the peak of parasitaemia after infection was not reached until the 61st day in one calf, and the 56th day in the other.

Reprinted from "*The Veterinary Bulletin*", Vol. 39, No. 1, January 1969.