

HAEMOPHILUS SEPTICEMIA IN PIGLETS

R. G. Thomson and H. Louise Ruhnke*

THE OWNER of a herd of 25 breeding sows and their progeny reported that sudden deaths had been occurring in his piglets over a period of about two years. Litters were affected sporadically, but always between one and two weeks of age. Usually most or all of an affected litter died. The pigs were in excellent nutritional condition and were found dead without having shown signs of illness. Sows which produced affected litters were culled.

In September 1962, two pigs of ten days of age from a litter of 13 were presented for autopsy. A third pig from this litter was presented six days later. The first deaths in this litter occurred when the pigs were six days of age; four pigs died on the seventh day and two on the tenth day after birth. According to the owner the course of events in this litter was typical of the disease.

The owner was advised that the disease probably could be treated with parenteral streptomycin, even though he might wait until the first pig died before treating the remainder of the litter. Subsequent history was obtained in January 1963. The disease had occurred in four litters since September, but treatment after the first death had prevented further losses. Autopsy was not carried out on these subsequent losses but events were considered typical of the disease by the owner.

PATHOLOGY

The interval between death and autopsy was approximately 12 hours. The three pigs which were autopsied had similar lesions. The lungs were congested and edematous and failed to collapse. They were sprinkled with very small hemorrhages. There was a small volume of serous effusion in the pleural sacs. The liver was enlarged two or three times, and its surface presented a blotchy appearance produced by areas of pallor and dark areas of congestion or hemorrhage. Numerous circumscribed yellowish foci of pin-head size were visible through the capsule and some of these were surrounded by a narrow zone of hyperemia. The spleen was enlarged to about twice its normal size and was very firm. Its surface was irregular and lumpy over dark areas of hemorrhage and numerous yellowish foci similar to those in the liver were visible through the capsule. Lymph nodes generally were enlarged and hemorrhagic. The intestine was slightly flaccid, and slightly edematous and hyperemic and there was a thin mucinous content. Serous membranes were clean. Bones and joints were not examined microscopically but were normal on gross inspection.

Microscopically, the liver was congested and there was a diffuse accumulation of mononuclear cells and leukocytes in the portal triads and sinusoids. Foci of necrosis occurred throughout the liver and at any location in a lobule (Fig. 1). The earliest lesion was a gathering in a sinusoid of a few leukocytic cells associated with two or three liver cells, all of which were degenerating. Such foci were quite distinct from the small areas of hemopoiesis which were still present in the livers. The foci became larger by necrosis of more liver cells, thrombosis

*Ontario Veterinary College, Guelph, Ontario.

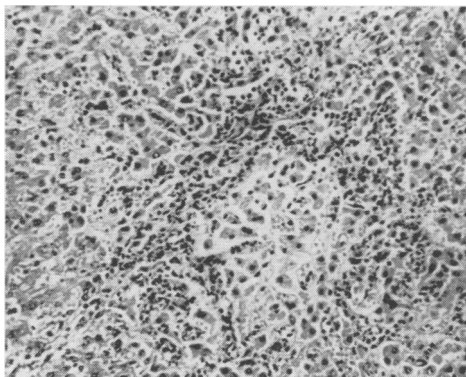


FIGURE 1. Focal necrosis in the liver surrounded by a zone of inflammatory cells and debris.

of adjacent sinusoids and a further increase in leukocytes. At this stage the foci consisted of an eosinophilic coagulum and degenerate cells. The largest and oldest foci were very densely cellular and contained mostly degenerating and necrotic cells with shrunken irregular nuclei. These cells could not be specifically identified but appeared to be a mixture of leukocytes, hepatocytes and reticuloendothelial cells. The largest foci involved about half of a lobule. There was an occasional microabscess (Fig. 2). In the liver of one pig there were a few bacterial colonies present in sinusoids not related to necrotic foci. Colonies of Gram-negative bacteria were more numerous in the lesions in the spleen, lymph nodes and lungs than in the liver.

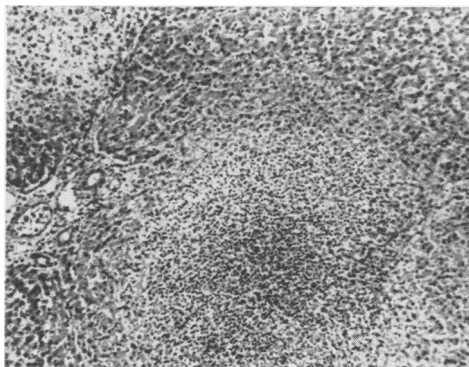


FIGURE 2. Focal abscessation in the liver.

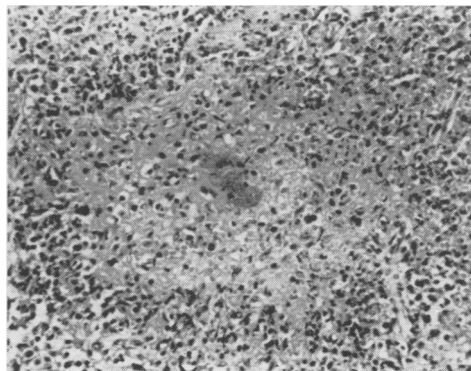


FIGURE 3. Focal necrosis in the spleen with central bacterial colony.

Necrotic foci in the spleen were numerous, mainly in the red pulp. The smaller foci consisted of an eosinophilic coagulum with a few shrunken degenerate cells but as in the liver, the larger foci became more densely cellular. Some foci were uniformly cellular while others had a dense ring of degenerate neutrophils at the circumference. Many of the necrotic foci contained a colony of bacteria (Fig. 3) but colonies did occur separate from the areas of necrosis.

The bronchi and bronchioles appeared normal. There was slight distention

HAEMOPHILUS SEPTICEMIA IN PIGLETS

of peribronchial lymphatics which were continuous with very distended interlobular lymphatics. A sprinkling of hemorrhages and leukocytes was present in the interlobular stroma. There was diffuse injury of bacteremic nature to alveolar septa producing hyperemia, edema and increased cellularity of the alveolar walls. Scattered throughout the lung were miliary microscopic foci of more severe injury affecting groups of alveoli, the vessels of which were plugged with fibrinoid thrombi and embolic colonies of bacteria. In such alveoli there was an effusion with strands or balls of fibrin, erythrocytes and desquamated alveolar epithelial cells. These foci of intense injury were of random distribution and varied in size. Their maturity was characterized by necrosis of tissue with intense infiltration of neutrophils. The larger focal lesions had a peripheral location in the lobule and often encroached upon or occurred in interlobular septa (Fig. 4). The pleura was normal.

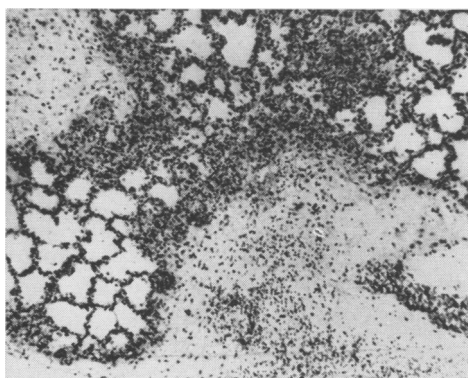


FIGURE 4. Embolic pneumonia with extension to septal tissue.

Colonies of bacteria and fibrinoid thrombi occurred in renal glomerular capillaries and bacterial colonies surrounded by a zone of necrosis, were present in the lamina propria of the intestine. Cerebral leukocytosis and pericapillary damage were evident in the nervous system, especially in the brain stem, but the meninges were normal. The myocardium contained random foci and streaks of acute degeneration as well as an occasional focus of myocarditis. The vessels in the periphery of the lymph nodes were dilated and congested. Some capillaries in this region were plugged with very large colonies of bacteria. Focal necrosis had occurred around some bacterial colonies. Lymphoid follicles were somewhat depleted of small lymphocytes. Skeletal muscle and eyes were normal.

The lesions were those of a bacteremia with embolism and thrombosis of capillaries.

BACTERIOLOGY

Organisms were not observed in smears made directly from the livers and stained by Gram's method. Portions of liver and spleen from the 10-day-old pigs, and of liver, spleen and lung from the 16-day-old pigs were cultured on 5 per cent citrated sheep blood agar plates after which a staphylococcus was streaked

across the plate. Plates were incubated aerobically for 48 hours at 37° C. Approximately fifteen satellite colonies were obtained from the liver of one of the 10-day-old pigs. From the 16-day-old pig, there were two colonies from the liver and one colony from the lung. Cultures of spleen were negative in each instance.

Colonies were transparent, convex and shiny with a diameter of 0.5–1.0 mm. Gram-stained smears of these colonies showed small, Gram-negative rods with many long, tangled filaments. When these colonies were subcultured they exhibited satellitism along the staphylococcus streak and good growth was obtained in 24 hours. The isolate from the liver of the 16-day-old pig was selected and maintained for further tests by subculture at 48-hour intervals on sheep blood agar with a staphylococcus streak. Subcultures were made to tryptose agar¹ tryptose agar plus a staphylococcus streak, trypticase soy broth² and trypticase soy broth plus 5.0 ug./ml. coenzyme. I³. The organism still exhibited satellitism along the staphylococcus streak on sheep blood agar and on tryptose agar, and good growth was obtained in trypticase soy broth with added coenzyme I. It did not grow on sheep blood agar or on tryptose agar without staphylococcus or in trypticase soy broth without coenzyme I.

Fermentation reactions were determined on the 15th subculture in phenol red broth base¹ with 0.5 per cent of the respective carbohydrate added. Coenzyme I (5.0 ug/ml.) was added to each tube. After incubation for five days at 37° C., acid without gas was produced from galactose, glucose, mannose, maltose, raffinose, sucrose and trehalose. There was no fermentation of lactose or rhamnose, arabinose, dulcitol, inulin, inositol, mannitol, salicin or xylose. Catalase activity was determined by mixing equal volumes of a 24-hour culture in trypticase soy broth with added coenzyme I (5.0 ug/ml.) and 10-volume hydrogen peroxide. Bubbles of gas were produced. An uninoculated broth control with added coenzyme incubated for the same length of time produced no gas when mixed with hydrogen peroxide. No attempt was made to measure the volume of gas produced.

This organism was dependent on the V factor (coenzyme I) since it grew well on tryptose agar when the V factor was supplied by the staphylococci and in trypticase soy broth when pure coenzyme I was added. It did not require the X factor as supplied in the sheep blood and was probably a member of the *Haemophilus parainfluenzae* group.

DISCUSSION

The best known associations of the genus *Haemophilus* with disease in pigs are the syndromes of swine influenza as elucidated by Shope, and Glasser's disease which is characterized by fibrino-purulent inflammation of serous and synovial membranes and of meninges. In both syndromes the organism is specified as *Haemophilus (influenzae) suis* (see review by Hjarre (3)). The same organism has been found as an apparent saprophyte in the respiratory

¹Difco, Detroit 1, Michigan.

²Baltimore Biological Laboratories, Baltimore, Maryland.

³Cozymase, Nutritional Biochemicals Corporation, Cleveland, Ohio.

HAEMOPHILUS SEPTICEMIA IN PIGLETS

tract in up to 60 per cent of young pigs in Europe and North America (3) and can be isolated as frequently from the pneumonic lungs of pigs with virus pneumonia of pigs (V.P.P.). Matthews and Pattison (5) isolated from a pig affected with pneumonia an organism which they classified with the *Haemophilus parainfluenzae* group, and which was capable of producing pneumonia by intratracheal inoculation. They thought this organism to be the same as one they had isolated earlier (6) from lung lesions in a case of hog cholera and which experimentally was a pulmonary pathogen only in association with the hog cholera virus. An organism similar to the one we have described has been isolated from meningitis in pigs and is reported by Radostits and co-workers in an accompanying paper (7). None of these diseases associated with *Haemophilus* resembles the syndrome described in this paper, which is however reminiscent of the septicemic disease of sheep caused by *Haemophilus agni* (2, 4). For tentative and for comparative purposes only we have assigned this organism to the *Haemophilus parainfluenzae* group. Comparative studies on many strains are clearly desirable; Alexander's scheme of classifying strains as *H. influenza* or *H. parainfluenza* according to requirements for X and V factors is too broad to be useful, isolates are unstable in their biochemical requirements and available serological data do not allow a differentiation according to biotypes or pathogenic potential (1).

SUMMARY

A fatal disease of piglets is described from which an *Haemophilus* organism was isolated. The disease was characterized by bacteremia with embolism and thrombosis of capillaries especially in the spleen, lymph nodes, lung and liver.

RÉSUMÉ

Les auteurs décrivent une maladie mortelle chez des porcelets avec isolement d'un organisme du type *Hémophilus*. La maladie est caractérisée par une bactériémie accompagnée d'embolismes et de thromboses des capillaires de la rate, des ganglions, du foie et des poumons.

REFERENCES

1. ALEXANDER, H. E. "The Hemophilus Group". In: Bacterial and Mycotic Infections of Man. R. J. Dubos, ed. 3. Philadelphia: Lippincott. 1958.
2. BIBERSTEIN, E. L., and CAMERON, H. S. The family Brucellaceae in veterinary research. Annual Rev. of Microbiol. 15: 93. 1961.
3. HJARRE, A. Enzootic virus pneumonia and Glasser's disease of swine. Advances in Vet. Sci. 4: 251. 1958.
4. KENNEDY, P. C., FRAZIER, L. M., THEILEN, G. H., and BIBERSTEIN, E. L. A septicemic disease of lambs caused by *Haemophilus agni* (new species). Am. J. Vet. Res. 19: 645. 1958.
5. MATTHEWS, P. R. J., and PATTISON, I. H. The identification of a Haemophilus-like organism associated with pneumonia and pleurisy in the pig. J. Comp. Path. 71: 44. 1961.
6. PATTISON, I. H., HOWELL, D. G., and ELLIOT, J. A Haemophilus-like organism isolated from pig lung and the associated pneumonic lesions. J. Comp. Path. 67: 320. 1957.
7. RADOSTITS, O. M., RUHNKE, H. L., and LOSOS, G. An outbreak of meningitis in swine caused by an Hemophilus species. Can. Vet. J. 4: 265. 1963.