

ORIGINAL ARTICLE

Radiological and biochemical resolution of nutritional rickets with calcium

L M Oginni, C A Sharp, O S Badru, J Risteli, M W J Davie, M Worsfold

Arch Dis Child 2003;88:812-817

See end of article for authors' affiliations

Correspondence to:
Dr M Worsfold, Charles
Salt Research Centre,
Robert Jones and Agnes
Hunt Orthopaedic &
District Hospital NHS Trust,
Oswestry, Shropshire
SY10 7AG, UK;
mike.worsfold@rjah.nhs.uk

Accepted
11 December 2002

Aims: To determine the response to oral calcium in Nigerian children with rickets.

Methods: In a teaching hospital in Western Nigeria, 26 children (13 boys, 13 girls, aged 2-5 years) with confirmed rickets received calcium lactate (2.7 g/day).

Results: Within one month of treatment leg pain was relieved and the children were more active. The mean x ray score improved from 3.3 at baseline to 1.7 at three months and 0.9 at six months (arbitrary scoring system, 0-6). Twelve cases were healed radiologically after six months, 11 others improved considerably, two showed no significant improvement, and a non-compliant patient was worse. There was progressive reversal of biochemical features. Median plasma alkaline phosphatase fell from 519 (range 178-1078) to 283 (209-443) IU/l ($p = 0.04$) in four months, while mean 1,25-dihydroxyvitamin D fell from 473 (251-1057) to 281 (155-481) pmol/l ($p = 0.04$), and mean plasma calcium increased from 2.26 (1.63-2.54) to 2.37 (2.06-2.54) mmol/l ($p = 0.13$). Parathyroid hormone fell from 5.3 (0.4-21.5) to 1.7 (0.45-7.4) pmol/l. Type I collagen carboxy terminal cross linked telopeptide was very high at baseline (20 (7.2-103) to 14 (1.1-24) $\mu\text{g/l}$) ($p = 0.03$) and fell promptly to normal.

Conclusion: Calcium supplementation alone effected healing of rickets in most of these Nigerian children and may provide sufficient treatment in this environment.

Until recently it had been generally considered that vitamin D deficiency was the main cause of privational rickets and that calcium deficiency alone was unusual,^{1,2} but studies from South Africa and Nigeria suggest that calcium deficiency may be a major cause of rickets in these regions.³⁻⁵ These reports, which deviate from the earlier concept, have stimulated much interest.⁶⁻⁹ More recently there have been reports of rickets apparently caused by calcium deficiency in Bangladesh¹⁰ and also Colombia,¹¹ whereas the rickets associated with dietary calcium deficiency in India appears to be linked to fluoride toxicity.¹² Some evidence of healing of rickets with calcium has been reported from South Africa¹³⁻¹⁵ and in Nigerian infants,⁴ but this has remained controversial. Recently, following our preliminary report¹⁶ in which we described clinical and radiological improvement in seven patients with calcium supplementation alone, our results have been confirmed by Thacher and colleagues.¹⁷ There has been no comprehensive study of the biochemical response to calcium supplementation, but a description of the changes of some of the serum biochemical measures contains discrepant values at least for parathyroid hormone.¹⁸ There is a continuing need to clarify the relative roles of calcium and vitamin D in the aetiology and treatment of rickets in different circumstances, which would be helped by detailed, integrated biochemical and clinical studies. There is also potential diagnostic and surveillance value in understanding the biochemistry of this metabolic disease.

In the present study, we have analysed, in 26 patients, the changes during treatment of the clinical and radiographic features, as well as of the plasma concentrations of calcium, alkaline phosphatase (ALP), 25-hydroxyvitamin D (25D), 1,25-dihydroxyvitamin D (1,25D), parathyroid hormone (PTH), osteocalcin, and markers of collagen turnover, in order to determine whether any of these quantities reflect radiographic measures of healing in calcium deficiency rickets, and so could serve as surrogates for x ray examination.

SUBJECTS, MATERIALS, AND METHODS

All patients ($n = 73$) presenting with active rickets to the Wesley Guild Hospital, Ilesa, unit of the Obafemi Awolowo University Teaching Hospital, Ile-Ife, Nigeria between January 1996 and June 1998, were examined. Patients with clinical rickets confirmed by typical radiological features, and who were not on any treatment prior to presentation were provisionally included in this study. Eighteen were lost to follow up, and for 26 there were insufficient biochemical results or x ray pictures to include them in the analysis. The absence of data was for technical reasons and was not related to the condition of the patients. Twenty six patients (13 boys, 13 girls; aged 2-5 years, mean 3.1 (0.9) years) completed six months of treatment and yielded enough data to be included in this study. One patient whose biochemical findings indicated vitamin D deficiency, as evidenced by marginally low 25D (22 nmol/l, 10 ng/ml) as well as low 1,25D (220 pmol/l, 83 pg/ml), was excluded from the analysis. Two patients had a femoral shaft fracture. An additional two cases were found because of referral of siblings. Diagnostic clinical criteria included enlarged wrists, rachitic rosaries, and lower limb deformities. Radiographic criteria applied to anteroposterior films of both wrists and knees included widening and cupping of the metaphysis, fraying and thickening of the physis, and generalised rarefaction. Enquiries about duration of breast feeding were also made. Informed consent was obtained from all parents and approval of the hospital's ethical committee was obtained.

Clinical and biochemical assessment of patients were carried out before treatment, after two weeks of treatment,

Abbreviations: 25D, 25-hydroxyvitamin D; 1,25D, 1,25-dihydroxyvitamin D; ALP, total alkaline phosphatase; ICTP, type I collagen carboxy terminal cross linked telopeptide (C1x-MMMP); iPINP, intact amino terminal propeptide of type I procollagen; PICP, carboxy terminal propeptide of type I procollagen; PTH, parathyroid hormone

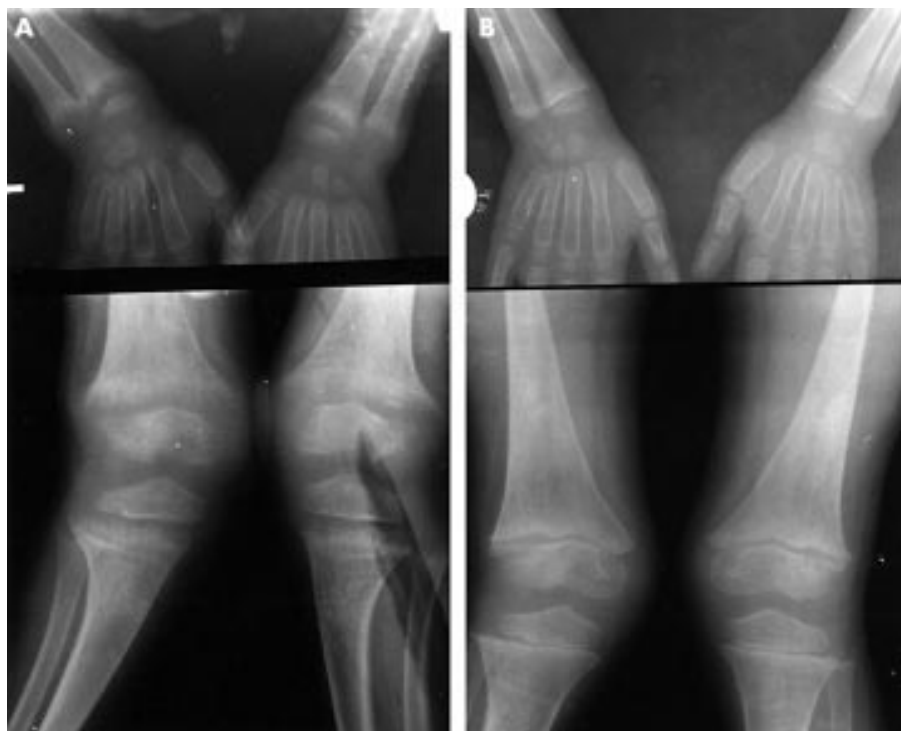


Figure 1 x Ray appearances of the wrist and knee in a florid case of rickets; (A) before treatment, scored 6; (B) after six months of treatment, scored 1.

after approximately two months, and at later intervals. The samples were taken at routine orthopaedic clinics between 11 am and 12 noon, centrifuged, stored at -20°C , and transported to England on ice for analysis. Radiographs were taken before treatment, and at three months and six months.

Plasma calcium, phosphate, albumin, and ALP were measured on a Kodak Ektachem autoanalyser. Plasma calcium values were adjusted for albumin.¹⁹ Radioimmunoassay methods were used to measure plasma concentrations of 25D (Incstar, UK), 1,25D (Immunodiagnostic Systems Ltd), and intact PTH (Gamma BCT intact, Immunodiagnostic Systems Ltd, UK),⁵ type I collagen carboxy terminal cross linked telopeptide (ICTP), and intact amino and carboxy terminal procollagen propeptides (iPINP, PICP) (Orion Diagnostica, Finland).²⁰ Osteocalcin was measured using bovine antigen and tracer, and a polyclonal rabbit antiserum.²¹

At the end of the study, the radiographs were randomised and scored blind by three independent people who had been trained on similar films in order to harmonise their scoring. The more severely affected bone of each joint (radius or ulna at the wrist, tibia, or femur at the knee) was scored. Each bone was scored on the basis of cupping of the metaphysis, sharpness (or fraying) of the metaphyseal margin of the growth plate (physis), and thickness of the physis, on a scale of 0 (not affected) to 2 (most affected); scores for each feature were summed to give a maximum score of 6 and a best score of 0. An average score was calculated for all the assessments of the knees and wrists in each patient.

Calcium lactate (2.7 g/day, 350 mg elemental Ca/day) was administered orally in three divided doses for at least six months after the initial investigations. There were no other dietary changes. Knee deformities were treated by serial wedging of cylinder plaster casts or by observation alone. None of the patients was hospitalised during the treatment period.

The data were analysed with Systat (SPSS, Inc., Chicago), using the Wilcoxon paired rank test for comparison and Spearman test (r) for correlation where appropriate. For illustrative purposes (figs 2 and 3), z scores, which are differences from reference means²⁰ expressed as standard deviation ratios, were calculated.

RESULTS

Clinical findings

The duration of deformity before presentation ranged from 1 to 36 months with a mean of 12 (9.4) months. The two children diagnosed from family screening were the younger siblings of presenting patients, just beginning to walk. They had minimal knee deformities, but their blood biochemistry and radiographs indicated more severe rickets than the presenting older siblings. The duration of breast feeding ranged from 3 to 12 months (mean 9.5 (4) months). Two children were not breast fed because their mothers died. The deformities of the presenting patients were noticed 3–6 months after they started to walk, by which time all had stopped breast feeding. Reference ranges of biochemical markers for a similarly aged group of healthy children from the same area are described in an earlier publication.²⁰

The main reason patients came to hospital was deformity at the knees, specifically bilateral genu valgum ($n = 10$), windswept deformity ($n = 9$) (a combination of genu valgum on one limb and genu varum on the other in the same patient²²), bilateral genu varum ($n = 7$), and anterior bowing of the tibia and femur ($n = 7$). Other clinical features included rachitic rosaries ($n = 23$), wrist enlargement ($n = 11$), leg pain ($n = 6$), delayed walking ($n = 2$), delayed eruption of teeth ($n = 2$), bossing of the skull ($n = 4$), delayed closure of fontanelle ($n = 3$), femoral shaft fractures ($n = 2$), and protuberant abdomen ($n = 4$). One patient did not comply with treatment.

The earliest clinical sign of improvement was the relief of leg pain within the first month. These children were also described by parents as being more physically active. The two children who had not walked by the age of 2 years started walking within three months. Wrist enlargement was noticeably reduced from three months and was normalised in 8 of 11 after six months. Rachitic rosaries, assessed subjectively (LMO and the mother) were improved in all patients, but only completely resolved in half of them. Knee deformities did not worsen in any of the patients during the period of treatment. Correction was achieved after six months in 5 of 9 patients who had serial wedging of plaster cylinder casts.

Table 1 Biochemical findings before and during treatment

Analyte	Duration of treatment				p value (Wilcoxon)		
	Baseline	2 weeks	2 months	>4 months	2 weeks	2 months	>4 months
Plasma calcium (mmol/l)	2.26 (1.63–2.54) 26	2.30 (1.15–2.50) 15	2.31 (2.01–2.54) 15	2.37 (2.06–2.54) 9	0.64	0.23	0.13
Phosphate (mmol/l)	1.48 (0.89–2.40) 25	1.63 (1.13–2.24) 15	1.6 (1.04–2.38) 15	1.7 (1.38–2.01) 9	0.08	0.29	0.03
PTH (pmol/l)	5.3 (0.4–21.5) 26	2.9 (0.3–14.9) 15	3.8 (0.02–19) 15	1.7 (0.45–7.4) 8	0.28	0.03	0.03
1,25D (pmol/l)	473 (251–1057) 24	407 (283–820) 14	400 (113–1194) 14	281 (155–481) 9	0.04	0.88	0.04
25D (nmol/l)	36 (15–202) 26	37 (15–115) 15	47 (24–78) 15	44 (31–80) 7	0.08	0.21	0.05
iPINP (µg/l)	1102 (402–1840) 24	1028 (627–3355) 15	829 (60–2440) 15	902 (410–1254) 9	0.61	0.16	0.12
PICP (µg/l)	561 (171–1402) 25	524 (241–1275) 15	409 (155–1226) 15	475 (295–668) 9	0.76	0.12	0.48
ICTP (µg/l)	20 (7.2–103) 25	17 (9–71) 15	13 (8–67) 15	14 (11–24) 8	0.08	0.02	0.03
ALP (IU/l)	519 (178–1078) 26	401 (158–945) 15	374 (176–859) 15	283 (209–443) 9	0.75	0.02	0.04
Osteocalcin (µg/l)	14 (1–55) 26	17 (1–81) 15	22 (1–122) 15	32 (5–82) 9	0.61	0.39	0.9

Data are expressed as median values (range) and number of subjects. All p values relate to comparisons with baseline values.

Radiological findings

The mean radiological score at presentation improved from 3.3 (SD 1.8, median 3, range 1–6, $n = 26$) to 1.7 (SD 1.4, median 1, range 0–4, $n = 17$) after three months of treatment and to 0.9 (SD 1.2, median 1, range 0–5, $n = 26$) after six months. Figure 1 shows the radiographic response of a severe case. The radiological score of 12 cases after six months was 0, indicating complete cure. The score of the non-compliant patient rose from 4 to 5, after transiently falling to 3.5.

Biochemical findings

At presentation the mean plasma concentrations of ALP, 1,25D, PTH, ICTP, iPINP, and PICP were raised (table 1, fig 2 and 3), while the plasma calcium was reduced compared with our normal ranges for local Nigerian children.²⁰ Pretreatment plasma levels of 25D were rather low (20, 20, 22 nmol/l, 8.0, 8.8, 8.8 ng/ml) in three patients (15%). Generally, there was progressive reversion towards normality of the biochemical pattern during treatment.

Within the first two weeks, the only significant biochemical change was a fall of median 1,25D from 473 to 407 pmol/l (from 197 to 170 pg/ml) ($p = 0.04$). At two months, PTH, ICTP, and ALP all fell significantly ($p = 0.03$, $p = 0.02$, $p = 0.02$), while 25D rose, but this was not significant until four months ($p = 0.05$). ALP, PTH, 1,25D, iPINP, and ICTP continued to fall to the end of the study period, but in the case of iPINP this was not significant ($p = 0.12$). The plasma Ca, PTH, ALP, iPINP, and ICTP in the non-compliant patient did not trend towards normality, but tended to deviate further from it.

ALP activity correlated strongly with ICTP, iPINP, and PTH both before treatment ($r = 0.74$, 0.73 , 0.64) and after four months treatment ($r = 0.83$, 0.77 , 0.60). PTH also correlated strongly with ICTP at all stages ($r = 0.48$ – 0.81). Baseline x ray scores correlated with PTH ($r = 0.51$), ALP ($r = 0.80$), iPINP ($r = 0.60$), and ICTP ($r = 0.57$). These relations diminished,

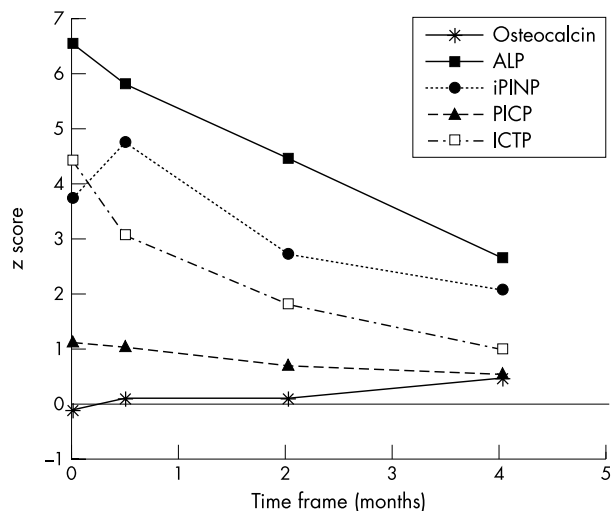


Figure 2 Serum bone markers: z scores relative to healthy controls.

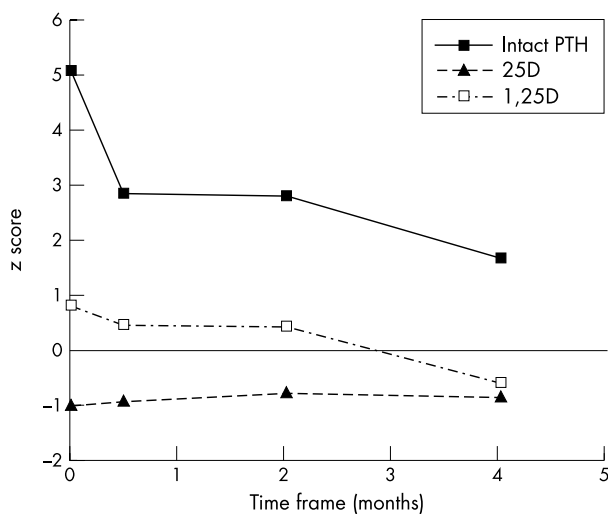


Figure 3 Serum calcitrophic hormones: z scores relative to healthy controls.

and mostly disappeared, after treatment started. Changes in x ray scores at six months correlated with changes in PTH ($r = 0.54$), ALP ($r = 0.63$), and iPINP ($r = 0.33$) at four months. Two patients who had poor radiographic healing did not respond with reversal of bone markers.

Overall, one patient (4%) had healed at three months and 12 (46%) by six months. A further 11 (42%) showed improvement but were still on treatment. Two patients (8%), including the non-compliant one, showed no significant improvement. They did not attend clinic regularly.

DISCUSSION

There have been several reports, mostly from South Africa, of deprivational rickets in adolescents.^{13–15} A similar syndrome in different parts of Nigeria seems to affect younger children.^{4 5 23 24} There is now good evidence and general agreement that much of the rickets in Nigeria and in some other regions is caused primarily by dietary calcium deprivation. This has been confirmed by documentation of cure of the disease by calcium supplementation alone.^{16 17 23}

Our patients presented with entirely typical clinical and radiological features of rickets. The biochemical profile in general is suggestive of calcium deficiency, but is not diagnostic in all individual cases. Biochemical evidence of vitamin D deficiency was seen in only one patient, who was excluded from the analysis. Three of our patients had 25D levels which were marginally low, but within the range which is encountered in rickets found to be associated with calcium deficiency.^{10 25} If such a reduction were the result of vitamin D deficiency, one would expect concomitantly low 1,25D levels, which were not seen in these patients. Twenty four of our 26 patients (92%) responded well to calcium treatment clinically and radiographically, confirming that calcium deprivation is the major cause. Serum calcium returned to normal where it had been low, and 1,25D and PTH tended towards normality although this was not achieved on average.

Biochemical characterisation of this type of rickets, and descriptions of the biochemical changes accompanying cure by calcium, are incomplete, and in some cases have been inconsistent. The finding of raised circulating 1,25D and PTH in calcium deficiency, which we have previously reported,⁵ agrees with those of Pettifor *et al* from somewhat older children in South Africa,¹⁴ and of Okonofua *et al* in Nigeria,⁴ as well as Legius *et al* in Belgium²⁵ and Pugliese *et al* in the USA.²⁶ On the other hand, one group has reported PTH levels in patients from Jos, Nigeria, which were lower than their controls,^{18 23 27} and which increased about tenfold on calcium

therapy. Their controls in the first of these studies had very high PTH levels (about 30-fold higher) compared with those reported by other workers.^{4 5 14 25 26 29 30} Paradoxically, earlier publications by the same group^{28 31} reported raised PTH levels in rickets patients from Jos compared with their controls, which were themselves 20-fold higher than most values in the literature. Furthermore, the rickets in these cases was not shown to be caused by calcium deficiency. It is possible that some of the anomalies may be a result of non-specificity of the assay methods used. In the past there have been problems from recognition of circulating fragments of PTH, especially in renal failure. Modern commercial assays appear to have overcome this problem, and in any case there is no obvious reason why such fragments should accumulate in the blood of rickets patients. Stability of this analyte in tropical conditions with limited access to refrigeration is also a potential problem, but some of the groups which report lower levels were working in a temperate climate under well controlled conditions. A later report from Jos, using a different assay kit which recognises the C-terminal mid-molecule portion of PTH, gave intermediate values for the controls and higher levels in rickets patients.³²

We have previously shown increased collagen turnover in children with rickets, as indicated by raised plasma concentrations of both intact PINP and PICP (markers of type I collagen formation) and increased ICTP, a degradation product of trivalently cross linked type I collagen.²⁰ In the present study, raised baseline concentrations of both propeptides reflect increased collagen synthesis concomitant with the compensatory expansion of the rachitic epiphyses. Degradation of mineralised bone collagen usually occurs through the actions of the osteoclast which produces an acidic secretion containing the proteinase cathepsin K, and generates, among other products, the cross linked amino terminal telopeptide of type I collagen (NTx) antigen. Another degradative mechanism using matrix metalloproteinases (MMPs) may not involve osteoclasts³⁵ and generates the ICTP antigen. In the initial stages of healing the poorly mineralised, but highly cross linked, matrix would be removed before deposition of new collagen which is more suitable for mineralisation. The high baseline concentration of ICTP could reflect non-osteoclastic turnover of collagen, with resorption mediated by MMPs, possibly from PTH stimulated osteoblasts, and which declines during treatment.

The progressive fall of all these collagen metabolites during treatment suggests a reduction in type I collagen turnover. In particular, the fall in circulating ICTP reflects the transition from rachitic to normally mineralised bone, and indicates bone healing. Interestingly, another study has reported a fall in the urinary output of the collagen cross link deoxypyridinoline after 12 weeks of calcium treatment of rickets, with a paradoxical rise of serum NTx.¹⁸ Since NTx is a product of osteoclastic cathepsin K activity, this increase during healing may reflect remodelling of newly mineralised bone.

The significant correlation between alkaline phosphatase activity and ICTP in our patients had not been seen by us in healthy subjects,²⁰ but nonetheless did not weaken during the period of this study. A similar correlation was reported by Scariano *et al* in a pooled healthy and rachitic sample of Nigerian children.²⁷ It is interesting that osteocalcin behaved differently from alkaline phosphatase, which is also a product of the osteoblast, in that osteocalcin was low at baseline and tended to rise with treatment (although not significantly).

The difference in age of onset between Nigerian and South African cases is not easily explained. Our patients were infants, aged between 1 and 5 years, and responded to treatment with calcium. The best potential source of calcium, especially for infants, is milk. Inadequate intake of milk or milk products may have led to calcium deficiency in our patients after cessation of breast feeding. Calcium deficiency rickets has been described in patients with milk allergy.³⁴ Soya drink, which is sometimes substituted for milk in Nigeria, has a lower calcium content than milk, since it is not usually fortified in that country, and has also been associated with calcium

deficiency rickets.²⁵ A thorough case-control epidemiological study in Nigeria by Thacher and coworkers³² concluded that inadequate dietary calcium interacts with genetic, hormonal, and other nutritional factors to cause rickets in this population. The same group³⁵ found evidence of differences in vitamin D receptor genes in rickets patients, but no explanation of a possible mechanism for an effect. Other geographical differences, such as the kinds of food which are available and the composition of drinking water, might also contribute to the apparent variation in the profile of rickets seen in different regions. In India, there is evidence that when calcium intake is marginal, fluoride in drinking water induces rickets which is cured by calcium supplementation.¹² There is also a report that strontium in the soil can have a similar effect.³⁶ In contrast to an earlier report from Tanzania,³⁷ Thacher and colleagues³² found no differences in the source of water between patients and controls living around Jos, but they did not report fluoride concentrations. There may be other sociocultural differences between our population and the South African one. For instance, the urban setting of our study with many health institutions might have favoured early diagnosis.

In conclusion, this study shows that supplemental calcium was effective in the treatment of rickets in most of our patients. Since dietary calcium deficiency was the main cause, there is potential for recurrence of the condition, especially at times of rapid growth, unless dietary intake continues to be adequate. Preventive measures, such as dietary supplementation for the population at risk, may provide a valuable and cost effective long term solution to this problem and may also go some way to reduce the childhood disease burden in these regions. Also, education about bone health in children should be incorporated into maternal and child health care programmes.

ACKNOWLEDGEMENTS

We are grateful to Drs Akinyoola, Ogunsuyi, Ogunlusi, and Adegbehingbe for their clinical assistance and in collecting blood samples. This work was undertaken at the Robert Jones and Agnes Hunt Orthopaedic Hospital NHS Trust who received a proportion of its funding from the NHS executive. LMO was supported by a Wellcome Trust International Travel Grant. CAS was supported by the Bone Disease Foundation.

Authors' affiliations

L M Oginni, O S Badru, Departments of Orthopaedic Surgery and Traumatology, College of Health Sciences, Obafemi Awolowo University, Ile-Ife, Nigeria

C A Sharp, M W J Davie, M Worsfold, Charles Salt Research Centre, Robert Jones and Agnes Hunt Orthopaedic & District Hospital NHS Trust, Oswestry, Shropshire SY10 7AG, UK

J Risteli, Department of Clinical Chemistry, University of Oulu, Oulu, Finland

○ S Badru is deceased

REFERENCES

- 1 **Antia AU**. Observations on nutritional rickets in childhood. *West Afr Med J* 1970;**19**:169-72.
- 2 **Laditan AAO**, Adeniyi A. Rickets in Nigerian children—response to vitamin D. *J Trop Med Hyg* 1975;**78**:206-9.
- 3 **Pettifor JM**. Privational rickets: a modern perspective. *J R Soc Med* 1994;**87**:723-5.
- 4 **Okonofua F**, Gill DS, Alabi ZO, et al. Rickets in Nigerian children: a consequence of calcium malnutrition. *Metab Clin Exp* 1991;**40**:209-13.
- 5 **Oginni LM**, Worsfold M, Oyelami OA, et al. Etiology of rickets in Nigerian children. *J Pediatr* 1996;**128**:692-4.
- 6 **Mimouni F**. Etiology of nutritional rickets: geographic variations. *J Pediatr* 1996;**128**:600-1.
- 7 **Walker ARP**. Etiology of nutritional rickets: geographic variations [letter]. *J Pediatr* 1996;**130**:501.
- 8 **Barness LA**. Rickets: the chicken or the egg [letter]. *J Pediatr* 1996;**129**:941.
- 9 **Mawer EB**, Davies M. Vitamin D deficiency, rickets and osteomalacia, a returning problem world-wide. In: Norman AW, Bouillon R, Thomasset M, eds. *Vitamin D. Chemistry, biology and clinical applications of the steroid hormone*. University of California, Riverside, 1997:897-906.
- 10 **Fischer PR**, Rahman A, Cimma JP, et al. Nutritional rickets without vitamin D deficiency in Bangladesh. *J Trop Pediatr* 1999;**45**:291-3.
- 11 **Sierra OL**, Alarcon Y, Penaloza LN, et al. Fractional intestinal calcium absorption in children with rickets and controls from Cauca, Colombia. *J Bone Mineral Res* 2000;**15**(suppl 1):S357.
- 12 **Teotia M**, Teotia SPS, Singh KP. Endemic chronic fluoride toxicity and dietary calcium deficiency interaction syndromes of metabolic bone disease and deformities in India: year 2000. *Ind J Pediatr* 1998;**65**:371-81.
- 13 **Pettifor JM**, Ross FP, Wang J, et al. Rickets in children of rural origin in South Africa: is low dietary calcium a factor? *J Pediatr* 1978;**92**:320-4.
- 14 **Pettifor JM**, Ross FP, Travers R, et al. Dietary calcium deficiency: a syndrome associated with bone deformities and elevated serum 1,25 dihydroxyvitamin D concentration. *Metab Bone Dis Rel Res* 1981;**2**:301-5.
- 15 **Marie PJ**, Pettifor JM, Ross FP, et al. Histological osteomalacia due to dietary calcium deficiency in children. *N Engl J Med* 1982;**307**:584-8.
- 16 **Oginni LM**, Sharp CA, Worsfold M, et al. Healing of rickets after calcium supplementation. *Lancet* 1999;**353**:296-7.
- 17 **Thacher TD**, Fischer PR, Pettifor JM, et al. A comparison of calcium, vitamin D, or both for nutritional rickets in Nigerian children. *N Engl J Med* 1999;**341**:563-8.
- 18 **Scariano JK**, Vanderjagt DJ, Thacher T, et al. Calcium supplements increase the serum levels of crosslinked N-telopeptides of bone collagen and parathyroid hormone in rachitic Nigerian children. *Clin Biochem* 1998;**31**:421-7.
- 19 **Varley H**, Gowenlock AN, Bell M. *Practical clinical biochemistry, Vol 1*, 5th edn. London: Heinemann, 1980:868-72.
- 20 **Sharp CA**, Oginni LM, Worsfold M, et al. Elevated collagen turnover in Nigerian children with calcium-deficiency rickets. *Calcif Tissue Int* 1997;**61**:87-94.
- 21 **Worsfold M**, Sharp CA, Davie MWJD. Serum osteocalcin and other indices of bone formation: an 8-decade population study in healthy men and women. *Clin Chim Acta* 1988;**178**:225-36.
- 22 **Smyth EHJ**. Windswept deformity. *J Bone Joint Surg* 1980;**62B**:166-7.
- 23 **Thacher T**, Glew RH, Isichei C, et al. Rickets in Nigerian children: response to calcium supplementation. *J Trop Pediatr* 1999;**45**:202-7.
- 24 **Akpede GO**, Omatara BA, Ambe JP. Rickets and deprivation: a Nigerian study. *J R Soc Promotion Health* 1999;**119**:216-22.
- 25 **Legius E**, Proesmans W, Eggermont E, et al. Rickets due to calcium deficiency. *Eur J Pediatr* 1989;**148**:784-5.
- 26 **Pugliese MT**, Blumberg DL, Hludzinski J, et al. Nutritional rickets in suburbia. *J Am Coll Nutr* 1998;**17**:637-41.
- 27 **Vanderjagt DJ**, Peery B, Thacher T, et al. Aminoaciduria in calcium-deficiency rickets in Northern Nigeria. *J Trop Pediatr* 1999;**45**:258-64.
- 28 **Tomassi M**, Bacciottini L, Benucci A, et al. Serum biochemical markers of bone turnover in healthy infants and children. *Int J Biol Markers* 1996;**11**:159-64.
- 29 **Scariano JK**, Walter EA, Glew RH, et al. Serum levels of the pyridinoline crosslinked carboxyterminal telopeptide of type I collagen (ICTP) and osteocalcin in rachitic children in Nigeria. *Clin Biochem* 1995;**28**:541-5.
- 30 **Shaw NJ**, Wheeldon J, Brocklebank JT. Indices of intact serum parathyroid hormone and renal excretion of calcium, phosphate and magnesium. *Arch Dis Child* 1990;**65**:1208-11.
- 31 **Walter EA**, Scariano JK, Easington CR, et al. Rickets and protein malnutrition in Northern Nigeria. *J Trop Pediatr* 1997;**43**:98-102.
- 32 **Thacher T**, Fisher PR, Pettifor JM, et al. Case-control study of factors associated with nutritional rickets in Nigerian children. *J Pediatr* 2000;**137**:367-73.
- 33 **Nishi Y**, Atley L, Eyre DE, et al. Determination of bone markers in pyknodysostosis: effects of cathepsin K deficiency on bone matrix degradation. *J Bone Mineral Res* 1999;**14**:1902-8.
- 34 **Davidovits M**, Levy Y, Avramovitz T, et al. Calcium deficiency rickets in a four-year old boy with milk allergy. *J Pediatr* 1993;**122**:249-51.
- 35 **Fischer PR**, Thacher TD, Pettifor JM, et al. Vitamin D receptor polymorphisms and nutritional rickets in Nigerian children. *J Bone Mineral Res* 2000;**15**:2206-10.
- 36 **Ozgur S**, Sumer H, Kocoglu G. Rickets and soil strontium. *Arch Dis Child* 1996;**75**:542-6.
- 37 **Walker RW**, Masuki G, Kinabo G, et al. Calcium deficiency rickets in rural Tanzania: is part of the answer in the water? *Trans R Soc Trop Med Hyg* 1996;**90**:479.

COMMENTARY

Traditionally, nutritional rickets has been attributed to vitamin D deficiency. Increasing recent evidence, however, shows that calcium insufficiency can cause rickets. Oginni and colleagues further explore both the pathophysiology and management of nutritional rickets.

Nutritional rickets is common in Nigeria,¹ and several lines of pre- and post-treatment evidence indicate that calcium deficiency is central to its pathogenesis. First, dietary calcium insufficiency is frequent in Nigeria. In addition, vitamin D deficiency was not identified by Oginni and colleagues in most children with rickets, and rachitic children had raised levels of

1,25-dihydroxyvitamin D, the active form of vitamin D that increases in response to calcium deprivation. Then, when treated with calcium, levels of alkaline phosphatase and 1,25-dihydroxyvitamin D were normalised in rachitic children, and they achieved radiological resolution of bone changes. Clearly, calcium deficiency is important aetiologically, and therapeutic calcium is effective.

The pathogenesis of rickets depends on the net mineral deposition in bone as bioavailable calcium interacts with bone matrix, osteoblasts, and osteoclasts. The data of Oginni and colleagues suggest that osteoclastic activity, as measured by serum levels of type I collagen carboxy terminal cross linked telopeptide, is increased in children with active rickets and promptly normalises with calcium supplementation.

Vitamin D deficiency is associated with secondary hyperparathyroidism. The parathyroid response to rickets with calcium deficiency is less well characterised. As noted by Oginni and colleagues, other studies have yielded conflicting results about parathyroid hormone (PTH) levels. Further studies can help determine whether variations in PTH responses to calcium deficiency rickets are artefactual or result from a currently unidentified metabolic process.

What should be done for children thought to have rickets in resource limited settings? Clinical features such as widened wrists, rib beading, and limb deformity can support the diagnosis of rickets when radiographs are not available.² Adequate clinical evaluation of the child can then exclude non-nutritional causes of rickets such as familial hypophosphataemia, liver disease, renal insufficiency, and anticonvulsant use.

If a young child presents with active rickets after having had very limited sun exposure and there is no access to vitamin D testing, a therapeutic trial of vitamin D³ is indicated. If, however, rickets occurs despite a history of adequate sun exposure, especially after the first year of life, a therapeutic trial of calcium would be indicated. A previous study reported healing with 1000 mg of elemental calcium per day,⁴ and Oginni and colleagues have now shown adequate outcomes with just 350 mg per day. Since many calcium formulations exist, physicians must be attentive to the actual content of elemental calcium. When pharmacological calcium is not

readily available, supplementation with other sources of calcium such as dairy products, ground fish (with bones included), or limestone salts could be considered.

Oginni and colleagues, and others previously,⁴ found healing after six months of treatment; further studies might help determine whether shorter courses are actually sufficient. Whatever the duration of therapy, ongoing adequate calcium intake should be ensured. All children with rickets should be followed carefully. If the response to initial calcium or vitamin D treatment is incomplete (child not feeling any better within one month, biochemical and radiological abnormalities not improved within three months or not normalised within six months), further aetiological testing or different treatment might be needed. The effectiveness of casting and bracing has not been studied prospectively.

Many children in resource limited areas of the world still suffer from lack of "simple" nutrients such as vitamin D and calcium. Prevention of nutritional rickets would avoid significant morbidity and mortality; proven, effective, preventive strategies are needed.

P R Fischer

Professor of Pediatrics, Mayo Clinic, 200 First Street SW, Rochester, Minnesota, USA; fischer.phil@mayo.edu

L M Oginni, O S Badru, Departments of Orthopaedic Surgery and Traumatology, College of Health Sciences, Obafemi Awolowo University, Ile-Ife, Nigeria

C A Sharp, M W J Davie, M Worsfold, Charles Salt Research Centre, Robert Jones and Agnes Hunt Orthopaedic & District Hospital NHS Trust, Oswestry, Shropshire SY10 7AG, UK

J Risteli, Department of Clinical Chemistry, University of Oulu, Oulu, Finland

O S Badru is deceased

REFERENCES

- 1 Pfitzner MA, Thacher TD, Pettifor JM, *et al.* Absence of vitamin D deficiency in young Nigerian children. *J Pediatr* 1998;**133**:740–4.
- 2 Thacher TD, Fischer PR, Pettifor JM. The usefulness of clinical features to identify active rickets. *Ann Trop Paediatr* 2002;**22**:229–37.
- 3 Ozuah PO, Adam HM. Planning the treatment of a patient who has rickets. *Pediatr Rev* 2000;**21**:286.
- 4 Thacher TD, Fischer PR, Pettifor JM, *et al.* A comparison of calcium, vitamin D, or both for nutritional rickets in Nigerian children. *N Engl J Med* 1999;**341**:563–8.