

CASE REPORT

Subcutaneous fat necrosis of the newborn: hypercalcaemia with hepatic and atrial myocardial calcification

J Dudink, F J Walther, R P Beekman

Arch Dis Child Fetal Neonatal Ed 2003;**88**:F343–F345

Subcutaneous fat necrosis of the newborn (SCFN) is a very rare disorder, which can be complicated by hypercalcaemia and thrombocytopenia. The case is presented of an infant with SCFN and symptomatic hypercalcaemia, who developed calcifications in the liver, the inferior vena cava, and the atrial septum of the heart. The hypercalcaemia was treated with hyperhydration, frusemide, glucocorticoids, and a diet low in calcium and vitamin D. Clinical features, diagnosis, complications, and treatment of this rare condition are discussed.

Subcutaneous fat necrosis of the newborn (SCFN) is a rare condition of unknown pathophysiology, characterised by erythematous to violaceous, firm, and painful subcutaneous nodules. The skin lesions are mainly found on the face, trunk, buttocks, and proximal extremities and appear soon after birth up to four weeks after delivery. Normally SCFN is a self limiting condition in which the skin lesions resolve spontaneously within weeks to months.^{1,2} Hypercalcaemia is a complication of SCFN, which can be life threatening if not treated adequately.^{3–8}

CASE REPORT

A female infant was delivered full term by caesarean section because of fetal distress. The pregnancy had been uncomplicated, except that the mother was admitted two days before the delivery because of an accidental fall. The birth weight was

3100 g. Apgar scores were 3, 7, and 8 at one, five, and 10 minutes. The baby was intubated and placed on mechanical ventilation for respiratory failure. The cord arterial pH was 6.85 and the base deficit 18.1 mmol/l. Blood cultures were drawn, and the infant received amoxicillin and gentamicin. A chest radiograph showed cardiac enlargement with clear lung fields. Echocardiography showed pulmonary hypertension with right to left shunting across the patent foramen ovale and ductus arteriosus. After 24 hours, mechanical ventilation could be discontinued, and the respiratory failure after birth was ascribed to persistent pulmonary hypertension following birth asphyxia. Blood cultures remained negative.

On the third day, the infant developed a red, painful, nodular swelling on her back with a diameter of 5 cm, suggestive of a bacterial skin infection. Laboratory investigation included: haemoglobin, 152 g/l; platelets, $56 \times 10^9/l$; white blood cells, $13 \times 10^9/l$; normal coagulation. Total calcium level was 2.8 mmol/l (normal range 2.1–2.6 mmol/l), ionised calcium level was 1.55 mmol/l (normal range 1.0–1.4 mmol/l), and 1,25-hydroxyvitamin D concentration was 160 pmol/l (normal range 40–140 pmol/l). Parathyroid hormone level was < 1.0 pmol/l, and parathyroid-like protein level was < 0.1 pmol/l. Serum calcium levels continued to increase progressively (maximum value 3.5 mmol/l on day 30), despite treatment with hydration (180 ml/kg/day) and frusemide (2 mg/kg/day). The hypercalcaemia became symptomatic, with vomiting, anorexia, and agitation. Because the skin lesions became more painful, first acetaminophen and later morphine (0.02 mg/kg/h) were administered. The hypercalcaemia and skin lesions started to resolve after treatment with prednisone (2 mg/kg/day) and a milk formula low in calcium and vitamin D (Basic CaD; Milupa, Friedrichshof, Germany). Within five days, total and ionised calcium levels normalised (day 35). Corticosteroid treatment was discontinued after one week, and the special milk formula and diuretics after one month.

A repeat echocardiogram depicted an echodense lesion in the atrial septum (fig 1), which was diagnosed as calcification on a computed tomographic scan (fig 2). Calcifications were also seen in the inferior vena cava and liver (fig 3).

Follow up by the family doctor showed normal physical and neurological development. A repeat echocardiogram and computed tomographic scan were declined by the parents.

DISCUSSION

SCFN is a rare, often painful condition of unknown pathophysiology. It usually occurs in the first week of life following a complicated delivery and is characterised by very painful, firm, indurated, erythematous nodules and plaques over the buttocks, trunk, arms, and cheeks. Newborns who develop SCFN are usually healthy and full term at delivery, but have had some obstetric trauma, meconium aspiration, asphyxia, hypothermia, or hypoxaemia. Owing to its benign, self limiting course, SCFN is thought to be underdiagnosed,

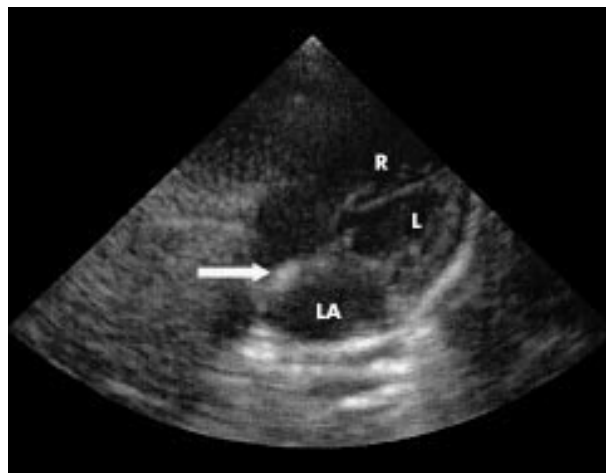


Figure 1 Echocardiographic subcostal four chamber view of the heart depicting the left atrium (LA) with the arrow pointing to the echodensity in the atrial septum. R, Right ventricle; L, left ventricle.

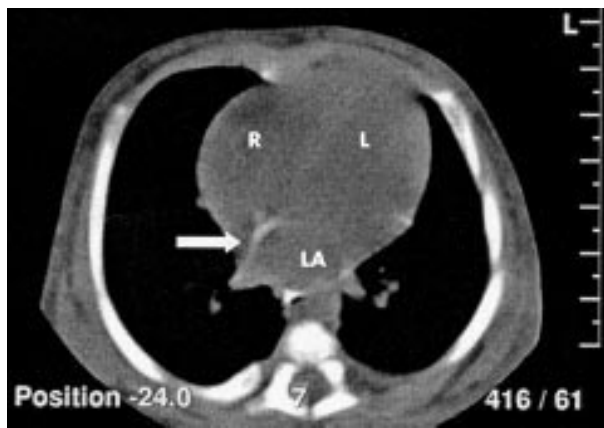

Figure 2 Computed tomographic image of an axial plane through the heart depicting the left atrium (LA) with the arrow pointing to the atrial septum. Note that the image intensity of the atrial septum approaches that of the ribs and is more intense than the ventricular walls and ventricular septum, which cannot be clearly distinguished. R, Right ventricle; L, left ventricle.

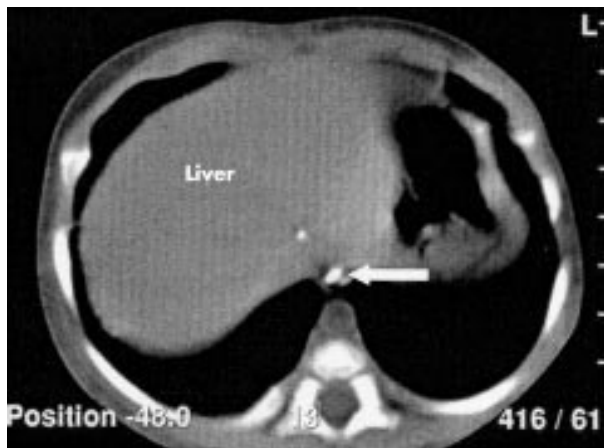

Figure 3 Computed tomographic image of an axial section through the upper abdomen depicting the liver with one spot in the parenchyma. The arrow points to a white spot in the inferior vena cava.

and its incidence is unknown. No racial or sex preference has been reported.

The cause and pathogenesis of SCFN are not known. It has been postulated that cold or stress induced injury to immature fat, resulting in necrosis and the development of a granulomatous infiltrate, may play a role in initiating the process.⁹ Various mechanisms for the development of the necrosis have been proposed: (a) an underlying defect in neonatal fat metabolism, resulting in an increase in saturated fatty acids within the subcutaneous tissue, which, exacerbated by neonatal stress, may precipitate this condition⁴; (b) fat necrosis caused by local trauma during delivery⁴; (c) hypothermia causing the neonatal fat, which is composed of saturated fatty acids with a relatively high melting point, to crystallise.^{9, 10} The areas of fat necrosis seldom progress to atrophy, scarring, or ulceration.

SCFN is a harmless, self limiting condition, but appreciable morbidity and mortality can result from the associated hypercalcaemia, the pathogenesis of which is not known.³⁻⁸ Potential causes include increased prostaglandin activity leading to osteoclast activation, calcium release from necrotic fat cells, and increased production of 1,25-dihydroxyvitamin D by

macrophages, leading to increased bone turnover.¹¹⁻¹³ The incidence of hypercalcaemia as a complication is uncertain. If mild hypercalcaemia is present, symptoms may be absent, or the child may display irritability, weight loss, apathy, or hypotonia.

Another known complication of SCFN is thrombocytopenia. It is postulated that the thrombocytopenia in newborns with SCFN may reflect local sequestration within the subcutaneous tissue.¹⁴ Increased levels of prostaglandin E have been reported in SCFN.¹⁵ When prostaglandin E is used therapeutically in newborns, thrombocytopenia is a known side effect. We postulate that there may be an association between the raised prostaglandin E levels and the thrombocytopenia in SCFN.

The tendency for calcification to occur in the atrial septum, inferior vena cava, and liver in this case is interesting, and has to our knowledge not previously been reported. It seems reasonable to assume that the hypercalcaemia and calcification are related. Well known causes of calcification, such as occur in atheromatous plaques or in neonatal hearts with systemic lupus erythematosus, do not appear to play a part. Congenital causes of soft tissue calcification can also be excluded because calcification of the atrial septum was not seen at the initial echocardiographic examination. The seven cases of massive myocardial calcification in the perinatal period reported by Drut *et al*¹⁶ have myocardial damage in common, although atrial myocardial calcification was not seen. In our case, perinatal asphyxia may have caused myocardial damage, but we have no proof of this. The initial echocardiographic findings depicted evidence of pulmonary hypertension, but not of depressed ventricular function. The massive myocardial calcification may represent the human counterpart of so called dystrophic cardiac calcinosis, a genetic disorder in mice.

When hypercalcaemia occurs, the first line of treatment is hyperhydration and calcium wasting diuretics (such as frusemide) and a milk formula with low calcium and vitamin D content.^{4, 7} Prednisone is used when these measures fail. Glucocorticoids interfere with the metabolism of vitamin D to its active form (1,25-hydroxyvitamin D) and also inhibit the production of 1,25-hydroxyvitamin D by the macrophages involved in the inflammatory process.¹⁰⁻¹² Short term etidronate (bisphosphonate) treatment has been used successfully to control hypercalcaemia by reducing bone resorption,⁷ but whether the cause of hypercalcaemia in SCFN is due to enhanced bone resorption has been questioned.¹⁷ As the serum calcium levels can be elevated for months, even after recovery from fat necrosis, serum calcium levels should be checked periodically.

Although SCFN and hypercalcaemia are rare complications in neonates with perinatal problems, the sequelae of hypercalcaemia can be life threatening. A neonate who develops skin lesions consistent with SCFN should therefore be followed for the possible onset of hypercalcaemia.

ACKNOWLEDGEMENTS

Thanks go to Dr Tjong a Lieng from the Radiology Department at the LUMC for assistance with computed tomography.

Authors' affiliations

J Dudink, F J Walther, R P Beekman, Department of Paediatrics, Divisions of Neonatology and Paediatric Cardiology, Leiden University Medical Center, Leiden, The Netherlands

J Dudink, Department of Paediatrics, Reinier de Graaf Gasthuis, Delft, The Netherlands

Correspondence to: Dr Walther, Department of Paediatrics, Division of Neonatology, Leiden University Medical Center, PO Box 9600, 2300 RC Leiden, The Netherlands; fwalther@lumc.nl

Accepted 26 September 2002

REFERENCES

- 1 **Burden AD**, Krafchik BR. Subcutaneous fat necrosis of the newborn: a review of 11 cases. *Pediatr Dermatol* 1999;**16**:384-7.
- 2 **Caple JI**, Reyes S. Subcutaneous fat necrosis of the newborn: a case presentation. *J Perinatol* 1996;**16**:140-1.
- 3 **Thomsen RJ**. Subcutaneous fat necrosis of the newborn and idiopathic hypercalcemia. *Arch Dermatol* 1980;**116**:1155-8.
- 4 **Hicks MJ**, Levy ML, Alexander J, *et al*. Subcutaneous fat necrosis of the newborn and hypercalcemia: case report and review of the literature. *Pediatr Dermatol* 1993;**10**:271-6.
- 5 **Ghirri P**, Bottone U, Coccoli L, *et al*. Symptomatic hypercalcemia in the first months of life: calcium-regulating hormones an treatment. *J Endocrinol Invest* 1999;**22**:349-53.
- 6 **Lum CK**, Solomon I, Bachrach LK. Asymptomatic hypercalcemia in subcutaneous fat necrosis. *Clin Pediatr* 1999;**38**:547-50.
- 7 **Rice AM**, Rivkees SA. Etidronate therapy for hypercalcemia in subcutaneous fat necrosis of the newborn. *J Pediatr* 1999;**134**:349-51.
- 8 **Puzenat E**, Aubin F, Zyka F, *et al*. Subcutaneous fat necrosis of the newborn with hypercalcemia. *Ann Dermatol Venerol* 2000;**127**:1087-9.
- 9 **Chuang SD**, Chiu HC, Chang CC. Subcutaneous fat necrosis of the newborn complicating hypothermic cardiac surgery. *Br J Dermatol* 1995;**132**:805-10.
- 10 **Silverman AK**, Michels EH, Rasmussen JE. Subcutaneous fat necrosis in an infant, occurring after hypothermic cardiac surgery. *J Am Acad Dermatol* 1986;**15**:331-6.
- 11 **Kruse K**, Irle U, Uhlig R. Elevated 1,25-dihydroxyvitamin D serum concentrations in infants with subcutaneous fat necrosis. *J Pediatr* 1993;**122**:460-3.
- 12 **Cook JS**, Stone MS, Hansen JR. Hypercalcemia in association with subcutaneous fat necrosis of the newborn: studies of calcium-regulating hormones. *Pediatrics* 1992;**90**:93-6.
- 13 **Finne PH**, Sanderud J, Aksnes L, *et al*. Hypercalcemia with increased and unregulated 1,25-dihydroxyvitamin D production in a neonate with subcutaneous fat necrosis. *J Pediatr* 1987;**112**:792-4.
- 14 **Chen TH**, Shewmake SW, Hansen DD, *et al*. Subcutaneous fat necrosis of the newborn. A case report. *Arch Dermatol* 1981;**117**:36-7.
- 15 **Sharata H**, Postellon DC, Hashimoto K. Subcutaneous fat necrosis, hypercalcemia and prostaglandin E. *Pediatr Dermatol* 1995;**12**:43-7.
- 16 **Drut R**, Drut RM, Greco MA. Massive myocardial calcification in the perinatal period. *Pediatr Dev Pathol* 1998;**1**:366-74.
- 17 **Bachrach LK**, Lum CK. Etidronate in subcutaneous fat necrosis of the newborn. *J Pediatr* 1999;**135**:530-1.

IMAGES IN NEONATAL MEDICINE.....

Stethoscope head to body weight ratios in the extremely preterm infant

It has been our observation that large nursing style stethoscopes are often used on extremely premature infants, whereas paradoxically a smaller neonatal stethoscope is usually used for the term neonate. Stethoscope heads were weighed using precision scales, and a ratio of stethoscope head weight to baby weight was calculated (SHBW ratio). This somewhat crude ratio does not take into account the added effect of the clinician pressing the stethoscope on to the chest. The weight of a large stethoscope head was 41 g and that of a small stethoscope head was 28 g. Figure 1 shows auscultation of a 25 week baby weighing 675 g. The SHBW ratio was 1:15 for the large stethoscope head shown.

Auscultation with a large stethoscope head may place undue force on the chest or abdomen of a tiny baby. Using the same ratio (1:15), a 70 kg male would have a stethoscope head weighing 4.4 kg placed on his chest, an uncomfortable experience for both patient and examiner! Auscultation and the associated pressure applied by the auscultator may well be an unpleasant experience for extremely low birthweight infants. Care should be taken to use the smallest stethoscope possible and to apply minimal pressure when examining low birthweight infants.

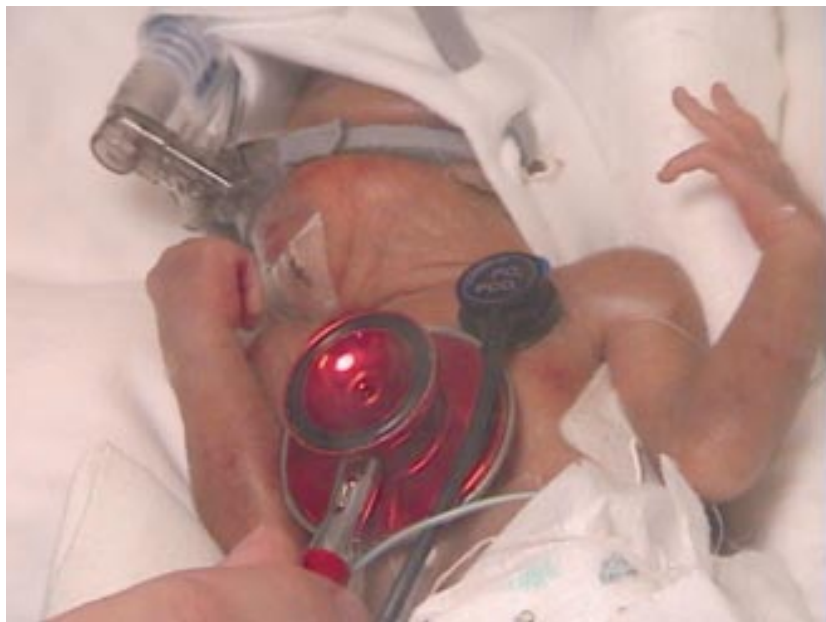

Figure 1 Auscultation of a premature (25 weeks gestation) baby.

D S Urquhart, V P Balasubramaniam
Neonatal Unit, Northwick Park Hospital, Watford
Road, Harrow, Middlesex HA1 3UJ, UK;
donurquhart72@doctors.org.uk