

LETTERS TO THE EDITOR

Human T cell lymphotropic virus type I associated uveitis in a child

EDITOR.—Human T cell lymphotropic virus type I (HTLV-I) has been shown to cause two systemic diseases: a haematological malignancy termed adult T cell leukaemia/lymphoma (ATL)¹ and a chronic progressive neurological disease, known as HTLV-I associated myelopathy or tropical spastic paraparesis (HAM/TSP).^{2,3} Among HTLV-I infected individuals, a certain type of uveitis has been reported,⁴ which responds to corticosteroids and visual outcome is usually favourable.⁵ Although perinatal virus transmission occurs frequently via breast feeding and saliva,⁶ the HTLV-I seroprevalence increases with age.⁴ We report here a child with severe HTLV-I associated uveitis (HAU).

CASE REPORT

A 12-year-old girl was admitted with abrupt onset of blurred vision and decreased visual acuity in the right eye. Her visual acuity was right eye, 0.02 and left eye, 0.8. Ocular examination revealed vitreous and retinal haemorrhages in the right eye and scarred retinal vasculitis in the left eye. She was suspected to have an acute posterior and intermediate uveitis. Physical examination demonstrated no evidence of arthritis, pulmonary involvement, hepatosplenomegaly, or neurological abnormalities. Laboratory examinations of peripheral blood, coagulation studies, autoantibodies to nuclear antigen and rheumatoid factor revealed no systemic abnormalities, and studies of antibodies to viruses including rubella, cytomegalovirus, herpes simplex virus, Epstein-Barr virus, varicella zoster virus, and *Toxoplasma gondii* indicated previous infections or no evidence of infection. Examination of the patient's serum revealed the antibody to HTLV-I by both particle agglutination assay (PA) and ELISA, which was confirmed by western blot. The PA titre for HTLV-I was initially 1:256 and increased to 1:8192 over the next 4 months. Provirus detection by polymerase chain reaction (PCR) using peripheral blood mononuclear cells was positive for HTLV-I DNA. The patient's mother was an asymptomatic carrier of HTLV-I. The girl was, therefore, diagnosed as having HTLV-I associated uveitis (HAU). Along with topical steroid eyedrops, 1 ml of intravenous liposteroid, consisting of lipid

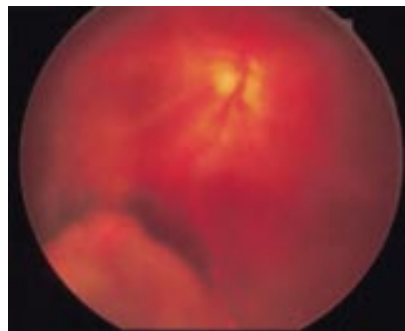


Figure 1 Fundus photograph of the right eye 3 weeks after vitrectomy. Diffuse vitreous opacities, irregular dilatation of retinal vessels, and subretinal exudate. Segmental protrusion is seen at the inferotemporal quadrant after buckling surgery for an iatrogenic break.

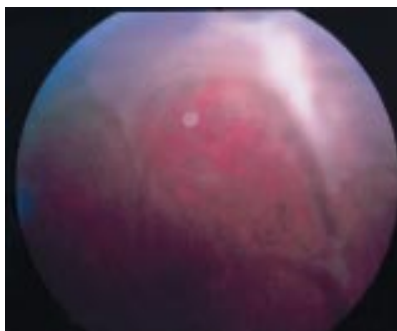


Figure 2 Fundus photograph of the left eye. Membranous tent-like vitreous opacity is seen in the periphery.

emulsified dexamethasone (L-Dx) microspheres (Limethason 1 ml; dexamethasone palmitate 4 mg) was injected twice a week in order to target steroids to the topical, ocular inflammatory lesion and to minimise adverse effects.⁷ By 3 weeks, the uveitis had nearly resolved, and injections of L-Dx were decreased. Her visual acuity of the right eye improved to right eye, 0.3. Six weeks later, a flaring of uveitis and retinal bleeding with iritis in right eye after a flu-like infection occurred. Visual acuity was right eye, 0.01 and left eye, 1.0. L-Dx injections were initiated twice a week again, and the acute inflammation improved within 3 weeks. However, retinal detachment and vitreous opacities in the right eye ultimately developed, which prompted surgical treatment (pars plana vitrectomy, three port system, 20% SF₆ exchange) (Figs 1 and 2). The fluid in the anterior chamber contained antibodies to HTLV-1 (1:160 by PA assay).

COMMENT

We report here a child with severe HAU associated with carriage of HTLV-I. The age of onset of HAU has been reported to be distributed from 19 years to 75 years (mean 46.03 (SD3.1) years),⁸ making our patient one of the youngest reported to date.

The diagnosis of HAU is based on the sudden onset of uveitis without defined causes, in addition to a seropositive result for antibodies to HTLV-I.⁹ Although some patients with ATL or HAM/TSP develop idiopathic granulomatous anterior uveitis, patients with HAU show no signs of neurological or haematological abnormalities except for antibodies to HTLV-I.⁹ Our patient satisfied these two criteria, and the titre of anti-HTLV-I antibody increased during the course of her disease. Moreover, proviral DNA was positive, which further contributed to confirm the diagnosis.

Unilateral intermediate and posterior uveitis was the initial ocular lesion in this case, ultimately progressing to panuveitis in both eyes. This explains the poor ocular prognosis in this child, who needed surgical therapy, although the visual acuity of most HAU patients is good (63%) or fairly good (24%).¹⁰ The retinal detachment presumably occurred by the traction of vitreous with neovascularisation as we could not find any retinal break during the vitreous surgery. Although this patient was free from haematological and neurological manifestations, it remains to be

established whether HAU is predictive of the subsequent development of other HTLV-I associated diseases.

SHIGEKI KATAKURA

Division of Pediatric Rheumatology,
Department of Pediatrics

YASUHIITO IJIMA

Department of Ophthalmology, Yokohama City
University School of Medicine

TOMOYUKI IMAGAWA

ETSUROU TOKUHIRO

Division of Pediatric Rheumatology,
Department of Pediatrics

SATOSHI NAKAMURA

KAZUROH YABUKI

JUNICHI YONEMOTO

SHIGEAKI OHNO

Department of Ophthalmology, Yokohama City
University School of Medicine

SHUMPEI YOKOTA

Division of Pediatric Rheumatology,
Department of Pediatrics

Correspondence to: S Yokota, MD, Department of Pediatrics, Yokohama City University School of Medicine, 3-9 Fukuura, Kanazawa-ku, Yokohama, Kanagawa 236, Japan.

Accepted for publication 4 June 1997

- Hinuma Y, Nagata K, Hanaoka M, Nakai M, Matsumoto T, Kinoshita K, *et al*. Adult T-cell leukemia: antigen in an ATL cell line and detection of antibodies to the antigen in human sera. *Proc Natl Acad Sci USA* 1981;78:6476-80.
- Gessain A, Barin F, Vernant JC, Gour O, Maurs J, Calender A, *et al*. Antibodies to human T-lymphotropic virus type I in patients with tropical spastic paraparesis. *Lancet* 1985;ii:407-10.
- Osame M, Usuku K, Izumo S, Ijichi N, Amitani H, Igata A, *et al*. HTLV-I-associated myelopathy, a new clinical entity. *Lancet* 1986;ii:1031-2.
- Nakao K, Matsumoto M, Ohba N. Seroprevalence of antibodies to HTLV-I in patients with ocular disorders. *Br J Ophthalmol* 1991;75:76-8.
- Mochizuki M, Watanabe T, Yamaguchi K, Tajima K, Yoshimura K, Nakashima B, *et al*. Uveitis associated with human T lymphotropic virus type I: seroepidemiological, clinical, and virological studies. *J Infect Dis* 1992;166:943-4.
- Komuro A, Hayami M, Fujii H. Vertical transmission of ATL virus. *Lancet* 1983;ii:240.
- Shouji Y, Mizushima Y, Yanagawa A, Yonaha T. Electron microscopic studies on tissue distribution of lipid microspheres used as drug delivery carriers. *Drug Exp Clin Res* 1985;11:601-9.
- Yoshimura K, Mochizuki M, Araki S, Miyata N, Yamaguchi K, Tajima K, *et al*. Clinical and immunological features of human T lymphotropic virus type I uveitis. *Am J Ophthalmol* 1993;116:156-63.
- Mochizuki M, Tajima K, Watanabe T, Watanabe T, Yamaguchi K. Human T lymphotropic virus type I uveitis. *Br J Ophthalmol* 1994;78:149-54.
- Yoshimura K, Mochizuki M, Araki S, Miyata N, Yamaguchi K, Tajima K, *et al*. Clinical and immunological features of human T-cell lymphotropic virus type I uveitis. *Am J Ophthalmol* 1993;116:156-63.

A case of meningococcal endophthalmitis in a well patient

EDITOR.—We report a previously well 17-year-old man who presented with a 1 day history of misty vision, pain in the right eye, and hypopyon. This latter proved to be due to metastatic meningococcal endophthalmitis. Despite appropriate therapy, the vision deteriorated to perception of light only in a matter of days, with no recovery of function.

Metastatic endophthalmitis is a rare presentation of meningococcal septicaemia, and should be considered in the differential

diagnosis of a rapid onset hypopyon uveitis, even in a well patient.

This young man's case was extremely unusual. The patient had demonstrable systemic meningococcal infection, and yet was well and afebrile at presentation, and throughout his admission.

CASE REPORT

A 17-year-old man was referred to eye casualty by his general practitioner, with a 1 day history of misty vision and pain in the right eye, which was unresponsive to topical antibiotics. His general practitioner had noted myalgia and arthralgia with a sore throat 4 days previously, the patient had felt transiently feverish, but had apparently remained afebrile and was otherwise well. There was nothing else in the history of note, in particular no past ocular or medical history, and on direct questioning there had been no sexual contacts or intravenous drug use.

On examination the vision was hand movements in the right, and 6/5 in the left. He had a very injected right eye, with an oedematous cornea, a 2.4 mm hypopyon, fibrin in the anterior chamber, and the pupil was bound down with posterior synechiae. There was no view of the fundus, and there was no afferent pupillary deficit. The left eye and intraocular pressures were normal.

Systemically he was afebrile with a normal blood pressure, a pulse of 80, and a normal neurological examination without meningism. There was no ulceration of the mucous membranes. He was found to have a fading vesicular rash over his feet and ankles.

He was admitted and treated for the very acute anterior uveitis, with subconjunctival Betnesol (betamethasone) and mydracaine and subsequently with hourly drops of Pred Forte (prednisolone) and twice daily atropine 1%. Investigations revealed a slightly raised white cell count and raised inflammatory markers (erythrocyte sedimentation rate and C reactive protein). The rash was biopsied and shown to be vasculitic in nature. Blood cultures, viral titres, and urine were also sent for analysis but all were negative. He seemed to improve over the next 24 hours.

At 48 hours from presentation, the patient had developed a dense right afferent pupillary defect, and the vision was reduced to perception of light in this eye. Orbital x ray and B scan ultrasonography were unremarkable and a diagnostic vitrectomy was performed; vancomycin 2 mg, ceftazidime 2 mg, and amphotericin 5 µg were administered intravitreally. Initial microscopy of the vitreous sample revealed no infective agents, but the following day a single Gram negative diplococcus was isolated, assumed to be *Neisseria meningitidis*. The patient was commenced on intravenous penicillin 2.4 g six times daily, and oral rifampicin 600 mg twice daily, with intensive topical cefuroxime and gentamicin Forte eye-drops. The organism was cultured and confirmed as *N meningitidis* sensitive to gentamicin, cefuroxime, penicillin, and chloramphenicol. Further blood cultures and throat swabs failed to grow any bacteria.

After 7 days of intravenous antibiotics under the joint care of ophthalmologists and physicians, the patient was allowed home, and topical treatment was gradually reduced over the next few weeks.

The right eye remained comfortable, with a clear cornea, a quiet anterior chamber, and a dense cataract. Vision was vague perception of light, and the dense relative afferent pupillary

defect persisted; the retina remained flat on B scan ultrasonography.

COMMENT

Meningococcal infections can present as a spectrum of disorders from fulminant septicaemia with meningitis to infections of individual systems.

Endophthalmitis may be exogenous or endogenous. Before the modern antibiotic era, the most common form of endophthalmitis was endogenous meningococcal disease, occurring in about 5% of meningococcal cases.¹ Recently, endogenous endophthalmitis is more commonly seen in immunocompromised patients, diabetics, and intravenous drug users and *N meningococcus* has been replaced by *Bacillus cereus* as the leading causative bacterial agent. Even so, metastatic bacterial endophthalmitis is relatively unusual, with 72 reported cases between 1976 and 1985, eight of these were caused by *N meningitidis*.² Since then only five other cases have been attributed to *N meningitidis*.³⁻⁶

Most of these cases describe patients who are systemically unwell, with fulminant septicaemia, or pyrexia with meningitis or with concurrent gastrointestinal or musculoskeletal symptoms. There have been only a few cases described where the systemic illness has been less dramatic or where the patients have not been unwell at the time of presentation.

Auerbach *et al* in 1989 presented a 13-month-old boy with endophthalmitis, a spontaneously resolving rash, and a persistent pyrexia where *N meningitidis* was found in the vitreous but not blood.⁴ Residual vision was slight after appropriate topical and intravenous antibiotics, but diagnosis was delayed by the atypical presentation. Brisner and Hess in 1981 described a 15-year-old girl with a rash and arthralgia which had resolved by the time eye symptoms and endophthalmitis developed.³ She remained slightly pyrexial. *N meningitidis* was isolated from the aqueous and vitreous, but not from the blood. She was left with HM vision and a dense cataract. Kearns and Sprott in 1991 presented a similar case, where a 23-year-old man had pyrexia and myalgia only at the time of presentation with his eye symptoms and endophthalmitis, but who despite appropriate therapy was left with perception of light vision only in the affected eye.⁵ Abousaasha *et al* presented a case of a man unwell at presentation with GI symptoms and with positive blood cultures, who developed a rash after presentation with endophthalmitis. This patient had a final visual acuity of 6/12.⁶

Our patient was very unusual in being well at presentation, despite having had a systemic meningococcal infection. He had negative blood cultures and he remained afebrile throughout. He had myalgia and a rash several days before presentation which presumably represented a bacteraemic event.

These cases demonstrate the occasional atypical presentation of metastatic meningococcal endophthalmitis. We should be aware of this diagnosis, even in seemingly systemically well patients, as the visual outcome is often poor despite aggressive and prompt therapy.

TAMSIN SLEEP

Department of Ophthalmology, Queen's Medical Centre, University Hospital NHS Trust, Nottingham NG2 7UH

MARK GRAHAM

Department of Ophthalmology, Torbay General Hospital, Torquay, Devon

Correspondence to: Ms T Sleep.

Accepted for publication 9 July 1997

- Lewis PW. Ocular complications of meningococcal meningitis: observations in 350 cases. *Am J Ophthalmol* 1940;23:617-32.
- Greenwald MJ, Wohl LG, Sell C. Metastatic bacterial endophthalmitis: a contemporary reappraisal. *Surv Ophthalmol* 1986;31:81-101.
- Brisner JH, Hess JB. Meningococcal endophthalmitis without meningitis. *Can J Ophthalmol* 1981;16:100-1.
- Auerbach SB, Leach CT, Bateman BJ, Sidikaro Y, Cherry LD. Meningococcal endophthalmitis without concomitant septicaemia or meningitis. *Pediatr Infect Dis J* 1989;8:411-3.
- Kearns AM, Sprott MS. Endophthalmitis caused by *Neisseria meningitidis*. *J Infect* 1991;22:299-300.
- Abousaasha F, Dogar GF, Young BJ, O'Hare J. Endophthalmitis as a presentation of meningococcal septicaemia. *Irish J Med Sci* 1993;162:495-6.

Ultrasound biomicroscopy of acute glaucoma in a patient with metastatic cancer

EDITOR,—Determination of the mechanism of acutely elevated intraocular pressure is extremely difficult if not impossible in the presence of impaired transparency of the anterior ocular segment. Ultrasound biomicroscopy (UBM), a high resolution (50 MHz) ultrasonographic technique, can be helpful in determining the underlying mechanisms in such a case.^{1 2}

CASE REPORT

A 61-year-old man presented with severe pain and profound visual impairment in his right eye. Ophthalmic examination revealed visual acuities of hand movement in the right eye and 20/30 in the left. Intraocular pressure (IOP) was 53 mm Hg in the right eye and 14 mm Hg in the left. Slit lamp biomicroscopy and gonioscopy of the left eye revealed a clear cornea, deep anterior chamber, normal iris, and wide open angles. In contrast, the right eye showed generalised corneal oedema and turbid aqueous with 4+ cellular reaction and a 2 mm hypopyon. The anterior chamber appeared deep; however, the angle structures could not be visualised on attempted gonioscopy (Fig 1). The left ocular fundus was unremarkable, but the right fundus could not be visualised.

Review of the patient's medical history elicited report of a 'brain tumour' and 'metastatic cancer in the lungs'. We were concerned about the possibility of metastatic carcinoma to the iris or ciliary body as the underlying mechanism.

B-scan ultrasonography of the right eye revealed a dense cataract and particulate intravitreal echoes consistent with inflammatory cells but no retinal detachment, choroidal detachment, intraocular tumour, or foreign body. UBM of the right eye, using the

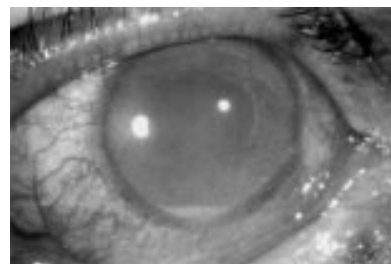

Figure 1 Slit lamp appearance, demonstrating severe clouding of anterior media.

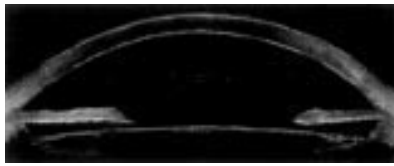

Figure 2 Reconstructed ultrasound biomicroscopic image (merging of adjacent horizontal images through midsection and nasal and temporal chamber angle using graphics program Photoshop), demonstrating a wide open angle, cell clumps in the aqueous and a thin elongated lens.

Humphrey UBM 840 system (Humphrey Instruments Inc, San Leandro, CA, USA), demonstrated a deep anterior chamber, open angles, and multiple cells and cell clumps in the aqueous. The lens appeared to be elongated but thin and exhibited capsular wrinkling and thickening (Fig 2). There was no evidence of focal or diffuse nodularity of the iris or ciliary body. The mechanism of acute intraocular pressure elevation and inflammation was therefore assumed to be phacolytic glaucoma.

The patient was treated medically with topical anti-inflammatory and antihypertensive medications until urgent uneventful extracapsular cataract surgery with posterior chamber lens implantation could be performed. Visual acuity recovered to 20/60, intraocular inflammation resolved, and IOP returned to normal without medications. Unfortunately, he died of complications related to his cancer 6 weeks after surgery. The eye was not obtained post mortem.

COMMENT

Diagnostic considerations in a patient with acutely elevated IOP associated with hypopyon and a medical history of active metastatic cancer include microbial forms of inflammation related to immunosuppression, metastatic carcinoma to the iris and ciliary body, and non-microbial forms of inflammation, such as lens induced uveitis, unrelated to the neoplastic disorder. Conventional B-scan ultrasonography did help partially to clarify the differential diagnosis by ruling out a posterior segment tumour. UBM revealed partial collapse of the lens, indicative of probable liquefaction of the lens cortex, leakage of lens material into the aqueous, and showed no evidence of metastatic processes. UBM findings were complementary to the conventional B-scan ultrasonography in this case and led to the presumptive diagnosis of phacolytic glaucoma and subsequent prompt, appropriate, and effective treatment for this disorder.³

In eyes with acutely elevated IOP and opacification of the anterior optical media, UBM should be considered a potentially helpful diagnostic adjunct.

INES M LANZL

Glaucoma Service, Wills Eye Hospital, Jefferson Medical College, Thomas Jefferson University, Philadelphia, Pennsylvania, USA

JAMES J AUGSBURGER

Retina Service, Wills Eye Hospital, Jefferson Medical College, Thomas Jefferson University, Philadelphia, Pennsylvania, USA

AUGUSTO AZUARA

MATTHEW R RUNDE

COURTLAND M SCHMIDT

Glaucoma Service, Wills Eye Hospital, Jefferson Medical College, Thomas Jefferson University, Philadelphia, Pennsylvania, USA

Correspondence to: James J Augsburger, MD, 900 Walnut Street, Philadelphia, PA 19107-5598, USA.

Accepted for publication 4 June 1997

- 1 Pavlin CJ, Harasiewicz K, Eng P, Foster FS. Ultrasound biomicroscopy of anterior segment structures in normal and glaucomatous eyes. *Am J Ophthalmol* 1992;113:381-9.
- 2 Pavlin CJ, Foster FS. Ultrasound biomicroscopy in glaucoma. *Acta Ophthalmol* 1992;70(suppl): 7-9.
- 3 Ellant JP, Obstbaum SA. Lens-induced glaucoma. *Doc Ophthalmol* 1992;81:317-38.

Non-caseating granulomas as a cause of ischaemic retinal vasculitis

EDITOR.—Retinal vasculitis (RV) can be classified into ischaemic and non-ischaemic forms according to fluorescein angiographic findings: ischaemic RV is characterised by venous or capillary closure, or both. The aetiology of vascular closure in ischaemic RV is not clear, and histological evidence is scarce, but it is generally considered to be due to localised thrombosis. We present a case of ischaemic RV which on postmortem examination was found to be due to retinal vascular occlusion by non-caseating granulomas, consistent with a diagnosis of sarcoidosis.

CASE REPORT

A 52-year-old woman was referred with a 7 month history of painless misty vision with floaters. She was well and had attended the local ophthalmic unit, where a diagnosis of retinal vasculitis was made. She had no symptoms suggestive of a systemic inflammatory disorder. She was a heavy smoker, and her father had died from a myocardial infarction aged 59 years.

On examination at her first attendance to the St Thomas's Medical Eye Unit, her visual acuities were 6/24, N12 in the right eye and 6/5, N4.5 in the left. Both anterior chambers were quiet, but there was low grade cellular infiltration in the vitreous bilaterally. Funduscopy revealed occasional peripheral intraretinal haemorrhages in the left eye, and in the right there was an oedematous macula, inferior intraretinal haemorrhages, and some sheathing of peripheral retinal vessels. Fluorescein angiography confirmed the presence of right cystoid macular oedema and bilateral peripheral retinal capillary closure (Fig 1).

On investigation, she had a lymphopenia, but erythrocyte sedimentation rate, serum ACE, and chest x ray were within normal limits. On this basis, a diagnosis of isolated idiopathic ischaemic RV was made. She was commenced on oral prednisolone, starting at a dosage of 40 mg/day, which was tailored according to the disease activity and was then stopped over the following months, when the RV was quiet. In view of her personal and family histories, an underlying thrombophilia

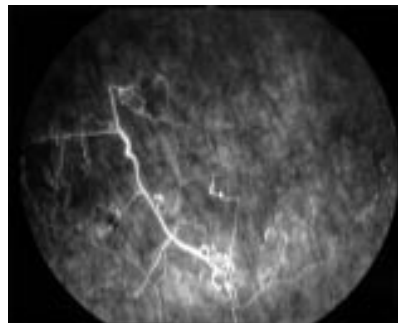


Figure 1 Fluorescein angiogram of the peripheral retina of the right eye showing capillary closure.

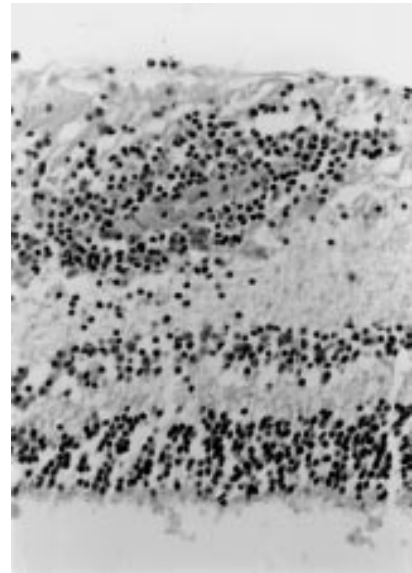


Figure 2 Postmortem histological section showing a non-caseating granuloma occluding a retinal blood vessel (haematoxylin and eosin, $\times 30$).

was investigated once she was off treatment: apart from a minimally raised fibrinogen level she had no haemostatic abnormalities. She had no further relapses of RV and never went on to have symptoms consistent with an underlying inflammatory disorder, so prednisolone treatment was never reinstigated. Eight months later she had a myocardial infarction and died.

Postmortem histological examination of the retina showed scattered non-caseating granulomas. There was evidence of these granulomas occluding the lumen of peripheral retinal vessels (Fig 2). There was no evidence of vasculitis or of granuloma formation in any major organs and the cause of death was confirmed as myocardial infarction secondary to arteriosclerosis.

COMMENT

Retinal vasculitis is a disorder characterised by inflammation of retinal blood vessels and cells in the vitreous. It can occur secondary to infection or neoplasia, or in association with an underlying systemic inflammatory disorder such as Behçet's disease or sarcoidosis, but is often idiopathic in origin.¹

The presence of non-caseating granulomas around retinal blood vessels is highly suggestive of localised ocular sarcoidosis, although the granuloma formation could have been due to chronic inflammation from other causes such as persistent infection. While granulomas are not pathognomonic of sarcoidosis, their presence points towards such a diagnosis and cases of sarcoidosis confined to the eye or brain have been reported.^{2,3} This patient had no symptoms suggestive of an underlying inflammatory condition, which ties in with the absence of vasculitis or granulomas in the major organs on post mortem. In retrospect, it would have been valuable to have performed further investigations, such as a Mantoux and bronchial lavage to prove or exclude sarcoidosis, but owing to the absence of systemic symptoms this diagnosis was not strongly suspected. However, the presence of a lymphopenia was, with hindsight, a useful clue and indicates that sarcoidosis should be considered in a patient presenting with RV at any age.

This patient had the ischaemic form of RV in the absence of a thrombophilia. While sarcoidosis is generally associated with non-ischaemic RV,⁴ cases with retinal vascular occlusion have been reported.⁵ These histology specimens show granuloma occluding the retinal vessels, rather than the presence of intravascular thrombosis, indicating that granuloma formation may be the direct cause of ischaemia in some patients. It is also of interest that the RV had clinically become quiescent, yet the presence of postmortem retinal granulomas indicates that intraocular inflammation persisted.

This case highlights the necessity to maintain a high index of suspicion of sarcoidosis, and confirms the need for further ocular histological specimens from RV patients to be examined whenever possible.

This work was supported by St Thomas's (Endowments) Committee and the Iris Fund for the Prevention of Blindness.

H E PALMER
M R STANFORD
A C E MCCARTNEY*
E M GRAHAM

Ocular Immunology Group, Rayne Institute,
St Thomas's Hospital, London SE1 7EH

Correspondence to: Dr Palmer.

Accepted for publication 25 June 1997

*Dr McCartney sadly died during the writing of this case report, following a long illness.

- Sanders MD. Retinal arteritis, retinal vasculitis and autoimmune retinal vasculitis. *Eye* 1987;1:441-65.
- Letocha CE, Shields JA, Goldberg RE. Retinal changes in sarcoidosis. *Can J Ophthalmol* 1975; 10:184-92.
- Cahill DW, Salzman M. Neurosarcoidosis: a review of the rarer manifestations. *Surg Neurol* 1981;15:204-11.
- Graham EM, Stanford MR, Sanders MD, Kasp E, Dumonde DC. A point prevalence study of 150 patients with idiopathic retinal vasculitis. 1 Diagnostic value of ophthalmological features. *Br J Ophthalmol* 1986;73:714-21.
- DeRosa AJ, Margo CE, Orlick ME. Hemorrhagic retinopathy as the presenting manifestation of sarcoidosis. *Retina* 1995;15:422-7.

Regression of conjunctival Kaposi's sarcoma under chemotherapy with bleomycin

EDITOR.—Kaposi's sarcoma (KS) is the most common neoplasm in patients with the acquired immunodeficiency syndrome (AIDS). In Europe, approximately 29% of patients with AIDS are affected; the tumour occurs much more frequently among HIV infected homosexual men compared with patients who contracted HIV through different routes of infection.^{1,2} Increasing evidence points to the role of the human herpesvirus 8 (HHV8) as a causative infectious agent for KS in immunosuppressed patients. It has not as yet been clarified, however, if HHV8 is required for the development of KS or if the virus preferentially infects and reduplicates within KS.²

Disseminated KS is currently treated with single or multiple agent chemotherapy, immunotherapy, and/or radiation therapy. For limited local disease cryotherapy, surgical excision, or local chemotherapy can be employed.³ We present a case of regression of conjunctival KS under systemic chemotherapy with bleomycin.

CASE REPORT

A 36-year-old homosexual, clinically asymptomatic male was proved to be HIV positive in June 1994. Within 16 months the patient rap-

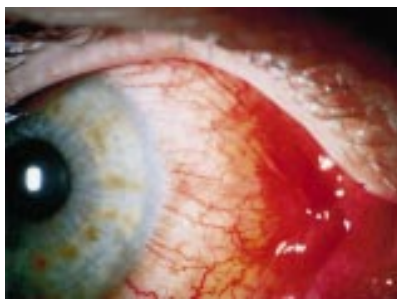


Figure 1 Appearance of Kaposi's sarcoma of the nasal bulbar conjunctiva before initiation of therapy.

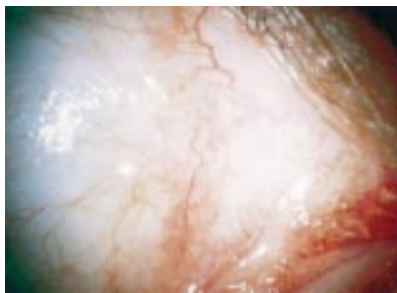


Figure 2 Regression of conjunctival Kaposi's sarcoma 8 months after initiation of treatment with bleomycin.

idly developed AIDS (CDC 3) showing severe psoriasis, oral candidiasis, and disseminated mucocutaneous KS. The development of clinical symptoms was paralleled by a drop in CD4+ cell counts from $800 \times 10^6/l$ to $28 \times 10^6/l$ during this period of time. Ocular examination showed a 8×4 mm, slightly elevated red-coloured lesion of the nasal bulbar conjunctiva of the right eye (see Fig 1), as well as two cutaneous lesions of the upper eyelid of the right eye and the lower eyelid of the left eye, respectively. Further ocular examination was unremarkable. As the patient was disturbed by constant irritation caused by the lesion as well as by its cosmetic appearance, a biopsy was performed which confirmed the diagnosis of conjunctival KS. Antiretroviral treatment was started with zidovudine plus zalcitabine in December 1995. Disseminated KS was treated with 5 mg/day bleomycin injections intramuscularly on 3 consecutive days every 2 weeks. This was initially combined with external beam radiation with ocular shielding for cutaneous lesions of the tip of the nose and the right cheek with a total dose of 12 Gy. No radiation was applied to the right eye. After 12 cycles of this regimen, complete tumour regression of cutaneous and ocular lesions (see Fig 2) occurred. During this period, CD4+ cell counts rose to $110 \times 10^6/l$. In December 1996, additional antiretroviral treatment with zidovudine and idinavir was started. No recurrence of KS was observed during the 17 month follow up until May 1997 with current CD4+ cell counts of $168 \times 10^6/l$.

COMMENT

With the increasing incidence of HIV infections, patients with ocular manifestations of AIDS are being seen more frequently. In patients with AIDS related KS, ocular involvement of the eyelids or the conjunctiva could be observed in 20% (20/100) of cases.⁴ Two cases of conjunctival KS as the initial clinical manifestation of AIDS have been reported.^{5,6} Conjunctival manifestations of HIV infections are

often neglected; they include KS, microvasculopathy, non-specific transient conjunctivitis, dry eye syndrome, and microspiral keratoconjunctivitis.^{4,6} KS of the conjunctiva appear as flat, reddish lesions, most often located in the lower fornix, which are easily mistaken for chronic subconjunctival haemorrhage, foreign body granuloma, or a cavernous haemangioma. Treatment of conjunctival KS is usually indicated for cosmetic reasons, if the lesion is complicated by haemorrhage or infection, or if it results in visual obstruction.⁴

Varying forms of treatment have been described; these include local excision with or without adjunct cryotherapy, fluorescein angiography based excision, external beam radiation, local immunotherapy, as well as single or multiple agent chemotherapy.^{4,8} The major complicating factor in local treatment of conjunctival KS is the relatively high rate of tumour recurrence in 29%–66% of cases.^{4,7}

Bleomycin as a single agent chemotherapy for mucocutaneous KS has been described by Caumes *et al.*⁹ With this therapy, a 74% (52/70) response rate could be achieved. The advantages of bleomycin over other chemotherapeutic agents include its good efficacy and the lack of haematotoxicity. The main side effects of bleomycin are adverse skin reactions (for example, flagellated pigmentations and Raynaud's phenomenon).⁹ Although two cases of conjunctival KS were included in the series of Caumes *et al.*, no details about their response to therapy are given.⁹

In this case, bleomycin therapy was accompanied by antiretroviral treatment; further, the regression of KS was paralleled by a rise in the CD4 cell count. A partial response of KS to antiretroviral therapy with zidovudine alone has been reported as well as a complete regression after treatment with indinavir, a new HIV-1 protease inhibitor.¹⁰ To what extent antiretroviral therapy might have contributed to the regression of KS in this case cannot be precisely differentiated from the effects of bleomycin above. However, we assume that bleomycin therapy was the major cause of regression of KS since, to our knowledge, complete regression of disseminated mucocutaneous KS with the antiretroviral treatment used in this case alone or in combination has not been reported to date despite the widespread use of antiretroviral agents in patients with AIDS and KS.

In conclusion, a complete and long standing remission of conjunctival KS could be achieved with intramuscular bleomycin therapy. This case is of particular interest in view of the rapid progression of symptoms and drop in CD4 cell count and the unusual involvement of the conjunctiva and both upper eyelids.

HEINRICH HEIMANN
KLAUS M KREUSEL
MICHAEL H FOERSTER
Department of Ophthalmology

RALF HUSAK
CONSTANTIN E ORFANOS
Department of Dermatology,
University Hospital Benjamin Franklin,
Free University of Berlin,
Berlin, Germany

Correspondence to: Dr H Heimann, Department of Ophthalmology, University Hospital Benjamin Franklin, Free University of Berlin, Hindenburgdamm 30, D-12200 Berlin, Germany.

Accepted for publication 4 June 1997

1 Hermans P, Lundgren J, Sommereijns B, Pedersen C, Vella S, Katlama C, *et al.* Epidemiology of AIDS-related Kaposi's sarcoma in Europe

- over 10 years. AIDS in Europe Study Group. *AIDS* 1996;10:911-7.
- Schulz TF, Boshoff CH, Weiss RA. HIV infection and neoplasia. *Lancet* 1996;348:587-91.
 - Northfelt DW. Treatment of Kaposi's sarcoma. Current guidelines and future perspectives. *Drugs* 1994;48:569-82.
 - Shuler JD, Holland GN, Miles SA, Miller BJ, Grossman I. Kaposi sarcoma of the conjunctiva and eyelids associated with the acquired immunodeficiency syndrome. *Arch Ophthalmol* 1989;107:858-62.
 - Hummer J, Gass JD, Huang AJ. Conjunctival Kaposi's sarcoma treated with interferon alpha-2a (letter). *Am J Ophthalmol* 1993;116:502-3.
 - Kurumety UR, Lustbader JM. Kaposi's sarcoma of the bulbar conjunctiva as an initial clinical manifestation of acquired immunodeficiency syndrome (letter). *Arch Ophthalmol* 1995;113:978.
 - Ghabrial R, Quivey JM, Dunn JP Jr, Char DH. Radiation therapy of acquired immunodeficiency syndrome-related Kaposi's sarcoma of the eyelids and conjunctiva. *Arch Ophthalmol* 1992;110:1423-6.
 - Dugel PU, Gill PS, Frangieh GT, Rao NA. Treatment of ocular adnexal Kaposi's sarcoma in acquired immune deficiency syndrome. *Ophthalmology* 1992;99:1127-32.
 - Caumes E, Guermonprez G, Katlama C, Gentilini M. AIDS-associated mucocutaneous Kaposi's sarcoma treated with bleomycin. *AIDS* 1992;6:1483-7.
 - Murphy M, Armstrong D, Sepkowitz KA, Ahkami RN, Myskowski PI. Regression of AIDS-related Kaposi's sarcoma following treatment with an HIV-1 protease inhibitor (letter). *AIDS* 1997;11:261-2.

Lacrimal gland epithelioid haemangioma

EDITOR.—Epithelioid haemangioma (EH) is the preferred name used to describe a rare primary, neoplastic disorder of vascular endothelium with a variable and secondary inflammatory response.¹ It is part of a spectrum of epithelioid vascular tumours and has been reported under a number terms, in particular angiolymphoid hyperplasia with eosinophilia. The term Kimura's disease has been used interchangeably with these terms but this should now be considered a separate disorder.^{2,3} We report a case in which EH involved the lacrimal gland in isolation, without systemic eosinophilia or other features of Kimura's disease.

CASE REPORT

A 77-year-old white woman with no previous medical history presented with a 1 year history of fullness in the right orbit and gradual right ptosis. She had developed epiphora 6 months before presentation and reported a non-specific visual disturbance in the same eye.

On examination corrected visual acuity was 6/9 right and 6/6 left. There was a 3 mm right non-axial proptosis with 2 mm of globe depression but no diplopia. A firm, non-tender mass was palpable in the lateral aspect of the right upper lid with a 1 mm ptosis. Ocular examination was otherwise normal.

A computed tomography scan of the orbit (Fig 1) showed a well defined homogeneous mass enlarging the right lacrimal gland, with no evidence of bone erosion or deformity of the adjacent globe. The left lacrimal gland was normal. The appearance was of a benign lacrimal tumour, most likely a pleomorphic adenoma. Routine haematological investigation was normal, with a white cell count of $5.2 \times 10^9/l$ and 1.9% eosinophils.

A right lateral orbitotomy was performed to improve surgical access and the lacrimal gland was excised with a margin of normal tissue.

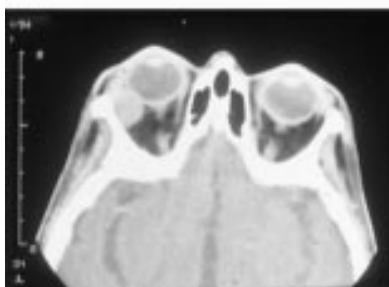
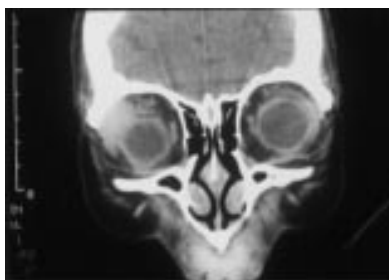


Figure 1 (Top) Sagittal computerised tomography scan showing diffuse right lacrimal gland enlargement and globe depression without bone or globe involvement. (Bottom) Axial computerised tomography scan showing diffuse right lacrimal gland enlargement and proptosis without bone or globe abnormality.

The proptosis resolved postoperatively; however, a 2 mm ptosis remained and she experienced diplopia on extreme right gaze because of right lateral rectus underaction.

Histological examination of the 25 mm mass showed a well circumscribed lesion with the typical features of EH (Fig 2A and B). Multiple thick walled vascular channels with plump endothelial cells were associated with an infiltrate of inflammatory cells, particularly eosinophils and plasma cells. The endothelial cells did not show cytological atypia, and mitoses were not evident. Lymphoid follicles were present in the periphery of the lesion.

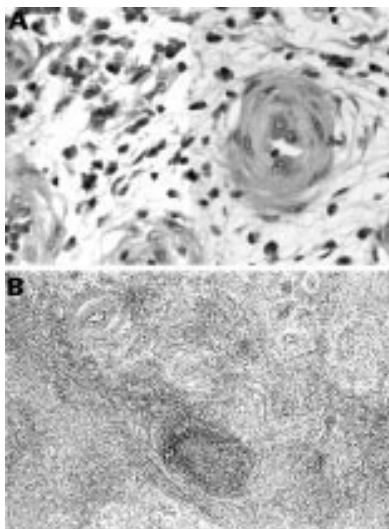


Figure 2 (A) Thick walled blood vessels are seen against a myxoid stroma which contains abundant plasma cells. Haematoxylin and eosin; $\times 40$. (B) Plump endothelial cells are evident in the blood vessels; plasma cells and a few eosinophils surround the vessels. Haematoxylin and eosin; $\times 165$.

COMMENT

Epithelioid haemangioma reported under the term angiolymphoid hyperplasia with eosinophilia (ALHE) is an exceptional entity in the orbit,² and usually involves the skin of the head and neck.⁴ The differential diagnosis includes angiosarcoma, eosinophilic granuloma, and granuloma faciale.^{2,5} Because of its benign nature its management is by local excision alone.² Recurrences have been treated with radiotherapy.²

Epithelioid haemangioma shows some histological features with Kimura's disease. Both have an inflammatory infiltrate of eosinophils, lymphocytes, and plasma cells, often in association with lymphoid follicles. However, the plump epithelioid cells that characterise EH are not found in Kimura's disease which also tends to show more fibrosis and to contain eosinophil microabscesses. Kimura's disease usually affects young Asian males, is associated with eosinophilia, and shows features of an autoimmune disorder. EH and Kimura's disease should therefore be considered separate clinicopathological entities.^{2,3}

Epithelioid haemangioma, under the term ALHE, has been previously reported in the lacrimal gland.^{6,7} However, these two cases were of young patients who had features of Kimura's disease and their initial presentation was with non-orbital involvement and later lacrimal gland enlargement. Both patients, one of Asian descent and the other Afro-Caribbean, had raised serum eosinophil counts. Our reported case of EH involves the lacrimal gland in isolation and affects an elderly white female without systemic eosinophilia or other characteristics of Kimura's disease.

A G A COOMBES

R M MANNERS

Southampton Eye Unit,
Southampton University Hospitals NHS Trust

D W ELLISON

Department of Pathology,
Southampton University Hospitals NHS Trust

B T EVANS

Department of Maxillofacial Surgery,
Southampton University Hospitals NHS Trust

Correspondence to: Mr A G A Coombes, Croydon Eye Unit, Mayday University Hospital, Mayday Road, Croydon, Surrey CR7 7YE.

Accepted for publication 10 June 1997

- Tsang WYW, Chan JKC. The family of epithelioid vascular tumours. *Histol Histopathol* 1993;8:87-212.
- Olsen TG, Helwig EB. Angiolymphoid hyperplasia with eosinophilia. A clinicopathologic study of 116 patients. *J Am Acad Dermatol* 1985;12:781-96.
- Urabe A, Tsneyoshi M, Enjoji M. Epithelioid haemangioma versus Kimura's disease: a comparative clinicopathologic study. *Am J Surg Pathol* 1987;11:758-66.
- Wells GC, Whimster IW. Subcutaneous angiolymphoid hyperplasia with eosinophilia. *Br J Dermatol* 1969;81:1-14.
- Hidayat AA, Cameron JD, Font RL, Zimmerman LE. Angiolymphoid hyperplasia with eosinophilia (Kimura's disease) of the orbit and ocular adnexa. *Am J Ophthalmol* 1983;96:176-89.
- Eisenberg E, Lowlicht R. Angiolymphoid hyperplasia with eosinophils: a clinical-pathological conference. *J Oral Pathol* 1985;14:216-23.
- Cook HT, Stafford ND. Angiolymphoid hyperplasia with eosinophilia involving the lacrimal gland: case report. *Br J Ophthalmol* 1988;72:710-2.

CORRESPONDENCE

Myopia of prematurity

EDITOR,—Fielder and Quinn¹ have provided an interesting hypothesis and speculation on the origin of myopia in premature infants' eyes following treatment for ROP. However, they have overstated the strength of the evidence in their opening statement that '... clinical research has shown that the degree of myopia is significantly less following laser therapy when compared with cryotherapy for severe ROP'. The three references quoted contain evidence only from historical comparison groups, raising questions about the strength of the evidence for this conclusion.²⁻⁴

The reports describe the incidence⁴ or severity² of myopia in two studies which compared laser with cryo treated ROP. Patient allocation of these 66 infants to the two treatments was not random, with the earlier historical comparison groups receiving cryotherapy. The third report³ describes 13 laser treated infants with no comparison group. Infants who lost vision were largely unreported. (In our own literature search a fourth report⁵ describes myopia outcomes in 17 infants treated with cryotherapy and 26 infants treated with laser therapy, but these are probably included among the infants reported by Algawi *et al.*⁴ An additional full report of reduced myopia following laser compared with cryotherapy was identified and the English abstract suggests a historically controlled comparison (Italian not yet translated),⁶ while a final abstract reports less myopia following laser in 14 infants compared with 20 non-randomly assigned cryotherapy infants⁷.)

Two methodological issues therefore raise a significant potential for biased conclusions: historical controls and non-reporting of treatment failures.

CONTROLS

The criteria for choosing infants for treatment in clinical practice are constantly under evolution as experience and judgment leads to potentially better choices of the time for treatment. Thus, the earlier treated (cryo) infants are more likely to have had more severe disease and a poorer overall prognosis and more sequelae than the later treated infants (laser). The effect of this type of bias would be that infants receiving laser treatment (compared with cryo treatment) would have less severe ROP at the time of treatment, a better prognosis because more of these would have regressed even without cryotherapy, and therefore they would be expected to have less myopia, even if there were no true myopia effect of cryo *v* laser treatment.

TREATMENT FAILURES

The number of infants who progressed to retinal detachments following either treatment is critical to evaluate because only infants with attached retinas can be assessed for myopia. If cryotherapy 'rescued' eyes that would have detached but leaves them myopic, that would still be a better outcome than if laser therapy failed to salvage those eyes but no myopia was found in the fewer eyes that did remain attached. It might be clearer to think of an

analysis of the proportion of the originally treated eyes that were not myopic or detached at follow up. Of course, this type of bias is unlikely to be a problem in this case, since randomised controlled trials of cryo *v* laser therapy have shown laser therapy to be at least as effective as cryotherapy in preventing unfavourable retinal outcomes.⁸⁻¹⁰

We agree with Fielder and Quinn that these are important observations, but they are not yet strong conclusions. We can hope that laser will reduce the sequelae of severe ROP even more than does cryotherapy, but a thorough search of the existing literature reveals only 90 infants entered in randomised, concurrent comparison trials of cryotherapy *v* laser ablation, and none of these has reported myopia outcomes to date.⁸⁻¹⁰ Given the consistency of observations from the non-randomised studies which used either historical controls^{2,4,7} or no controls,³ it may well be that there is a true reduction in the rate of myopia following laser. However, the validity of this conclusion and the accurate estimation of the magnitude of such an effect depend on data from randomised controlled trials. The investigators who conducted those controlled trials should seek out and publish myopia outcomes from those children to permit a best estimate of potential true differences. If the hypothesised differences in myopia rates are true, there are important questions for basic science laboratories to answer, and clear clinical practice implications.

D L PHELPS

University of Rochester, 601 Elmwood Avenue,
Rochester, NY 14642, USA

- 1 Fielder AR, Quinn QE. Myopia of prematurity: nature, nurture, or disease? (Editorial) *Br J Ophthalmol* 1997;81:2-3.
- 2 Laws F, Laws D, Clark D. Cryotherapy and laser treatment for acute retinopathy of prematurity: refractive outcomes, a longitudinal study. *Br J Ophthalmol* 1997;81:12-5.
- 3 Ling, CS, Fleck, BW, Wright, E, Anderson, C, Laing, I. Diode laser treatment for retinopathy of prematurity: structural and functional outcome. *Br J Ophthalmol* 1995;79:637-41.
- 4 Algawi K, Goggin M, O'Keefe M. Refractive outcome following diode laser versus cryotherapy for eyes with retinopathy of prematurity. *Br J Ophthalmol* 1994;78:612-4.
- 5 Knight-Nanan DM, O'Keefe M. Refractive outcome in eyes with retinopathy of prematurity treated with cryotherapy or diode laser—3 year follow up. *Br J Ophthalmol* 1996;80:998-1001.
- 6 Scuderi A, Di PM, Marino A, Reibaldi A. Myopia and ROP. (Italian) *Annali di Ottalmologia e Clinica Oculistica* 1995;121:601-7.
- 7 Jandek C, Kellner U, Foerster MH. Retinopathy of prematurity (ROP) less myopia following laser treatment. *Invest Ophthalmol Vis Sci* 1996;37:600 (abstract).
- 8 Laser ROP Study Group. Laser therapy for retinopathy of prematurity. *Arch Ophthalmol* 1994;112:154-6.
- 9 Hunter DG, Repka MX. Diode laser photocoagulation for threshold retinopathy of prematurity. A randomised study. *Ophthalmology* 1993;100:238-44.
- 10 Iverson DA, Trese MT, Orgel IK, Williams GA. Laser photocoagulation for threshold retinopathy of prematurity. *Arch Ophthalmol* 1991;109:1342-3.

Reply

EDITOR,—Upon review of our recently published editorial 'Myopia of prematurity: nature, nurture, or disease?' based on an article by Laws *et al.*,¹ comparing refractive outcomes in eyes that received laser *v* cryotherapy for severe retinopathy of prematurity (ROP), we are concerned that we may have conveyed two false impressions:

(1) The data presented by Laws *et al* do not necessarily 'confirm' in a scientific sense the finding that lasered eyes had less myopia than

eyes that underwent cryotherapy for severe ROP. Rather the study by Laws *et al* and the other two studies they cited were unrandomised, uncontrolled studies and they all contributed to the suggestion that lasered eyes may be less likely to have severe degrees of myopia than those which are treated by cryotherapy.

(2) Laws *et al* found that the 'cryoed' eyes were highly myopic without citing data on the natural course of untreated eyes which regress after developing severe retinopathy. As we indicated in our editorial, the distribution in cryo treated and control eyes in the CRYO-ROP study was virtually the same for eyes with myopia up to 6 dioptres and hyperopic eyes.^{2,3} This suggests that the abnormal refractions are probably due to the disease of ROP and not the surgical intervention of cryotherapy. Finally, we would reiterate the point that there is 'vital work to do not only with regard to refractive development', but also to improve our care of the eyes of these preterm infants.

ALISTAIR R FIELDER

Imperial College School of Medicine at St Mary's
Academic Unit of Ophthalmology,
Western Eye Hospital,
London NW1 5YE

GRAHAM E QUINN

Division of Pediatric Ophthalmology,
The Children's Hospital of Philadelphia,
University of Pennsylvania,
Philadelphia, PA, USA

- 1 Laws F, Laws D, Clark D. Cryotherapy and laser treatment for acute retinopathy of prematurity: refractive outcomes, a longitudinal study. *Br J Ophthalmol* 1997;81:12-5.
- 2 Cryotherapy for retinopathy of prematurity Cooperative Group. Multicenter Trial of Cryotherapy for Retinopathy of Prematurity: one year outcome—structure and function. *Arch Ophthalmol* 1990;108:1408-16.
- 3 Cryotherapy for retinopathy of prematurity Cooperative Group. Multicenter Trial of Cryotherapy for Retinopathy of Prematurity: 3½ year outcome—structure and function. *Arch Ophthalmol* 1993;111:339-44.

BOOK REVIEWS

Uveitis Vol 1. Differential Diagnosis. By Manfred Zierhut. Pp 190. £32.50. Buren, Netherlands: Aeolus Press, 1995. ISBN 0-7506-9589-7.

Vol 2. Therapy. By Manfred Zierhut. Pp 176. £32.50. Buren, Netherlands: Aeolus Press, 1996. ISBN 0-7506-9815-2.

Uveitis is undoubtedly a difficult field for many ophthalmologists since there are a bewildering number of clinical entities for both anterior and posterior uveitis.

Manfried Zierhut has produced a concise text which takes the form of two small handbooks which can easily slip into the pocket of the doctor's white coat. The aims of the text are to simplify the ophthalmologist's approach to uveitis. In the first section of volume 1 a general overview of the clinical signs and symptoms that one might observe in uveitis is outlined. This is then followed by a fairly extensive list of the various forms of uveitis classified into infective and non-infective uveitis, autoimmune uveitis, endogenous uveitis, and uveitis associated with systemic disease.

While there may be some disagreement concerning the precise classification of individual entities this handbook provides a very useful overview of a wide range of causes and presentations of uveitis and its aim of simplification of this complex field has been achieved.

Volume 2 follows the same overall plan. In the first two sections a general strategy for uveitis therapy is outlined with particular attention paid to the need to intervene, highlighted in section I.2. A novel view of the available anti-inflammatory, antibiotic, and immunosuppressive drugs is followed by a section outlining the various surgical procedures which are required for specific uveitis complications. There are some idiosyncratic inclusions here such as the inclusion of plasmapheresis in the surgical section and reference to other unusual therapies such as climatotherapy which is surely only used in very selected clinics.

The remainder of the book is an outline of the therapy for each of the conditions described in volume 1. Much reliance is placed on simple bullet point presentation with no frills and it is easy to find exactly what one is looking for. While specific therapies of discrete entities described in volume 2 represent Dr Zierhut's management of his own patients most of the approaches fall within the mainstream of generally accepted therapeutic ideas.

These two volumes will be very useful to both the practising and the trainee ophthalmologist in this field.

JOHN V FORRESTER

Colour atlas and text of ocular plastic surgery. By Jacques C van der Meulen, Joseph S Gruss. Pp 311. £120. London: Mosby-Wolfe, 1996. ISBN 07234 19248.

The title for this work might mislead one into thinking that it is 'just another book' describing oculoplastic reconstruction, although nothing could be further from the truth. Written largely by craniofacial surgeons, this magnificent book is a treasure trove of ideas and illustrations.

Many of the procedures described and vividly illustrated would not be performed by ophthalmic plastic surgeons, but the principles of the described techniques can be applied to other areas of oculoplastic surgery. Just as it is possible to learn from observing an experienced surgeon operating, this book—with its largely non-ophthalmic view of periocular reconstruction—provides a wealth of new ideas and will broaden the horizons of the ophthalmic plastic surgeon.

The anatomy of the orbit is presented very much from the developmental viewpoint and this is followed by coverage of three dimensional computed tomography scanning of the orbit. The chapter on three dimensional computed tomography imaging is of limited applicability to ophthalmic surgeons being, in reality, a series of fascinating cases with congenital anomaly, acquired disease, or trauma to the facial structures. The chapter entitled 'Orbital surgery' covers the principles of both reconstructive flaps and osteotomies very well, but does not give detail of intraorbital surgical techniques. Three chapters cover the treatment of anophthalmia, microphthalmia, and cranio-orbital maldevelopments in detail.

The sections covering blepharoptosis, facial nerve palsy, palpebral anomalies, and malpositions are well illustrated and of particular relevance to an oculoplastic surgeon, as are the

sections on the diagnosis and surgical treatment of eyelid tumours and socket surgery. For such a common problem, the coverage of age related lid malpositions is, however, rather limited. Although reconstruction of the lacrimal drainage system appears to be an afterthought in this book, basic lacrimal surgery is covered very well in the last chapter.

The management of orbital tumours, vascular anomalies and neurofibromatosis, and trauma (both primary and secondary repair) is very much the province of a craniofacial surgeon and not the type of case typically managed by an orbital or ophthalmic plastic surgeon; likewise, the extensive facial reconstructions described—after excision of major facial tumours, with trauma or after burns—are largely the province of the facial plastic surgeon.

The quality of presentation, printing, and binding is excellent and the number of errors is relatively few. There is no doubt that this book is a delight to read and to repeatedly browse. It is a must for a medical library and for the craniofacial surgeon, but perhaps not essential to the personal library of an ophthalmic plastic surgeon.

GEOFFREY E ROSE

Dictionary of Eye Terminology. 3rd ed. By B Cassin, S A B Solomon. Pp 238. \$US 24.95. Gainesville, Florida: Triad Publishing Company, 1997.

In this third edition the authors have gone beyond the realms of a mere definitional text. This edition includes clear definitions ranging from the simple jargon one would expect to find in such a work to complicated rare syndromes, even daring to give the occasional differential diagnosis. This book goes further than previous editions to include many more drugs, and systemic disease with ocular manifestations.

Its user friendly layout allows those with a modicum of ophthalmological knowledge to access most terms used within the eye world even when incorrectly spelt. It defines simply so a scientific background is not a prerequisite. It is inevitable that with this being a 'American' publication care has to be taken when applied in a UK context. For example, the legal definition of blindness has to be disregarded. Perhaps expansion of the contact lens terminology may have been appropriate. However, almost every other relevant area has been well covered.

It remains a compact, well produced, spiral bound dictionary which should be found in the pockets of those who endeavour to tackle the full spectrum of ophthalmology. A useful reference for all those involved in eyes and related professions.

KARON A ROBINSON

Practical paediatric ophthalmology. By D Taylor, C Hoyt. Pp 248. £34.50. Oxford: Blackwell Science, 1997. ISBN 086542 7208.

Practical Paediatric Ophthalmology is a beautifully illustrated volume from the same 'stable' as *Paediatric Ophthalmology*, which has become the classic text for this subspecialty. With 27 chapters it offers a comprehensive review of most aspects of children's eye disorders. The exception is strabismus which is mentioned only briefly in the context of screening, refractive errors, and as part of the

presentation of various other ophthalmic disorders.

The illustrations are of exceptional quality, reproducing many of those available in the 'big book'. These high quality illustrations and succinct summaries of the various disorders have already made it a firm favourite in our department, with both trainee ophthalmologists and paediatricians finding it a valuable reference guide.

However, there are some reservations. Though readers are exhorted to use the sister text *Practical Strabismus Management*, the cost and size of the combined texts takes them beyond the 'handy quick reference' category. Also the devotion of 59 pages to aspects of neuro-ophthalmology very much reflects the authors' interests and practice rather than the paediatric ophthalmology that most readers with a subspecialty interest will encounter. Fourteen pages on nystagmus but only one devoted to the difficult question of glaucoma management serves to emphasise this bias.

Furthermore, the text while clearly written and informative is written in a discursive style and is meant to be read through, cover to cover, rather than dipped into for easy reference in a clinic setting. I therefore found myself wondering why a junior would not, instead, use the 'big book' to learn about the diagnosis and management of difficult problems.

It is of course no criticism of a book that a reviewer cannot easily identify its intended audience, and I suspect that it will be enormously popular and thus answer those particular misgivings. The authors have produced a fine text and, only because the other large text with which they are involved is so exceptional, do I feel the need to offer any criticism.

H E WILLSHAW

NOTICES

Retinopathy of Prematurity

The latest issue of the *Journal of Community Eye Health* (no 22) deals with retinopathy of prematurity. Editorial by Alistair R Fielder. For further information please contact Ann Naughton, ICEH, Institute of Ophthalmology, 11-43 Bath Street, London EC1V 9EL. Tel: 0171 608 6910. Annual subscription: £25. Free to eye health workers in developing countries.

International Centennial Meeting on Pseudoxanthoma Elasticum

PXE International, Inc, along with the National Institute of Arthritis, Musculoskeletal and Skin Diseases (NIH), is sponsoring an International Centennial Meeting on Pseudoxanthoma Elasticum (PXE) on 6-7 November 1997 in Bethesda, MD, USA. The meeting will focus on genetic, extracellular matrix, and clinical issues. Further details: Sharon Terry, MA, President PXE International, Inc, 23 Mountain Street, Sharon, MA 02067, USA. (Tel and fax: 617 784 3817; email: pxe@tiac.net)

2nd International PRK and Lasik Workshop

The 2nd International PRK and Lasik Workshop will be held on 27 November 1997 at the Mater Hospital, Dublin, Ireland. Further details: Ms M Hennerty, Laser Coordinator, Mater Private Hospital, Dublin, Ireland. (Tel: +353-1-8384444 ext 1732; fax +353-1-8386314.)

10th Annual Wilmer Institute's Current Concepts in Ophthalmology

The 10th Annual Wilmer Institute's Current Concepts in Ophthalmology will be held on 11–13 December 1997 at the Johns Hopkins Medical Institutions, Baltimore, Maryland. Further details: Program Coordinator, Johns Hopkins Medical Institutions, Office of Continuing Medical Education, Turner 20/720 Rutland Avenue, Baltimore, MD 21205, USA. (Tel: 410 955-2959; fax: 410 955-0807; email: cmenet@som.adm.jhu.edu; homepage:<http://ww2.med.jhu.edu.cme>)

20th Annual Wilmer Institute's Current Concepts in Ophthalmology

The 20th Annual Wilmer Institute's Current Concepts in Ophthalmology will be held on 5–10 February 1998 at the Hyatt Regency Cerromar Beach Hotel, Dorado, Puerto Rico. Further details: Program Coordinator, Johns Hopkins Medical Institutions, Office of Continuing Medical Education, Turner 20/720 Rutland Avenue, Baltimore, MD 21205, USA. (Tel: 410 955-2959; fax: 410 955-0807; email: cmenet@som.adm.jhu.edu; homepage:<http://ww2.med.jhu.edu.cme>)

2nd International Glaucoma Symposium (IGS)

The 2nd International Glaucoma Symposium will be held on 15–20 March 1998 in Jerusalem, Israel. Further details: The

2nd IGS Secretariat, PO Box 50006, Tel Aviv 61500, Israel. (Tel: +972-3-514-0000; fax: +972-3-517-5674; email: glaucoma@kenes.com)

15th Annual Wilmer Institute's Current Concepts in Ophthalmology

The 15th Annual Wilmer Institute's Current Concepts in Ophthalmology will be held on 15–20 March 1998 at Manor Vail Lodge, Vail, Colorado. Further details: Program Coordinator, Johns Hopkins Medical Institutions, Office of Continuing Medical Education, Turner 20/720 Rutland Avenue, Baltimore, MD 21205, USA. (Tel: 410 955-2959; fax: 410 955-0807; email: cmenet@som.adm.jhu.edu; homepage:<http://ww2.med.jhu.edu.cme>)

11th Annual Meeting of German Ophthalmic Surgeons

The 11th Annual Meeting of German Ophthalmic Surgeons will be held on 28–31 May 1998 in Nürnberg, Germany, Meistersingerhalle. Further details: organisation Nürnberg GmbH, Wielandstrasse 6, D-90419 Nürnberg, Germany. (Tel: +49-911-393160; fax: +49-911-331204.)

XXVIIIth International Congress of Ophthalmology

The XXVIIIth International Congress of Ophthalmology will be held in Amsterdam on 21–26 June 1998. Further details: Eurocongres Conference Management, Jan van Goyenkade 11, 1075 HP Amsterdam, the Netherlands. (Tel: +31-20-6793411; fax: +31-20-6737306; internet <http://www.solution.nl/ico-98/>)

First Combined International Symposium on Ocular Immunology and Inflammation

The First Combined International Symposium on Ocular Immunology and Inflammation will be held in Amsterdam on 27 June–1 July 1998. The meeting is sponsored by the International Ocular Immunology and Inflammation Society, the International Uveitis Study Group, and the Immunology and Immunopathology of the Eye Organisation. Further details: Professor Aize Kijlstra, The Netherlands Ophthalmic Research Institute, PO Box 12141, 1100 AC Amsterdam, Netherlands (email: a.kijlstra@amc.uva.nl)

2nd International Conference on Ocular Infections

The 2nd International Conference on Ocular Infections will be held on 22–26 August 1998 in Munich, Germany. Further details: Professor J Frucht-Pery, 2nd International Conference on Ocular Infections, PO Box 50006, Tel Aviv, 61500, Israel. (Tel: 972 3 5140000; fax: 972 3 5175674 or 5140077; email: ocular@kenes.com)

First International Conference on the Optic Nerve

The First International Conference on the Optic Nerve to be held in Tel Aviv, Israel on 30 August–4 September 1998 has been cancelled due to lack of financial support.

ICOP 98

The next International Conference in Ophthalmic Photography (ICOP) will be held on 19–21 September 1998. Further details: Mrs Gillian Bennerson, Senior Ophthalmic Photographer, Bristol Eye Hospital, Lower Maudlin Street, Bristol BS1 2LX. (Tel: 0117-928-4677.)

INSTRUCTIONS FOR AUTHORS

Adherence to the following guidelines is essential if efficient and expeditious processing of your manuscript is to be achieved. Manuscripts will be returned to authors for revision before peer review if they are submitted in incorrect format. Please indicate in a covering letter which category of paper your article represents.

The *British Journal of Ophthalmology* is an international journal covering all aspects of clinical ophthalmology and the visual/ophthalmic sciences. Contributors should consider the widely varying readership and write clear, simple articles with the minimum of technical detail. Space in the journal is limited and articles should therefore be as concise as possible. One page of text is approximately 1000 words.

Manuscripts should be sent to the editor who selects them on the basis of their suitability for the journal and of reports from independent referees. Manuscripts are acknowledged on receipt and the majority (>80%) are sent for review. Those that are not reviewed are returned to the author as rapidly as possible so that they may be submitted elsewhere.

Manuscripts may be processed by section editors who deal with specific areas of ophthalmology including surgical retina, medical retina, neuro-ophthalmology, glaucoma, paediatric ophthalmology, ocular motility, orbital disease, anterior segment disease, oncology, lens, optics and visual sciences, laboratory sciences, pathology, and immunology. A minimum of two referees, chosen for their specific expertise, review each article.

Papers are accepted on the understanding that they have not been and will not be published elsewhere, and that there are no ethical problems with the work described. If requested, authors shall produce the data upon which the manuscript is based for examination by the editor.

Categories of papers

ORIGINAL ARTICLES

(a) Clinical science

Articles on clinical topics are research reports of a general or specialised nature comprising approximately 3000 words and 4-6 display items (Figures and Tables).

(b) Laboratory science

Articles on ophthalmic or visual sciences are research reports of experimental work generally of the same size as clinical research reports. Laboratory science papers will be included in a designated section of the journal.

Both types of original article should include the following: title; key words (up to four); address and which author address for correspondence; structured abstract (approx 200 words, headings 'Aims/background', 'Methods', 'Results', and 'Conclusion'); introduction; materials and methods; results and discussion sections; references and acknowledgements; legends for display items (Figures and Tables).

REVIEW ARTICLES

Substantive review articles will be included under the section 'Perspective' and will address any aspect of clinical or laboratory

ophthalmology. Review articles will be approximately 3000-5000 words in length including references and may contain display items (Figures and Tables). Most review articles are commissioned but uninvited reviews are welcomed. Prior discussion with the Editor is recommended. All reviews are subject to independent refereeing.

LETTERS TO THE EDITOR

Case reports will be published as 'Letters to the editor'. These are normally 500-600 words written in the form of a letter with a maximum of two display items (Figures and Tables). The letter should include an introductory section (without heading), the case report (heading: Case report) and a comment (heading: Comment), plus a maximum of 10 references.

CORRESPONDENCE

Letters are normally constructed in the form of scientific correspondence and are usually 200-300 words.

Preparation of manuscripts

Manuscripts will be received on the understanding that they have not been and will not be published elsewhere while under editorial review. Manuscripts may be subject to editorial revision with the author's agreement. All communications should be sent to the Editor, *British Journal of Ophthalmology*, Department of Ophthalmology, University of Aberdeen Medical School, Foresterhill, Aberdeen AB9 2ZD, Scotland, UK. (Tel: 01224 663812; Fax: 01224 663832.)

Manuscripts must be submitted in triplicate, and typed double spaced on one side of the paper only, with one inch margins. Each author must sign the covering letter as evidence of consent to publication. Revised manuscripts should be submitted as hard copy and on disk. Detailed instructions will be sent to authors on invitation to revise.

ILLUSTRATIONS

Illustrations must be submitted in triplicate. Transparencies must be accompanied by prints. Only salient detail should be included. All must be labelled with the author's name, numbered in the same order as they are cited in the text irrespective of whether they are in colour or black and white, and have the top indicated. Radiographs must be submitted as prints. Line drawings should be clearly labelled and will be redrawn to house style. The width of illustrations for the original articles should be 68 mm, 104 mm, 140 mm or, in exceptional circumstances, 176 mm, to fit the column layout of the journal. Illustrations for 'Letters to the editor' should be 56 mm or 116 mm. Stain used and a scale bar (or magnification) should be given. Legends must be typed on a separate sheet.

TABLES

Each table should be on a separate sheet, have a heading, and contain no vertical rules.

REFERENCES

In accordance with the Vancouver agreement references are cited by the numerical system. They must be typed double spaced.

References in the text must be cited in numerical order of first appearance. References in the list must be given in the numerical order in which they first appear in the text, not in alphabetical order of authors' names. References with one to six authors must include all authors' names; for references with more than six authors the first six should be given and then *et al.* Titles of journals should be abbreviated in accordance with the *Index Medicus* or given in full.¹ References to books must include names of editor(s) if there is one, town where published, name of publisher, year, volume, page numbers.²

- 1 Kaye SB, Shimeld C, Grinfield E, Maitland NJ, Hill TJ, Easty DL. Non-traumatic acquisition of herpes simplex virus infection through the eye. *Br J Ophthalmol* 1992; 76: 412-8.
- 2 Jakobiec FA, Font RL. Orbit. In: Spencer WB, ed. *Ophthalmic pathology: an atlas and textbook*. 3rd ed. Philadelphia: Saunders, 1986: 2461-76.

References will not be checked in the editorial office. Responsibility for their accuracy and completeness lies with the author.

SI UNITS

The work should be reported in the units used. If these were not SI units, the equivalent in SI units should be given in parentheses.

STATISTICS

Particular attention should be paid to the description of any sample selection process; in particular, the representativeness of the sample should be argued and the handling of any missing data justified. Authors are asked to check tables etc to ensure that missing data are accounted for, that percentages add up to 100 and that numbers in tables are not at variance with those quoted in the text. The policy of the *British Journal of Ophthalmology* is based on the statistical guidelines published in the *British Medical Journal* in 1983 and these are a useful source of information for authors (Altman DG, Gore SM, Gardner MJ, Pocock SJ. Statistical guidelines for contributors to medical journals, *BMJ* 1983; 286: 1489-93). Blanket statements on the use of statistical techniques should be avoided; it must be made quite clear in context which procedure is being used. Authors should bear in mind that relatively simple analyses are often quite adequate to support the arguments presented.

Advice may be available to authors before submission of papers.

Proofs

Contributors will receive ONE proof, and should read it carefully for printers' errors. Alterations to the original text should be kept to a minimum and may be charged to the author. Responsibility for validation of the proof lies with the author.

Reprints

These may be ordered from the Offprint Office when proofs are returned.