

LETTERS TO THE EDITOR

Surgically removed submacular nematode

EDITOR.—Intraocular filariasis is an uncommon disease in civilised countries. In only a few cases has the worm been surgically removed from the posterior portion of the eye and identified.¹ In this report we describe a patient who had a filaria-like worm in an epimacular and/or submacular lesion, which was successfully removed surgically.

CASE REPORT

A 38 year old woman complained of decreased visual acuity in her left eye of 5 days' duration. Her medical history was unremarkable. The patient had two pet dogs, and she had not travelled to foreign countries in recent years. On examination, her corrected visual acuity was 20/20 in the right eye and 20/100 in the left. No inflammation was present in the anterior segment or vitreous cavity bilaterally. Ophthalmoscopic examination disclosed a white worm, approximately 3 disc diameters in length, equivalent to about 4.5 mm, moving slowly in the macula at the epiretina. Epiretinal and intraretinal haemorrhages were observed in and around the macular region. The body of the worm was tapered at one end and slightly rounded at the other (Fig 1). A round, preretinal haemorrhage was observed on a branch of the superonasal retinal artery, which could have been the route of entry into the eye.

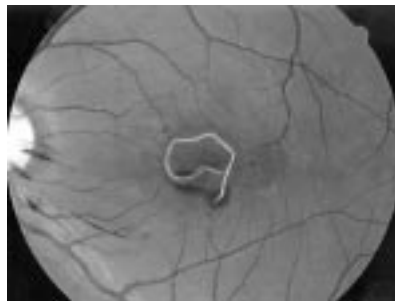

Figure 1 Fundus photograph of the left posterior pole demonstrates a white worm and preretinal haemorrhage.

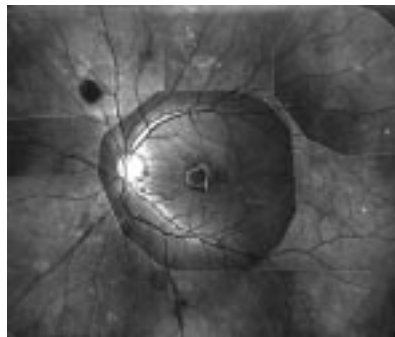


Figure 2 Fundus photograph of the left eye shows a white worm at the macula, a round, preretinal haemorrhage along the superonasal retinal artery, and numerous subretinal hypopigmented tracks in the superior retina.

Numerous subretinal hypopigmented tracks with small haemorrhages were noted in the superior retina, and perivascular haemorrhages were observed around the inferior branch of the central retinal vein (Fig 2). Fluorescein angiography showed numerous hyperfluorescent tracks without dye leakage. The patient's blood test revealed a slightly elevated white blood cell count ($10\,200 \times 10^9/l$; normal <9000) and elevated IgE in the serum (680 U/ml; normal <250).

On the following day pars plana vitrectomy was performed and the worm was found partially migrated into the subretinal space of the macula. The worm was aspirated successfully through a 20 gauge silicone tipped needle and submitted for parasitological study; however, it was lost during transportation to a different laboratory. Parasitological study of the patient's serum detected an antibody to *Dirofilaria*. Six months after surgery, the patient's visual acuity was still 20/50. Ophthalmoscopically the hypopigmented tracks had faded, and mildly irregular pigment was observed at the deep retina in the macular lesion. Cone and rod electroretinograms to full field stimuli were normal bilaterally.

COMMENT

Our patient owned two dogs, and her ocular findings could be differentiated from toxocarosis, in which only larvae of *Toxocara canis* can infect humans. The length of the *Toxocara* larva is about 400 μ m, and grows no longer. Although no direct microscopical evidence of *Dirofilaria* infection was obtained in our patient, a positive antibody to *Dirofilaria* in the serum indicated its infection. There have been many reports of intraocular filariasis; however, the filariae were removed and identified in only six of 56 cases reviewed by Beaver in 1989.¹ Direct parasitological microscopic examination is necessary for accurate diagnosis, but serological study can be helpful, as shown in the present case.

Various types of management for intraocular parasites have been reported. Direct photocoagulation to the worm body has been successfully reported in cases with filaria-like worms^{2,3} and in one case with insect parasites.⁴ It has been suggested that photocoagulation denatures the parasite proteins and mitigates the immune reaction.^{2,4} If the parasite is located in the posterior pole of the retina, however, photocoagulation may cause permanent visual impairment, and surgical removal should be selected. Furthermore, photocoagulation would make parasitological identification impossible. Preretinal or subretinal parasites were retrieved successfully by pars plana vitrectomy in several reported cases.^{5,6} In the present case, the visual acuity was still 20/50 6 months postoperatively. The migrating worm may have caused considerable damage to macular function, therefore, we believe that intraocular parasites should be removed as soon as possible.

The authors are grateful to Dr Keizo Yamaguchi for parasitological examination and Mr Shingo Yamazaki for fundus photographs.

SHUICHI YAMAMOTO
MASANORI HAYASHI
SHINOBU TAKEUCHI

Department of Ophthalmology,
Toho University Sakura Hospital, Sakura, Japan

Correspondence to: Shuichi Yamamoto, MD, Department of Ophthalmology, Toho University Sakura Hospital, 564-1 Shimoshizu, Sakura, Chiba 2858741, Japan.

Accepted for publication 19 July 1999

- 1 Beaver PC. Intraocular filariasis: a brief review. *Am J Trop Med Hyg* 1989;40:40-5.
- 2 Raymond LA, Gutierrez Y, Strong LE, et al. Living retinal nematode (filarial-like) destroyed with photocoagulation. *Ophthalmology* 1978;85:944-9.
- 3 Ittyerah TP. Nematode in the retina. *Indian J Ophthalmol* 1990;38:178-9.
- 4 Fitzgerald CR, Rubin ML. Intraocular parasite destroyed by photocoagulation. *Arch Ophthalmol* 1974;91:162-4.
- 5 Goodart RA, Riekhof FT, Beaver PC. Subretinal nematode: an unusual etiology for uveitis and retinal detachment. *Retina* 1985;5:87-90.
- 6 Funata M, Custis P, De la Cruz Z, et al. Intraocular gnathostomiasis. *Retina* 1993;13:240-4.

Acanthamoeba keratitis occurring with daily disposable contact lens wear

EDITOR.—Up to 92% of cases of acanthamoeba keratitis occur in contact lens users of all types.¹ Failure to disinfect soft contact lenses and the use of chlorine disinfection systems are major factors accounting for the increase in cases of acanthamoeba keratitis.² It is thought that "daily disposable" contact lenses, which require no disinfection, will have a much lower risk for the development of all forms of infectious keratitis. We report a case of acanthamoeba keratitis occurring in a daily disposable contact lens wearer. We believe this is the first such reported case.

CASE REPORT

A healthy 21 year old woman, who had been wearing daily disposable contact lenses for 1 year, wore her lenses for 4 hours on 1 day and then stored the lenses in preserved saline solution overnight in a new contact lens case. She rewore the lenses for a further 3 hours the following day. She reports that this was the first time that she had done this. She then developed a painful left eye. This was initially treated as conjunctivitis by her general practitioner and local accident and emergency department. After 2 weeks her local eye unit suspected acanthamoeba keratitis and performed an epithelial scrape that "revealed amoeba species". She was then referred to our unit for our opinion.

On examination her visual acuity was reduced to 6/18 in the left eye. There was conjunctival injection and a mild scleritis. The

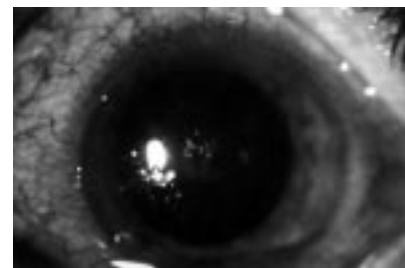


Figure 1 The cornea showing diffuse punctate staining with linear epithelial infiltrates.

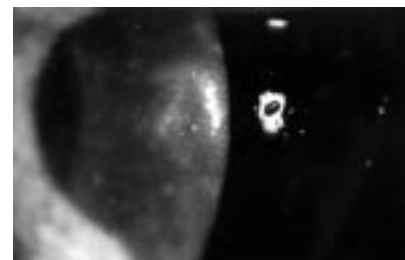

Figure 2 The cornea showing diffuse punctate staining with perineural infiltrates.

cornea had diffuse punctate staining with linear epithelial and perineural infiltrates (Figs 1 and 2). She had a mild anterior uveitis. Acanthamoeba was strongly suspected. Corneal epithelium was removed for microscopy, culture, and histology. Her contact lens case and solutions were also sent for culture. Acanthamoeba was cultured from both corneal epithelium and lens case, but not the lens solutions. She was treated with topical polyhexamethylene biguanide 0.02% (PHMB) and prednisolone 0.3% as well as oral flurbiprofen (Froben, Knoll Ltd, Nottingham). Six weeks after diagnosis she was asymptomatic with a visual acuity of 6/9. The eye was quiet, though some corneal infiltrates remained.

COMMENT

Acanthamoebae are free living protozoa commonly found in soil and water, including bathroom tap water.³ Acanthamoeba keratitis is an uncommon but potentially devastating corneal infection. The number of cases diagnosed in the United Kingdom has steadily risen over the past 20 years owing to increased awareness of the condition and the rise in contact lens wear.⁴

Radford *et al* found that daily wear disposable contact lenses were associated with greatly increased risk of acanthamoeba keratitis compared with other lens types and wear systems.^{1,2} Multivariable analysis showed that this was largely attributable to a lack of disinfection, the use of non-sterile saline, and the use of chlorine based disinfection rather than alternative chemical systems. It was concluded that 80% of cases of acanthamoeba keratitis could be prevented by the adequate use of an effective disinfection system. It was felt that the "low care" philosophy of daily wear disposable lenses had become "no care" in practice.

Daily disposable contact lenses, in which the lens is discarded after 1 day's wear only, were introduced in 1995. When used properly and discarded after a single day's wear, they do not carry the risks of inadequate lens disinfection, contaminated lens solutions, and storage cases. A case of acanthamoeba keratitis occurring in an extended wear disposable lens wearer has been reported, illustrating that even without the risks of inadequate lens disinfection and contaminated lens cases the infection can occur.⁵ However, it is known that contact lens wear increases the susceptibility to keratitis independent of factors relating to disinfection and cleaning.

Our case of acanthamoeba keratitis in a daily disposable lens wearer illustrates that misuse occurs and when it does so inadequate disinfection is almost inevitable leading to greatly increased risk of acanthamoeba infection. Misuse, as in this case, may often be associated with storage in saline or water without disinfection. This has been shown by Radford *et al* to increase the relative risk of acanthamoeba keratitis to 55.86 (10–302) $p < 0.001$. Our case does not, however, indicate the mechanism of infection. It is possible that the infection is unrelated to the lens misuse and could have been acquired from other unrelated sources, such as exposure to contaminated tap water while wearing lenses. However, we would recommend greater education of daily disposable lens wearers on the importance of strict adherence to wearing their lenses for 1 day only and of the risks of misuse of their lenses.

Correspondence to: Mr J K G Dart.
Accepted for publication 22 March 1999

- 1 Radford CF, Lehmann OJ, Dart JKG. Acanthamoeba keratitis: multicentre survey in England 1992–6. *Br J Ophthalmol* 1998;82:1387–92.
- 2 Radford CF, Bacon AS, Dart JKG, *et al*. Risk factors for acanthamoeba keratitis in contact lens users: a case control study. *BMJ* 1995;310:1567–70.
- 3 Seal D, Stapleton F, Dart JKG. Possible environmental sources of acanthamoeba spp in contact lens wearers. A case control study. *Br J Ophthalmol* 1992;76:424–7.
- 4 Bacon AS, Frazer DG, Dart JKG, *et al*. A review of 72 consecutive cases of acanthamoeba keratitis, 1984–1992. *Eye* 1993;7:719–25.
- 5 Ficker L, Hunter P, Seal D, *et al*. Acanthamoeba keratitis occurring with disposable contact lens wear. *Am J Ophthalmol* 1989;108:453.

Clinical course of acute zonal occult outer retinopathy in visual field and multifocal electroretinogram

EDITOR.—Patients with acute zonal occult outer retinopathy (AZOOR) may present with a normal fundus examination and almost normal fluorescein angiography (FA), despite severe loss of visual field and electroretinogram (ERG) abnormalities.^{1,2} The lesion defined zones of the retinal receptor cells; however, the cause of the disease remain unclear.³ There is also no established conclusion about progression of visual field loss.¹

With a multifocal ERG (m-ERG), a large number of retinal locations can be stimulated simultaneously and local responses can be extracted independently in a single recording session. High resolution topographic mapping of retinal function also is possible.⁴ A previous report indicates its efficiency in the diagnosis of AZOOR.⁵ There are no reports about the clinical course. Thus, using m-ERG and static perimetry (Humphrey 30-2), the alteration of retinal function in a clinical course of a patient with AZOOR was investigated.

CASE REPORT

A healthy 26 year old woman presented to our outpatient clinic complaining of acute onset of

visual disturbance in her left eye. Her corrected visual acuity was 20/20 in her right eye, and 20/100 in her left. The pupils were equal and reactive normally. Slit lamp and fundus examination, computed tomography, magnetic resonance imaging scan, and general examination were normal. HVF 30-2 demonstrated blind spot enlargement breaking out to the inferotemporal periphery in the left eye (Fig 1, top). Full field ERG showed grossly reduced A and B waves in the left eye. The FA showed slight leakage from peripapillary capillaries. Indocyanine green (ICG) angiography showed slight hypofluorescence of the macular area at a late phase.

Analysis of the mean deviation in HVF over the clinical course corresponded with the visual acuity (Fig 1, bottom). In addition, m-ERG (Veris III, Tomey, Nagoya, Japan) was analysed during the clinical course. In this examination, the fundus was divided into four foci and the sum of amplitudes in each group was measured (Fig 2, top). In the left eye, the sum of amplitudes was altered individually but all of them were affected during the clinical course. Only in the inferotemporal area did it correspond with HVF. The values in the right eye were about 5000 μV in each focus. This is almost the same as normal volunteers in our clinic (data not shown).

COMMENT

AZOOR may be precipitated by various retinal disorders and is characterised by rapid visual field loss which cannot be explained by the ophthalmoscopic changes resulting from the initiating disease. The ERG is abnormal, indicating that the field loss is due to retinal dysfunction.⁶ The cause of the acute damage to sharply defined zones of the retinal receptor cells in the absence of visible fundus changes in patients with AZOOR is unknown.⁷ In some previous reports, an apparent response to corticosteroid therapy suggested that an inflammatory and perhaps an immune reaction may play a part in the disease; however, there is no specific evidence for an immune abnormality.^{6,8} An infectious aetiology could also be the cause of AZOOR.⁸

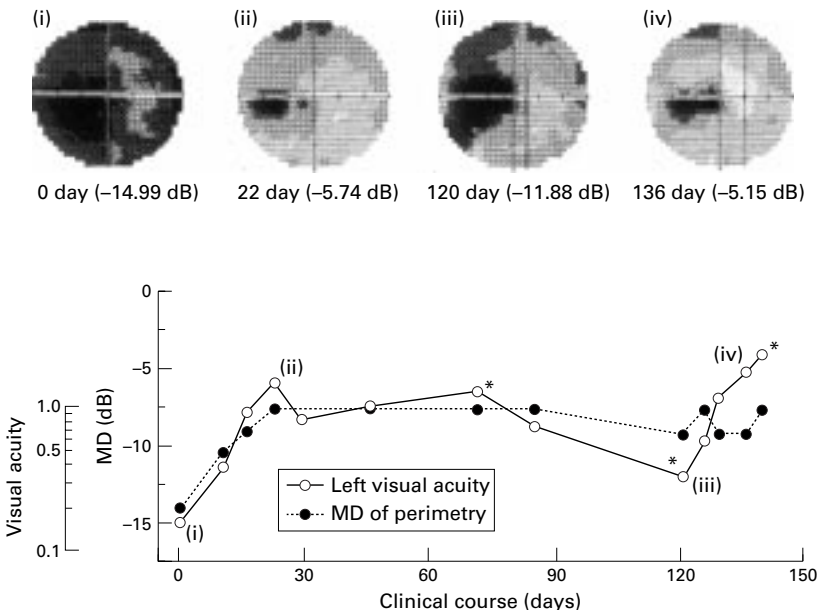


Figure 1 (Top) Raw images of Humphrey 30-2 visual fields in the left eye. (Bottom) The relation between clinical course and mean deviation (MD) of Humphrey 30-2 visual field and visual acuity in the left eye. Asterisks indicate the day in which multifocal ERG was analysed. The roman numerals correspond with raw images in the upper part of the figure.

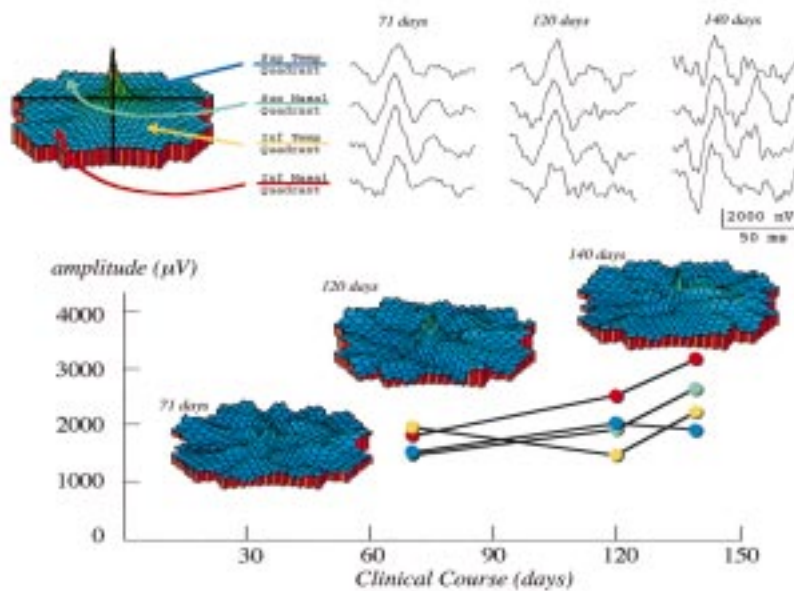


Figure 2 (Top left) In the multifocal ERG, the fundus was divided into four foci. (Top right) Sum of the amplitudes in each foci was altered during the clinical course. (Bottom) The three dimensional topography and sum of the amplitudes in each of four foci of the m-ERG were indicated.

The findings of AZOOR that we observed in our patient suggest that the retinal recovery assessed by m-ERG was different for the lesion (main focus was related to the inferotemporal retina) and was delayed compared with visual acuity and HVF. Perhaps this delayed retinal recovery reflects a subtle microcirculatory disturbance that can not be clearly detected by FA or ICG. Slight leakage in FA and slight hypofluorescence on the late phase in ICG would suggest such a microcirculation disorder.

When better understanding of the aetiology and pathophysiology of AZOOR is available, the clinical response to appropriate therapy may perhaps best be followed by m-ERG.

KANAKO YASUDA
MASAHIKO SHIMURA
MICHIRU NORO
MITSURU NAKAZAWA
MAKOTO TAMAI

Department of Ophthalmology, School of Medicine,
Tohoku University, Sendai 980-8574, Japan

Correspondence to: Masahiko Shimura, MD, Department of Ophthalmology, School of Medicine, Tohoku University, Sendai, 980-8574, Japan.

Accepted for publication 26 March 1999

- Gass JDM. Acute zonal occult outer retinopathy. Donders Lecture: The Netherlands Ophthalmological Society, Maastricht, Holland, 19 June 1992. *J Clin Neuro-Ophthalmol* 1993;13:79-97.
- Lee AG, Prager TC. Acute zonal occult outer retinopathy. *Acta Ophthalmol Scand* 1996;74:93-5.
- Jacobson SG, Morales DS, Sun XK, et al. Pattern of retinal dysfunction in acute zonal occult outer retinopathy. *Ophthalmology* 1995;102:1187-98.
- Sutter EE, Tran DD. The field topography of ERG components in man. I: The photopic luminance response. *Vis Res* 1992;32:433-46.
- Arai M, Nao-i N, Sawada A, et al. Multifocal electroretinogram indicates visual field loss in acute zonal occult outer retinopathy. *Am J Ophthalmol* 1998;126:466-9.
- Holz FG, Kim RY, Schwartz SD, et al. Acute zonal occult outer retinopathy (AZOOR) associated with multifocal choroidopathy. *Eye* 1994;8:77-83.
- Gass JDM. Acute zonal occult outer retinopathy. In: *Stereoscopic atlas of macular diseases: diagnosis and treatment*. St Louis: Patterson, 1997:682-3.
- Jampol LM, Wiredu A, MEWDS, MFC, PIC, AMN, AIBSE, and AZOOR: one disease or many? (Editorial.) *Retina* 1995;15:373-8.

Hypotonic maculopathy following pneumatic retinopexy: a UBM study

EDITOR.—Pneumatic retinopexy is a promising surgical alternative in selected cases of retinal detachment.

We report a rare complication, to our knowledge the first ever reported, of this procedure—namely, hypotonic maculopathy, caused by a wound dehiscence on a patient who had previously undergone a standard extracapsular extraction with posterior chamber implant. Ultrasound biomicroscopy (UBM) proved to be a valuable adjunct in both the diagnosis and management of this complicated case.

CASE REPORT

A 63 year old white man, complaining of a shadow in his right visual field, was referred to our department in April 1997 for further management. Ocular history was notable for bilateral extracapsular cataract extraction with posterior chamber lens implantation (PC/IOL); right eye in January 1997 and left eye in June 1996. Visual acuities were 20/25 in both eyes. IOPs were within normal limits. Anterior segment examination was unremarkable with well positioned IOLs. Fundal examination of his right eye revealed a superotemporal macula on rhegmatogenous retinal detachment, produced by a single horseshoe retinal break around 10 o'clock. After the risks and benefits of pneumatic retinopexy were explained to the patient he chose to have the procedure.

Cryopexy was applied to the tear and after an anterior chamber paracentesis was performed 0.7 ml of 100% SF₆ gas was injected into the vitreous cavity 3.5 mm behind the limbus inferotemporally.

He tolerated the procedure well and made an excellent recovery with the retina totally attached. He maintained a 20/30 visual acuity right eye, IOP remained within normal limits until 3 months later. At that time an IOP of 6 mm Hg and a deterioration of visual acuity to 20/70 was noted. Initially this visual loss was attributed to a posterior capsule opacification and a YAG capsulotomy was performed.

Between October 1997 and November 1997 he was presented to our unit on three occasions complaining of further deterioration of vision to 20/200, IOPs between 3-5 mm Hg, and a full blown hypotonous maculopathy. After 5 months of hypotony of "unknown origin", a diagnosis was made by a glaucoma specialist using indentation gonioscopy revealing a dehiscence of the cataract wound. A preoperative UBM study confirmed the presence of an internal wound gap, behind the limbus, superotemporally, 3 mm in circumference. Ultrasonically the wound dehiscence was depicted as a narrow slit (Fig 1) with a flat inadvertent bleb above which was not apparent clinically. A surgical repair of the wound was decided upon. Intraoperatively no definite dehiscence could be clinically identified. Balanced salt solution through a 30 gauge needle was repeatedly injected under pressure to the anterior chamber but this failed to localise any suspicious area. At this point, based on the ultrasonic study, two 10-0 nylon interrupted sutures were placed through the sclera parallel to the limbus in the suspicious area. These bites were moderately deep in an attempt to engage the internal flap of the cataract wound.

Two weeks postoperatively, the pressure normalised (IOP 12 mm Hg), maculopathy was reversed, and visual acuity improved to 20/50.

Hypotonic maculopathy is an unusual and, to our knowledge, the first reported complication^{1,2} of this kind after pneumatic retinopexy. We hypothesise that the original cataract wound did not heal properly and the additional cryoprobe manipulation caused the

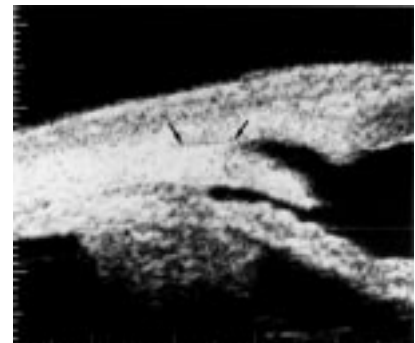


Figure 1 UBM picture of right eye showing the external part of the dehiscence cataract wound, as a narrow slit, before repair (area between arrows). There is a full blown hypotonous maculopathy in this eye, with VA 20/200.

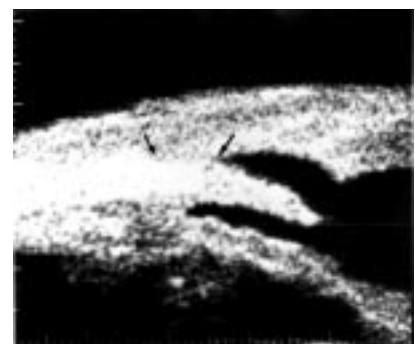

Figure 2 UBM picture of right eye showing the same area after repair. Note that the external part of the wound is totally closed (area between arrows) while internal wound gap appears to be more pronounced postoperatively. However, at this point the leak is rectified. IOP and macula are normal with VA of 20/50.

wound to leak. The UBM study provided us with an interesting insight into how the scleral suture repair may have worked to correct the wound leak as shown in Figure 2. The fact that hypotony resolved after suturing the wound, indicated that the external part of the wound was secure (no slit is apparent) despite the fact that the internal part of the wound was gaping even more postoperatively. This finding implies, therefore, that only minimal overall alteration of the wound architecture postoperatively, sufficient to rectify the leak.

We believe that UBM is a valuable adjunct in the management of similar cases by clearly identifying both the presence and exact location of leak. Finally, pneumatic retinopexy should be performed with caution, especially in cases of previously operated eyes with large incision wounds.

IOANNIS M ASLANIDES

Department of Ophthalmology, Vitreo-retinal Unit,
St Michael's Hospital, University of Toronto,
Canada and VEIC (Vardinoyannion Eye Institute of
Crete), Greece

CHARLES J PAVLIN

Department of Ophthalmology, Ocular Oncology Clinic,
Princess Margaret Hospital, University of Toronto,
Canada

LOUIS R GIAVEDONI

Department of Ophthalmology, Vitreo-retinal Unit,
St Michael's Hospital, University of Toronto,
Canada

Correspondence to: Dr Ioannis M Aslanides, Vardinoyannion Eye Institute of Crete. University of Crete Medical School, Voutes PO Box 1352, Iraklion-Crete 71110, Greece.

Accepted for publication 26 March 1999

- Hilton GF, Tornambe PE. Pneumatic retinopexy. An analysis of intraoperative and postoperative complications. The Retinal Detachment Group. *Retina* 1991;11:285-94.
- Hilton GF, Tornambe PE, Brinton DA, et al. The complication of pneumatic retinopexy. *Trans Am Ophthalmol Soc* 1990;88:191-207; discussion 207-10.

Bilateral electrical cataract

EDITOR.—Electric trauma is not uncommon in India where majority of the population lives in the rural setting. Few cases of electric cataract have been reported in literature probably because few patients survive the high voltage of current that induces cataract formation. Most patients with electric cataract have no subjective complaints early on but become aware of the reducing visual function several months later.¹

CASE REPORT

A 26 year old man complained of gradual and painless diminution of vision in both eyes, right more than left, for the past 2-3 years. There was a history of an overhead high tension electric transmission cable accidentally falling on the patient's head 4-5 years earlier. This had resulted in immediate burn to the scalp. The patient was visually asymptomatic till about 1 year after the mishap, when he began to notice the gradual fall in vision that had progressed to its present state.

Corrected visual acuity was 20/200 right eye and 20/60 left eye. A 15 × 2.5 cm linear, sagittal scar extending from the frontal to the occipital region of the head was noticed. The lids, conjunctiva, cornea, and pupils showed no abnormality in either eye. Fundus examination was unremarkable. Slit lamp examination revealed multiple, mid-peripheral snowflake-like anterior subcapsular lens

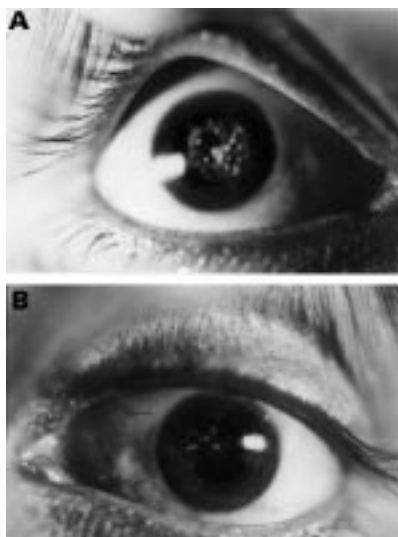


Figure 1 The characteristic anterior subcapsular lens opacities. (A) Right eye, (B) left eye.

opacities in both eyes, right greater than left. In the right eye some of these opacities were seen encroaching into the visual axis and additionally a few posterior subcapsular opacities were noticed (Fig 1).

In view of the history of electrical injury and classic location and typical appearance of the lens opacities, a diagnosis of bilateral electric cataract was made. Extracapsular cataract extraction (ECCE) with posterior chamber intraocular lens implantation was undertaken in both eyes, right eye first followed 3 months later in left eye. The intraoperative and postoperative course were uneventful and the patient has achieved corrected visual acuity of 20/20 in both eyes.

COMMENT

Involvement of the lens exclusively, sparing other ocular structures is rare. This case documents such a possibility and also highlights the salient features involving electric trauma to the lens. The scalp burn in this case

represents the entrance wound for the electrical energy but the lack of an exit wound makes this case particularly peculiar. Both entry and exit sites for the electric current have been reported by all previous authors.

The excellent surgical results noted in both eyes of this patient are in keeping with the similar result reported by Portellos *et al.*² This observation should encourage the ophthalmologist to undertake surgery for electric cataract, where necessary, without any undue concern.

USHA K RAINA

DEVEN TULI

Guru Nanak Eye Center, Maulana Azad Medical College, New Delhi, India

Correspondence to: Dr Usha K Raina, 427 Hawa Singh Block, Asiad Village Complex, New Delhi-110 049, India.

Accepted for publication 7 April 1999

- Long JC. Electric cataract: report of three cases. *Am J Ophthalmol* 1966;61:1235-9.
- Portellos M, Orlin SE, Kozart DM. Electric cataracts. *Arch Ophthalmol* 1996;114:1022.

Monckeberg's sclerosis in temporal artery biopsy specimens

EDITOR.—Temporal artery biopsies are performed routinely on patients suspected of having giant cell arteritis. Of 131 pathology specimens examined at University of Illinois at Chicago Eye Center from 1975 to 1998, the most common diagnosis was atherosclerosis with myointimal fibrosis (63%) followed by giant cell arteritis (13%). In about 6% of cases we encountered calcific sclerosis confined to the tunica media which was associated with mild tissue disorganisation surrounding the calcific plaque and disruption of the internal elastic lamina (Fig 1).

Monckeberg's sclerosis as seen in these specimens was first described by Monckeberg in 1903. It commonly affects medium size muscular arteries and is described in femoral, tibial, radial, coronary, cerebral, and visceral arteries.¹ However, its association with the temporal artery is uncommon. The infrequent occurrence of this condition in the temporal artery and the presence of a fragmented inter-

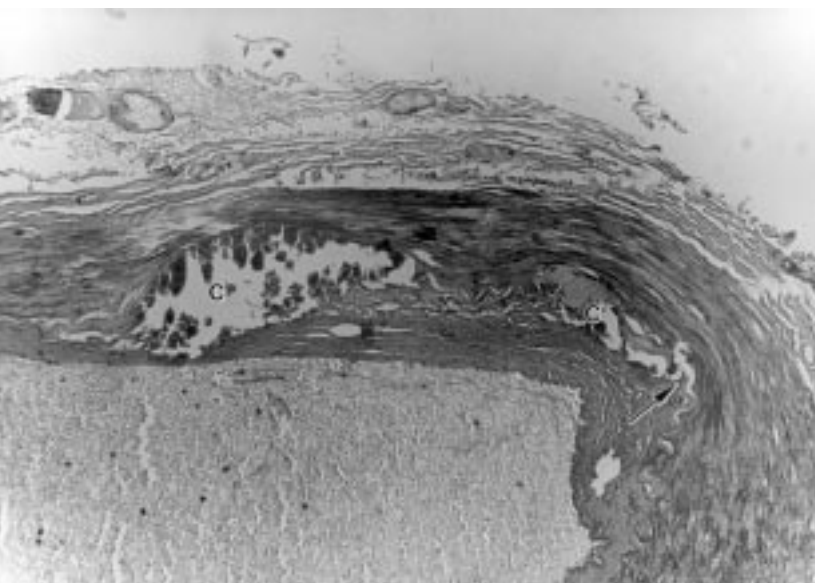


Figure 1 Cross section through temporal artery showing disrupted internal elastic lamina (arrow) and large calcific plaques (C) in the tunica media (haematoxylin and eosin; original magnification ×40).

nal elastic lamina should not be erroneously interpreted as sequelae of previous arterial inflammation. The pathophysiology of Monckeberg's arteriosclerosis is still unclear, but it can be induced in animal models by injecting adrenalin, nicotine, parathyroid hormone, and vitamin D.² In addition, lumbar sympathectomy has been shown to promote occurrence of Monckeberg's arteriosclerosis of the lower extremities in humans.³ Automatic dysfunction from diabetic neuropathy is thought to be responsible for the occurrence of Monckeberg's in diabetic patients.⁴ Unlike atherosclerosis, Monckeberg's arteriosclerosis is a benign condition and does not cause vascular thrombosis. In conclusion, Monckeberg's arteriosclerosis of the temporal artery may be seen occasionally in the temporal artery.⁵ It is an interesting histological diagnosis that has little clinical significance but should be recognised in temporal biopsy specimens.

BIENVENIDO V CASTILLO JR
ELISE TORCZYNSKI
DEEPAK P EDWARD

Department of Ophthalmology, University of Illinois at Chicago, Chicago, IL, USA

Correspondence to: Dr Deepak P Edward, Department of Ophthalmology, University of Illinois at Chicago, 1855 W Taylor Street, Chicago, IL 60612, USA.

Accepted for publication 9 April 1999

- 1 Lachman A, Spray T, Kerwin D, *et al.* Medial calcinosis of Monckeberg. A review of the problem and a description of a patient with involvement of peripheral, visceral, and coronary arteries. *Am J Med* 1977;63:615-22.
- 2 Silbert S, Lippmann H, Gordon E. Monckeberg's arteriosclerosis. *JAMA* 1953;151:1176-9.
- 3 Goebel F, Fuessel H. Monckeberg's sclerosis after sympathetic denervation in diabetic and non-diabetic subjects. *Diabetologia* 1983;24:347-50.
- 4 Gentile S, Bizzaro A, Mario R, *et al.* Medial arterial calcification and diabetic neuropathy. *Acta Diabetol Lat* 1990;27:243-53.
- 5 Albert D. Principles of pathology. In: Albert D, Jakobiec, eds. *Principles and practice of ophthalmology* 1994;4:2113.

Retinal vascular abnormality in Poland's syndrome

EDITOR.—Poland's syndrome is a congenital anomaly first described in 1841¹ consisting of unilateral hypoplasia or aplasia of the pectoralis major muscle and ipsilateral upper extremity abnormalities which often include ipsilateral syndactyly. Since then a number of associated anomalies have been reported. These include absence of the pectoralis minor muscle, absence or atrophy of ipsilateral ribs two to five, aplasia of the ipsilateral breast or nipple, and simian crease of the affected extremity. Although vascular alterations associated with this syndrome have been described,² no involvement of eye vasculature has been reported so far.

CASE REPORT

We examined a 39 year old man previously diagnosed with Poland's syndrome who came to our clinic because he had experienced blurred vision in the right eye for 2 months. Computed axial tomography, arteriography, and abdominal echography revealed absence of the left kidney. There was no history of diabetes or hypertension. The ophthalmological examination of the right eye revealed a visual acuity of 20/50 and a paracentral relative scotoma. The right eye fundus showed perimacular capillary telangiectasis, retinal vascular distortion, moderate perimacular

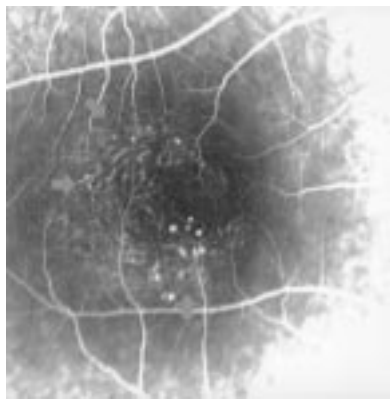


Figure 1 Early venous phase fluorescein angiogram of the right eye, macular area. Note the easily visible telangiectatic retinal capillaries (arrows). These abnormal vessels showed significant leakage of fluorescein in the late phase of the angiogram.

hard exudates, and retinal swelling, all of them more prominent in the temporal perimacular area. Fluorescein angiography clearly showed the vascular abnormalities (Fig 1). The left eye fundus was normal. A diagnosis of juxtafoveal retinal telangiectasis³ was made.

COMMENT

Juxtafoveal telangiectasis is difficult to detect ophthalmoscopically⁴ and therefore can be neglected by routine eye fundus examinations made before the first visual symptoms appear. Unilateral renal agenesis occurs in approximately 1 per 1000 births and can be associated with vascular anomalies.⁵

The aetiology of juxtafoveal telangiectasis is unknown. The patient we examined had retinal vascular malformations that may have originated in the early stages of life. Indeed, the deformed capillaries may dysfunction for many years before endothelial decompensation causes retinal swelling.³ While the exact pathogenesis of Poland's syndrome is not well known, it has been postulated that the original cause may be a vascular abnormality at the embryonic stages.⁶ The vascular abnormalities, mostly of the diseased hemithorax, reported in this syndrome² and our finding of retinal vascular abnormalities in this patient support this hypothesis.

To our knowledge, this is the first reported case of coexistent juxtafoveal telangiectasis, renal agenesis, and Poland's syndrome. Although we are not aware of direct evidence reported in the literature indicating any retinal involvement linked to this syndrome, it is plausible that the three anomalies found in this patient may have had common original vascular causative factors. Therefore, we recommend a careful eye fundus examination of patients presenting with this syndrome.

This work was partially supported by grants XUGA-20802B97 and DGESIC PB97-0521.

FRANCISCO GOMEZ-ULLA
Servicio de Oftalmología, Facultad de Medicina,
Complejo Hospitalario Universitario de Santiago,
E-15705 Santiago de Compostela, Spain

FRANCISCO GONZALEZ
Servicio de Oftalmología and Departamento de
Fisiología, Facultad de Medicina, Complejo
Hospitalario Universitario de Santiago,
E-15705 Santiago de Compostela, Spain

Correspondence to: Dr Francisco Gomez-Ulla or Dr Francisco Gonzalez, Servicio de Oftalmología,

Complejo Hospitalario Universitario de Santiago, c/Galeras s/n E-15705 Santiago de Compostela, Spain.

Accepted for publication 9 April 1999

- 1 Poland A. Deficiency of the pectoral muscles. *Guys Hosp Rep* 1841;6:191-3.
- 2 Beer GM, Kompatscher P, Hergan K. Poland's syndrome and vascular malformations. *Br J Plast Surg* 1996;49:482-4.
- 3 Gass JD, Blodi BA. Idiopathic juxtafoveal retinal telangiectasis. Update of classification and follow-up study. *Ophthalmology* 1993;100:1536-46.
- 4 Park DW, Schatz H, McDonald R, *et al.* Grid laser photocoagulation for macular edema in bilateral juxtafoveal telangiectasis. *Ophthalmology* 1997;104:1838-46.
- 5 Welling LW, Grantham JJ. Cystic and developmental diseases of the kidney. In: BM Brenner, FC Rector Jr, eds. *The kidney*, 4th ed. Philadelphia: WB Saunders, 1991:1657-94.
- 6 Bavnick JNB, Weaver DD. Subclavian artery supply disruption sequence: hypothesis of a vascular etiology for Poland, Klippel-Feil, and Möbius anomalies. *Am J Med Genet* 1986;23: 903-18.

Bilateral optic disc oedema associated with latanoprost

EDITOR.—Latanoprost is a recent addition to the medical management of raised intraocular pressure in chronic open angle glaucoma and ocular hypertension. It is a potent ocular hypotensive agent with few ocular or systemic side effects.

We report a case of bilateral optic disc oedema developing soon after commencing treatment with latanoprost which resolved once therapy was stopped.

CASE REPORT

An asymptomatic 64 year old woman presented with raised intraocular pressure. She maintained good general health, had no significant past medical or family history, and was not on any medication. Snellen visual acuities were 6/5 both eyes. The intraocular pressures were 28 mm Hg right eye and 26 mm Hg left eye. Ocular examination was otherwise unremarkable with open angles, normal optic nerves, and full Humphrey 24-2 visual fields. She was thus diagnosed as having ocular hypertension and consented to enter a prospective double masked trial comparing some of the intraocular pressure lowering drops. Therapy was commenced with one of the drugs involved in the study and at a 1 month review she reported no problems with the drops. The intraocular pressures had lowered to 16 mm Hg in both eyes and the examination was otherwise unchanged. At her third visit 2 months later, she was again asymptomatic with visual acuities of 6/5 in both eyes and intraocular pressures of 15 mm Hg. However, examination of the optic nerves revealed bilateral oedema which was more prominent in the left eye. There were no signs of uveitis in either eye, pupillary reflexes were normal, colour vision and Amsler testing were not affected, and the visual fields were full. At this point the code for the trial drug was broken and it was seen that she had been using latanoprost 0.005% eye drops at night to both eyes over the 3 month period. A neurological consultation failed to find any neurological abnormality and all haematological and biochemical analyses were normal. A computed tomograph scan with contrast showed no abnormality and she was discharged from neurological review. Follow up in the eye clinic revealed no change after 72 hours. The latanoprost was stopped and the disc swelling had largely resolved at 1 week. By 10 weeks

both optic nerves looked normal. Visual acuities were still 6/5 in both eyes and there was no loss of colour vision or visual field. The intraocular pressures had increased to 22 mm Hg in both eyes.

COMMENT

Latanoprost is a prostaglandin $F_{2\alpha}$ analogue which acts by increasing uveoscleral outflow. Side effects include increased iris pigmentation,¹⁻³ hypertrichosis and increased eyelash pigmentation,⁴ anterior uveitis in patients with complicated glaucoma or in those having had previous incisional surgery,^{5,6} and cystoid macular oedema occurring soon after beginning latanoprost in pseudophakic or aphakic eyes.⁶⁻⁹ Ocular hypotony with choroidal effusions and facial rash have also been attributed to latanoprost.⁹ To the best of our knowledge, optic disc oedema associated with latanoprost has not previously been described. The mechanism behind this association is unclear. One may not be surprised to see optic nerve swelling in association with signs of posterior uveitis or hypotony but in this case it occurred without any sign of ocular inflammation and the lowest recorded intraocular pressure was 15 mm Hg. It may be feasible that the perfusion to the optic nerve heads via the short posterior ciliary arteries was compromised by a prostaglandin-like action manifesting as disc oedema. Astin found that latanoprost acid and prostaglandin $F_{2\alpha}$ at high concentrations could cause vasoconstriction of bovine ciliary arteries¹⁰ and a similar action cannot be discounted in this case. The rapid resolution of the swelling with seemingly no long term sequelae once latanoprost was stopped would perhaps support this hypothesis.

OWEN STEWART
LOUISE WALSH
MILIND PANDE

Department of Ophthalmology,
Hull Royal Infirmary, Hull

Correspondence to: Mr Owen Stewart, Department of Ophthalmology, St James's University Hospital, Leeds LS9 7TF.

Accepted for publication 12 April 1999

- 1 Watson PG. Latanoprost. Two years' experience of its use in the United Kingdom. *Latanoprost Study Group. Ophthalmology* 1998;105:82-7.
- 2 Alm A, Camras CB, Watson PG. Phase III latanoprost studies in Scandinavia, the United Kingdom and the United States. *Surv Ophthalmol* 1997;41(Suppl 2):S105-10.
- 3 Bito LZ. Prostaglandins: a new approach to glaucoma management with a new, intriguing side effect. *Surv Ophthalmol* 1997;41(Suppl 2):S1-14.
- 4 Johnstone MA. Hypertrichosis and increased pigmentation of eyelashes and adjacent hair in the region of the ipsilateral eyelids of patients treated with unilateral topical latanoprost. *Am J Ophthalmol* 1997;124:544-7.
- 5 Fechtner RD, Khouri AS, Zimmerman TJ, et al. Anterior uveitis associated with latanoprost. *Am J Ophthalmol* 1998;126:37-41.
- 6 Warwar RE, Bullock JD, Ballal D. Cystoid macular edema and anterior uveitis associated with latanoprost use. Experience and incidence in a retrospective review of 94 patients. *Ophthalmology* 1998;105:263-8.
- 7 Callanan D, Fellman RL, Savage JA. Latanoprost-associated cystoid macular edema. *Am J Ophthalmol* 1998;126:134-5.
- 8 Gaddie IB, Bennett DW. Cystoid macular edema associated with the use of latanoprost. *J Am Optom Assoc* 1998;69:122-8.
- 9 Rowe JA, Hattenhauer MG, Herman DC. Adverse side effects associated with latanoprost. *Am J Ophthalmol* 1997;124:683-5.
- 10 Astin M. Effects of prostaglandin E2, F2alpha, and latanoprost acid on isolated ocular blood vessels in vitro. *J Ocular Pharmacol Ther* 1998;14:119-28.

Somatostatin scan positive gastrinoma ocular metastasis

EDITOR.—Symptomatic ocular metastases are uncommon despite the 4% prevalence in patients dying of all types of malignancy in postmortem series.¹ We report a case of ocular metastasis from a gastrinoma, which was part of the Wermer's syndrome (multiple endocrine neoplasia (MEN) type 1), diagnosed by indium labelled octreotide scanning.

CASE REPORT

A 57 year old man presented with a 1 week history of blurring in his peripheral vision in his right eye and severe loss of visual acuity, worse early morning. He had been diagnosed with MEN type 1, 8 years previously after two perforated jejunal ulcers (1978, 1990) led to a diagnosis of Zollinger-Ellison syndrome, and a hyperplastic parathyroid gland had been removed for hypercalcaemia (1990). His mother had MEN type 1.

Ophthalmic examination revealed 6/12 acuity in the right eye and 6/5 in the left. His anterior segments were unremarkable. His right fundus showed a solid amelanotic lesion about one disc diameter above the right disc. Ultrasonography demonstrated a base of 13 mm and a height of 8 mm. He also had bilateral inferior retinoschisis. One month later the tumour base measured 14.5 mm and the thickness measured 7.9 mm. The posterior edge now practically abutted the optic disc (Fig 1). There was subretinal fluid accumulation.

A liver ultrasound scan showed multiple lesions and a tumour biopsy was composed of small solid islands of polygonal cells with granular cytoplasm, diagnostic of metastatic neuroendocrine carcinoma (immunostaining positive for chromogranin, neuron specific enolase, and NCAM, negative for S-100 and HMB45 (melanoma markers)). His urinary 5HIAA was marginally raised at 133 $\mu\text{mol}/24$ hours (normal up to 75), and a fasting intestinal peptide screen, showed a highly elevated gastrin level (on omeprazole 40 mg per day) of 343 pmol/l (normal range 0-40 pmol/l) but normal levels of other polypeptides.

No primary tumour or further metastases were seen using body computed tomograph and magnetic resonance imaging scans and the I-123 MIBG scan (meta-iodobenzyl guanidine) was also negative. An indium (In-111) labelled octreotide scan at 1 and 4 hours +SPET showed focal areas of increased uptake in the right orbit (Fig 2), the nasal region, mediastinum, multiple sites in the liver, and possibly other abdomen sites. However, a positive octreotide scan is not exclu-

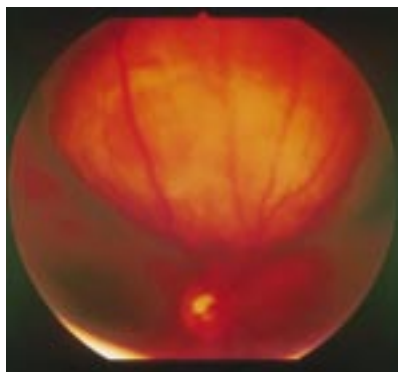


Figure 1 Retinal photograph showing amelanotic neuroendocrine tumour.

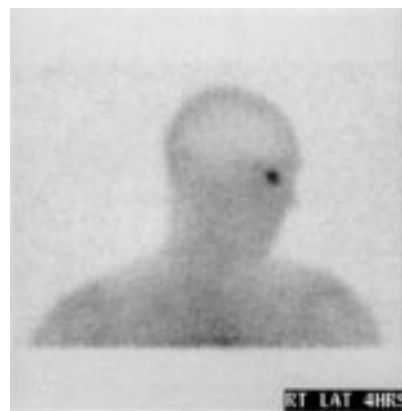

Figure 2 Image from indium (In-111) labelled octreotide scan taken 4 hours after injection showing very avid focal uptake in the right orbit.

sively seen with neuroendocrine tumours, since other tissues have somatostatin receptors. These include high grade lymphoma, some small cell lung cancers, occasional tumours of the breast, and in chronic inflammatory conditions where there is T cell activation including endocrine ophthalmopathy with orbital involvement. Thus, although an absolute positive diagnosis of metastatic gastrinoma cannot be made definitively in the absence of histology, in the context of this clinical case it is highly probable that the choroidal tumour is due to ocular metastasis from gastrinoma.

COMMENT

Gastrinoma may occur sporadically or as part of multiple endocrine neoplasia. MEN type 1 is a rare disorder, usually inherited in an autosomal dominant fashion with high penetrance which affects multiple endocrine glands (hyperparathyroid hyperplasia in 80-90%, pancreatic islet tumours in 50%, and pituitary adenomas in 40-50%).²

Ocular metastasis from gastrinoma has not previously been reported, although it has been reported in other neuroendocrine tumours—for example, carcinoid.³ Multiple or metastatic gastrinomas (especially if actively secreting) are best localised by a new radioisotope scan using radioactively labelled somatostatin analogues.^{4,5} Somatostatin is a peptide elaborated by the delta cells of the islets of Langerhans and the hypothalamus. It inhibits the secretion of gastrin by gastric mucosa and many other hormones such as insulin, thyrotropin, and corticotropin. Somatostatin receptors are found on neuroendocrine tumours (80% of gastrinomas) and indium labelled octreotide visualises all somatostatin receptor positive gastrinomas.^{4,5} Our scans revealed somatostatin avid liver metastases. Interestingly, the scan also very clearly confirmed the ocular/orbital disease. Orbital radiotherapy and chemotherapy were recommended.⁶

KEIR E LEWIS
PAUL B ROGERS
Department of Clinical Oncology

JOHN HUNGERFORD
Department of Ocular Oncology

KEITH E BRITTON
Department of Nuclear Medicine

P NICHOLAS PLOWMAN
Department of Clinical Oncology, St Bartholomew's
Hospital, West Smithfield, London EC1A 7BE

Correspondence to: Dr Plowman.

Accepted for publication 12 April 1999

- 1 Nelson CC, Hertzberg BS, Klintworth GK. A histopathologic study of 716 unselected eyes in patients with cancer at the time of death. *Am J Ophthalmol* 1983;**95**:788-93.
- 2 Thakker RV. Multiple endocrine neoplasia type 1. In: Grossman A, ed. *Clinical endocrinology*. 2nd ed. Oxford: Blackwell Science, 1998:621-34.
- 3 Riddle PJ, Font RL, Zimmerman LE. Carcinoid tumors of the eye and orbit: a clinicopathologic study of 15 cases with histochemical and electron microscopic observations. *Hum Pathol* 1982;**13**:459-69.
- 4 McInerney GF, Carmalt H, MaGee M, et al. Detection of multiple hepatic metastases of gastrinoma not apparent on CT by In-111 octreotide scintigraphy. *Clin Nucl Med* 1996;**21**:730-1.
- 5 Kisker O, Bartsch D, Weinel RJ, et al. The value of somatostatin-receptor scintigraphy in newly diagnosed endocrine gastroenteropancreatic tumors. *J Am Coll Surg* 1997;**184**:487-92.
- 6 Minatel E, Trozo MG, Forrer L, et al. The efficacy of radiotherapy in the treatment of intraocular metastases. *Br J Radiol* 1993;**66**:699-702.

Retinal neovascularisation in Goltz syndrome (focal dermal hypoplasia)

EDITOR.—This is the first reported case of Goltz syndrome with documented peripheral retinal non-perfusion with subsequent retinal neovascularisation and vitreous haemorrhage. In the eye this represents solely a mesodermal disturbance compared with the more common cases which present with both mesodermal and neuroectodermal disturbances, such as colobomata or microphthalmia.

CASE REPORT

Goltz syndrome was diagnosed shortly after birth in a girl with linear lesions of atrophic skin following Blaschko's lines on the trunk and symmetrical syndactyly of the third to fourth fingers and second to third toes. Initial ophthalmic screening revealed no ocular anomalies. Dental screening revealed the congenital absence of one deciduous incisor. Screening of the parents, brother, and sister was negative for skin, skeletal, and ocular anomalies. When she was aged 5 years, routine ophthalmic review showed a vision of right eye 6/9 and left eye 6/5, with a minor right myopia.

Age 7 years, she complained of a brief episode of photopsia and floaters in the right eye. Vision was right eye 6/20 and left eye 6/6. Examination revealed a right vitreous haemorrhage, telangiectatic vessels temporal to the macula, and temporal equatorial fibrotic

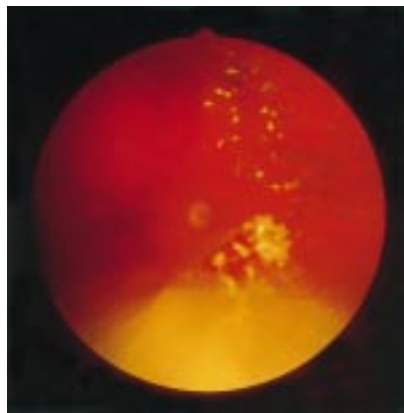


Figure 1 Colour fundus photograph of right temporal retina showing perfused retina (photo right) to peripheral non-perfusion (photo left) with fibrotic vessels and neovascular complex in the transition zone. (Inferior discoloration is artefact.)

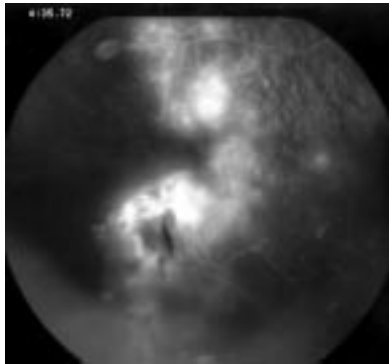


Figure 2 Fluorescein angiogram of same area showing peripheral non-perfusion and haemorrhage arising from the neovascular complex. The arborisation of the retinal vessels appears normal till the transitional zone.

vessels and haemorrhage. Fluorescein angiography showed bilateral peripheral retinal non-perfusion and right temporal neovascularisation (see Figs 1 and 2). This was treated conservatively for 2 years; however, after six bleeds within 3 months indirect retinal photocoagulation to the areas of non-perfusion was performed with subsequent new vessel regression within weeks.

COMMENT

Focal dermal hypoplasia is a rare disorder of ectodermal and mesodermal dysplasia originally described by Goltz *et al.*¹ It is characterised by congenital atrophic skin changes often associated with herniation of the subcutaneous fat; skeletal anomalies, in particular syndactyly, polydactyly, or adactyly as well as scoliosis, kyphosis, spina bifida occulta, rib and scapula anomalies; and dental anomalies, especially hypodontia.

Ocular anomalies occur in 40% of cases.² Colobomata have been reported in one third of cases, then less frequently microphthalmia, strabismus, nystagmus, and ectopia lentis.³ Other reported ocular anomalies include anophthalmia, corneal clouding, aniridia, heterochromia, and optic atrophy. Rarely ectropion and ptosis may occur as well as lid margin or conjunctival papillomatous lesions (histological angiofibromas).^{1,2,4,5} Only one case of cloudy vitreous has been reported. This was in association with microphthalmia, aniridia, and lens subluxation.⁶ Retinal sclerosis or hypopigmentation was reported in Goltz's original case review.¹ No attempt was made to explain these findings. In our case, there was peripheral retinal non-perfusion and temporal retinal telangiectasia with subsequent neovascularisation and vitreous haemorrhage.

The differential diagnosis of retinal vascular anomalies associated with skin lesions includes incontinentia pigmenti (IP) and Cockayne's syndrome. Although focal skin atrophy may occur in IP, the initial skin lesions are vesicles and bullae which may later become pigmented maculae. The skin lesions in Cockayne's syndrome are pigmented scars due to light sensitivity and trauma. Neither syndrome is associated with digital anomalies.

The genetic anomaly in Goltz syndrome remains to be determined. Most cases are sporadic. It is generally thought to be X linked dominant with lethality in males, like IP; however, 9% of cases are male. These are proposed to be the result of half chromatid mutations.⁷ Deletions in the region of the chromosome Xp22 are a suggested site, though these must be differentiated from the

deletions seen in microphthalmia with linear skin defects (MLS) and that of microphthalmia, dermal aplasia, and sclerocornea (MIDAS), which are now considered to be distinct entities.^{8,9} The wide variation in severity of expression is thought to be due to mosaicism.

A A S DUNLOP
Medical Retinal Unit, Moorfields Eye Hospital,
City Road, London

J I HARPER
Department of Dermatology, Great Ormond Street
Hospital for Children, London

A M P HAMILTON
Medical Retinal Unit, Moorfields Eye Hospital,
City Road, London

Correspondence to: Dr A A S Dunlop, 66 King Street, Newcastle, NSW 2300, Australia.
Accepted for publication 19 April 1999

- 1 Goltz RW, Peterson WC, Gorlin RJ, et al. Focal dermal hypoplasia. *Arch Derm* 1962;**86**:708-17.
- 2 Thomas JV, Yoshizumi MO, Beyer CK, et al. Ocular manifestations of focal dermal hypoplasia syndrome. *Arch Ophthalmol* 1977;**95**:1997-2001.
- 3 Warburg M. Focal dermal hypoplasia: ocular and general manifestations with a survey of the literature. *Acta Ophthalmol* 1970;**48**:525-36.
- 4 Hall EH, Terezhalmay GT. Focal dermal hypoplasia syndrome: case report and literature review. *J Am Acad Dermatol* 1983;**9**:443-51.
- 5 Marcus DM, Shore JW, Albert DM. Anophthalmia in the focal dermal hypoplasia syndrome. *Arch Ophthalmol* 1990;**108**:96-100.
- 6 Holden JD, Akers WA. Goltz's syndrome: focal dermal hypoplasia. A combined mesoectodermal dysplasia. *Am J Dis Child* 1967;**114**:292-300.
- 7 Temple IK, MacDowall P, Baraitser M, et al. Focal dermal hypoplasia (Goltz syndrome). *J Med Genet* 1990;**27**:180-7.
- 8 Van den Veyver IB, Cormier TA, Jurecic V, et al. Characterization and physical mapping in human and mouse of a novel RING finger gene in Xp22. *Genomics* 1998;**15**:251-61.
- 9 Happle R, Daniels O, Koopman RJ. MIDAS syndrome (microphthalmia, dermal aplasia and sclerocornea): an X-linked phenotype distinct from Goltz syndrome. *Am J Med Genet* 1993;**47**:710-3.

Retinitis sclopeteria associated with airbag inflation

EDITOR.—Chorioretinitis sclopeteria is a severe form of blunt trauma, caused by a high velocity object grazing the globe but not penetrating it. It is a concussion injury, which usually manifests as severe choroidal and retinal rupture associated with haemorrhage but an intact sclera.¹ We report a case of chorioretinitis sclopeteria resulting from deployment of an airbag in a stationary motor vehicle.

CASE REPORT

A 32 year old pregnant woman was the driver in a car accident in which the airbag failed to deploy at the time of impact but inflated when she returned to sit in the driver's seat approximately 5 minutes after the accident occurred. The patient was not wearing spectacles and there was no evidence of injury from other sources.

At presentation the visual acuity was hand movements in the left eye and 6/6 in the right eye. Examination revealed evidence of swollen eyelids and marked chemosis and subconjunctival haemorrhages on the left, with no bony injury and a full range of eye movements. Anterior segment examination revealed a clear left cornea and a quiet anterior chamber with a microhyphaema. The lens was clear and there was no evidence of subluxation. There was no angle recession and the intraocular

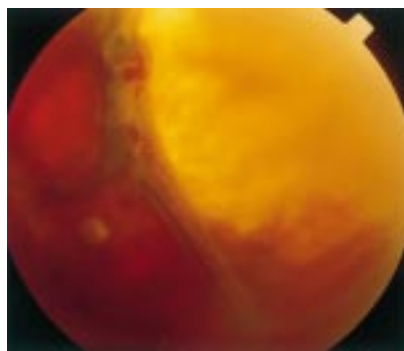


Figure 1 Airbag injury with retinitis sclopeteria, an intragel haemorrhage, and attached retina.

pressure was recorded at less than 4 mm Hg. Fundal examination revealed evidence of a retinal tear although details were obscured by a diffuse vitreous haemorrhage. An ultrasound examination showed a vitreous haemorrhage and large retinal tear but no evidence of a scleral perforation.

An examination under anaesthesia performed the following day confirmed that there was no scleral rupture and indirect ophthalmoscopy confirmed the findings of diffuse vitreous haemorrhage and a retinal tear.

At the 2 week postoperative clinic visit, visual acuity had improved to 6/18. There was 2+ cells in the anterior chamber and the intraocular pressure was 24 mm Hg. Posterior segment findings were an intragel haemorrhage and retinitis sclopeteria with no evidence of retinal detachment.

Four months later, the best corrected visual acuity was 6/36. The anterior chamber activity had settled; the intraocular pressure was 10 mm Hg, and fundal examination was unchanged. In view of the persistent vitreous haemorrhage the patient was listed for routine pars plana vitrectomy in the postpartum period.

COMMENT

Airbags are designed to protect the driver from direct impact from the steering wheel, dashboard, and windscreen. They are designed to inflate in 10 ms in response to sudden deceleration and during deployment, the airbag is propelled out of its storage compartment at speeds of more than 100 mph.² Following inflation the airbag deflates slowly within seconds.

Facial and ocular injuries associated with airbags have been reported in the literature. Skin abrasions, burns, and eyelid ecchymoses are the most common facial injuries. Reported ocular injuries include orbital fractures, keratitis, corneal abrasions, hyphaemas, angle recession, and lens subluxation. In the posterior segment, vitreous and retinal haemorrhages, commotio retinae, retinal tears and dialyses, and choroidal ruptures have been reported.³⁻⁸ To our knowledge, this is the first reported case of retinitis sclopeteria secondary to airbag inflation.

Although airbags have clearly been shown to reduce serious morbidity and mortality

associated with road traffic accidents, they are associated with a number of injuries directly attributable to their inflation. Some of these are serious ocular injuries and it is important for ophthalmologists and others involved with trauma cases to be aware of these complications. A full ophthalmic assessment is mandatory in all cases and this should include indentation ophthalmoscopy. A variety of posterior segment injuries have been reported in the literature but this is the first report of retinitis sclopeteria resulting from airbag deployment.

R H Y ASARIA

A ZAMAN

P M SULLIVAN

Moorfields Eye Hospital, City Road,
London EC1V 2PD

Correspondence to: Mr Asaria.

Accepted for publication 19 April 1999

- 1 Richards RD, West CE, Meisels AA. Choroid-retinitis sclopeteria. *Am J Ophthalmol* 1968;852-60.
- 2 Whitacre MM, Pilchard WA. Air bag injury producing retinal dialysis and detachment [letter]. *Arch Ophthalmol* 1993;111:1320.
- 3 Leshner MP, Durrie DS, Stiles MC. Corneal edema, hyphema, and angle recession after air bag inflation [letter]. *Arch Ophthalmol* 1993;111:1320-2.
- 4 Manche EE, Goldberg RA, Mondino BJ. Air bag-related ocular injuries. *Ophthalmic Surg Lasers* 1997;28:246-50.
- 5 Rosenblatt MA, Freilich B, Kirsch D. Air bag-associated ocular injury [letter; comment]. *Arch Ophthalmol* 1993;111:1318.
- 6 Scott IU, John GR, Stark WJ. Airbag-associated ocular injury and periorbital fractures [letter]. *Arch Ophthalmol* 1993;111:25.
- 7 Han DP. Retinal detachment caused by air bag injury. *Arch Ophthalmol* 1993;191:1333-4.
- 8 Vichnin MC, Jaeger EA, Gault JA, et al. Ocular injuries related to air bag inflation. *Ophthalmic Surg Lasers* 1995;26:542-8.

Specular microscopic findings of corneal deposits in patients with Bietti's crystalline corneal retinal dystrophy

EDITOR,—In 1937, Bietti¹ first described three cases of tapetoretinal degeneration characterised by yellowish glistening retinal crystals, tapetoretinal degeneration with choroidal sclerosis, and marginal crystalline deposits of the cornea. Although more than 100 cases of crystalline retinopathy have been reported, crystalline deposits of the corneal limbus have been observed in only four out of 52 Japanese patients with crystalline retinopathy. Recently, observation using specular microscopy^{2,3} has been reported to be useful in detecting crystalline deposits at the limbus of patients with crystalline corneal retinal dystrophy. Therefore, in this study, we examined four patients with crystalline retinopathy using specular microscopy under a "con-surface" mode, which is used for the observation of the corneal surface, and we detected the deposits at the limbus.

Twelve months after the initial specular microscopic examination, we reinspected the crystalline deposits of two cases. Interestingly, the changes in the locations and forms of the crystalline deposits in the corneal limbus were exposed over time (Fig 1). More crystalline

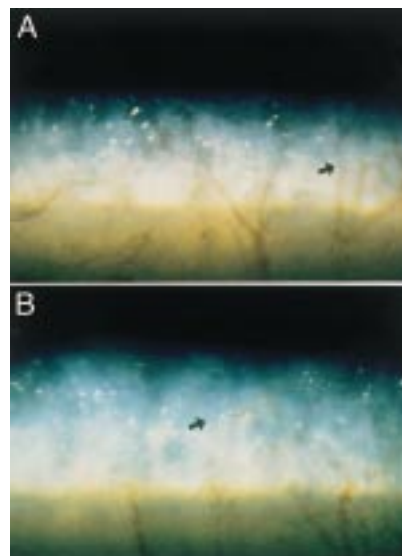


Figure 1 Specular microscopic findings. (A) Many crystalline deposits are observed at the limbus. (B) Specular microscopic findings re-examined after 1 year. The change of the locations and forms of crystalline deposit from the same vessels can be seen.

deposits were found in the patients with more advanced retinopathy. It is supposed that corneal deposits and fundus deposits are essentially the same and it is suggested that crystalline retinopathy is caused by systemic abnormality. Although the exact pathogenesis of crystalline deposits is still uncertain, it is possible that destroyed fibroblasts appear to glitter or fibroblasts with crystalline-like deposits look glittering during breakdown. Further biochemical or cellular biological studies are needed to clarify these possibilities.

YUKO WADA

Department of Ophthalmology, Tohoku University
School of Medicine, Sendai Japan

MITSURU NAKAZAWA

Department of Ophthalmology, Hirosaki University
School of Medicine, Hirosaki, Aomori, Japan

TOSHIKI ABE

TAKASHI SHIONO

MAKOTO TAMAI

Department of Ophthalmology, Tohoku University
School of Medicine, Sendai Japan

Correspondence to: Yuko Wada, MD, Department of Ophthalmology, Tohoku University School of Medicine, 1-1 Seiryomachi, Aoba-ku, Sendai, 980-8754, Japan.

Accepted for publication 19 April 1999

- 1 Bietti G. Ueber familiares Vorkommen von Retinitis punctata albescens (Verbunden mit "Dystrophia marginalis crystallinea cornea"). Glitzen des Glaskorpers und andern degenerativen Augenveränderungen *Klin Monatsbl Augenheilkd* 1937;99:737-56.
- 2 Morimoto M, Shiragami F, et al. A case of crystalline retinopathy with crystalline deposits in the cornea. *Nippon Ganka Gakkai Zasshi* 1990;94:321-7.
- 3 Takikawa C, Miyake Y, Yagasaki K. Re-evaluation of crystalline retinopathy based on corneal findings. *Folia Ophthalmol Jpn* 1992;43:969-78.