

Cyclodiode laser therapy for painful, blind glaucomatous eyes

Keith R G Martin, David C Broadway

Abstract

Aims—To determine the ability of cyclodiode laser treatment to relieve discomfort in painful blind glaucomatous eyes.

Methods—30 eyes underwent cyclodiode to reduce intraocular pressure (IOP) and relieve pain. Patients graded their pre-cyclodiode and post-cyclodiode pain.

Results—After a minimum follow up of 6 months, a single cyclodiode treatment lowered mean IOP from 51 mm Hg (95% CI plus or minus 3.7 mm Hg) to 26 mm Hg (95% CI plus or minus 5.8 mm Hg) providing pain relief in 73.3% (22/30). After retreatment of six eyes, mean IOP was reduced to 22 (95% CI plus or minus 5.3) mm Hg and pain relief was obtained in 96.7% (29/30). For eyes achieving pain relief after one treatment, IOP was reduced by >30% in 81.0% (17/21). For eyes not achieving pain relief after one treatment, IOP was reduced by >30% in only 22.2% (2/9) ($p=0.0042$, Fisher's exact test).

Conclusion—Cyclodiode was highly successful in providing pain relief in painful blind hypertensive glaucomatous eyes. The best predictor of successful pain relief was IOP reduction of > 30% from baseline.

(Br J Ophthalmol 2001;85:474–476)

Cyclodiode laser treatment is being used increasingly to treat refractory glaucoma.^{1–8} In patients with blind and painful eyes, perhaps the most important outcome measure is whether or not treatment renders the affected eye comfortable, yet few published studies have considered symptom relief as an outcome. The aim of the current study was to establish the ability of cyclodiode to improve comfort in patients with painful, blind eyes due to glaucoma. Our secondary aim was to establish which treatment related variables correlated with the achievement of a comfortable eye.

Materials and methods

The study design was prospective, longitudinal, and observational. Thirty patients (30 eyes) meeting the inclusion criteria (visual acuity worse than hand movements at 1 metre, significant ocular discomfort, IOP >30 mm Hg, and no previous cyclodestructive procedures) were recruited between May 1998 and May 1999. Mean age was 73 years (SD 12.2 years). Eighteen patients had neovascular glaucoma, four had aphakic glaucoma, two had raised IOP following vitreoretinal surgery, and six had multiple pathologies. Informed consent was obtained in all cases. The aim of cyclodiode

treatment was to achieve adequate IOP reduction and a comfortable eye. Minimum follow up was 6 months (mean 10.8 months, range 6–22 months). All patients were assessed 2–4 weeks after treatment. The frequency of further follow up was at the discretion of the clinician with a mean of 2.6 (1.13) visits between 1 month and 1 year.

Patients graded their ocular discomfort before and at each assessment after cyclodiode treatment. Pain was graded as “severe” (grade 3), “moderate” (grade 2), “mild” (grade 1), or “none” (grade 0). Topical and systemic treatment, visual acuity and IOP were recorded at each pretreatment and post-treatment visit.

Cyclodiode treatment was performed under peribulbar anaesthesia with 2% lignocaine using the OcuLight SLX semiconductor diode 810 nm laser (Iris Medical Instruments Inc, Mountain View, CA, USA) and the contact G-probe (Iris Medical Instruments). Treatment was delivered through a 600 μ m quartz fibre protruding 0.7 mm from the G-probe contact surface to indent the conjunctiva and sclera, thus improving energy delivery to the ciliary body. Transillumination was used to identify the ciliary body and 40 laser “shots” were applied, 10 in each quadrant of the ciliary body sparing the 3 and 9 o'clock positions. For first treatment sessions, the power of each shot was 1500 mW for 1500 ms (90 J per session). For retreatments, the duration of each shot was increased to 2000 ms (120 J per session). The criteria for retreatment were persistent pain and IOP >30 mm Hg. Topical dexamethasone 0.1% was administered four times daily for 1 month after each cyclodiode treatment.

Results

CHANGE IN INTRAOCULAR PRESSURE (FIG 1)

The mean IOP recorded on the day of cyclodiode treatment was 51 mm Hg (95% CI plus or minus 3.7 mm Hg, range 34–72 mm Hg). After a single cyclodiode treatment, the mean IOP fell to 26 mm Hg (95% CI plus or minus 5.8 mm Hg, range 1–66 mm Hg). At final follow up, after one ($n=23$), two ($n=6$), or three ($n=1$) cyclodiode treatments, the mean IOP was 22 mm Hg (95% CI plus or minus 5.3 mm Hg, range 1–66 mm Hg). Twenty two of 30 eyes (73.3%) had an IOP reduction of greater than 30% with one treatment, and 27 of 30 eyes achieved a 30% reduction when retreatments were included.

PRE-CYCLODIODE AND POST-CYCLODIODE ANTIGLAUCOMATOUS THERAPY

Before cyclodiode treatment, five patients (16.7%) were receiving oral acetazolamide treatment compared with two patients (6.7%)

Department of
Ophthalmology,
Norfolk and Norwich
Healthcare NHS Trust,
West Norwich
Hospital, Norwich, UK
K R G Martin
D C Broadway

Correspondence to:
David C Broadway,
Department of
Ophthalmology, West
Norwich Hospital,
Bowthorpe Road, Norwich,
NR2 3TU, UK
david.broadway@
norfolk.norwich.thenhs.com

Accepted for publication
24 October 2000

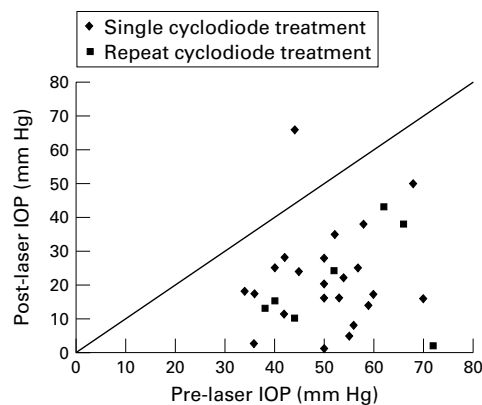


Figure 1 Pretreatment and post-treatment intraocular pressures following single and repeat cyclodiode therapy.

at final follow up. Twenty two eyes (73.3%) were being treated with topical antiglaucomatous drugs before cyclodiode treatment compared with 12 eyes (40.0%) at final follow up.

PRE-CYCLODIODE AND POST-CYCLODIODE PAIN SCORES

After a single cyclodiode, pain was reduced in 22 of 30 eyes (73.3%) and abolished in 21 of 30 eyes (70.0%). After retreatments, pain was reduced in 29 of 30 eyes (96.7%) and abolished in 26 of 30 eyes (86.7%) (Table 1). The only factor identified by multiple linear regression analysis (SPSS 6.1 for Windows, SPSS Inc, Chicago, IL, USA) to be associated with pain relief after a single treatment was IOP reduction > 30% from baseline ($p < 0.001$). Factors unassociated with successful pain relief included patient age, sex, ocular diagnosis, previous surgical/medical treatment, and pre-cyclodiode IOP and pain levels.

COMPLICATIONS

Complications occurred in six eyes. Three patients (10.0%) developed persistent hypotony (IOP < 5 mm Hg), one hypotonous eye remained painful at final follow up but none developed phthisis. Post-treatment uveitis occurred in two eyes and transient hyphaema in one eye.

Discussion

We are aware of few studies on symptom control following cyclodiode treatment, although Walland *et al* reported pain control in six of eight painful, blind glaucomatous eyes using a treatment protocol similar to ours.⁷ We have demonstrated that cyclodiode treatment is very effective at relieving pain in patients with blind, painful, glaucomatous eyes. The treatment was well tolerated and only one of 30 eyes (3.3%) remained painful at final follow up. Multiple

linear regression analysis identified IOP reduction from baseline as the only variable correlating significantly with reduction in pain ($p < 0.001$). The single most important factor in achieving complete pain relief with one treatment was a reduction in IOP of >30% from baseline. For eyes achieving complete pain relief after one treatment, IOP was reduced by >30% in 81.0% (17/21). For eyes not achieving pain relief after one treatment, IOP was reduced by >30% in only 22.2% (2/9) ($p = 0.0042$, Fisher's exact test).

We used a very simple pain grading system, similar to the system used by Harmon,⁹ with patients classifying their pain as "severe" (grade 3), "moderate" (grade 2), "mild" (grade 1), or "none" (grade 0) at each assessment. This system was preferred to a "Visual analogue scale" system^{10 11} because we felt it was easier for patients to understand and was likely to be more repeatable.

We used a treatment protocol similar to that described by Bloom *et al*,¹ delivering 90 J to the ciliary body in the first treatment session and 120 J on retreatment. Spencer and Vernon⁵ have recently reported good results using 14 applications of 2 W for 2 seconds (56 J per session) over 270 degrees; two of 58 eyes (3.4%) developed hypotony (final IOP < 5 mm Hg) compared with three of 30 eyes (10.0%) in our study and three of 210 (1.4%) in the study of Bloom.¹ Our protocol involved a relatively high energy delivery to the ciliary body, which may explain the higher hypotony rate. However, only seven of our 30 (23.3%) patients required retreatment compared with 45%,⁵ 49%,¹ and 65%¹² in other published series. Our study included only patients with already "blind" eyes; the glaucoma in these eyes might therefore be expected to be more severe than other study populations. The pre-treatment mean IOP of 51 mm Hg in our series was also markedly higher than in the series of Bloom (34.1 mm Hg),¹ Hawkins (32.5%),¹³ and Spencer (33.0 mm Hg),⁵ consistent with more severe disease in patients with painful, blind eyes.

Other potential complications of cyclodiode treatment include malignant glaucoma,¹⁴ neurotrophic corneal defects,¹⁵ scleral perforation,¹⁶ and a theoretical risk of sympathetic ophthalmia. No such complications occurred in the present series.

Conclusions

Cyclodiode laser treatment very effectively eliminated discomfort in previously painful, blind, glaucomatous eyes. The best predictor of successful pain relief was reduction in IOP of > 30% from baseline. "Ideal" treatment parameters remain uncertain and protocols using slightly less total energy delivery to the ciliary body might have a lower risk of hypotony, although a corresponding increase in the need for retreatments might be expected.

Funding: Norwich Glaucoma Research Fund.
Conflicting interests: none.

Table 1 Pre-cyclodiode and post-cyclodiode pain assessment

	Pre-cyclodiode		After single cyclodiode		After repeat cyclodiode (if necessary)	
	No	%	No	%	No	%
No pain	0	0.0	21	70.0	26	86.7
Mild pain	0	0.0	1	3.3	2	6.7
Moderate pain	24	80.0	7	23.3	2	6.7
Severe pain	6	20.0	1	3.3	0	0.0

- 1 Bloom PA, Tsai JC, Sharma K, *et al.* "Cyclodiode". Transscleral diode laser cyclophotocoagulation in the treatment of advanced refractory glaucoma. *Ophthalmology* 1997;104:1508-19
- 2 Gupta N, Weinreb RN. Diode laser transscleral cyclophotocoagulation. *J Glaucoma* 1997;6:426-9.
- 3 Kosoko O, Gaasterland DE, Pollack IP, *et al.* Long-term outcome of initial ciliary ablation with contact diode laser transscleral cyclophotocoagulation for severe glaucoma. The Diode Laser Ciliary Ablation Study Group. *Ophthalmology* 1996;103:1294-302.
- 4 Montanari P, Italia A, Marangoni P, *et al.* Diode laser transscleral cyclophotocoagulation in refractory glaucoma treatment. *Acta Ophthalmol Scand Suppl* 1997;224:38.
- 5 Spencer AF, Vernon SA. "Cyclodiode": results of a standard protocol. *Br J Ophthalmol* 1999;83:311-6.
- 6 Threlkeld AB, Johnson MH. Contact transscleral diode cyclophotocoagulation for refractory glaucoma. *J Glaucoma* 1999;8:3-7.
- 7 Walland MJ. Diode laser cyclophotocoagulation: dose-standardized therapy in end-stage glaucoma. *Aust NZ J Ophthalmol* 1998;26:135-9.
- 8 Yap-Veloso MI, Simmons RB, Echelman DA, *et al.* Intraocular pressure control after contact transscleral diode cyclophotocoagulation in eyes with intractable glaucoma. *J Glaucoma* 1998;7:319-28.
- 9 Harmon GK. Ultrasound therapy for treatment of glaucoma (cyclosclerosthermy). In: El Sayyad F, Spaeth GL, Shields MB, Hitchings RA, eds. *The refractory glaucomas*. 1st ed. New York, Tokyo: Igaku-Shoin, 1995:277-94.
- 10 Yarnitsky D, Sprecher E, Zaslansky R, *et al.* Multiple session experimental pain measurement. *Pain* 1996;67:327-33.
- 11 Todd KH, Funk KG, Funk JP, *et al.* Clinical significance of reported changes in pain severity. *Ann Emerg Med* 1996;27:485-9.
- 12 Brancato R, Carassa RG, Bettin P, *et al.* Contact transscleral cyclophotocoagulation with diode laser in refractory glaucoma. *Eur J Ophthalmol* 1995;5:32-9.
- 13 Hawkins TA, Stewart WC. One-year results of semiconductor transscleral cyclophotocoagulation in patients with glaucoma. *Arch Ophthalmol* 1993;111:488-91.
- 14 Azuara-Blanco A, Dua HS. Malignant glaucoma after diode laser cyclophotocoagulation. *Am J Ophthalmol* 1999;127:467-9.
- 15 Johnson SM. Neurotrophic corneal defects after diode laser cycloablation. *Am J Ophthalmol* 1998;126:725-7.
- 16 Sabri K, Vernon SA. Scleral perforation following transscleral cyclodiode. *Br J Ophthalmol* 1999;83:502-3.