

## CASE REPORT

# Tear of the acetabular labrum in an elite athlete

D Binningsley

*Br J Sports Med* 2003;**37**:84–88

The case is reported of a professional footballer with a tear of the acetabular labrum. The clinical findings, treatment, and rehabilitation are described as well as a discussion of the difficulties of diagnosis.

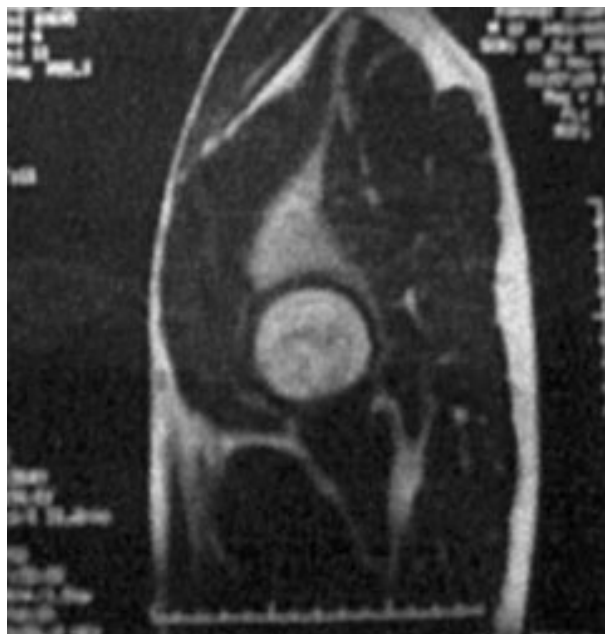A torn labrum of the hip joint is a rare and often difficult condition to diagnose. This case study highlights the clinical findings, treatment, and rehabilitation for a young professional footballer.

Emphasis is given to the process involved in diagnosis and subsequent treatment, highlighting possible differential diagnoses within the pelvic complex.

### CASE REPORT

An 18 year old central midfield/defender who is an England U18 international had recently made his first team debut. He is predominantly a right footed player. Earlier in the season he had experienced two episodes of what appeared clinically to be a proximal musculotendinous junction lesion of the sartorius muscle; both resolved within 14 days.

He then experienced further right groin pain after playing a full game. Examination showed limitation of internal rotation and abduction. The remaining movements were full and pain-free, presenting a Cyriax capsular pattern<sup>1</sup>—that is, limitation of flexion, abduction, and internal rotation, slight limitation of extension, with little or no limitation of lateral rotation.



**Figure 1** Magnetic resonance imaging scan. Lateral view of the hip.

Resisted tests through full range produced pain on internal rotation and flexion, which subsided with increasing degree of flexion.

As this was the third episode, magnetic resonance imaging was arranged (fig 1). The results showed a minor muscle tear close to the proximal enthesis of the tensor fascia latae and the anterior margin of the gluteus minimus, with some associated marrow oedema in the iliac crest. There was no evidence of other pathology.

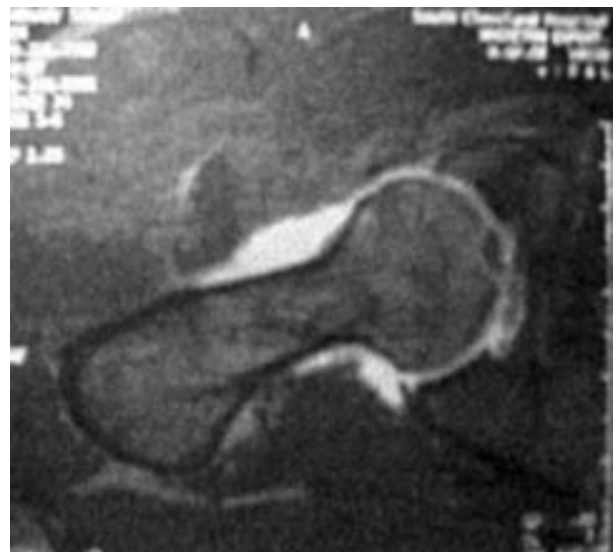The muscle lesion was treated for 10 days with good results. The player was able to jog without pain and began light ball rehabilitation. Pain still persisted with either active or passive internal rotation of 20°, full abduction, full flexion, and active straight leg raise. The pain was not affecting rehabilitation, and the player was able to return to full training after 18 days.

After a week of training, he still had pain on internal rotation. The consultant radiologist advised the use of a magnetic resonance arthrogram. The gadolinium enhanced scan showed no abnormality (fig 2). After discussion with the player, his parents, and the medical staff, it was agreed that arthroscopy of the hip should be considered.

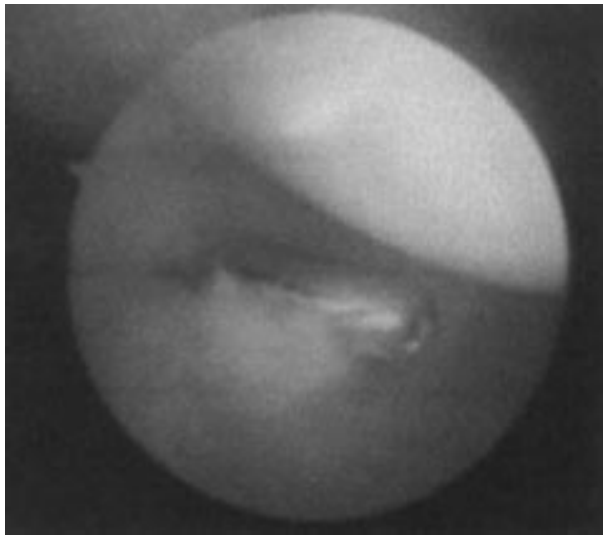
At the initial consultation, the surgeon considered that a labral tear was the most likely diagnosis. An arthroscopy was performed as a day case identifying a tear in the anterior portion of the labrum; this could then be trimmed (fig 3).

The player was mobilised on crutches, non-weight bearing on the right leg, for five days, after which a rehabilitation programme for the upper limb and abdomen was started. The two portal wounds had healed by 10 days, which allowed active exercises in the pool.

The surgeon advised a four to six week period of restricted activity, because of the joint distraction involved. During this



**Figure 2** Magnetic resonance arthrogram showing cross section of the femoral head and acetabulum.



**Figure 3** Arthroscopy identifying a tear in the anterior portion of the labrum.

period, cardiovascular work was maintained using cycling without resistance, and upper limb ergometer work and a general conditioning programme were undertaken. Training in proprioception began after five days, with a programme twice a week, initially using the Biodex Stability platform, before progressing to more functional work.

Gentle running began after five weeks, and then a speed of 11 km/h in week 6 increasing to 15 km/h in week 7. The player spent a total of four weeks in functional rehabilitation, which included speed/endurance, agility, plyometric, and advanced proprioceptive sessions.

Isokinetic work was introduced at week 5 using the Biodex System 3 working with high repetition, high speed ( $>180^\circ/\text{s}$ ) protocols over a constant 30 second duration, involving hip flexion/extension, abduction/adduction, and knee flexion/extension. Speeds were gradually lowered as the player achieved 90% of peak torque when compared with the uninvolved leg. Week 7 saw the bilateral equalisation of total work and peak torque. Final results showed that the right hip flexors were 18% stronger at  $120^\circ/\text{s}$ , producing 135.8 N.m at peak torque. Other speeds produced non-significant differences.

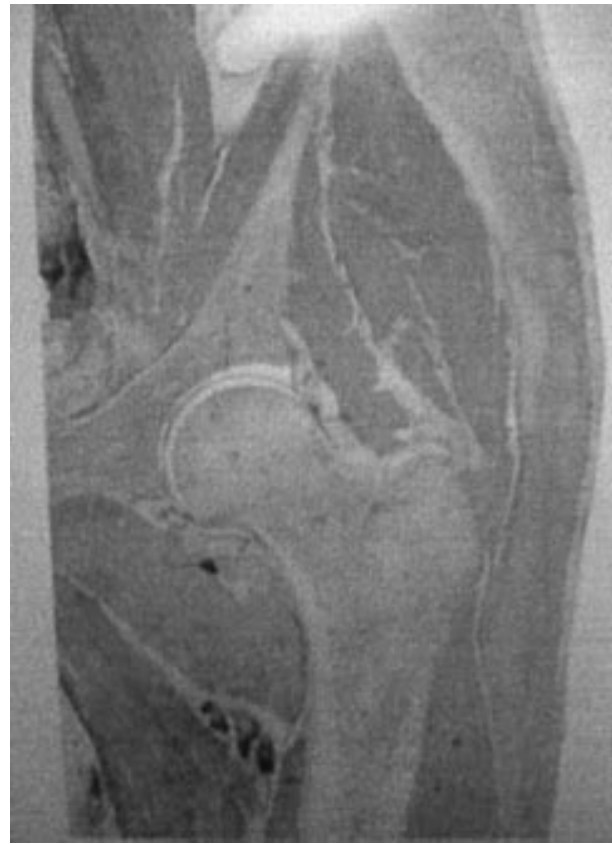Ball work was introduced at week 5, primarily as part of the proprioceptive work, using a size 3 soccer ball. Drills involving a full size ball were gradually introduced from week 6. Full training was started at week 10. After two further weeks, the player successfully completed 90 minutes of competitive soccer.

## DISCUSSION AND REVIEW OF LITERATURE

### Anatomy

The labrum is a fibrocartilaginous rim which attaches to the acetabulum (fig 4). It deepens the cavity and at the same time protects the bone and reduces any inequalities in its surface. It is triangular in section, being thicker above and posteriorly than below and anteriorly. A double layered synovial membrane surrounds the joint, the external membrane communicating with the capsule, while the internal one helps to narrow the acetabulum.

The fibrocartilage is a dense collagenous tissue, usually triangular in shape,<sup>3</sup> consisting of alternating layers of hyaline cartilage matrix and thick layers of collagen fibres, all orientated in the direction of functional stresses. The integrity of cartilage is maintained by chondrocytes, which are embedded in the extracellular matrix. Cartilage in the superior



**Figure 4** Coronal section of left hip joint.<sup>2</sup> (Reproduced with kind permission of the publisher Mosby.)

region is considerably thicker, with a higher glycosaminoglycan content and lower water and collagen content than in its periphery.<sup>4</sup> Aydingoz and Ozturk<sup>3</sup> showed a difference of about 15% in labral shape, compared with the opposite side, even in asymptomatic people.

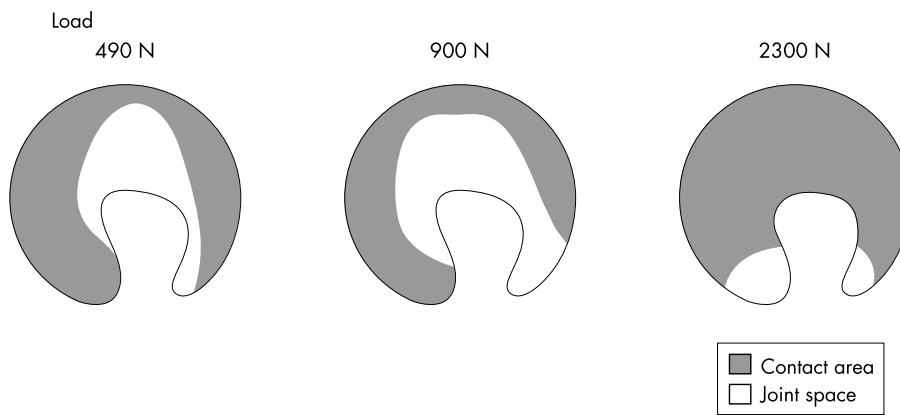
The vascularity is seen as an influential factor in labral tears. A fresh cadaveric study showed that the labrum has minimal vascular invasion. The most vascularised area, which is also the most common site of pathology, is a zone encompassing the anterior, posterior, and inferior parts of the labrum.<sup>5</sup> This is also the area that encounters the highest mechanical stresses (figs 5 and 6).

The importance of the labrum is shown by the contact stresses between the joint surfaces, which creates a "sealing effect".<sup>7</sup> After removal of the labrum, the frictional force between the femoral and acetabular surfaces is greatly increased, by up to 92%.<sup>7</sup> The centre of contact also shifts towards the acetabular rim, proving that the labrum provides both structural resistances to lateral movement of the femoral head and joint congruity.<sup>7,8</sup> It is important to note that labrum tears are uncommon.<sup>9</sup> Therefore it is also important to consider differential diagnoses in athletes with groin pain (table 1). There are many papers that very effectively describe groin pain in athletes<sup>10-12</sup> and offer a number of alternatives that must be considered before surgery.

### Radiological diagnostic techniques

There are a number of diagnostic techniques available for investigating the hip joint. These include computed tomography, magnetic resonance imaging, magnetic resonance arthrography, ultrasound, and radioisotope scans.

The sensitivity of these tests varies. Radiological studies have shown a very poor diagnostic yield for intra-articular pathology.<sup>13,14</sup> McCarthy *et al*<sup>15</sup> reviewed histories on 94



**Figure 5** Contact area of the acetabulum. (Reproduced with kind permission of Butterworth-Heinemann<sup>6</sup>.)

patients with intractable hip pain. In all cases the results of radiological investigation were equivocal, yet subsequent arthroscopy disclosed labrum tears in 55% of cases. They concluded that accurate diagnosis of remitting hip pain was accomplished only 4% of the time with imaging techniques. Abe *et al*<sup>16</sup> advocated the use of a modified technique, radial sequence magnetic resonance, which they found significantly increased the accuracy of diagnosis when taken every 15° perpendicular to the labrum.

Although the use of magnetic resonance arthrography, in which gadolinium is infiltrated into the joint, is a promising diagnostic technique for evaluating the acetabulum,<sup>17,18</sup> diagnosis of small detachments and degeneration of the labrum is less reliable.<sup>19</sup>

A radiological technique does not exist that can accurately and reliably diagnose labrum tears. Diagnosis is therefore usually based on sound clinical judgment. Many authors agree that clinical signs are most important, a negative rather than a positive radiological series being a better indicator for arthroscopy in undiagnosed hip pain.

### Physical diagnostic techniques

Symptoms of a torn labrum will usually present after a traumatic event, usually pivoting. McCarthy *et al*<sup>20</sup> noted that in the North American population labrum tears occurred with sudden twisting or pivoting motions, whereas in Asians tears were associated with hyperflexion or squatting movements.

An intra-articular lesion causing hip pain can present in a number of ways. Pain may exist in the anterior groin (labrum

tear correlates significantly with anterior inguinal pain), anterior thigh, and buttock around the greater trochanter.<sup>21</sup> Fitzgerald<sup>22</sup> found that 87% of subjects with labrum tears reported groin pain.

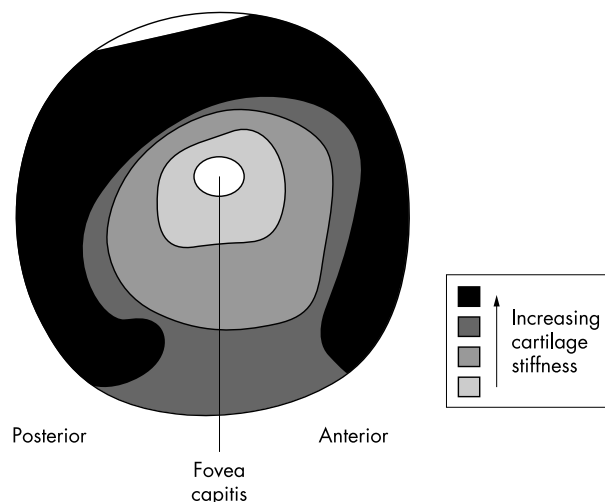
Symptoms may include clicking, transient locking, and “giving way”, and objective signs may include positive hip extension, resisted straight leg raise, and reduced range of movement. Fitzgerald<sup>22</sup> found that 80% of patients had an audible/palpable click. Other clinicians report pain with either active or passive internal rotation at 90° of hip flexion and axial compression.<sup>21</sup>

There are a number of tests that are positive in the presence of a labrum tear. The FABRE test (fig 7) encourages anterior translation of the femoral head on to the anterior surface of the labrum, impinging on any suspected tear. Also, by taking the hip into flexion, adduction with a small end range amplitude movement into internal rotation, the impingement test, will compress the anterior surface of the labrum.

### Arthroscopy

Hip arthroscopy has become increasingly popular over the last 10 years, because of developments in both technique and instrumentation, which allow minimally invasive diagnostic and therapeutic procedures to be performed. The first reported use of hip arthroscopy was in 1931.<sup>23</sup> The anatomical make up of the hip joint has been a limiting factor in its development. The great advantage of hip arthroscopy is that it allows visual inspection of all quadrants of the hip joint.

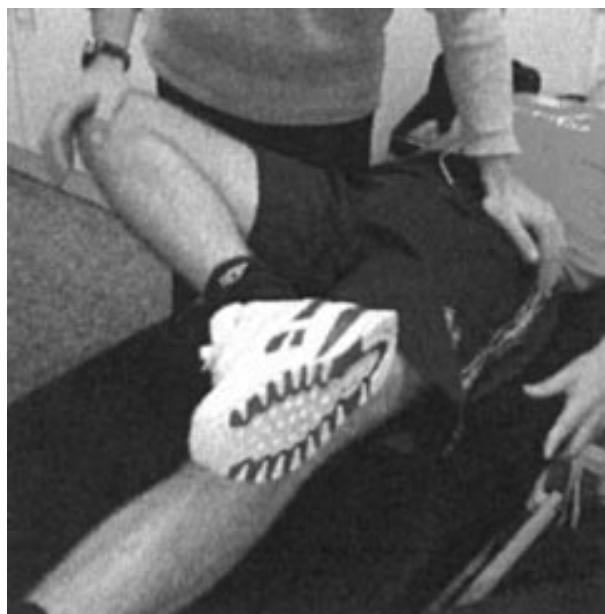Arthroscopic evaluation is considered when joint symptoms are unremitting, usually more than six months, and radiographic studies are unable to provide a diagnosis. In these situations, it is reported that arthroscopy facilitated a diagnosis in 40% of cases.<sup>24</sup> In a retrospective study of 267 subjects



**Figure 6** Distribution of cartilage stiffness over the femoral head. (Reproduced with kind permission of Butterworth-Heinemann<sup>6</sup>.)

**Table 1** Groin pain differential diagnosis

• Bursitis
• Myositis ossificans
• Stress fractures of the femoral head or neck
• <b>Slipped capital femoral epiphysis (SCFE)</b>
• Osteoarthritis of the femoral head
• Avascular necrosis of the femoral head
• <b>Acetabular labrum lesion</b>
• Osteitis pubis
• <b>Hernia</b>
• <b>Osteoporosis</b>
• Meralgia paraesthetica
• Muscle lesions
• Gynaecological problems
• Urological problems
• Referred pain



**Figure 7** The FABRE test.

with undiagnosed hip pain, 13.9% were found to have labrum tears under arthroscopy. After labrectomy, 78% were improved at one year follow up.<sup>25</sup>

The actual operating technique is beyond the scope of this article, but it is worth noting the forces required to distract the hip joint during surgery. The actual force required to distract the femoral head from the acetabulum varies considerably between patients, ranging from 25 lb (about 112 N) to 200 lb (about 900 N). Most cases can be performed with 50 lb (225 N) or less of distraction force. It is estimated that as much as half of the total resistance to hip distraction in non-anaesthetised patients is related to the negative pressure and resultant vacuum effect.<sup>26</sup> The average time for the procedure is 30–40 minutes depending on the findings.

Owing to the complexity of the operation and possible diversity of diagnosis, surgeons often advise a period of conservative treatment before surgical intervention is considered. Poor vascularity means that conservative treatments will normally fail to improve symptoms if the diagnosis of a labrum tear is accurate. Therefore it can be concluded that, even in recreational athletes who are experiencing symptoms of a torn labrum, surgery is the only effective management available.

Few complications have been documented after hip arthroscopy, although many vital neurological and vascular structures are at risk during the procedure. The rate of complications has been estimated at 1.6%, none of which were major or long term. They include transient palsy of sciatic and femoral nerves, perineal injury, bleeding from the portal wounds, trochanteric bursa, and intra-articular breakage of instruments.<sup>20–27</sup> Infection rates are low, as in other joint arthroscopies, because of the large volumes of fluid used during surgery. Ferguson *et al*<sup>7</sup> believes that labrum damage and early arthrosis may compromise the sealing effect of the joint, as discussed above.

### Pathology

The incidence of labrum tear is poorly reported; lesions most commonly occur on the articular edge of the tissue. The lesion may contribute to, or can occur in association with, articular cartilage lesions of the femoral head or acetabulum.

A cadaveric study of 55 elderly hips (average age 78 years) showed that 96% had labrum tears, of which 74% were located in the anterosuperior quadrant. The authors concluded that an acetabular tear appears to be an acquired condition that is

### Take home message

- Lesions to the acetabular labrum are rare and difficult to diagnose
- Arthroscopy is a safe and effective treatment
- Expected return to full elite level competition is 12 weeks

highly prevalent in aging adult hips.<sup>28</sup> As with damage to the knee meniscus, labrum tears, especially those that have existed for a number of years, can contribute to the progression of osteoarthritis.

### Conclusion

In the mature adult the hip joint is a rare site of injury. The incidence of lesions to the acetabular labrum has not been reported, but its occurrence in athletes is becoming more common as technology to identify such lesions becomes more advanced. A past history of vague recurrent groin/thigh injury should alert the clinician to the possibility of a labrum tear.

The awareness of such a diagnosis is important even for those clinicians not dealing directly with athletes, as lesions are very common in the elderly. In the future, more efficient imaging and diagnosis of hip pathologies, together with the availability of hip arthroscopy on a wider scale, may reduce the need for major arthroplastic surgery, especially in the older population.

Further research is needed to identify possible biomechanical or physiological predisposing factors that may result in such injury.

### Author's affiliation

**D Binningsley**, Academy Chartered Physiotherapist, Middlesbrough Football Club, Training Headquarters, Rockcliffe Park, Hurworth Place, Nr Darlington DL2 2DH, UK; david@binningsley.valiant.co.uk

Accepted 13 May 2002

### REFERENCES

- 1 **Cyriax JH**, Cyriax PJ. *Cyriax's illustrated manual of orthopaedic medicine*. 2nd ed. Oxford: Butterworth-Heinemann, 1996
- 2 **McMinn RHM**, Hutchings RT, Logan BM. *Foot and ankle anatomy*. 2nd ed. London: Mosby-Wolfe, 1996:20.
- 3 **Aydingoz U**, Ozturk. MR imaging of the acetabular labrum: a comparative study of both hips in 180 asymptomatic volunteers. *Eur Radiol* 2001;**11**:567–74.
- 4 **Venn MF**. Chemical composition of human femoral and head cartilage: influence of topographical position and fibrillation. *Ann Rheum Dis* 1979;**38**:57–62.
- 5 **Shapiro GS**, Kelly BT, Buly R, *et al*. Vascularity of the hip labrum: an anatomical study. *American Academy Of Orthopaedic Surgeons Conference 2001*. San Francisco, CA: American Academy of Orthopaedic Surgeons On-Line.
- 6 **Palastanga N**, Field D, Soames R. *Anatomy and human movement: structure and function*. 2nd ed. London: Butterworth-Heinemann, 1994.
- 7 **Ferguson SJ**, Bryant JT, Ganz R, *et al*. The influence of the acetabular labrum on hip joint cartilage consolidation: a poroelastic finite element model. *J Biomech* 2000;**33**:953–60.
- 8 **Konrath GA**, Hamel AJ, Olson SA, *et al*. The role of the acetabular labrum and the transverse acetabular ligament in load transmission in the hip. *J Bone Joint Surg* 1998;**80**:1781–88.
- 9 **Bonnomet F**, Llefeyre Y, Clavert P, *et al*. Arthroscopic treatment of acetabular labrum lesions: a series of 12 patients with a 4-year follow-up. *Rev Chir Orthop Reparatrice Appar Mot* 2000;**86**:787–93.
- 10 **Ruane JJ**, Rossi TA. When groin pain is more than "just a strain". Navigating a broad differential. *Physician and Sports Medicine* 1998;**26**:78–103.
- 11 **Swain R**, Snodgrass S. Managing groin pain. *Physician and Sports Medicine* 1995;**23**:55–66.
- 12 **Hasselmann C T**, Best T M, Garrett W E Jr. when groin pain signals an adductor strain. *Physician and Sports Medicine* 1995;**23**:53–60.
- 13 **Edwards DJ**, Lomas D, Villar RN. Diagnosis of the painful hip by MRI and arthroscopy. *J Bone Joint Surg* 1995;**77**:374–6.
- 14 **McCarthy JC**, Lee JA. Current techniques in hip arthroscopy. *Medscape* 2000.
- 15 **McCarthy JC**, Day B, Busconi B. Hip arthroscopy: applications and technique. *J Am Acad Orthop Surg* 1995;**73**:170–1.



- 16 **Abe I**, Harada Y, Tsuchiya A, *et al.* Lesions of the acetabular labrum: diagnostic accuracy of MRI versus arthroscopy. *American Academy Of Orthopaedic Surgeons Conference Notes 1999*. Anaheim, CA: American Academy of Orthopaedic Surgeons On-Line.
- 17 **Stiris MG**. MR arthrography of the hip joint in patients with suspected rupture of labrum acetabulare. *Tidsskr Nor Laegeforen* 2001;**121**:698–700.
- 18 **Czerny C**, Kramer J, Neuhold A, *et al.* MR imaging and MR arthrography of the acetabular labrum: comparison with surgical findings [German abstract]. *Rofo Fortschr Geb Rontgenstr* 2001;**173**:702–7.
- 19 **Plotz GM**, Brossmann J, Schunke M, *et al.* MR arthrography of the acetabular labrum. Macroscopic and histological correlation in 20 cadavers. *J Bone Joint Surg* 2000;**82**:426–32.
- 20 **McCarthy JC**, Wardell S, Mason J, *et al.* Injuries to the acetabular labrum: classification, outcome, and relationship to degenerative arthritis. *Program and Abstracts of the American Academy of Orthopaedic Surgeons Annual Meeting 2000*. Orlando, FL: American Academy of Orthopaedic Surgeons On-Line.
- 21 **Hase T**, Ueo T. Acetabular labral tear: arthroscopic diagnosis and treatment. *Arthroscopy* 1999;**15**:138–41.
- 22 **Fitzgerald RH Jr.** Acetabular labral tears: diagnosis and treatment. *Clin Orthop* 1995;**311**:60–8.
- 23 **Burman M**. Arthroscopy or the direct visualisation of joints. *J Bone Joint Surg* 1931;**4**:669–95.
- 24 **Villar RN**. Hip arthroscopy. *Br J Hosp Med* 1992;**4**:763–6.
- 25 **Conn KS**, Villar RN. Labrum lesions from the viewpoint of arthroscopic hip surgery. *Orthopaedics* 1998;**27**:699–703.
- 26 **Eriksson E**, Arvidsson I, Arvidsson H. Diagnostic and operative arthroscopy of the hip. *Orthopaedics* 1986;**10**:392–9.
- 27 **Griffin DR**, Villar RN. Complications of arthroscopy of the hip. *J Bone Joint Surg* 1999;**81**:604–6.
- 28 **Seldes RM**, Tan V, Hunt J, *et al.* Anatomy, histological features and vascularity of the adult acetabular labrum. *Clin Orthop* 2001;**382**:232–40.

## What's in the next issue

### Future content

See which articles have just been accepted for publication and preview the table of contents for the next issue a month before it is published

[www.bjsportmed.com](http://www.bjsportmed.com)