

ORIGINAL ARTICLE

Surgical repair of complete proximal hamstring tendon ruptures in water skiers and bull riders: a report of four cases and review of the literature

J Chakravarthy, N Ramisetty, A Pimpalnerkar, N Mohtadi

Br J Sports Med 2005;39:569–572. doi: 10.1136/bjsm.2004.015719

See end of article for authors' affiliations

Correspondence to: Jagannath Chakravarthy, Royal Centre for Defence Medicine, Selly Oak Hospital, Birmingham, UK; cs_jagan@yahoo.com

Accepted 23 November 2004

Objective: Hamstring strains are one of the most common muscle strains in athletes; however, complete rupture of the proximal hamstring origin is rare and results from significant trauma. The objective of this paper is to present our experience of management of complete ruptures where surgical repair resulted in good results in both acute and delayed cases.

Methods: Two water skiers and two bull riders sustained complete rupture of the proximal origin of the hamstring muscles. All underwent repair of the hamstring origin and sciatic nerve neurolysis. A post operative hamstring rehabilitation programme was instituted. Regular follow up was performed at 2, 3, 6, 9, and 12 months.

Results: At a minimum final follow up of 12 months all patients had regained functional knee flexion strength with no pain and a near normal range of knee flexion. All four individuals were able to return to their previous line of work and three were able to return to their pre-injury level of sport.

Conclusion: Complete rupture of the hamstring origin is a potentially devastating sports injury that has implications affecting the individual's activities of daily living as well as potential as a sportsperson. Surgical repair restores the distorted anatomy, allows early functional rehabilitation, and avoids the potential debilitating neurological problem of gluteal sciatica.

The hamstring muscle unit is a powerful knee flexor and hip extensor, spanning both the hip and knee joints. It is, therefore, prone to injury during sports. It is also one of the least stretched muscles in the body and is therefore easily injured during eccentric muscular contraction. Although hamstring strains are common muscle strains in athletes, complete rupture of proximal hamstring origin is a rare sports injury. The severity of the injury is often overlooked especially in the acute setting. Currently there is no consensus on optimum management, which varies from conservative treatment in a flexion splint to acute or delayed surgical repair.

METHODS

Our study group consisted of four patients presenting to the sports clinic having sustained injury to their hamstring muscles. Two suffered the injury while water skiing and two while bull riding. All gave a common history of a sudden tearing or popping sensation in their gluteal region. On examination all had bruising over the posterior aspect of the thigh (fig 1) and a palpable gap just distal to the ischial tuberosity. All had gross weakness in knee flexion and functional disability. MR scans confirmed the diagnosis in all cases (fig 2).

Surgical technique

The procedure was carried out under general anaesthesia with the patient prone. A posterior longitudinal incision was made starting from the gluteal crease extending 10 cm distal to the retracted hamstring origin. The posterior cutaneous nerve of the thigh was identified and protected. The sciatic nerve was identified starting distally from normal anatomy (fig 3). A careful neurolysis was then done. Care was taken to identify and protect the branches to the semi-membranosus. All three muscles and the tendon ends were carefully dissected (fig 4). The ischial tuberosity and the proximal

tendon stump were exposed. The tendon origin was then carefully approximated (fig 5) with the knee at a right angle. The repair was then carried out using No. 5 Ethibond suture (Ethicon, Somerville, NJ). Two Merselene (5 mm) tapes were passed through either end and were tied together using a simple box suture to create a de-tensioning device.

In two cases the tendon was found to have avulsed off the ischial tuberosity. In these cases the ischial tuberosity was cleared of soft tissue until we obtained a bleeding bone surface. The proximal end of the distal stump was fixed to the ischial tuberosity with a Corkscrew (Arthrex, Naples, FL). The Corkscrew is a titanium self-tapping compressing screw with two No. 2 non-absorbable braided polyester sutures.

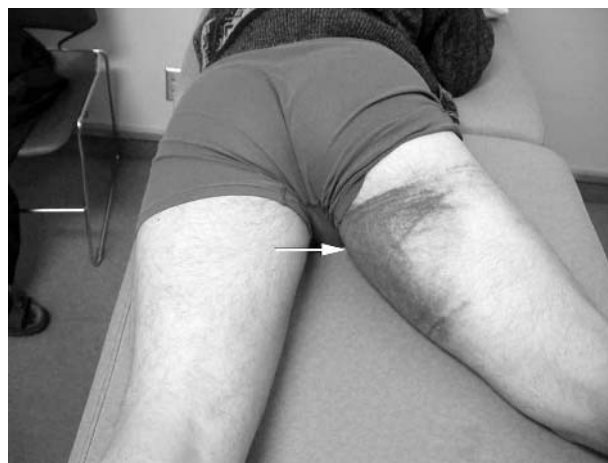

Figure 1 Haematoma over posterior aspect of the thigh (white arrow). (Photograph reproduced with permission)

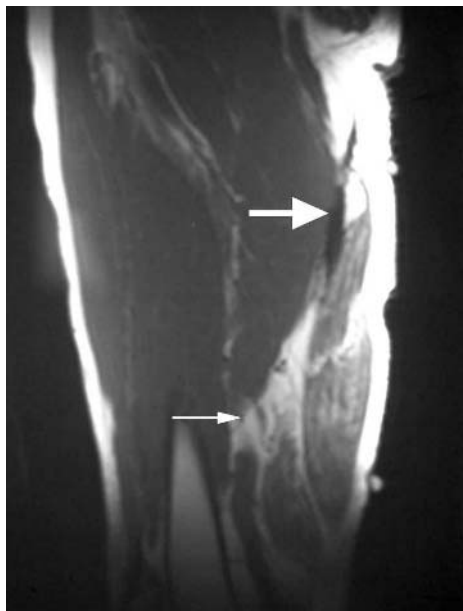


Figure 2 MR scan following ruptured proximal end of hamstring. Small arrow shows a haematoma and large arrow shows the ruptured muscular head of the hamstrings. (Photograph reproduced with permission)

Merselene tape was used as a de-tensioning device by passing the tape through drill holes in the ischium.

The repair was tested by allowing the knee to passively extend to 45°. Post operatively the limb was splinted at 90° for 2 weeks. A thermoplastic splint was made at that time and rehabilitation was carried out using the hamstring protocol. Each patient was followed up at 2, 3, 6, 9, and 12 months. The knee splint was adjusted at each follow up to improve the safe flexion-extension arc.

Hamstring rehabilitation

Hamstring rehabilitation consisted of the following:

- Initially isotonic knee flexion in prone from 90° to full flexion and passive extension up to pain tolerance
- Isotonic strengthening under loads
- Followed by iso-kinetic work and dynamic stretching

RESULTS

Four patients were diagnosed with proximal hamstring rupture. All were male. Two suffered the injury when being suddenly pulled while water skiing and two sustained the injury whilst bull riding. Two patients were referred from other units after a trial of non-operative treatment, keeping the knee in a flexion splint with a graduated rehabilitation programme. The duration of conservative treatment was 12 and 13 months, respectively. One patient was initially managed in our unit non-operatively but was offered surgery after 6 months. All these patients had significant deficit in knee flexion strength and thigh pain. Two of these patients suffered from sciatic neuralgia pre-operatively. One patient was surgically treated after 2 weeks. All patients were followed up for at least a year (range 12–24 months; average 14.6 months). All patients had regained functional strength with no pain and a near normal range of knee flexion and extension. In the three delayed repairs there was also complete recovery of the sciatica neuralgia. All four individuals were able to return to their previous line of work and three were able to return to their pre-injury level of sport.

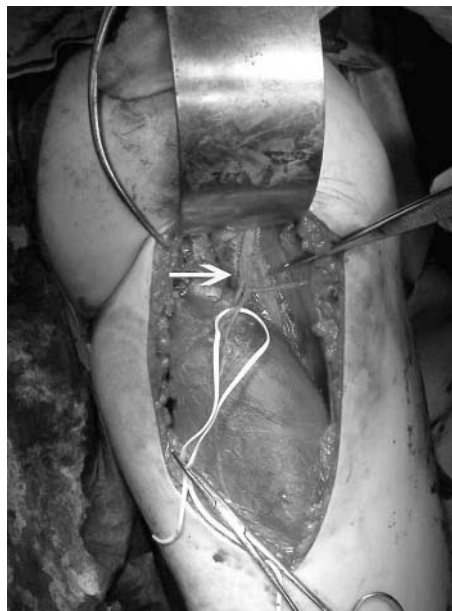


Figure 3 Sciatic nerve neurolysis. The white arrow shows the dissected sciatic nerve and its branches. (Photograph reproduced with permission)

Muscle strength and endurance were assessed at 12 months using a Cybex machine which revealed a mean side to side deficit of 10% and 15%, respectively.

DISCUSSION

Hamstring injuries are the most common muscle strains in athletes.^{1–4} Complete rupture of the ischial origin is, however, rare. Apophyseal avulsions in the adolescent population are well recognised with good results being obtained following acute surgical repair.⁵

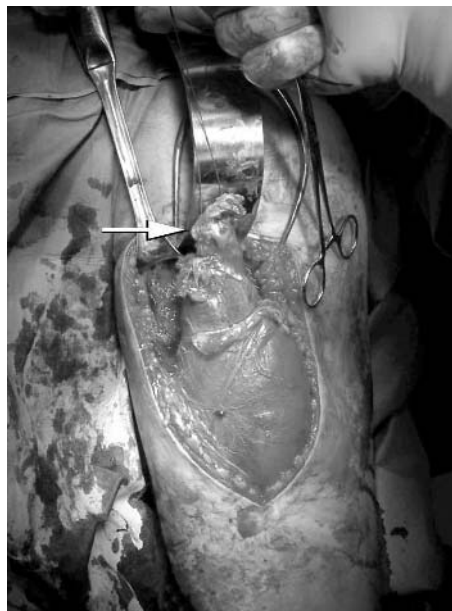


Figure 4 Dissection and mobilisation of the distal end of the ruptured muscle (white arrow). (Photograph reproduced with permission)

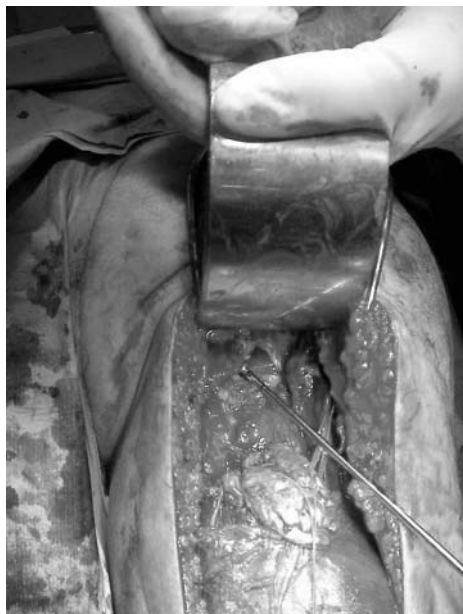

Figure 5 Anatomic repair of the hamstring origin. (Photograph reproduced with permission)

Mechanism of injury

Water skiers

The injury occurs as a result of violent eccentric contraction of the muscle as the individual is being pulled out of the water (Hurdler's position). The eccentric contraction occurs due to the forced flexion of the hip with the knee in extension as the motor boat pulls away. This is illustrated in fig 6.

Bull riders

The eccentric contraction occurs when the rider's foot gets caught in the steer's waist rope and when the rider is being flung around violently.

Diagnosis of this injury is usually made on a high index of clinical suspicion and careful clinical examination. MR imaging appears to be valuable in differentiating incomplete from complete injuries and in planning management.⁶

Literature review revealed very few reports describing complete hamstring ruptures and scanty information on the optimal method of management. Ishikawa *et al*⁷ reported on two such cases treated surgically, one operated within 5 days and the other at 2 months following injury, with both resulting in satisfactory outcomes. Blasier and Morawa⁸ reported good long term results at 7 years following acute surgical repair carried out within 48 h in a water skier. Sallay *et al*⁹ reported hamstring injuries in 12 water skiers, eight of whom described a similar mechanism of injury to ours. Orava and Kujala¹⁰ recommend acute surgical repair in complete hamstring origin ruptures. Cross *et al*² reported good results in nine cases where delayed repair was carried out at a mean of 36 months. In five cases the injury was related to water skiing in which the mechanism of injury was eccentric loading. Two cases from their series had pre-operative neurological symptoms similar to gluteal sciatica which was cured, as in our cases, following neurolysis of the sciatic nerve at the time of surgical repair of the hamstrings. The cause of this pain has so far not been defined. We postulate that it occurs either due to scarring around the sciatic nerve or because of traction neuritis on it or its branches as the detached hamstring muscles contract. The third possible cause could be the formation of a tight fibrotic band distal to the

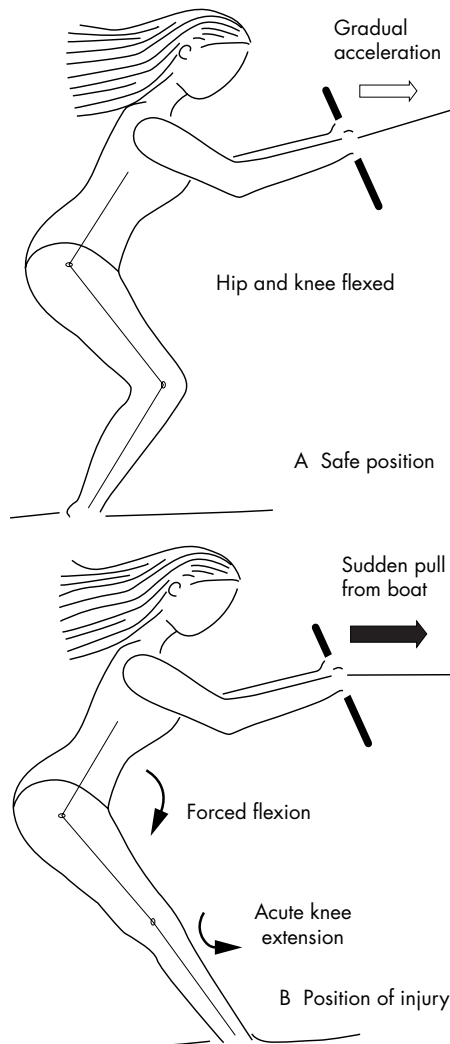


Figure 6 (A) Safe position whilst water skiing. Hip and knee are flexed when boat pulls forward. (B) The position predisposing to the injury. Hip is flexed while the knee is extended, causing eccentric contraction of the hamstrings when suddenly pulled by the boat.

ischial tuberosity compressing the sciatic nerve not unlike that seen in hamstring syndrome.¹¹ Whatever the cause, division of the fibrotic bands and surgical neurolysis of the nerve and its branches in addition to repair of the hamstrings seems to resolve this problem. Cross *et al*² used a combination of No. 5 Ethibond suture (Ethico) and Stay-Tec sutures (Zimmer, Warsaw, IN) for their repairs and recommended post-operative immobilisation for 8 weeks after which a rehabilitation programme should be commenced. In our patients, we used 5 mm Merselene tape as a de-tensioning construct which acts to protect the repair. In addition, we test the amount of extension we are able to gain intra-operatively so as to determine a safe ROM arc through which the knee can be mobilised early on in the rehabilitation programme. This allows us to commence physiotherapy at a much earlier time of 2 weeks, avoiding the drawbacks of prolonged immobilisation. This is very much in line with recent studies that have shown that only a short period of immobilisation is required to allow for the formation of granulation tissue after which mobilisation and strengthening is necessary to improve muscle strength and endurance and to prevent muscle atrophy.¹²

In their series, Cross *et al*² found that seven out of their nine cases were able to return to their pre-injury sport, albeit with

What is already known on this topic

Complete rupture of proximal hamstring origin is rare. Currently management varies from conservative treatment in a flexion splint to acute or delayed surgical repair.

less intensity. Three of our four patients were able to return to their pre-injury sports level and all patients returned to their previous levels of work.

CONCLUSION

Optimal treatment for complete rupture of the hamstring origin is still unclear. A high index of suspicion should be maintained and we recommend the use of MR imaging to differentiate complete from incomplete ruptures. Although delayed repair can give good results, we would recommend early surgery. Apart from the relative ease of surgical repair in the acute setting where anatomy is not distorted, early surgery would allow for early functional rehabilitation and also avoid the potential neurological symptoms of gluteal sciatica.

Authors' affiliations

J Chakravarthy, N Ramisetty, A Pimpalnerkar, Royal Centre for Defence Medicine, Selly Oak Hospital, Birmingham, UK
N Mohtadi, Sports Medicine Centre, University of Calgary, Alberta, Canada

Competing interests: none declared

Consent was obtained for the publication of figures in this article.

What this study adds

Although delayed repair of complete rupture of proximal hamstring origin can give good results, early surgery allows for early functional rehabilitation and also avoids the potential neurological symptoms of gluteal sciatica.

REFERENCES

- 1 **Brubaker CE**, James SL. Injuries to runners. *J Sports Med* 1974;**2**:189–98.
- 2 **Cross MJ**, Vandersluis R, Wood D, *et al*. Surgical repair of chronic complete hamstring tendon ruptures in the adult patient. *Am J Sports Med* 1998;**26**:785–8.
- 3 **Ekstrand J**, Gillquist J. Soccer injuries and their mechanisms: a prospective study. *Med Sci Sports Exerc* 1983;**15**:267–70.
- 4 **Garrett WE Jr**. Muscle strain injuries. *Am J Sports Med* 1996;**24**:S2–8.
- 5 **Wootton JR**, Cross MJ, Holt KWG. Avulsion of the ischial apophysis. The case for open reduction and internal fixation. *J Bone Joint Surg* 1990;**72**:625–7.
- 6 **Verrall GM**, Slavotinek JP, Barnes PG, *et al*. Diagnostic and prognostic value of clinical findings in 83 athletes with posterior thigh injury: comparison of clinical findings with magnetic resonance imaging documentation of hamstring muscle strain. *Am J Sports Med* 2003;**31**:969–73.
- 7 **Ishikawa K**, Kai K, Mizuta H. Avulsion of the hamstring muscles from the ischial tuberosity. *Clin Orthop* 1988;**232**:153–5.
- 8 **Blasier RB**, Morawa LG. Complete rupture of the hamstring origin from a water skiing injury. *Am J Sports Med* 1990;**18**:435–7.
- 9 **Sallay PI**, Friedman RL, Coogan PG, *et al*. Hamstring muscle injuries among water skiers: functional outcome and prevention. *Am J Sports Med* 1996;**24**:137–43.
- 10 **Orava S**, Kujala UM. Rupture of ischial origin of the hamstring muscles. *Am J Sports Med* 1995;**23**:702–5.
- 11 **Puranen J**, Orava S. The hamstring syndrome: a new diagnosis of gluteal sciatic pain. *Am J Sports Med* 1988;**16**:517–21.
- 12 **Kujala UM**, Orava S, Jarvinen M. Hamstring injuries. Current trends in treatment and prevention. *Sports Med* 1997;**23**:397–404.