

## CASE REPORT

## Topical tacrolimus may be effective in the treatment of oral and perineal Crohn's disease

D H Casson, M Eltumi, S Tomlin, J A Walker-Smith, S H Murch

### Abstract

**Background**—Crohn's disease of the mouth or perineum is more common in young people, and notably resistant to treatment. However, there is increasing evidence that topical therapy with tacrolimus (FK506) may be effective in skin diseases resistant to cyclosporin because of its high uptake in inflamed skin and subsequent reduction in keratinocyte chemokine production.

**Patients and methods**—Tacrolimus ointment was made up inhouse from the intravenous or oral formulation and suspended in appropriate vehicles for peri oral or perianal administration at an initial concentration of 0.5 mg/g. This was administered open label to eight children (aged 5–18 years) with treatment resistant oral (three patients) and/or ulcerating perineal (six patients) Crohn's disease.

**Results**—Marked improvement was seen in 7/8 patients within six weeks and healing within 1–6 months. One child with gross perineal and colonic disease showed little response. Two of the responders showed rebound worsening when tacrolimus was stopped or the dosage reduced rapidly, and one of these eventually required proctectomy. Slower weaning of drug concentration has been successful in 6/8 patients, with four receiving intermittent treatment and two on regular reduced dosage (0.1–0.3 mg/g) with follow up times of six months to 3.5 years. Serum concentrations of tacrolimus were undetectable in all patients.

**Conclusions**—Topical tacrolimus at low concentrations (0.5 mg/g) shows promise in the management of childhood perineal and oral Crohn's disease, with no evidence of significant systemic absorption. However, rapid weaning or abrupt cessation of therapy may cause rebound worsening of disease. Further controlled studies are required to assess the efficacy and safety of this treatment.

(Gut 2000;47:436–440)

Keywords: Crohn's disease; tacrolimus; children

Although often not associated with significant disease of the small or large bowel, Crohn's disease of the mouth or perineum may cause

significant morbidity and is often a major cause of psychological distress, particularly in young people, in whom it appears to be most common.<sup>1–3</sup> Severe disease in these locations is also notoriously difficult to treat and is frequently resistant to corticosteroids, immunosuppression, enteral nutrition, and antibiotics.<sup>1 2 4 5</sup> There are few reports of successful therapy although long term hyperbaric oxygen may be helpful.<sup>6</sup> The success of anti-tumour necrosis factor (TNF) monoclonal therapy in perianal fistula<sup>7</sup> suggests that this may become an important option in the future, although there are as yet no paediatric studies of long term safety.

Tacrolimus (FK506) is an immunosuppressant drug with a similar mechanism of action to cyclosporin, although it is more potent.<sup>8 9</sup> After systemic tacrolimus induced resolution of psoriasis in post-transplant patients, early trials of topical tacrolimus were instituted and showed significant benefit in atopic dermatitis and psoriasis, where topical cyclosporin had been ineffective.<sup>8–11</sup> This early promise has now been confirmed in multicentre placebo controlled trials.<sup>12 13</sup> Tacrolimus ointment is better absorbed through skin than cyclosporin,<sup>14</sup> and experimental studies have shown that it reduces cytokine generation and T cell activation in both the epidermis and draining lymph nodes.<sup>15</sup> Of particular note, it has been reported to be effective in otherwise treatment resistant pyoderma gangrenosum.<sup>16</sup>

As both oral and perineal Crohn's disease are potentially amenable to topical therapy, we and others attempted treatment with topical cyclosporin, with no evidence of efficacy.<sup>5</sup> We report here contrasting findings of clinical efficacy of topical tacrolimus, prepared inhouse from the intravenous and/or oral formulation.

### Methods

#### PREPARATION OF TOPICAL TACROLIMUS

At the time that we commenced this study (1996), supplies of topical tacrolimus cream were restricted by the manufacturers (Yanagisawa) for ongoing trials in dermatological conditions such as psoriasis. We thus elected to make up the formulation ourselves inhouse using the readily available systemic preparations.

**Abbreviations used in this paper:** TNF, tumour necrosis factor; HDPD, highly destructive perianal disease.

University  
Department of  
Paediatric  
Gastroenterology,  
Royal Free and  
University College  
School of Medicine,  
London, UK  
D H Casson  
J A Walker-Smith  
S H Murch

Department of  
Pharmacy, Royal Free  
and University College  
School of Medicine,  
London, UK  
S Tomlin

Department of  
Paediatrics, Watford  
General Hospital,  
Hertfordshire, UK  
M Eltumi

Correspondence to:  
Dr S Murch, University  
Department of Paediatric  
Gastroenterology, Royal Free  
and University College  
School of Medicine, Royal  
Free Campus, Rowland Hill  
St, London NW3 2PF, UK  
Email: smurch@rfhsm.ac.uk

Accepted for publication  
25 November 1999

Table 1 Clinical response to topical tacrolimus in eight patients

Patient No	Age (y); Sex	Site of disease	Previous unsuccessful therapy	Response to topical tacrolimus (0.5 mg/g twice daily)	Effects of dosage reduction/stopping treatment
1	13; F	HDPD	OS, TS, EN, ASA, TCya, Met, Cip.	Rapid granulation of cavity edges. Initial healing by 6 months.	Partial breakdown when dose reduced. Subsequently healed after returned to full dosage. Later able to tolerate dose reduction.
2	8; F	Extensive perineal ulceration	OS, TS, EN, ASA, TCya, Aza, Met, Cip. Past response to OCya	Rapid response, with healing in 5 weeks.	Marked relapse when treatment stopped. Subsequently less good response. Eventual requirement for proctectomy.
3	5; M	Oral Crohn's, later HDPD	OS, TS, exclusion diets, Met	Marked resolution of lip swelling in 4 weeks. Subsequent rapid resolution of perianal ulceration.	No relapse as dosage reduced. Now on intermittent dosage as required.
4	14; M	Perianal ulceration with distal proctitis	OS, TS, ASA, Met, Cip, AZA	Resolution of perianal disease within 8 weeks. Distal proctitis unchanged.	No relapse as dosage reduced. Now off therapy.
5	11; F	HDPD with severe colitis	OS, TS, AZA, TCya, OCya, Met, Cip	Used with oral tacrolimus. Improvement in pain, but no remission.	Worsening whenever dose reduced. Subsequent moderate improvement with anti-TNF monoclonal.
6	18; M	Oral Crohn's with severe lip swelling	OS, TS, ASA, EN, exclusion diets, AZA, Met	Rapid reduction in lip swelling. Able to wean from high dose steroids.	Able to reduce to once daily dose without recurrence.
7	9; M	Perianal ulceration and fistula	OS, ASA, Met, Cip	Rapid response in 4 weeks, with healing of deep fissure.	Remains well on reduced dosage.
8	10; M	Severe lip swelling	EN, ASA	Lips normal at 6 weeks.	No immediate problems after weaning, but relapsed at 6/12—again responded to tacrolimus.

HDPD, highly destructive perianal disease; OS, oral steroids; TS, topical steroids; ASA, aminosalicylates; OCya, oral cyclosporin; TCya, topical cyclosporin; Met, metronidazole; Cip, ciprofloxacin; AZA, azathioprine; EN, enteral nutrition.

Use of the oral preparation requires laminar flow conditions for safe manufacture and thus initially we used the intravenous formulation. Effective treatment for psoriasis had been reported at concentrations ranging from 0.3 to 3 mg/g of ointment, although measurable systemic concentrations of up to 20 ng/ml had been reported at the higher concentrations when absorbed through broken skin. We thus opted for a concentration at the lower end of this range (0.5 mg/g), made up in Ung Merck or Orabase as clinically appropriate.

### Case reports

The overall response to topical tacrolimus in the eight patients is shown in table 1, with details of previous unsuccessful therapy.

#### CASE NO 1

A 13 year old girl with low grade Crohn's disease of the terminal ileum had suffered extensive treatment resistant highly destructive perianal disease (HDPD) for three years (table 1, fig 1C–E). Topical tacrolimus (0.5 mg of intravenous tacrolimus/g Orabase twice daily) was commenced in April 1996. Granulation of the ulcer margins was visible by two weeks and clear evidence of healing by one month. Repeated estimations of serum tacrolimus found no detectable drug levels. By six months the ulcer was completely healed but she maintained a pattern of partial breakdown on reduction of dosage. She was eventually weaned to 0.1 mg/g and remains in full remission 3.5 years later.

#### CASE NO 2

An eight year old girl with severe Crohn's colitis had extensive perianal and vulval ulceration that had only responded transiently to systemic cyclosporin and had not responded to subtotal colectomy with ileostomy. Application of tac-

rolimus (0.5 mg/g in Orabase twice daily) induced rapid improvement, also without detectable serum levels, and perineal inflammation had resolved completely by five weeks. The treatment was discontinued and she suffered rebound relapse, with rapid recurrence, and only partial response to reintroduction of tacrolimus. No subsequent medication was effective, and she later underwent proctectomy.

#### CASE NO 3

A five year old boy presented with treatment resistant oral Crohn's disease (fig 1A) and minor terminal ileal disease. Topical tacrolimus (0.5 mg/g in Orabase) caused almost complete resolution of his lip lesions within four weeks (fig 1B) which was maintained following slow withdrawal of tacrolimus, and has not recurred. He subsequently developed severe perianal disease with ulceration, and topical tacrolimus (0.5 mg/g in Ung Merck) induced rapid healing, maintained over two years, without regular application. He has had three brief recurrences of perianal inflammation which have responded to 4–5 days of the preparation.

#### CASE NO 4

A 14 year old boy with treatment resistant distal proctitis developed perianal inflammation with superficial erosions that was also resistant to local and systemic therapy. He was commenced on topical tacrolimus therapy (0.5 mg/g in Ung Merck) and experienced rapid resolution, with no relapse of his perianal disease on slow reduction and discontinuation of therapy.

#### CASE NO 5

An 11 year old girl with severe Crohn's colitis developed gross perineal ulcerating disease completely resistant to all treatment. She was treated with both oral and topical tacrolimus

(0.5 mg/g in Ung Merck three times daily) and showed diminution of her perineal disease but did not achieve remission. Dosage reduction was followed by rapid return of pain and exacerbation of local swelling. She later showed only partial response to three infusions of anti-TNF monoclonal (infliximab).

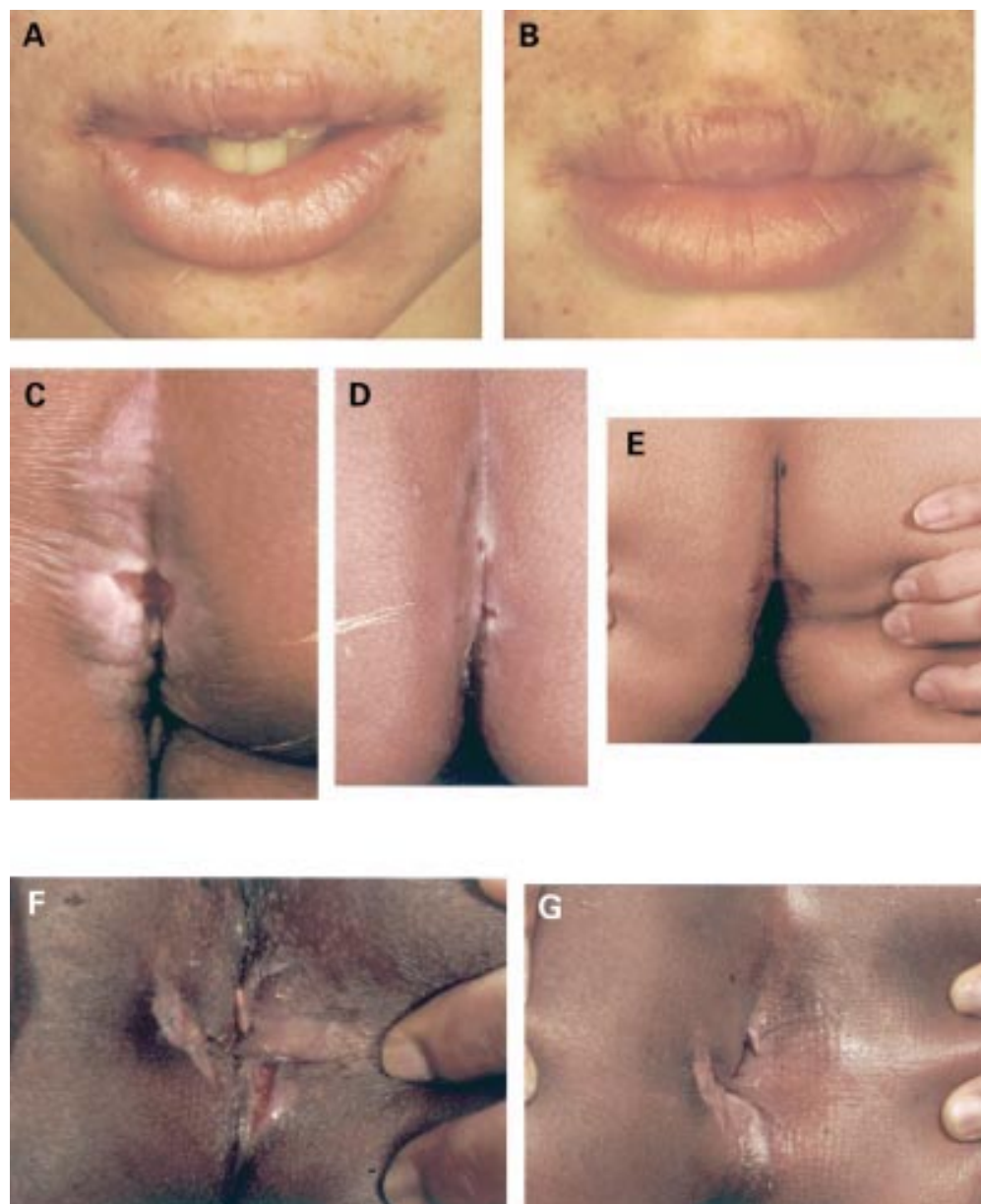
#### CASE NO 6

An 18 year old boy had oral Crohn's disease with severe lip swelling, requiring 40–60 mg of prednisolone daily for over four years to keep his lip swelling at cosmetically acceptable levels. Twice

daily perioral topical tacrolimus (0.5 mg/g in Orabase) induced prompt and maintained reduction in lip swelling, allowing reduction of prednisolone dosage to 5–10 mg daily which has been maintained for 18 months.

#### CASE NO 7

A nine year old boy with duodenal and ileocolonic Crohn's disease presented with a painful perianal fistula together with a deep anal ulcer which had not responded to surgery (fig 1F). He was commenced on topical tacrolimus (0.5 mg/g in Ung Merck). He responded



**Figure 1** Clinical response to topical tacrolimus therapy in three children with oral or perianal disease. Case No 3 is shown in (A) and (B); case No 1 in (C–E); and case No 7 in (F) and (G). (A) Gross lip swelling with angular cheilitis which had not responded to steroids or nutritional exclusions in a five year old boy (case No 3). (B) Marked resolution of lip swelling after four weeks of topical tacrolimus therapy. He has subsequently shown a similar response to perianal disease. (C) Severe perianal ulceration in a girl with Crohn's disease (case No 1). The ulceration was deep, with a 2–3 cm cavity, which is not apparent on the photograph. (D) Marked healing of the lesion periphery in the same case after several months but with two areas of breakdown that occurred after a reduction in dosage (she had previously healed completely but had not been photographed). (E) Eventual complete healing which has been maintained on a programme of very slow reduction in tacrolimus concentration. (F) Marked perianal ulceration with open fistula track in a nine year old boy (case No 7). This had persisted despite successful treatment of his intra-abdominal disease. (G) Follow up appearances after four weeks of topical tacrolimus with marked improvement and healing of his fistula track.



rapidly, with relief of local pain, and showed healing of his deep fissure by four weeks (fig 1G). This has been maintained, and he remains free from perineal ulceration nine months later with only intermittent topical applications.

#### CASE NO 8

A 10 year old boy with Crohn's disease of the mouth, oesophagus, terminal ileum, and colon achieved full remission of systemic disease on enteral nutrition and mesalazine but his marked lip swelling and fissuring were not improved. Topical tacrolimus (0.5 mg/g in Orobace twice daily) induced complete remission in six weeks and he was able to be weaned off the tacrolimus over the next month, but he again developed swelling and fissuring six months later. This responded well to a second course, and he is currently asymptomatic.

#### Discussion

Our preliminary observations in children with severe treatment resistant Crohn's disease of the mouth and perineum suggest that topical tacrolimus may be effective in the management of these therapeutically challenging groups. This is in contrast with topical cyclosporin therapy, and this study was initiated only following early reports of high efficacy in skin diseases.<sup>8-11</sup> It is important to note that it was not universally successful, and it is likely that when gross perineal disease occurs with severe distal colitis a highly potent systemic therapy such as anti-TNF may be required. However, the response was sufficiently impressive in those children with isolated perioral and perineal disease that we would recommend that topical therapy with tacrolimus be considered early, particularly as to date it has shown no evidence of systemic absorption.

Systemic tacrolimus has provided less striking results than might have been expected in Crohn's disease, not least because its profound suppression of T cell activation by preventing nuclear localisation of NF-AT (nuclear factor of activated T cells)<sup>17</sup> and interleukin-2 transcription made it theoretically ideal.<sup>3 18</sup> This relative inefficacy in gut inflammation, despite high potency in preventing allograft rejection, may be explained by inhibition of an activation pathway dependent on signalling via the T cell receptor/CD3 complex.<sup>9</sup> However, intestinal lymphocytes are relatively refractory to activation via CD3<sup>19</sup> and respond instead to signalling via the costimulatory molecule CD2.<sup>20</sup> In contrast, the striking efficacy of topical tacrolimus in a variety of skin diseases may reflect its 3000-fold increased concentration in inflamed compared with normal skin<sup>9 14</sup> and distinct additional modes of action. In skin inflammation, the microenvironment of the draining lymph nodes is shifted away from inflammatory proliferation by tacrolimus,<sup>15</sup> and keratinocyte production of the chemokine interleukin-8 is specifically inhibited.<sup>21</sup>

An adverse response that occurred in two children was rebound relapse of inflammation on reducing or stopping tacrolimus, a phenomenon recognised in transplant surgery. In one patient this relapse did not respond adequately

to recommencing therapy. In contrast, others were able to reduce or stop dosage at will. However, we would recommend that rapid dosage reduction is avoided to minimise the occurrence of this complication. In those who respond but remain sensitive to dosage reduction, a subsequent very slow reduction in concentration may be successful.

We detected no other adverse effects, apart from mild stinging on application in two patients. Importantly, there were no detectable serum levels, which suggests that there may be few of the systemic effects of oral administration. This contrast with findings in adults with psoriasis<sup>22</sup> may relate to the smaller area treated, or may have occurred because we maintained drug concentrations at the lowest end of the reported therapeutic range (0.5 mg/g). As there is a dose-response relationship in psoriasis, it is possible that concentrations of up to 2-3 mg/g may be more effective in oroanal Crohn's disease, although serum concentrations should be monitored.

The treatment is undeniably expensive. Using the intravenous preparation, a 30 g tube at 0.5 mg/g, allowing twice daily applications for two weeks to a large perineal lesion, costs approximately £240. Use of oral capsules, provided laminar flow facilities are available, reduces these costs to less than a quarter of this figure. When a topical preparation becomes commercially available, the cost may reduce further. However, it is unlikely that this will be formulated in a vehicle ideally suited for both oral and perianal application, and the advantages of inhouse manufacture are that a concentration and a base suitable for the patient, disease localisation, and character can be chosen and an appropriate rate of dose weaning instituted.

We thank the children and their families for taking part in the study. We are grateful to Drs Neil Shah and Raoul Furlano for expediting the clinical photographs, Simon Keady for continuing preparation of topical tacrolimus and support of the families, and Dr Malcolm Rustin for advice and support.

This study was presented at the April 1999 meeting of the Royal College of Paediatrics and Child Health (*Arch Dis Child* 1999; 80:S(1):A22).

- 1 Tolia V. Perianal Crohn's disease in children and adolescents. *Am J Gastroenterol* 1996;91:922-6.
- 2 Markowitz J, Grancher K, Rosa J, Simpser E, Aiges H, Daum F. Highly destructive perianal disease in children with Crohn's disease. *J Pediatr Gastroenterol Nutr* 1995;21:149-53.
- 3 Walker-Smith JA, Murch SH. Crohn's disease and abdominal tuberculosis. In: *Diseases of the small intestine in childhood*, 4th Edn. Oxford: Isis Medical Media, 1999:299-328.
- 4 O'Donoghue DP, Hyland JM. Perianal Crohn's disease. *Eur J Gastroenterol Hepatol* 1997;9:235-6.
- 5 Murch SH, Walker-Smith JA. Medical therapy of chronic inflammatory bowel disease. *Baillieres Clin Gastroenterol* 1994;8:133-48.
- 6 Noyer CM, Brandt LJ. Hyperbaric oxygen therapy for perineal Crohn's disease. *Am J Gastroenterol* 1999;94:318-21.
- 7 Present DH, Rutgeerts P, Targan S, et al. Infliximab for the treatment of fistulas in patients with Crohn's disease. *New Engl J Med* 1999;340:1398-405.
- 8 Lauerma AI, Maibach HI. Topical FK506—clinical potential or laboratory curiosity? *Dermatology* 1994;188:173-6.
- 9 Michel G, Kemény L, Homey B, Ruzicka T. FK506 in the treatment of inflammatory skin disease: promises and perspectives. *Immunol Today* 1996;17:106-8.
- 10 Nakagawa H, Etoh T, Ishibashi Y, et al. Tacrolimus ointment for atopic dermatitis. *Lancet* 1994;344:883.
- 11 Lauerma AI, Maibach HI, Granlund H, Erkkö P, Kartamaa M, Stubb S. Inhibition of contact allergens by topical FK506. *Lancet* 1992;340:556.
- 12 Ruzicka T, Bieber T, Schöpf E, et al. A short-term trial of tacrolimus ointment for atopic dermatitis. European Tacrolimus Multicenter Atopic Dermatitis Study Group. *New Engl J Med* 1997;337:816-21.

- 13 Ruzicka T, Assmann T, Homey B. Tacrolimus—the drug for the turn of the millenium. *Arch Dermatol* 1999;**135**:574–80.
- 14 Lauerma AI, Surber C, Maibach HI. Absorption of topical tacrolimus (FK506) *in vitro* through human skin: comparison with cyclosporin A. *Skin Pharmacol* 1997;**10**:230–4.
- 15 Homey B, Assmann T, Vohr HW, et al. Topical FK506 suppresses cytokine and costimulatory molecule expression in epidermal and local draining lymph node cells during primary immune responses. *J Immunol* 1998;**160**:5331–40.
- 16 Schuppe H-C, Homey B, Assmann T, Martens R, Ruzicka T. Topical tacrolimus for pyoderma gangrenosum. *Lancet* 1998;**351**:832.
- 17 Zhu J, McKeon F. NF-AT activation requires suppression of Crm1-dependent export by calcineurin. *Nature* 1999;**398**:256–60.
- 18 MacDonald TT, Murch SH. The aetiology and pathogenesis of chronic inflammatory bowel disease. *Baillieres Clin Gastroenterol* 1994;**8**:1–34.
- 19 Christ AD, Colgan SP, Balk SP, Blumberg RS. Human intestinal epithelial cell lines produce factor(s) that inhibit CD3-mediated T-lymphocyte proliferation. *Immunol Lett* 1997;**58**:159–65.
- 20 Targan SR, Deem RL, Liu M, Wang S, Nel A. Definition of a lamina propria T cell responsive state. Enhanced cytokine responsiveness of T cells stimulated through the CD2 pathway. *J Immunol* 1995;**154**:664–675.
- 21 Michel G, Auer H, Kemény L, Böcking A, Ruzicka T. Antioncogene p53 and mitogenic cytokine interleukin-8 aberrantly expressed in psoriatic skin are inversely regulated by the antipsoriatic drug tacrolimus (FK506). *Biochem Pharmacol* 1996;**51**:1315–20.
- 22 Kawashima M, Nakagawa H, Ohtsuki M, Tamaki K, Ishibashi Y. Tacrolimus concentrations in blood during topical treatment of atopic dermatitis. *Lancet* 1996;**348**:1240–1.