

## CASE STUDY

## Myocardial infarction in young people with normal coronary arteries

M J A Williams, N J Restieaux, C J S Low

### Abstract

**Myocardial infarction occurring in young people with angiographically normal coronary arteries is well described but the pathophysiology of this condition remains unknown. Coronary artery spasm in association with thrombus formation and minimal atheromatous disease or spontaneous coronary artery dissection are possible causes. Two young men presented with severe chest pain after acute alcohol intoxication and each sustained an extensive anterior myocardial infarction. Investigations including intravascular ultrasound showed no evidence of atherosclerotic coronary artery disease. Coronary artery spasm associated with acute alcohol intoxication as well as a prothrombotic state and endothelial damage related to cigarette smoking may be mechanisms leading to acute myocardial infarction in these cases. Acute myocardial infarction occurs in young persons with normal coronary arteries and the diagnosis should be considered in young patients presenting with severe chest pain, particularly those abusing cocaine or alcohol, so that reperfusion therapy can be initiated promptly.**

(Heart 1998;79:191-194)

Keywords: myocardial infarction; coronary vasospasm; alcohol; intravascular ultrasound

Acute myocardial infarction may occur when the coronary arteries are normal or nearly normal.<sup>1-3</sup> In patients with normal coronary arteries there is strong evidence for the participation of thrombus formation in the pathogenesis of myocardial infarction.<sup>4</sup> Coronary artery spasm may also play a role in initiating coronary occlusion and infarction.<sup>5</sup> There is strong evidence to suggest that cigarette smoking is an important predisposing risk factor for myocardial infarction in the presence of normal coronary arteries.

We report two cases of acute myocardial infarction in young male smokers where alcohol was implicated as a precipitating factor. These cases illustrate an association between cigarette smoking, acute alcohol intoxication, and myocardial infarction in the absence of coronary artery disease.

### Case reports

#### CASE 1

A 21 year old man presented to a peripheral hospital with sudden onset severe chest pain during a rugby match. He had been binge drinking spirits with the rugby team the night before. He smoked 15 cigarettes a day and denied any illicit drug use including cocaine. There was no family history of premature coronary artery disease. The ECG at admission showed hyperacute T waves in the anteroseptal leads with 2 mV ST segment depression in V2-3. He was treated with morphine but was not pain free until 12 hours later. The following day the ECG demonstrated Q waves from V1-5 with ST-T wave changes consistent with an extensive anterior myocardial infarction. The patient was transferred to a tertiary centre for further assessment.

Creatine kinase peaked at 4404 IU/l (normal < 90) and echocardiography showed akinesis of the anterior and anteroseptal segments from base to apex, with moderate impairment of left ventricular function. He was treated with aspirin, intravenous heparin, and captopril. Coronary angiography performed five days after presentation showed no evidence of obstructive coronary disease. Subsequently he was free from angina on no antianginal treatment and had normal exercise tolerance at five years' follow up. Echocardiography showed persistent wall motion abnormalities of the anterior and anteroseptal segments and overall left ventricular function remained moderately impaired.

#### CASE 2

A 23 year old man presented to hospital with sudden onset severe chest pain waking him from sleep in the early hours of the morning. He gave a history of consuming approximately one litre of bourbon the preceding evening but denied using cocaine at any time. He smoked 20 cigarettes a day and there was no family history of premature coronary artery disease. ECG at admission showed Q waves from V1-3 and hyperacute ST segment elevation across the anterior chest leads. He was treated with morphine and aspirin. The day after admission creatine kinase peaked at 4843 IU/l and he developed a pericardial rub and pulmonary oedema. Frusemide and captopril were administered. He was transferred to a tertiary

Department of  
Medicine, University  
of Otago, 201 Great  
King Street, Dunedin,  
New Zealand  
M J A Williams  
N J Restieaux  
C J S Low

Correspondence to:  
Dr Williams  
email: michael.williams@  
stonebow.otago.ac.nz

Accepted for publication  
20 August 1997

centre for further assessment seven days after admission.

Echocardiography revealed extensive akinesis of the anteroseptal, anterior, and anterolateral segments from base to apex with severe impairment of left ventricular function. Mural thrombus was present, extending anteriorly from the apex to the mid-ventricular level, for which anticoagulation with heparin was commenced.

Coronary angiography showed proximal occlusion of the left anterior descending artery (fig 1). Intravascular ultrasound examination (3.0 F, 30 MHz imaging catheter; Boston Scientific, Boston, Massachusetts, USA) of the left main, proximal, and middle segments of the left anterior descending coronary arteries demonstrated no evidence of atherosclerotic plaque. An extensive area of mobile intraluminal speckled echodensity (fig 1, inset) was present in the proximal segment of the left anterior descending coronary artery, consistent with mural thrombus.<sup>6</sup>

Angioplasty was performed which resulted in TIMI-3 flow in the left anterior descending artery. Angiographically there appeared to be extensive persistent thrombus in the left anterior descending artery with displacement of thrombus into the proximal circumflex artery. These findings were confirmed by repeat intravascular ultrasound. The patient was started on an infusion of abciximab (chimeric monoclonal antibody 7E3 directed against the glycoprotein IIb/IIIa platelet receptor), continued on heparin, and was anticoagulated with warfarin.

Coronary arteriography was repeated one week later, which confirmed patency of the left anterior descending artery and resolution of thrombus. At the time of hospital discharge echocardiography showed left ventricular function remained severely impaired. Subsequently

he had several readmissions with ventricular tachycardia and heart failure culminating in admission with resistant ventricular tachycardia and cardiogenic shock. Coronary angiography was repeated and showed that all coronary arteries were patent without evidence of intraluminal thrombus. He died a week later while awaiting urgent cardiac transplantation.

## Discussion

The pathogenetic mechanism of myocardial infarction in patients with normal coronary arteries remains unknown. Coronary artery spasm has been shown to cause myocardial infarction in patients with normal coronary arteries<sup>5</sup> and it has been concluded that spasm may initiate myocardial infarction, but only in approximately one third of such patients.<sup>4,7</sup> It has been hypothesised that the mechanism of acute myocardial infarction in these patients is temporary occlusion of the infarct related vessel by spasm or thrombus or a combination of both.<sup>4</sup>

In people using cocaine as a recreational drug there is evidence to suggest that cocaine induced coronary spasm can lead to thrombosis and acute myocardial infarction in patients with normal coronary arteries.<sup>8,9</sup> The mechanism of myocardial infarction in these patients includes coronary vasoconstriction,<sup>10</sup> platelet activation,<sup>11</sup> and platelet  $\alpha$  granule release.<sup>12</sup>

Myocardial infarction with normal coronary arteries occurring after alcohol intoxication is not well documented, with this association previously reported in only four patients.<sup>13,14</sup> However, it is well known that ethanol induces concentration dependent vasospasm in coronary arteries.<sup>15</sup> It has also been shown that coronary vasoconstriction itself may damage the endothelium, thereby increasing the likelihood of platelet adhesion and thrombus formation following ethanol related vasoconstriction.<sup>16</sup>

Epidemiological studies have shown higher rates of alcohol abuse in men younger than 40 with a first myocardial infarction<sup>17</sup> and higher rates of sudden death in heavy alcohol consumers.<sup>18</sup> In addition, alcohol and cigarette smoking have been shown to have additive effects on increasing the risk of coronary death,<sup>19</sup> which suggests both are important factors in the pathogenesis of abrupt coronary occlusion in patients with normal coronary arteries.

Cigarette smoking is a commonly identified risk factor in young patients with normal coronary arteries suffering myocardial infarction.<sup>1,3,7</sup> It has been shown that there is increased platelet consumption in young smokers without clinical evidence of coronary artery disease.<sup>20</sup> This relation is presumably related to the mechanism of enhanced platelet aggregation and adhesion seen after smoking cigarettes<sup>21,22</sup> that would be expected to increase the thrombotic risk in smokers with normal coronary arteries.

Previous studies have shown that acute exposure to cigarette smoke does not produce coronary vasoconstriction in subjects with normal coronary arteries.<sup>23</sup> However, there is strong evidence that endothelium dependent

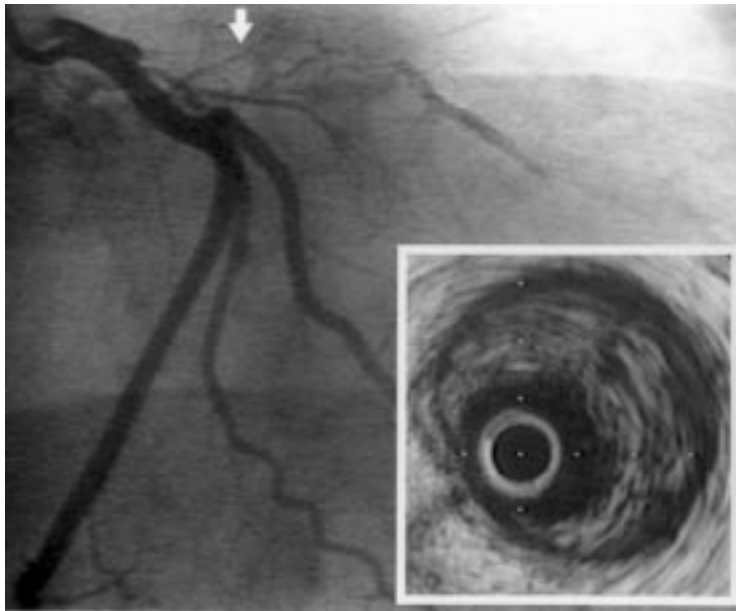


Figure 1 Coronary angiogram in the right anterior oblique projection of case 2 showing proximal occlusion of the left anterior descending artery and decreased filling distally. Inset, intravascular ultrasound image of the proximal left anterior descending artery (site indicated by arrow) showing extensive intraluminal thrombus.

(flow mediated) vasodilatation is impaired in smokers<sup>24</sup> and passive smokers<sup>25</sup> without clinical evidence of coronary artery disease. This raises the possibility that chronic smokers without angiographic evidence of coronary artery disease have preclinical vascular disease, and may have an increased susceptibility to vasospastic agents such as alcohol or cocaine.

The most common mechanism of acute coronary thrombosis is rupture of a plaque with a thin fibrous cap overlying a large lipid core.<sup>26</sup> It is established that such vulnerable plaques can be present in arteries that appear angiographically normal.<sup>27</sup> A second mechanism of coronary thrombosis is related to erosion and denudation of endothelial cells over the surface of plaques rich in proteoglycans, and smooth muscle cells adjacent to the lumen.<sup>28</sup> It has been suggested that this mechanism of thrombosis is more likely in younger patients and in women.<sup>29</sup> Cigarette smoking is a risk factor for thrombosis associated with both plaque rupture and endothelial erosion<sup>28</sup> possibly through the mechanism of direct toxic effects on vascular endothelium.<sup>30</sup>

Spontaneous coronary artery dissection is a rare cause of acute myocardial infarction or sudden death occurring most commonly in young women.<sup>31</sup> Histological examination usually reveals evidence of subadventitial haematoma with compression of the true lumen, and obstruction to coronary flow.<sup>32</sup> Intimal thickening with smooth muscle cell infiltration is observed but intimal tears are unusual.<sup>33</sup> Early angiography may demonstrate a radiolucent line representing the intima and media separating true and false channels.<sup>34</sup> If there is no flow into the area of the haematoma, angiography reveals a decrease in luminal area indistinguishable from other causes of stenosis. In this situation, with resolution of the haematoma, subsequent angiography reveals an artery with an apparently normal lumen although the organised haematoma remains recognisable in histological sections.

The angiographic definition of normal coronary arteries relies on axial contrast angiograms of the vessel lumen, which underestimate the presence of atherosclerotic plaque.<sup>35</sup> A contributing factor to the insensitivity of angiography for detection of plaques is that atherosclerosis is associated with medial atrophy and vessel wall dilatation resulting in diffusely diseased arteries appearing to have an angiographically normal lumen.<sup>36</sup> Given the inherent limitations of angiography it is not surprising that there is limited information about the true prevalence of plaques in patients with myocardial infarction and normal coronary arteries. Further insights into the role of plaques in the pathogenesis of thrombosis in such patients is dependent on improved methods of visualising atherosclerotic plaque.

Intravascular ultrasound overcomes the limitations of angiography with tomographic images, which provide accurate characterisation of the vessel lumen and wall geometry, as well as the presence and distribution of atherosclerotic plaque.<sup>37</sup> These advantages mean that intravascular ultrasound is the most sensitive

technique for detecting the presence of coronary atherosclerosis in young persons with myocardial infarction and angiographically normal coronary arteries.<sup>38</sup>

The advantages of intravascular ultrasound examination are exemplified in the second case where angiography demonstrated an occluded vessel without distinguishing between the possibilities of atherosclerotic obstruction, thrombotic occlusion or spontaneous coronary artery dissection. Intravascular ultrasound showed no evidence of underlying atherosclerotic plaque, but did demonstrate significant intraluminal thrombus.<sup>6</sup> These appearances are consistent with a vasospastic/thrombotic process rather than rupture of lipid laden plaque or plaque erosion precipitating thrombotic occlusion and infarction as seen in those with established coronary artery disease.

Initial reports describe successful lysis of the occluding "thrombus" with intracoronary streptokinase in patients with normal coronary arteries.<sup>4</sup> It is probable, although not proved, that intravenous thrombolysis in this group should be of similar efficacy to those with established coronary artery disease, and thus should be the standard therapy for young patients presenting with ECG changes of acute myocardial infarction where immediate coronary angiography is not being considered.

Intracoronary vasodilators have been given during the acute phase of myocardial infarction in patients with normal coronary arteries, and have not been effective in achieving reperfusion.<sup>5 39</sup> In the second case described in this report it was elected to perform angioplasty and administer an intravenous infusion of group IIb/IIIa platelet receptor blocker to achieve the best likelihood of prolonged patency of the infarct related artery and improved survival.<sup>40 41</sup>

The prognosis of patients with normal coronary arteries following myocardial infarction has been reported as generally favourable with an 85–96% survival rate.<sup>7 42</sup> An increased risk of subsequent death is associated with more severe impairment of left ventricular function and ventricular arrhythmia<sup>7 39</sup> as seen in our second case.

Coronary artery spasm associated with acute alcohol intoxication and a prothrombotic state related to the platelet and endothelial effects of cigarette smoking are possible mechanisms of acute myocardial infarction in the two cases presented in this report. The diagnosis of acute myocardial infarction should be seriously considered in all young smokers, especially after acute alcohol intoxication or cocaine exposure. Failure to consider thrombolytic therapy or coronary angioplasty may result in extensive myocardial infarction and impairment of left ventricular function. Early diagnosis and initiation of treatment to achieve early arterial patency should improve outcome in these patients.

- 1 Khan AH, Haywood LJ. Myocardial infarction in nine patients with radiologically patent coronary arteries. *N Engl J Med* 1974;291:427-31.
- 2 Arnett EN, Roberts WC. Acute myocardial infarction and angiographically normal coronary arteries. An unproven combination. *Circulation* 1976;53:395-400.
- 3 McKenna WJ, Chew CY, Oakley CM. Myocardial infarction with normal coronary angiogram. Possible mechanism of smoking risk in coronary artery disease. *Br Heart J* 1980;43:493-8.
- 4 Lindsay J Jr, Pichard AD. Acute myocardial infarction with normal coronary arteries. *Am J Cardiol* 1984;54:902-4.
- 5 Vincent GM, Anderson JL, Marshall HW. Coronary spasm producing coronary thrombosis and myocardial infarction. *N Engl J Med* 1983;309:220-3.
- 6 Chemarin-Alibelli MJ, Pieraggi MT, Elbaz M, Carrie D, Fourcade J, Puel J, et al. Identification of coronary thrombus after myocardial infarction by intracoronary ultrasound compared with histology of tissues sampled by atherectomy. *Am J Cardiol* 1996;77:344-9.
- 7 Raymond R, Lynch J, Underwood D, Leatherman J, Razavi M. Myocardial infarction and normal coronary arteriography: a 10 year clinical and risk analysis of 74 patients. *J Am Coll Cardiol* 1988;11:471-7.
- 8 Zimmerman FH, Gustafson GM, Kemp HG Jr. Recurrent myocardial infarction associated with cocaine abuse in a young man with normal coronary arteries: evidence for coronary artery spasm culminating in thrombosis. *J Am Coll Cardiol* 1987;9:964-8.
- 9 Williams MJA, Stewart RAH. Serial angiography in cocaine-induced myocardial infarction. *Chest* 1997;111:822-4.
- 10 Lange RA, Cigarroa RG, Yancy CW Jr, Willard JE, Popma JJ, Sills MN, et al. Cocaine-induced coronary-artery vasoconstriction. *N Engl J Med* 1989;321:1557-62.
- 11 Kugelmass AD, Oda A, Monahan K, Cabral C, Ware JA. Activation of human platelets by cocaine. *Circulation* 1993;88:876-83.
- 12 Rinder HM, Ault KA, Jatlow PI, Kosten TR, Smith BR. Platelet alpha-granule release in cocaine users. *Circulation* 1994;90:1162-7.
- 13 Moreyra AE, Kostis JB, Passannante AJ, Kuo PT. Acute myocardial infarction in patients with normal coronary arteries after acute ethanol intoxication. *Clin Cardiol* 1982;5:425-30.
- 14 Tomono S, Ohshima S, Murata K. The risk factors for ischemic heart disease in young adults. *Jpn Circ J* 1990;54:436-41.
- 15 Altura BM, Altura BT, Carella A. Ethanol produces coronary vasospasm: evidence for a direct action of ethanol on vascular muscle. *Br J Pharmacol* 1983;78:260-2.
- 16 Gertz SD, Uretsky G, Wajsborg RS, Navot N, Gotsman MS. Endothelial cell damage and thrombus formation after partial arterial constriction: relevance to the role of coronary artery spasm in the pathogenesis of myocardial infarction. *Circulation* 1981;63:476-86.
- 17 Bergstrand R, Vedin A, Wilhelmsson C, Wilhelmsen L. Characteristics of males with myocardial infarction below age 40. *J Chronic Dis* 1983;36:289-96.
- 18 Fraser GE, Upsdell M. Alcohol and other discriminants between cases of sudden death and myocardial infarction. *Am J Epidemiol* 1981;114:462-76.
- 19 Rosengren A, Wilhelmsen L, Wedel H. Separate and combined effects of smoking and alcohol abuse in middle-aged men. *Acta Med Scand* 1988;223:111-18.
- 20 Fuster V, Chesebro JH, Frye RL, Elveback LR. Platelet survival and the development of coronary artery disease in the young adult: effects of cigarette smoking, strong family history and medical therapy. *Circulation* 1981;63:546-51.
- 21 Levine PH. An acute effect of cigarette smoking on platelet function. A possible link between smoking and arterial thrombosis. *Circulation* 1973;48:619-23.
- 22 Pittilo RM, Clarke JM, Harris D, Mackie IJ, Rowles PM, Machin SJ, et al. Cigarette smoking and platelet adhesion. *Br J Haematol* 1984;58:627-32.
- 23 Barger LM, Ehmke D, Gonlubol F, Castellanos A, Siegel A, Bing RJ. Effect of cigarette smoking on coronary blood flow and myocardial metabolism. *Circulation* 1957;15:251-7.
- 24 Celermaier DS, Sorensen KE, Georgakopoulos D, Bull C, Thomas O, Robinson J, et al. Cigarette smoking is associated with dose-related and potentially reversible impairment of endothelium-dependent dilation in healthy young adults. *Circulation* 1993;88:2149-55.
- 25 Celermaier DS, Adams MR, Clarkson P, Robinson J, McCredie R, Donald A, et al. Passive smoking and impaired endothelium-dependent arterial dilatation in healthy young adults. *N Engl J Med* 1996;334:150-4.
- 26 Davies MJ. Stability and instability: two faces of coronary atherosclerosis. *Circulation* 1996;94:2013-20.
- 27 Mann JM, Davies MJ. Vulnerable plaque. Relation of characteristics to degree of stenosis in human coronary arteries. *Circulation* 1996;94:928-31.
- 28 Burke AP, Farb A, Malcom GT, Liang YH, Smialek J, Virmani R. Coronary risk factors and plaque morphology in men with coronary disease who died suddenly. *N Engl J Med* 1997;336:1276-82.
- 29 Farb A, Burke AP, Tang AL, Liang TY, Mannan P, Smialek J, et al. Coronary plaque erosion without rupture into a lipid core. A frequent cause of coronary thrombosis in sudden coronary death. *Circulation* 1996;93:1354-63.
- 30 Davis JW, Shelton L, Eigenberg DA, Hignite CE, Watanabe IS. Effects of tobacco and non-tobacco cigarette smoking on endothelium and platelets. *Clin Pharmacol Ther* 1985;37:529-33.
- 31 Basso C, Morgagni GL, Thiene G. Spontaneous coronary artery dissection: a neglected cause of acute myocardial ischaemia and sudden death. *Heart* 1996;75:451-4.
- 32 Davies MJ, Treasure T, Richardson PD. The pathogenesis of spontaneous arterial dissection. *Heart* 1996;75:434-5.
- 33 Molloy PJ, Ablett MB, Anderson KR. Left main stem coronary artery dissection. *Br Heart J* 1980;43:705-8.
- 34 Jorgensen MB, Aharonian V, Mansukhani P, Mahrer PR. Spontaneous coronary dissection: a cluster of cases with this rare finding. *Am Heart J* 1994;127:1382-7.
- 35 Arnett EN, Isner JM, Redwood DR, Kent KM, Baker WP, Ackerstein H, et al. Coronary artery narrowing in coronary heart disease: comparison of cineangiographic and necropsy findings. *Ann Intern Med* 1979;91:350-6.
- 36 Glagov S, Weisenberg E, Zarins CK, Stankunavicius R, Koletts GJ. Compensatory enlargement of human atherosclerotic coronary arteries. *N Engl J Med* 1987;316:1371-5.
- 37 Potkin BN, Bartorelli AL, Gessert JM, Neville RF, Almagor Y, Roberts WC, et al. Coronary artery imaging with intravascular high-frequency ultrasound. *Circulation* 1990;81:1575-85.
- 38 St Goar FG, Pinto FJ, Alderman EL, Fitzgerald PJ, Stinson EB, Billingham ME, et al. Detection of coronary atherosclerosis in young adult hearts using intravascular ultrasound. *Circulation* 1992;86:756-63.
- 39 Pecora MJ, Roubin GS, Cobbs BW Jr, Ellis SG, Weintraub WS, King SB III. Presentation and late outcome of myocardial infarction in the absence of angiographically significant coronary artery disease. *Am J Cardiol* 1988;62:363-7.
- 40 Topol EJ, Califf RM, Weisman HF, Ellis SG, Tchong JE, Worley S, et al. Randomised trial of coronary intervention with antibody against platelet IIb/IIIa integrin for reduction of clinical restenosis: results at six months. *Lancet* 1994;343:881-6.
- 41 Brodie BR, Stuckey TD, Kissling G, Hansen CJ, Weintraub RA, Kelly TA. Importance of infarct-related artery patency for recovery of left ventricular function and late survival after primary angioplasty for acute myocardial infarction. *J Am Coll Cardiol* 1996;28:319-25.
- 42 Ciraulo DA, Bresnahan GF, Frankel PS, Isely PE, Zimmerman WR, Chesne RB. Transmural myocardial infarction with normal coronary angiograms and with single vessel coronary obstruction: clinical-angiographic features and five-year follow-up. *Chest* 1983;83:196-202.