

CASE REPORT

Varicella myocarditis in an adult

P Alter, W Grimm, B Maisch

Abstract

A 24 year old male with varicella myocarditis was admitted with chest pain and fever up to 39°C. The ECG showed J point and ST elevation in leads V2–V4, and inverted T waves in leads V5 and V6. Creatine kinase (CK) was raised to 435 U/l (CK-MB 36 U/l), troponin I was 63.4 µg/l, and lactate dehydrogenase was 359 U/l, suggesting cardiac involvement of varicella infection. The left ventricle was dilated (58 mm) and left ventricular ejection fraction was globally reduced (ejection fraction 45%). Myocarditis was confirmed by endomyocardial biopsy. The patient was treated with specific varicella hyperimmunoglobulins, aciclovir, and a non-steroidal anti-inflammatory drug. During two months follow up the patient recovered completely. This case report is a reminder that a varicella infection can cause myocarditis in adults. Early diagnosis and appropriate treatment of this rare form of myocarditis may lead to complete recovery.

(Heart 2001;85:e2)

Keywords: myocarditis; varicella zoster; endomyocardial biopsy

Myocarditis in adults has been observed during the course of a wide variety of viral, rickettsial, bacterial, and protozoal diseases. More than 20 different viruses have been shown to cause myocarditis in humans.¹ Myocarditis caused by

infection by varicella zoster virus has been occasionally observed in children.^{2,3} To the best of our knowledge only one case of a biopsy proven myocarditis has been reported in a child, and no case of a biopsy proven myocarditis due to varicella zoster has been reported in an adult.⁴

Case report

A 24 year old male was admitted to our hospital with chest pain, fever up to 39°C, and a papulomaculoid exanthema on his back and upper extremities consistent with a chicken pox infection. Creatine kinase (CK) was raised to 435 U/l with a notable CK-MB concentration of 36 U/l (8.3%). Troponin I was increased to 38.5 µg/l, lactate dehydrogenase (LDH) to 359 U/l, C reactive protein to 35 mg/l, and white blood cell count to 12.4 G/l. An enzyme linked immunosorbent assay (ELISA) test for specific varicella immunoglobulins revealed distinctly raised concentrations for IgM and IgG (2300 mIU/ml). Persistence of varicella virus genome was documented by polymerase chain reaction from the papulomaculoid exanthema on the back of the patient. The 12 lead resting ECG showed regular sinus rhythm (80 beats/min), J point and 0.3 mV ST elevation in leads V2–V4, and inverted T waves in leads V5 and V6. Echocardiographic study revealed dilated end diastolic left ventricular diameter (LVEDD 58 mm) and reduced left ventricular ejection fraction (45%). Neither valvar heart disease nor pericardial effusion were found. Coronary artery disease was excluded by coronary angiography. Ventriculography revealed a reduced left ventricular ejection fraction of 46%. Histological and immunological examination of the left ventricular endomyocardial biopsy documented myocarditis with lymphocytic infiltration as shown in fig 1.

The patient was treated in our intensive care unit with specific varicella hyperimmunoglobulins on the second and fourth day (Varitect, 2 ml/kg bodyweight). In addition, he received aciclovir (10 mg/kg bodyweight per day intravenously) and a non-steroidal anti-inflammatory drug (NSAID) for the first five days (diclofenac 50 mg three times daily). CK returned to normal by the fifth day. Arrhythmias were not observed at any time during hospitalisation. During two months of follow up the cardiac function of our patient recovered completely and he remained free of symptoms (LVEDD 51 mm, ejection fraction 72%).

Department of Internal Medicine—Cardiology, Philipps-University of Marburg, Baldingerstraße, D-35033

Marburg/Lahn, Germany
P Alter
W Grimm
B Maisch

Correspondence to:
Dr med Peter Alter
alter@mail.uni-marburg.de

Accepted 28 June 2000

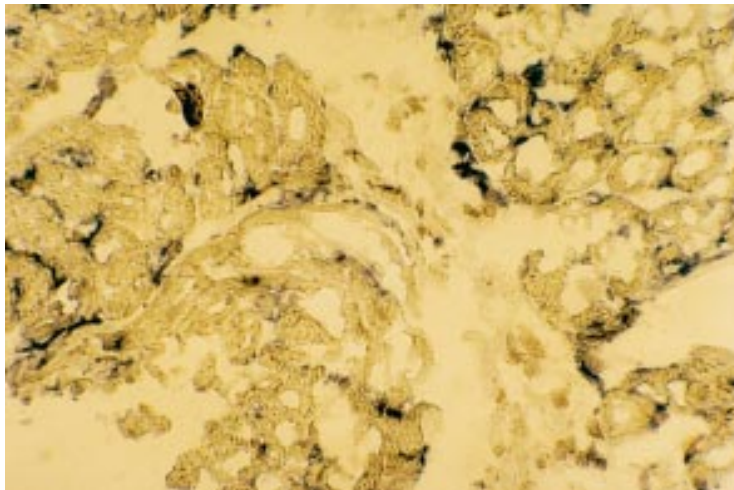


Figure 1 Immunostaining for CD T200 lymphocytes.

Discussion

To the best of our knowledge this report is the first description of a biopsy proven active myocarditis in an adult caused by varicella zoster infection. Tsintsof and colleagues⁴ previously described a biopsy proven varicella myocarditis in a 12 year old girl with progressive heart failure necessitating heart transplantation. Since suspected varicella myocarditis in children as well as in adults may be associated with several severe complications, including progressive heart failure as well as malignant arrhythmias and sudden death, the consensus is that these patients should receive medical intensive care.^{2-3 5-10} Owing to the rarity of this disease, however, there are no generally accepted therapeutic guidelines for varicella myocarditis. The patient in the present report was treated with a combination of aciclovir, specific hyperimmunoglobulins, and an NSAID which resulted in complete recovery after two months.

- 1 Marboe DD, Fenoglio JJ. Pathology and natural history of human myocarditis. *Pathol Immunopathol Res* 1988;7:226.
- 2 Fiddler GI, Campbell RW, Pottage A, et al. Varicella myocarditis presenting with unusual ventricular arrhythmias. *Br Heart J* 1977;39:1150-3.
- 3 Senellart F, Bozio A, Sassolas F, et al. Varicella myocarditis and junctional ectopic tachycardia. *Pediatrics* 1991;46:267-70.
- 4 Tsintsof A, Delprado WJ, Keogh AM. Varicella zoster myocarditis progressing to cardiomyopathy and cardiac transplantation. *Br Heart J* 1993;70:93-5.
- 5 Ettegui J, Ladusans E, Bamford M. Complete heart block as a complication of varicella. *Int J Cardiol* 1987;14:362-5.
- 6 Lorber A, Zonis Z, Maisuls E, et al. The scale of myocardial involvement in varicella myocarditis. *Int J Cardiol* 1988;20:257-62.
- 7 Bachli E, Kagi MK, Krause M. Visceral and neurological complications in varicella infections of adults. *Schweiz Med Wochenschr* 1996;126:440-6.
- 8 Noren GR, Tobin JD, Staley NA, et al. Association of varicella, myocarditis, and congestive cardiomyopathy. *Pediatr Cardiol* 1982;3:53-7.
- 9 Coppack SW, Doshi R, Ghose AR. Fatal varicella in a healthy young adult. *Postgrad Med J* 1985;61:529-31.
- 10 Noriega Peiro F, Costas Alonso MI, Vilar Freire M, et al. Acute myocarditis caused by varicella virus. *Rev Esp Cardiol* 1998;51:677-9.