

Short reports

Silicone lymphadenopathy mimicking a lymphoma in a patient with a metatarsophalangeal joint prosthesis

M Péoc'h, D Duprez, G Grice, B Fabre-Bocquentin, R Gressin, B Pasquier

Abstract

With lymph node enlargement, the possibility of a malignant process such as metastatic carcinoma or lymphoma needs to be excluded. This report describes a 47 year old woman with inguinal lymph node enlargement initially suspicious for lymphoma. Fine needle aspiration findings favoured reactive hyperplasia, but a malignant process could not be excluded. The final histological diagnosis was a foreign body granulomatous inflammatory response as a result of regionally disseminated silicone particles from an over looked metatarsophalangeal joint prosthesis. Because of the large number of joint prostheses world wide, it should be kept in mind that migration of wear particles can create granulomatous inflammation and node enlargement.

(J Clin Pathol 2000;53:549-551)

Keywords: lymphadenopathy; silicone; prosthesis

Although complications associated with the use of joint prostheses are recognised in the orthopaedic literature, they are less well recognised by physicians in other specialties. The production of wear debris after arthroplasty has been widely reported and inflammatory responses to biomaterials are still described.¹ Metal, silicone elastomers, and polyethylene are the biomaterials most commonly implicated. In tissues found adjacent to implants there is often a histiocytic reaction. Wear debris commonly disseminates to lymph nodes,² whereas systemic dissemination with granulomatous reaction is less frequent.³ The same lymph node may harbour both granulomatous inflammation, as a result of wear particles, and metastatic carcinoma or lymphoma. Our present case draws attention to the fact that the possibility of lymph node enlargement as a result of silicone wear particles from a 15 year old arthroplasty was not elicited in the initial evaluation for lymphadenopathy.

Case report

A 47 year old woman presented in October 1997 with left inguinal lymph node enlargement. She denied any fevers, chills, or other systemic symptoms. The only finding on

physical examination was an enlarged, non-inflamed, mobile lymph node. Since 1992, she had been receiving gold salts and non-steroid anti-inflammatory drugs for rheumatoid arthritis. She underwent a fine needle aspiration of the enlarged lymph node and reactive hyperplasia was favoured, but a malignant process could not be excluded. One year later, she noted an increase in the size of the lymph node. The lymph node was surgically excised and submitted for pathological evaluation.

The specimen consisted of a lymph node, approximately 25 mm in diameter, with a light tan appearance and a homogeneous consistency on cut section. The specimen was separated into several portions. One segment was fixed in formalin, embedded in paraffin wax, and processed for light microscopy and immunohistochemistry. Another portion was frozen. Another segment was processed for cytogenetic and flow cytometry evaluation. The formalin fixed sections were stained with haematoxylin erythrosin saffron (HES), Giemsa, periodic acid Schiff, Perls, and for CD20, CD3 and BCL-2 (all from Dako, Glostrup, Denmark) using the streptavidin-biotin method. The frozen sections were stained with oil red O. There was no abnormality on cytogenetic examination and no monoclonality detected in flow cytometry. The histological examination showed follicular hyperplasia and numerous multinucleated foreign body giant cells within sinuses and interfollicular spaces (fig 1). The immunohistochemistry study

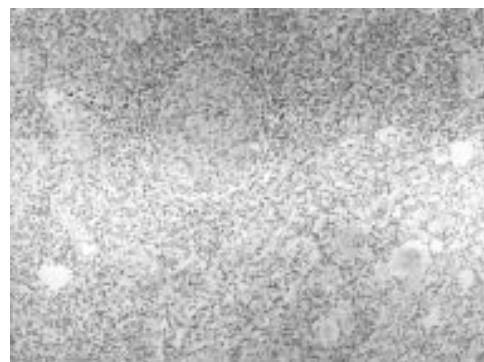

Figure 1 Lymph node with germinal centre surrounded by sinuses filled with numerous multinucleated foreign body giant cells containing refractile silicone particles (haematoxylin erythrosin saffron stain; magnification, $\times 100$).

Department of Pathology, Centre Hospitalier Universitaire, Grenoble 38043, France

M Péoc'h
B Fabre-Bocquentin
B Pasquier

Department of Haematology, Centre Hospitalier Universitaire R Gressin

Department of Surgery, Centre Hospitalier Region Annecienne, Annecy, France
D Duprez

Armed Forces Institute of Pathology, Washington DC, USA
G Grice

Correspondence to: Dr Peoc'h, Service d'Anatomie Pathologique, CHU, BP 217, 38043 Grenoble cedex 09, France
email: Michel.Peoch@ujf-grenoble.fr

Accepted for publication 7 December 1999

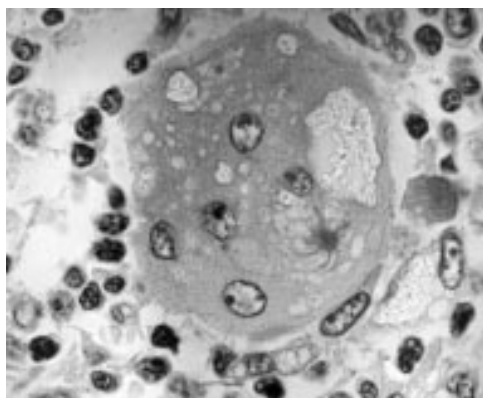


Figure 2 Multinucleated giant cells containing intracytoplasmic asteroid bodies and refractile silicone particles (haematoxylin erythrosin saffron stain; magnification, $\times 1000$).

showed normal compartmentalisation of B cells (mainly in the follicular centre) and T cells (in the interfollicular space). BCL-2 immunostaining showed negativity of the B cell population within the hyperplastic follicles. Many of the giant cells contained irregular particles of refractile material as well as asteroid bodies (fig 2). The particles showed a mean diameter of 24 μm ; the largest measured particle was 40 μm in diameter. These particles were not doubly refractile under polarised light and special stains were negative. The histological appearance of these particles was suggestive of silicone, so we queried the patient about this possibility. She related that she had a left metatarsophalangeal joint prosthesis, which was placed 15 years ago for a bone deformity (hallux valgus). It was a Swanson silastic prosthesis, for which plain film radiographs did not reveal any evidence of damage.

Discussion

Silicone elastomer arthroplasties for joint diseases involving the small joints of the hands and feet have been used worldwide since the late 1960s. Medical silicones, or polydimethylsiloxane, can be formulated in different ways, resulting in materials of varying structures and consistencies, which can be individually tailored for different body parts. For example, elastomers are used for joint prostheses, gel for breast implants, and liquid for soft tissue injection. As in joint prostheses,¹ a local granulomatous reaction can be encountered for the different physical forms of silicone applied in medicine. In fact, such a reaction is found in breast⁴ and testicular,⁵ implants as well as in subcutaneous injections.⁶ In such cases, it is important to realise that silicone leakage can migrate to a location far from the site of application and can lead to—for example, regional lymphadenopathy, which might be clinically relevant. As in the few cases reported previously, in our present case, the adenopathy was initially thought to be caused by malignancy or infection. Further investigation disclosed that foreign material might be the cause.

The frequency of lymphadenopathy after this common procedure is still difficult to establish. In a study of 23 cases of silastic arthroplasty it

was shown that silicone lymphadenopathy may be a frequent complication (13%).⁷ However, in a review of the literature regarding long term complications of 15 556 small joint implants, lymphadenopathy as a result of wear debris was reported in only 13 cases (0.08%).⁸

A history of previous silastic arthroplasty might not always be available to the clinician (much less to the pathologist), but the histological appearance is sufficiently characteristic to prompt an appropriate inquiry. The chemical identity can be confirmed by infrared imaging spectroscopy or by electron microscopy coupled with energy dispersive x ray analysis. This case emphasises the long latency period that can be associated with this clinical phenomenon, which may mimic other, more serious, diseases. Fine needle aspiration cytology can be useful in the diagnosis of such lymphadenopathy, if it shows a foreign body giant cell reaction to particulate matter morphologically compatible with silicone elastomer.⁹ In our case, retrospective review of the original cytology slides failed to identify any pronounced pathology. With currently increasing numbers of silastic joint arthroplasties performed for rheumatoid arthritis or bone deformity, silicone lymphadenopathy should always be considered in the differential diagnosis of node enlargement. Uncommonly, there may be an associated malignant process. A review of the reports of concurrent malignant tumour cells and exogenous silicone particles in the same lymph node has shown that lymphoma is usually found with particles from joint prostheses,¹⁰⁻¹³ and carcinoma with particles from breast implants.¹⁴ All of the patients with both joint prosthesis related lymphadenopathy and non-Hodgkin's lymphoma had longstanding rheumatoid arthritis. Patients with rheumatoid arthritis are at an increased risk of developing malignant lymphoma, compared with the general population. They form the population most likely to be treated with Swanson joint implants. Therefore, the presence of silicone joint implants in patients with rheumatoid arthritis and lymphoma might be a concomitant rather than a causal finding.⁸ Similarly, follicular hyperplasia, as initially seen in the present case, is more likely to be a manifestation of rheumatoid arthritis than a response to foreign material.

The long term outlook in terms of foreign body reaction is reported to be very good, but the first reported case of silicone lymphadenopathy associated with a finger joint implant had a recurrence in an ipsilateral node four years later.¹⁵ Therefore, it is recommended that prostheses should be replaced if they result in pronounced lymphadenopathy as a result of migrating wear debris.

- 1 Tang L, Eaton JW. Inflammatory responses to biomaterials. *Am J Clin Pathol* 1995;103:466-71.
- 2 Albores-Saavedra J, Vuitch F, Delgado R, et al. Sinus histiocytosis of pelvic lymph nodes after hip replacement. *Am J Surg Pathol* 1994;18:83-90.
- 3 Peoc'h M, Moulin C, Pasquier B. Systemic granulomatous reaction to a foreign body after hip replacement. *N Engl J Med* 1996;335:133-4.
- 4 van Diest PJ, Beekman WH, Hage J. Pathology of silicone leakage from breast implants. *J Clin Pathol* 1998;51:493-7.
- 5 Hage JJ, van Amerongen T, van Diest PJ. Rupture of silicone gel filled testicular prosthesis: causes, diagnostic modalities and treatment of a rare event. *J Urol* 1999;161:467-71.

- 6 Travis WD, Balogh K, Abraham JL. Silicone granulomas: report of three cases and review of the literature. *Hum Pathol* 1985;16:19-27.
- 7 Lazaro MA, Garcia-Morteo D, de Benyacar MA, et al. Lymphadenopathy secondary to silicone hand joint prostheses. *Clin Exp Rheumatol* 1990;8:17-22.
- 8 Foliart DE. Swanson silicone finger joint implants: a review of the literature regarding long-term complications. *J Hand Surg [Am]* 1995;20:445-9.
- 9 Tabatowski K, Sammarco GJ. Fine needle aspiration cytology of silicone lymphadenopathy in a patient with an artificial joint. *Acta Cytol* 1992;36:529-32.
- 10 Digby JM. Malignant lymphoma with intranodal silicone rubber particles following metacarpophalangeal joint replacement. *Hand* 1982;14:326-8.
- 11 Benjamin E, Ahmed A, Rashio ATMF, et al. Silicone lymphadenopathy: a report of two cases, one with concomitant malignant lymphoma. *Diagn Histopathol* 1982;5:133-41.
- 12 Schneid AR, Taylor TH, Groff GD. Complications of silicone implant. *JAMA* 1985;253:635.
- 13 Murakata LA, Ruagwala AF. Silicone lymphadenopathy with concomitant malignant lymphoma. *J Rheumatol* 1989;16:1481-3.
- 14 Truong LD, Cartwright MD, Goodman MD, et al. Silicone lymphadenopathy associated with augmentation mammoplasty. *Am J Surg Pathol* 1988;12:484-91.
- 15 Christie AJ, Weinberger KA, Dietrich M. Recurrence of silicone lymphadenopathy. *JAMA* 1981;245:1314.

MP

MOLECULAR
PATHOLOGY

Contents

June 2000 Vol 53 No 3

Review

- 111 Demystified ... Monoclonal antibodies *P N Nelson, G M Reynolds, E E Waldron, E Ward, K Giannopoulos, P G Murray*

Papers

- 118 Genetic relation of lobular carcinoma in situ, ductal carcinoma in situ, and associated invasive carcinoma of the breast *H Buerger, R Simon, K-L Schäfer, R Diallo, R Littmann, C Poremba, P J van Diest, B Dockhorn-Dworniczak, W Böcker*
- 122 Expression of π -class glutathione S-transferase: two populations of high grade prostatic intraepithelial neoplasia with different relations to carcinoma *R Montironi, R Mazzucchelli, D Stramazzotti, R Pomante, D Thompson, P H Bartels*
- 129 Interphase argyrophilic nucleolar organiser regions and nucleolar counts in transitional cell bladder tumours *I A Korneyev, N N Mamaev, V V Kozlov, M G Rybakova, S H Al-Shukri*
- 133 Telomerase activity in pancreatic endocrine tumours: a potential marker for malignancy *K Y Lam, C Y Lo, S T Fan, J M Luk*
- 137 Role of chromosome 3p12-p21 tumour suppressor genes in clear cell renal cell carcinoma: analysis of VHL dependent and VHL independent pathways of tumorigenesis *A Martinez, P Fullwood, K Kondo, T Kishida, M Yao, E R Maher, F Latif*
- 145 Expression of the matrix metalloproteinase 9 in Hodgkin's disease is independent of EBV status *J R Flavell, K R N Baumforth, D M Williams, M Lukesova, J Madarova, V Noskova, J Prochazkova, D Lowe, Z Kolar, P G Murray, P N Nelson*
- 150 Detection of clonal T cell populations by high resolution PCR using fluorescently labelled nucleotides; evaluation using conventional LIS-SSCP *C L Wickham, C Lynas, S Ellard*
- 155 Immunoblotting can help the diagnosis of ocular toxoplasmosis *D O Ho-Yen, D J Chapman, D Ashburn*

Short report

- 159 Selective genetic analysis of p53 immunostain positive cells *M Phelps, B S Wilkins, D B Jones*

Miscellanea

- 162 Correspondence • Book reviews • Notice