

## Age related changes in the tunica media of the vertebral artery: implications for the assessment of vessels injured by trauma

C P Johnson, R Baugh, C A Wilson, J Burns

### Abstract

**Aims**—To provide an illustrated, detailed semiquantitative analysis of the important degenerative changes along the length of the vertebral artery so that pathologists faced with investigating a fatal arterial injury can identify important pre-existing wall abnormalities.

**Methods**—Ten transverse annuli were taken along 34 vertebral arteries from 17 subjects and stained sections were prepared using haematoxylin and eosin and the picro-sirius red method. After routine microscopy, the elastic fibres, collagen, and smooth muscle nuclei in the tunica media were quantified using an eyepiece graticule. An estimate of the severity and extent of elastic tissue fragmentation, collagenous scarring, and intimal thickening/atheroma was then undertaken.

**Results**—Smooth muscle counts remained constant along the artery but collagen counts were higher and elastic counts substantially lower within the intracranial segment. Elastic fibre fragmentation was recognised in infancy and was moderately advanced by early adulthood but considerable collagenous scarring developed later in life. Some individuals demonstrated severe fragmentation and scarring before the age of 35 years. The degenerative changes were often focal and spared the intracranial segment almost completely. Atheroma increased with age but was rarely severe and appeared not to worsen appreciably beyond the age of 40 years. An unusual arrangement of the collagenous tissue was described within the upper cervical loops.

**Conclusion**—Damaged vertebral arteries need to be sampled extensively to allow a proper histological assessment. The picro-sirius red method was successful in delineating the fine connective tissue structure of the wall and early degenerative changes. An understanding of the age and site specific changes should allow the pathologist to recognise important pre-existing abnormalities more easily.

(*J Clin Pathol* 2001;54:139–145)

Keywords: vertebral artery; picro-sirius red; degenerative change; injury

The vertebral artery can become damaged by several types of trauma including road traffic accidents, sporting accidents, therapeutic neck manipulation, and blows to the head and neck.<sup>1–7</sup> The mechanism of arterial injury is

often not entirely clear and may be multifactorial, although in some cases there appears to be a close association with head and neck movements. Dissecting aneurysms or thrombosis appear to be the cause of vertebro-basilar insufficiency after neck manipulation and the clinical outcome is often poor, with severe long term neurological disability and death affecting some 30% of cases. The vascular tearing associated with traumatic basal subarachnoid haemorrhage, after blows to the head and neck, is usually rapidly fatal and such cases continue to cause problems for the pathologist, not least because simply identifying the source of bleeding can be difficult. Not only are vertebral arteries rarely damaged when one considers how frequently physical altercations occur, but some injuries can follow apparently minor trauma (DJ Gee. Proceedings of the 12th Congress of the International Academy of Forensic and Social Medicine 1982:495–8). This suggests that some individuals are more prone to vertebral artery damage. We have previously considered the possible relevance of variations in the shape and size of the protective upper cervical vertebral artery loops<sup>8</sup> and biomechanical behaviour<sup>9</sup> in influencing outcome. However, an important additional factor must be the condition of the artery wall before the insult occurred. It is unclear what role this may play when considerable blunt trauma is applied, but occasional cases of medial cystic necrosis and vascular dysplasia have been reported in association with the development of dissecting aneurysms after minor neck trauma.

Most published cases of traumatic subarachnoid haemorrhage do not include a histological description and the thorough sampling of the vessel, which has been advocated by Vanezis,<sup>10</sup> is probably rarely undertaken in practice. Because the extracranial course of the vertebral artery is not examined routinely at necropsy, it is probable that most pathologists are unfamiliar with the normal variations in histological appearance along the vertebral artery, making it difficult to provide an opinion on the underlying state of an injured vessel. This may be of medicolegal importance, not only in cases that follow assault, but when it is claimed that a practitioner, such as a chiropractor, has been negligent. The presence of a pre-existing structural abnormality may indicate that a tear could have followed the application of relatively minor force, or that a dissecting aneurysm was a spontaneous event, unrelated to a clinical procedure. Such factors may become important in any subsequent legal proceedings. To

Sub-Department of Forensic Pathology, University of Liverpool, Duncan Building, Daulby Street, Liverpool L69 3GA, UK  
C P Johnson  
R Baugh  
C A Wilson  
J Burns

Correspondence to: Dr Johnson

Accepted for publication 23 August 2000

redress this state of affairs, we have undertaken a detailed semiquantitative study of the vertebral artery, concentrating on the components of the tunica media. The results of the assessment of proteoglycan accumulation along with the histomorphometry of the vessel wall were described previously.<sup>11 12</sup>

### Methods

Thirty four vertebral arteries were excised at necropsy, as described previously,<sup>11</sup> from 17 subjects, aged 9 months to 84 years. There was no known history of hypertension, diabetes mellitus, or cerebrovascular disease.

Ten transverse annuli, approximately 0.5 cm long, were taken from each artery at the sites indicated in fig 1. The specimens were rinsed in saline to remove any blood and then fixed in 10% formol saline for 12 hours. Routine processing and embedding was undertaken and 5 µm tissue sections were cut. A section was stained with haematoxylin and eosin and another with the picro-sirius red method. This method stains the elastic fibres black, the collagen red, and the muscle, red cells, and other components yellow. The modification was found to improve dramatically the delineation of the collagenous components of the vessel wall when compared with standard connective tissue stains.

The general changes in the structure of the wall with age, particularly those of the tunica

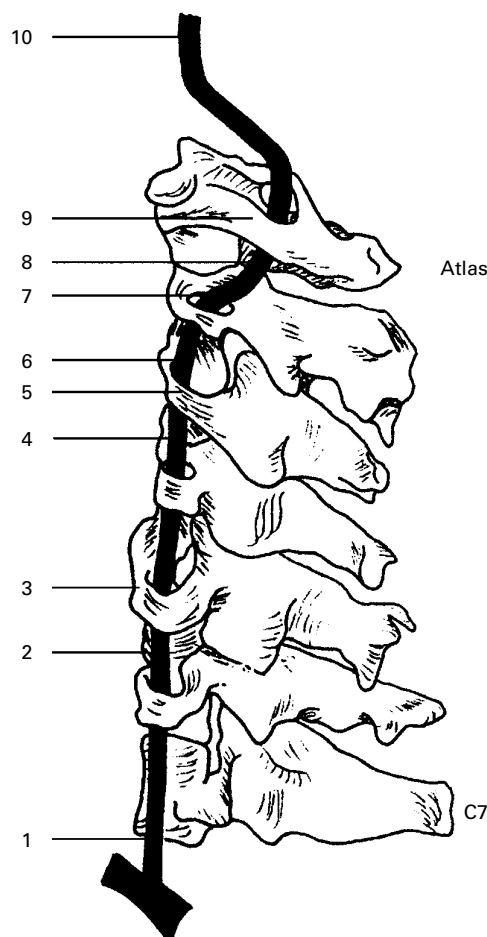


Figure 1 Sites from which the annuli were taken.

media, were studied using routine light microscopy at a total of 340 different arterial levels. A qualitative and semiquantitative analysis was then made of the elastic fibres, collagen, and smooth muscle nuclei within the tunica media of each annulus, the number of fields required being estimated using Chalkey's method of accumulating means. The grade of elastic fibre fragmentation, collagen scarring, and intimal thickening was then assessed.

### QUANTITATION OF ELASTIC FIBRES AND COLLAGEN FIBRES

Picro-sirius red sections were examined under an oil immersion lens ( $\times 100$ ) of a Leitz labophot microscope using an eyepiece graticule (E11, 21 mm, 1 mm grid; Graticules Ltd, Tonbridge, Kent, UK). At this magnification the graticule field fitted neatly over the tunica media. The first field was selected at random and 10 adjacent fields were examined sequentially. Formed elastic fibres that fell directly beneath grid intersections were counted as positive points. After this, collagen fibres and scars that fell directly beneath grid intersections were counted as positive points.

### QUANTITATION OF SMOOTH MUSCLE NUCLEI

This was undertaken on the haematoxylin and eosin stained sections using the same graticule and method as that described above. Smooth muscle nuclei that fell directly beneath grid intersections were counted as positive points.

### GRADING OF ELASTIC FIBRE FRAGMENTATION

The degree of elastic fibre fragmentation was assessed using a simple four point grading system depending on the appearances of the elastic fibres in the tunica media of each picro-sirius red stained tissue section. The grade was allocated depending on the most advanced fragmentation that was present.

Grade E<sub>0</sub>: no appreciable elastic fragmentation with a normal lamellar structure.

Grade E<sub>1</sub>: early focal fragmentation but with a preserved lamellar structure.

Grade E<sub>2</sub>: established, moderately advanced fragmentation but with a largely preserved lamellar structure.

Grade E<sub>3</sub>: severe fragmentation often with complete disruption of the lamellar structure in whole segments of the section.

### GRADING OF COLLAGEN DISORGANISATION

This was assessed on the picro-sirius red stained sections using a simple four point grading system. The grade allocated depended on the most advanced disorganisation that was present.

Grade C<sub>0</sub>: normal lamellar structure of orientated fibres.

Grade C<sub>1</sub>: focal disruption of lamellar organisation with condensation and some disarray of collagen.

Grade C<sub>2</sub>: small "scars" present extending across adjacent lamellae.

Grade C<sub>3</sub>: moderate to severe disruption with larger areas of scarring.

#### GRADING OF INTIMAL THICKENING/ATHEROMA ("ATHEROMA GRADE")

This was assessed on the picro-sirius red stained sections using a simple four point grading system.

Grade  $A_0$ : no intimal thickening.

Grade  $A_1$ : 0–30% narrowing of lumen by intimal thickening/atheroma.

Grade  $A_2$ : 30–50% narrowing of lumen by intimal thickening/atheroma.

Grade  $A_3$ : > 50% narrowing of lumen by intimal thickening/atheroma.

#### Results

The adventitial tissues were composed of varying proportions of collagen and elastic fibres, being most dense around the origin of the vertebral arteries from the subclavian artery and also just proximal to the meninges. The fibres were often more condensed adjacent to the tunica media (creating the variably formed external elastic lamina), being arranged in a looser fashion peripherally. The external elastic lamina was much less dense and often not discernible intracranially. Our study concentrated on the tunica media because of the major contribution this plays in the biomechanical behaviour of the vessel.

Figures 2–4 show the results of the grading of the "atheroma". There is an age related increase in the severity of atheromatous thickening, with only the very young demonstrating minimal involvement. Note that there appears to be no substantial increase in thickening after the subjects reach the age of 20–40 years. There was no specific level along the artery that appeared to be more prone to the development of atheroma, and higher grades ( $A_2$  and  $A_3$ ) were distinctly uncommon in this series of arteries.

The elastic tissue in the tunica media appeared to be arranged as fibres predominantly in a circumferential (circular) manner with tiny fibrils also evident (fig 5A) and there was a close lamellar arrangement with the collagen fibres (fig 5B). The internal elastic lamina was dense along the whole artery. Breaks in this structure were commonplace, even in the very young (fig 5C), and in the absence of associated pathology (for example, pronounced atheroma, fibrosis, elastic fibre fragmentation) were considered of no relevance and possibly a processing artefact. The elastic fibre counts (fig 6) demonstrate that

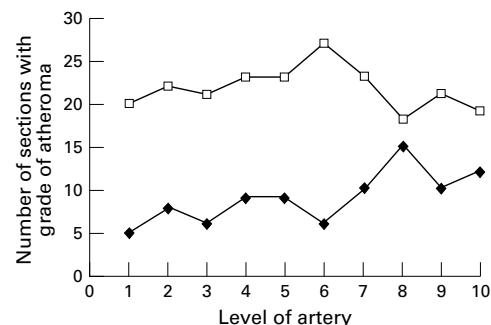


Figure 2 Graph showing lower grades of atheroma along the artery. Closed diamonds,  $A_0$ , open squares,  $A_1$ .

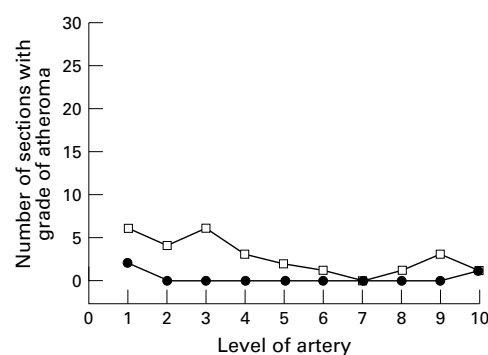


Figure 3 Graph showing higher grades of atheroma along the artery. Open squares,  $A_2$ ; closed circles,  $A_3$ .

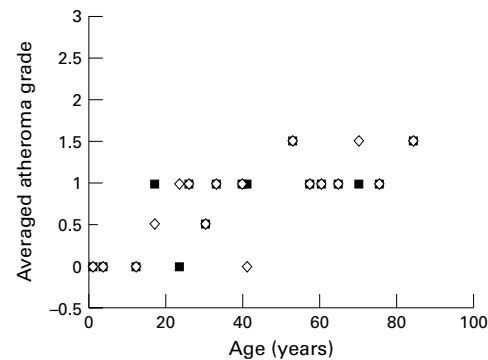


Figure 4 Graph showing the effect of age on the grade of atheroma. Closed squares, left artery; open diamonds, right artery.

there was slightly more elastic tissue (being in fact also visibly thicker) at the origin of the vertebral arteries than in most of the remainder of the extracranial course, but that there was a striking, apparently universal, diminution in the elastic fibre counts within the intracranial portion, also seen in fig 5D. No change in the elastic counts occurred with age. However, elastic fibre fragmentation occurred even in infancy, being recognisable as breaks in the laminae in some of the tissue sections from the 9 month old subject. Mild degrees of fragmentation were almost universal from the age of 4 years onwards. There was an obvious age related increase in the severity and extent of the elastic fragmentation (fig 7) with mild to moderate degrees usually present by the age of 20 years (fig 8A). Some individuals showed advanced fragmentation and disruption within the extracranial portion before the age of 40 years associated with severe scarring (fig 8B). Beyond this age, focal or diffuse areas of severe fragmentation became commonplace. Figures 9 and 10 show that moderate to advanced elastic fragmentation is frequently present in the extracranial segment but is exceptional (involving only four sections) within the intracranial segment, where no fragmentation or mild fragmentation is the normal finding. Even when there is widespread, severe fragmentation involving the extracranial segment, the intracranial segment remains largely unaffected by the degenerative process. Severe degenerative changes may be limited to certain levels of the vessel and, indeed, only to parts of the wall annulus (being "focal and segmental").

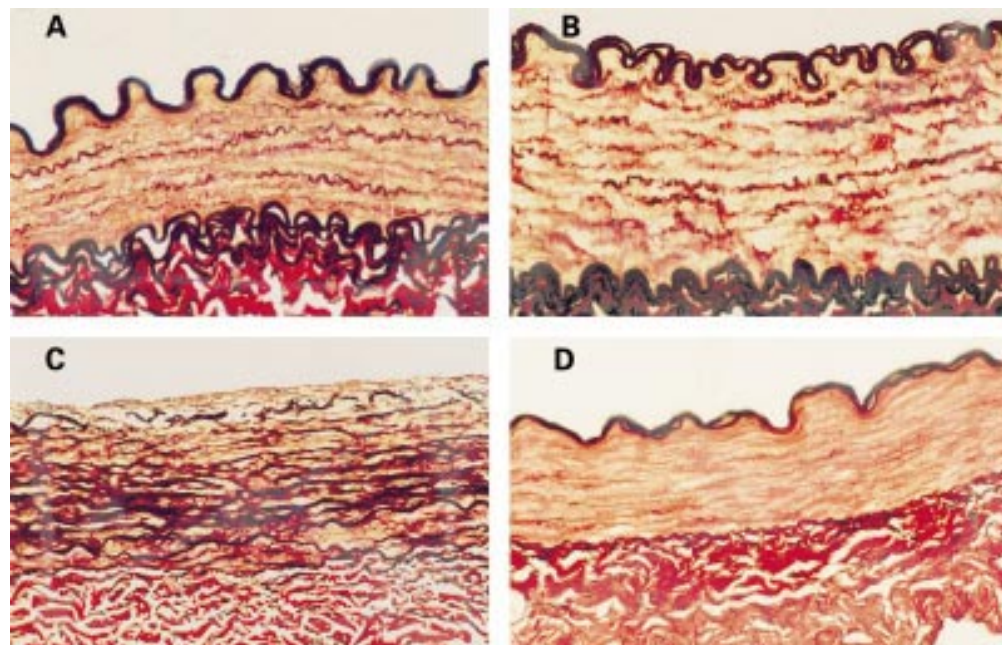


Figure 5 (A) Transverse extracranial vertebral artery section from a 9 month old child showing well formed internal and external elastic lamina, the circumferential arrangement of the elastic fibres, and an absence of fragmentation and scarring. (B) Extracranial vertebral artery section from a 4 year old child. Note the close relation between the elastic fibres and collagen. The fine architecture is evident as is the absence of fragmentation or scarring. (C) Section of extracranial vertebral artery from a 9 month old child showing early intimal thickening and obvious breaks in the internal elastic lamina. (D) Typical intracranial vertebral artery transverse section (age 12 years) showing very little elastic tissue in the tunica media and a poorly formed external elastic lamina (all stained with picro-sirius red).

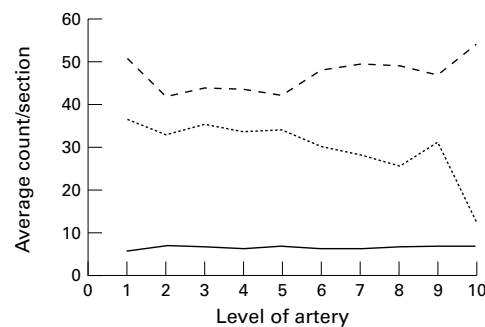


Figure 6 Graph showing the average count/section along the artery for elastic fibres (small dashes), collagen fibres (large dashes), and smooth muscle nuclei (continuous line). The changes along the vessel are clearly demonstrated and are most striking at the origin and as the vessel becomes intracranial.

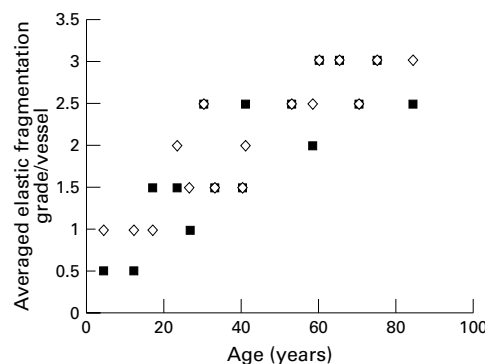


Figure 7 Graph showing the age related increase in elastic fibre fragmentation. Closed squares, left artery; open diamonds, right artery.

The collagen fibres were arranged in a predominantly circumferential (circular) manner around the tunica media, largely in

lamellae with the elastic tissue, and showed smaller collagen fibrils extending haphazardly, and at right angles, between the larger fibres. This was clearly delineated by the picro-sirius red method (fig 5A and B). The number and the thickness of the collagen fibres varied between subjects and between vessels from the left and right sides of the neck. Point counts remained fairly constant along the length of the artery but with higher counts at the origin and within the intracranial segments (fig 6). However, the fibres were usually finer and more uniformly distributed intracranially. Early scarring was not seen in vessels from the very young but was focally evident in most sections by the age of 17 years. Small collagen scars can be difficult to distinguish from the normal variation in the thickness of collagen fibres but the disruption of the lamellae, the amorphous nature, and the irregularity of the scar edge are helpful features (fig 11). Once the scars extended across several lamellae they became easy to recognise (fig 8B). The development of wall scarring appeared to "lag" behind the elastic fragmentation, being minimal or absent in the young vessel but more closely associated in subjects over the age of 60 years, when advanced degenerative changes were usual. This age related increase in scarring is demonstrated in fig 12. Site specific changes were also evident, with the most important relating to the almost total absence of scarring within the intracranial segment (data not shown). Only four of 340 sections showed mild (C<sub>1</sub>) scarring, with the remainder being completely unaffected. Care must be taken when interpreting the structure of the upper cervical loop segments because dense, irregular sheets of collagen can be seen in

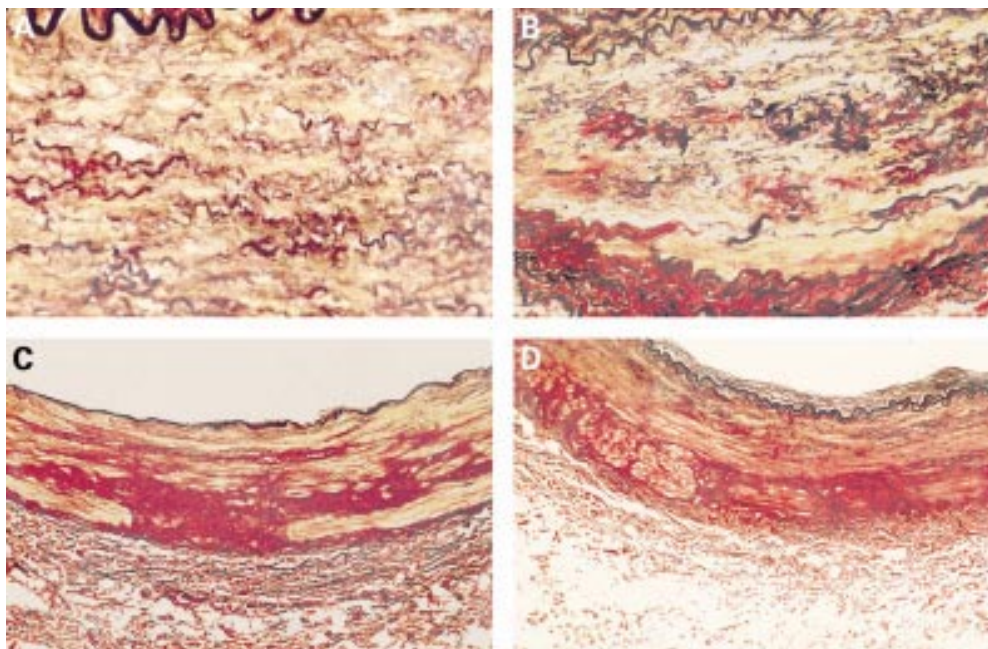


Figure 8 (A) Extracranial vertebral artery transverse section from a 17 year old subject, showing mild to moderate elastic fibre fragmentation ( $E_1$ - $E_2$ ). (B) Extracranial vertebral artery section from a 33 year old subject. Note the advanced elastic fibre fragmentation ( $E_3$ ) and severe collagen scarring ( $C_3$ ). (C) Transverse vertebral artery section from the upper cervical loop segment of a 30 year old subject. Note the very dense distribution of collagen extending from the adventitia into the media. (D) Transverse vertebral artery section from the upper cervical loop segment of a 33 year old subject. Again, note the unusual arrangement of peripheral collagen extending from the adventitia (all stained with picro-sirius red).

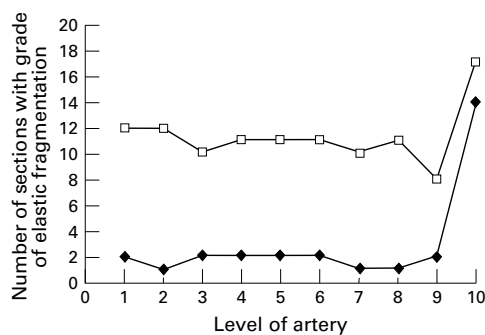


Figure 9 Graph showing the number of sections with lower grades of elastic fragmentation along the artery. Note the change as the vessel becomes intracranial (level 10). Closed diamonds,  $E_2$ ; open squares,  $E_1$ .

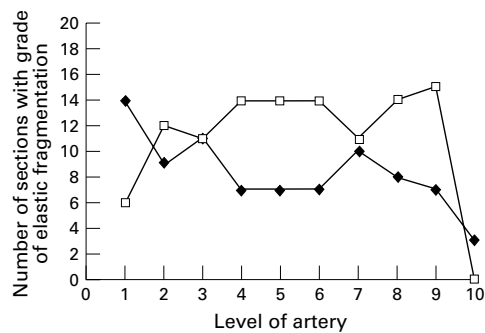


Figure 10 Graph showing the number of sections with higher grades of elastic fragmentation along the artery. Note the change as the vessel becomes intracranial (level 10). Closed diamonds,  $E_3$ ; open squares,  $C$ .

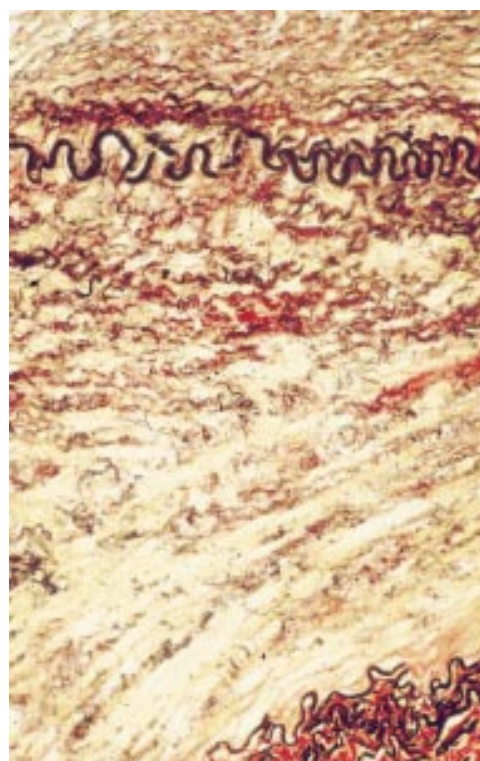


Figure 11 Transverse section of extracranial vertebral artery from a 60 year old subject showing moderate elastic fragmentation ( $E_3$ ) and two foci of early scarring ( $C$ ). (Stained with picro-sirius red.)

normal vessels extending from the adventitial tissues into the tunica media, an appearance that does not represent true dysplasia (fig 8C and D). This may be partly the result of cross cutting and orientation of the specimens but, in

our view, is largely structural, explainable on the basis of the abrupt changes in the course of the vessel around the atlas and axis.

The smooth muscle cells appeared to be orientated mainly in a circumferential manner, broadly in parallel with the elastic fibres. Focal

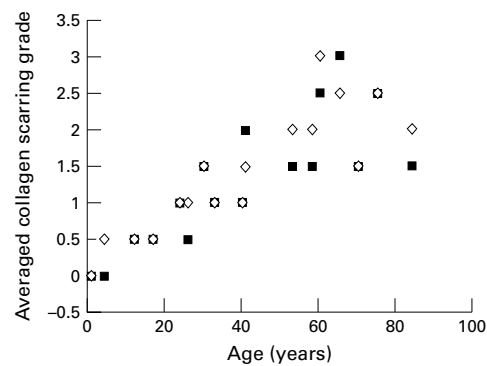


Figure 12 Graph showing age related increase in the severity of collagenous scarring. Closed squares, left artery; open diamonds, right artery.

disorientation of the nuclei was seen in some instances when degenerative changes were pronounced and also with the dense collagenous changes around the upper cervical loops. Smooth muscle nuclei counts remained constant along the artery (fig 6) and there was no significant fall in counts with increasing age of the subject.

### Discussion

Vertebral artery tears after blows to the head and neck are usually associated with basal subarachnoid haemorrhage and a rapidly fatal outcome. These are uncommon, making up some 0.1% of all medicolegal necropsies in Denmark from 1967 to 1981,<sup>7</sup> and 0.12% of such necropsies in southern Alberta.<sup>13</sup> Fatal vertebral artery dissections and luminal thrombosis, following various head and neck insults, are rarely associated with subarachnoid haemorrhage, with the clinical course being more often prolonged, allowing time for some investigations, such as angiography, to be undertaken before death occurs. Even then, problems in identifying the site of vascular damage can occur, particularly if the site is inaccessible and obscured by blood. Depending on the circumstances, a histological examination may be helpful in confirming that a putative tear is genuine and not caused artefactually during dissection. The histology may also indicate the age of the injury but, most importantly, allows the pathologist to assess the pre-existing state of the vessel wall.

Such pre-existing abnormalities may become important in the subsequent medicolegal process. The pathologist, wanting to form a balanced opinion in these matters, faces several problems. The first concerns his own experience of vertebral artery histology. Given the rarity of the injury, it may be that the opportunity, or need, has not arisen to examine other vertebral arteries before being presented with a difficult case. The literature will provide limited help with degenerative disease processes involving the vertebral artery.

Hutchinson and Yates<sup>14</sup> undertook a clinicopathological study of 48 subjects, with most of the cases being investigated by postmortem angiography and dissection, after defleshing and decalcification. They were interested primarily in the effects of cervical spondylosis

and atherosclerosis on luminal stenosis. Stenosing atheroma was present in 19 of the 48 subjects. Histology was undertaken, but the published description of the findings was limited to confirming or documenting the presence of atheroma and to describing a single case of cystic medial necrosis.

A more detailed histological approach was adopted by Wilkinson,<sup>15</sup> who studied the structure of 20 vertebral arteries removed from 10 persons aged 60–75 years, at several levels of the artery including sections from the extracranial course and, in particular, sections from the vessel as it penetrated the dura. The author describes the structure of the vertebral artery as unchanged from its origin, through the bony course, up to a point 1 cm proximal to dural perforation. During this length, the vessel had a well developed adventitia and an underlying thick elastic lamina, with a broad tunica media consisting of smooth muscle, collagen, and elastic fibres. However, striking changes occurred as the vessel penetrated the dura, becoming thinner, with a diminution of adventitial collagen and the external elastic lamina becoming either completely absent, or represented by sparse fibrils.

This transition in structure was confirmed by Coast and Gee<sup>5</sup> and by Winckler.<sup>16</sup> The latter study described a circular arrangement of the smooth muscle cells and elastic fibres within the media, but both an inner circular and outer longitudinal arrangement of the elastic fibres within the adventitia.

Piffer and Zorzetto<sup>17</sup> studied the histological structure within the suboccipital and intracranial segments in four cadavers and found a similar arrangement of the wall components. The relation between the vertebral artery and the adjoining tissue was considered by Chopard *et al*,<sup>18</sup> who found the vessel to be enveloped in bundles of delicate collagen fibres, which formed continuous laminae extending to the periosteum of the cervical vertebra and the fascia of the intertransverse muscles.

Although these studies have contributed greatly to the understanding of the transitional nature of the vertebral artery, they provide insufficient help to the pathologist faced with examining a damaged vessel. This is why we undertook our systematic semiquantitative study based on principles similar to an earlier study on the human aorta.<sup>19</sup> We were able to confirm many of the earlier observations concerning the structure of the vertebral artery but, in addition, we have described the important degenerative changes occurring at each level of the vessel. Key observations include the early development of degenerative features, such as elastic tissue fragmentation and collagenous scars in the young, and the virtual absence of such changes within the intracranial segment. Often the vessel shows only very focal degeneration, indicating the need for comprehensive histological sampling, and the pathologist must remain aware of the histological changes that can occur within the upper cervical loops. The picro-sirius red method was found to provide excellent delineation of the collagenous components.

It is currently unclear whether such degenerative changes greatly alter the mechanical properties of the arterial wall. As already indicated, most published cases of vertebral artery injury do not include a histological assessment. However, some vessel wall abnormalities have been described in such cases. Dowling and Curry<sup>13</sup> described a torn artery with widespread medial fibrosis and several authors, including Simonsen,<sup>20</sup> found "abnormally thin walled arteries". Cystic medial necrosis has also been described but not in association with traumatic subarachnoid haemorrhage. Changes in the staining pattern of the smooth muscle cells have been noted by Pollanen *et al* in torn vertebral arteries,<sup>21</sup> both at the site of rupture and distant to the tear, taking the form of discontinuous, non-circumferential, apparently necrotic regions of the tunica media. This was seen only in those victims who survived for at least one hour and showed that, rather than being a pre-existing abnormality, it followed the release of cytosol from damaged smooth muscle cells. We are currently evaluating the histological data from a series of vertebral arteries that have undergone biomechanical testing, to elucidate possible markers of poor function, and have also instigated a project to look for pre-existent degenerative changes in case material.

Several questions remain to be answered but we hope that our study will prove of some practical assistance to the pathologist investigating a death resulting from vertebral artery injury and in providing an opinion that may become central to the medicolegal process.

The authors would like to thank Mr A Williams and Mrs E Brandwood for the excellent illustrations and Mrs L Dew for typing the manuscript.

- 1 Vanezis P. Vertebral artery injuries in road traffic accidents; a post-mortem study. *J Forensic Sci Soc* 1986;**26**:281-91.
- 2 Sherman MR, Smialek JE, Zane WE. Pathogenesis of vertebral artery occlusion following cervical spine manipulation. *Arch Pathol Lab Med* 1987;**111**:851-3.
- 3 Pratt-Thomas HR, Berger KE. Cerebellar and spinal injuries after chiropractic manipulation. *JAMA* 1947;**103**:600-3.
- 4 Contostavlos DL. Massive subarachnoid haemorrhage due to laceration of the vertebral artery associated with fracture of the transverse process of the atlas. *J Forensic Sci* 1971;**16**:40-56.
- 5 Coast GC, Gee DJ. Traumatic subarachnoid haemorrhage—an alternative source. *J Clin Pathol* 1984;**37**:1245-8.
- 6 Harland WA, Pitts JF, Watson AA. Subarachnoid haemorrhage due to upper cervical trauma. *J Clin Pathol* 1983;**36**:1335-41.
- 7 Simonsen J. Fatal subarachnoid haemorrhages in relation to minor injuries in Denmark from 1967 to 1981. *Forensic Sci Int* 1984;**24**:57-63.
- 8 Johnson CP, Scraggs M, How T, *et al*. A necropsy study of abnormalities in the course of the vertebral artery associated with ossified stylohyoid ligaments. *J Clin Pathol* 1995;**48**:637-40.
- 9 Johnson CP, Scraggs M, How T, *et al*. The poor biomechanical response of the vertebral artery to longitudinal extension [abstract]. *J Pathol* 1994;**173**:234a.

## Appendix

### PICRO-SIRIUS RED METHOD

#### Reagents

- 0.5% potassium permanganate
- 1% oxalic acid
- Millers' elastic stain
- Picro-sirius red stain:
  - 100 ml picric acid (sat. Aq)
  - 6 ml 1% acid fuchsin
  - 6 ml 1% sirius red.

#### Controls

- Aorta or skin.

#### Method

- (1) Sections to water.
- (2) Treat with 0.5% potassium permanganate for 10 minutes.
- (3) Wash.
- (4) Decolourise in 1% oxalic acid for one to two minutes.
- (5) Rinse in water.
- (6) Rinse in 95% alcohol.
- (7) Stain in Millers' elastic stain for one hour.
- (8) Rinse in 95% alcohol to remove excess stain.
- (9) Rinse in water and check microscopically.
- (10) Rinse.
- (11) Counterstain in picro-sirius red for 20-30 minutes.
- (12) Rinse in water very briefly. Wipe around section and dry in slide drier.
- (13) Rinse in alcohol to remove any excess stain from the slide.
- (14) Clear in xylene. Mount.

- 10 Vanezis P. Techniques used in the evaluation of vertebral artery trauma at post-mortem. *Forensic Sci Int* 1979;**13**:159-65.
- 11 Johnson CP, Burns J. The medicolegal significance of proteoglycans in the tunica media of the vertebral artery. *Am J Forensic Med Pathol* 1993;**14**:165-9.
- 12 Johnson CP, Lawler W, Burns J. Histomorphometry in the assessment of fatal vertebral artery dissection. *J Clin Pathol* 1993;**46**:1000-3.
- 13 Dowling G, Curry B. Traumatic basal subarachnoid haemorrhage—report of six cases and review of the literature. *Am J Forensic Med Pathol* 1988;**9**:23-31.
- 14 Hutchinson EC, Yates PO. The cervical portion of the vertebral artery: a clinicopathological study. *Brain* 1956;**79**:319-31.
- 15 Wilkinson IMS. The vertebral artery. Extracranial and intracranial structure. *Arch Neurol* 1972;**27**:392-6.
- 16 Winckler G. Remarques sur la structure de l'artere vertebrale. *Quadrerni di Anatomia Practica S XXV111* 1972;**N1-4**:105-15.
- 17 Piffer CR, Zozetto NL. Microscopy anatomy of the vertebral artery in the suboccipital and intracranial segments. *Anatomischer Anzeiger (Jena)* 1980;**147**:382-8.
- 18 Chopard RP, Neto MHM, Lucas GA, *et al*. The vertebral artery: its relationship with adjoining tissues in its course intra and intertransverse processes in man. *Rev Paul Med* 1992;**110**:245-50.
- 19 Schlattmann AJM, Becker AE. Histologic changes in the normal ageing aorta: implications for dissecting aortic aneurysm. *Am J Cardiol* 1977;**39**:13-20.
- 20 Simonsen J. Traumatic subarachnoid haemorrhage in alcohol intoxication. *J Forensic Sci* 1963;**8**:97-116.
- 21 Pollanen MS, Deck JHN, Boutilier L, *et al*. Lesions of the tunica media in traumatic rupture of the vertebral arteries; histologic and biochemical studies. *Can J Neurol Sci* 1992;**19**:53-6.