

Clinical and molecular findings in a patient with a deletion on the long arm of chromosome 12

EDITOR—Reports of congenital abnormalities resulting from deletions on the long arm of chromosome 12 are rare.¹⁻⁴ A number of genes have been mapped to 12q, which include a gene for Noonan syndrome (NS) in some families⁵ and the gene for insulin-like growth factor I (IGF-I).⁶ The patient presented here was referred for assessment regarding the diagnosis of NS in view of her short stature, dysmorphic facies, and developmental delay and was found to have a *de novo* interstitial deletion on chromosome 12q. Despite some of the similar clinical findings to NS in this patient, molecular analysis showed that the deletion mapped approximately 17 cM centromeric to the critical region for NS. To our knowledge, there have been no similar cases of interstitial deletion reported on chromosome 12q.

The patient, a 15 year old girl was the first born child to a 23 year old mother and an unrelated 21 year old father. Her younger brother, aged 11 years, was fit and well. The family history was unremarkable. The pregnancy was normal. She was born at term as an emergency caesarean section for fetal distress. Her birth weight was 2860 g. She was admitted to the special care baby unit for 24 hours for observation. The neonatal period was complicated by pyloric stenosis for which surgery was carried out on day 16. During the postoperative period, she developed severe candidiasis and lactose intolerance. At the age of 1 year she was challenged with milk and seemed to have recovered from the intolerance. Developmentally she was able to sit unsupported at the age of 8 months and walked independently at the age of 2 years. Her speech was delayed and she was unable to say two words together until the age of 3 years. She has had no visual or hearing problems. Her height has always been below the 3rd centile. At the age of 12 years, just as she was entering puberty, she was diagnosed as having growth hormone deficiency. Her peak growth hormone level on glucagon stimulation test was 7 mU/l. She was started on treatment with growth hormone and she showed a good response with sustained growth over a three year period. She had no known cardiac abnormalities. She suffered from recurrent nose bleeds but there was no other history of bleeding problems. Physical examination at the age of 15 years indicated that her height and weight were just below the 3rd centile and her head circumference was on the 3rd centile. She had pectus excavatum, but her nipples were not widely spaced. She had bilateral ptosis, hypertelorism, and low set and posteriorly rotated ears (fig 1). Her hair was thin, fine, and sparse. Her posterior hairline was trident and low. Her neck was short with mild webbing. Cardiovascular examination showed a grade II ejection systolic murmur at the second left intercostal space. Echocardiogram showed normal dimensions and arrangements of the cardiac chambers and heart valves. The velocity of blood flow in the proximal pulmonary artery was slightly increased and this was thought to be the origin of the systolic murmur. Neurological examination was normal, but she had relatively poor coordination. Coagulation studies, including intrinsic clotting factor assays, were normal. Growth hormone secretion was normal with a peak response of 40.7 mU/l during the insulin tolerance test. Basal levels of IGF-I were normal (IGF-I 371 ng/ml, normal range 70-420 ng/ml).

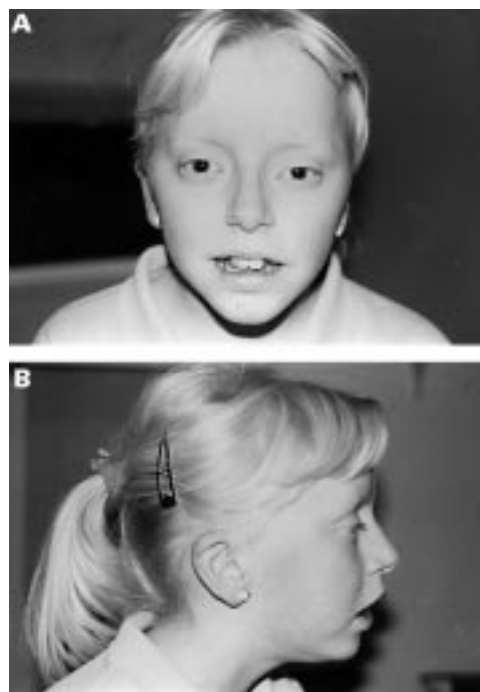


Figure 1 Photographs of the patient at the age of 15 years showing (A) hypertelorism and ptosis and (B) low set, posteriorly rotated ears. (Photographs reproduced with permission.)

Chromosome analysis by GTG banding was carried out on peripheral lymphocyte cultures. This showed an interstitial deletion of chromosome 12 (fig 2), karyotype 46,XX,del(12)(q21.2q23.2). Parental chromosomes were normal. FISH studies were not performed.

Venous blood was sampled from the patient, her normal brother, and her unaffected parents and genomic DNA was isolated. Seventeen microsatellite markers (D12S291, D12S96, D12S90, D12S335, D12S313, D12S80, D12S92, D12S337, D12S88, D12S81, D12S82, D12S101, D12S218, D12S346, IGF-I, D12S78, D12S84) of chromosome 12q were analysed. PCR amplification of 50 ng genomic DNA was performed in a 15 µl reaction mixture containing 30 ng of each primer, 200 µmol/l dNTPs, 50 mmol/l KCl, 1.5 mmol/l MgCl₂, 10 mmol/l Tris-HCl, 0.01% gelatin, 0.1% Triton X-100, and 0.1 U

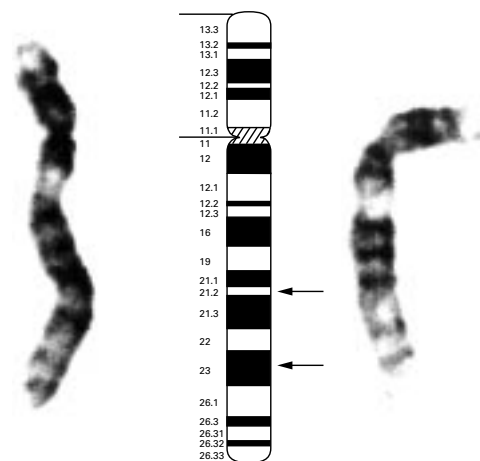


Figure 2 Chromosomes 12 of the patient showing her normal (left) and deleted (right) chromosomes 12 and an ideogram of chromosome 12 (centre). The breakpoints are indicated by arrows on the ideogram.

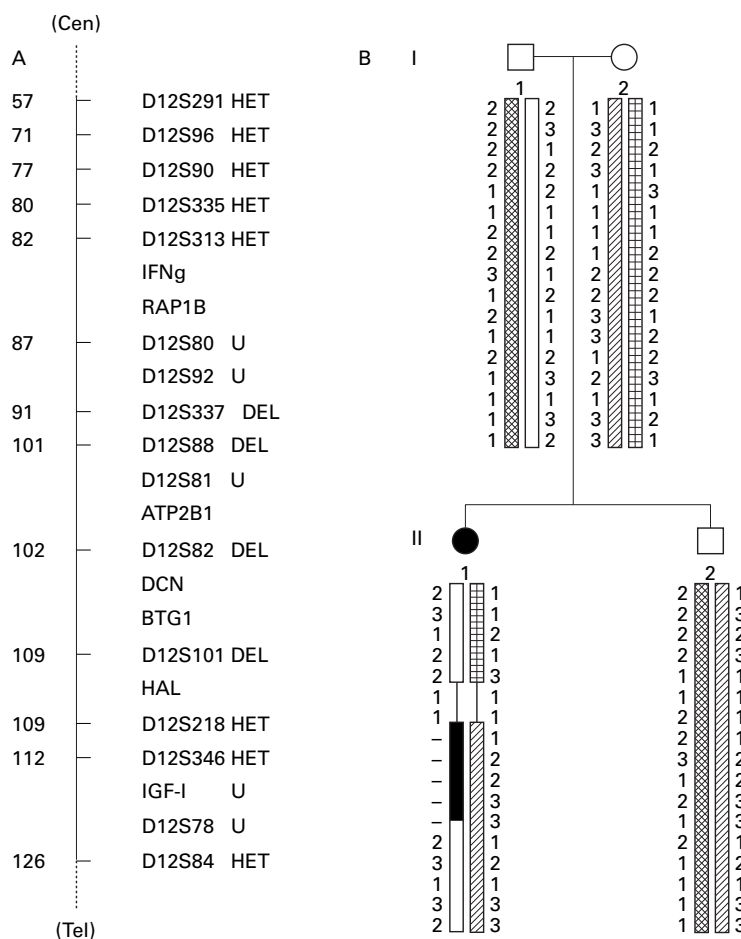


Figure 3 Results of analysis of microsatellite markers in the patient showing (A) genetic map of chromosome 12q with results of analysis of microsatellite markers (right) and their distance apart (left),⁷ and (B) haplotype in the patient and her family; the thick black bar represents area deleted. The names of the genes in the area deleted are given in Krauter *et al.*⁷ DEL=deleted, U=uninformative, HET=heterozygous. IFNg=interferon gamma, RAP1B=ras related protein, ATP2B1=human PMCA1, DCN=decorin, BTG1=B cell translocation gene 1, HAL=histidine ammonia lyase, IGF-I=insulin-like growth factor I.

SuperTaq DNA polymerase (HT Biotechnology Ltd). In all reactions, 30 cycles (one minute at 94°C, two minutes at 55°C, and two minutes at 72°C with a final seven minute elongation step) were carried out in an automated thermal cycler (Hybaid). The amplified products were separated by electrophoresis on 10% polyacrylamide gels. The gels were silver stained and dried. Haploinsufficiency of markers D12S337, D12S88, D12S82, and D12S101 was found. Haplotype analysis indicated that the deletion was paternal in origin and mapped between markers D12S313 and D12S218. The deletion represented a minimum region of about 18 cM positioned approximately 17 cM proximal to the critical region for NS (fig 3).

We have reported a girl with short stature, dysmorphic facies, developmental delay, and a de novo interstitial deletion on chromosome 12q. Interstitial deletions of chromosome 12q are rare. There have only been three previous cases reported to our knowledge with deletions on chromosome 12q, a male with a deletion (12)(q13.3q21.1),¹ a female with a deletion (12)(q15q21.2),² and a male with a deletion (12)(q12q13.12).⁴ A female with a derivative chromosome 9 and a recombinant chromosome 12 resulting from a balanced complex rearrangement involving chromosomes 8, 9, and 12 was suspected of having a submicroscopic deletion of chromosome 12q.³

Common characteristics between our case and the reported cases were hypertelorism,¹⁻⁴ apparently low set ears,¹⁻⁴ posteriorly rotated ears,^{1,3} sparse, fine hair,^{2,4} developmental delay,¹⁻⁴ growth retardation, and pectus deform-

ity (table 1).^{3,4} From the UK cytogenetic databases, a male patient with a deletion on chromosome 12, del(12)(q21.33q24.1), had been seen by the clinical geneticists in Edinburgh. He was found to have marked developmental delay, short stature, hydrocephalus, prominent eyes, and long, thin fingers. He did not have any facial features of NS and no congenital heart defect (Dr David Fitzpatrick, Department of Clinical Genetics, Western General Hospital, Edinburgh, personal communication). Isolated deficiency of IGF-I, the gene for which has been mapped to chromosome 12q22-24.1,⁶ has been found in pygmies of the Central African Republic.⁸ In view of our patient's short stature, dysmorphic facies, and increased pulmonary valve blood flow, it was suspected that the deletion might involve either the IGF-I gene or the critical region for NS on chromosome 12q. Analysis using microsatellite markers showed that the deletion was proximal to the critical region for NS and also proximal to the IGF-I gene (fig 3), making either scenario unlikely. Some of the genes which lie in the area deleted are shown in fig 3. The patient reported by Tonoki *et al.*¹ had features similar to those found in NS and the authors suggested that the deleted region in their patient may contain a gene for NS. Similarly, the deleted segment in our patient may also contain a gene for NS. Since the deletions in these patients do not overlap, it would mean that three genes responsible for NS would have to be situated on chromosome 12q, a considerable distance apart. This seems an unlikely event. Although the deletion in our patient lies outside the critical

Table 1 Clinical features reported in patients with interstitial deletions of chromosome 12q

Clinical feature	Meinecke and Meinecke ¹	Watson et al ²	Masuno et al ³	Tonoki et al ⁴	Present patient
Karyotype	46,XY,del(12)(q13.3q21.1)	46,XX,del(12)(q15q21.2)	46,XX,-9,-12,+der(9)(9pter-9q32::12q15-12qter),+rec(12)(12pter-12q15::9q32-9qter)mat	46,XY,del(12)(q12q13.12)	46,XX,del(12)(q21.2q23.2)
Hypertelorism	+	-	+	+	+
Ptosis	-	-	-	+	+
Low set ears	+	+	+	+	+
Posteriorly rotated ears	+	-	+	-	+
Short neck/webbed neck	-	-	-	+	+
Low posterior hairline	-	-	-	+	+
Sparse, fine hair	-	+	-	+	+
Growth retardation	-	-	+	+	+
Developmental delay	+	+	+	+	+
Pectus deformity	-	-	+	+	+
Other features	Bilateral cleft lip and palate, upward slanting palpebral fissures, macrostomia, retrognathia, overriding toes and rocker bottom feet, atrial and ventricular septal defects	Broad forehead, frontal bossing, flattened occiput, sunken eyes, beaked nose, thin upper lip, high arched palate, some syndactyly of toes, cutis marmorata	Patent foramen ovale, trigonocephaly, broad nasal root, triangular face, fifth finger clinodactyly, brain CT scan abnormal	Cleft palate, inguinal hernia, undescended testes, hypocalcaemia, iron defic anaemia, strabismus, downward slanting palpebral fissures, epicanthus, short nose, anteverted nostrils, long philtrum, micrognathia, shield shaped chest, small hands and feet, scoliosis, clinodactyly little fingers	Pyloric stenosis, slightly increased pulmonary artery blood flow

+present, -absent.

region for NS, it is possible that genes in this region may regulate genes in the NS critical region. Interestingly, our patient has a relatively mild clinical phenotype despite the size of the deletion. This suggests that the region deleted in this patient may only contain a small number of critical developmental genes. Alternatively, the effects of the genes deleted in this patient may be compensated for by the corresponding genes present on the non-deleted chromosome 12.

We thank the family for all their help with this study. We are most grateful for the financial support from the Birth Defects Foundation and the British Heart Foundation.

ANGELA F BRADY
MADIHA M ELSAWI
C RUTH JAMIESON
KAREN MARKS
STEVE JEFFERY
MICHAEL A PATTON

Medical Genetics Unit, St George's Hospital Medical School, London
SW17 ORE, UK

LILY MURTAZA

Department of Child Health, St John's Hospital, Chelmsford CM2 9BG,
UK

MARTIN O SAVAGE

Paediatric Endocrinology Section, St Bartholomew's Hospital, London,
EC1A 7BE, UK

Correspondence to: Dr Brady, Kennedy-Galton Centre, Northwick Park and St Mark's NHS Trust, Watford Road, Harrow, Middlesex HA1 3UJ, UK

- Meinecke P, Meinecke R. Multiple malformation syndrome including cleft lip and palate and cardiac abnormalities due to an interstitial deletion of chromosome 12q. *J Med Genet* 1987;24:187.
- Watson MS, McAllister-Barton L, Mahoney MJ, Breg WR. Deletion (12)(q15q21.2). *J Med Genet* 1989;26:343-4.
- Masuno M, Asano J, Yasuda K, Kondo T, Orii T. Balanced complex rearrangement involving chromosomes 8, 9 and 12 in a normal mother, derivative chromosome 9 with recombinant chromosome 12 in her daughter with minor anomalies. *Am J Med Genet* 1993;45:65-7.
- Tonoki H, Saito S, Kobayashi K. Patient with del(12)(q12q13.12) manifesting abnormalities compatible with Noonan syndrome. *Am J Med Genet* 1998;75:416-18.
- Jamieson CR, van der Burgt I, Brady AF, et al. Mapping a gene for Noonan syndrome to the long arm of chromosome 12. *Nat Genet* 1994;8:357-60.
- Morton CC, Byers MG, Nakai H, Bell GI, Shows TB. Human genes for insulin-like growth factors I and II and epidermal growth factor are located on 12q22-24.1, 11p15, and 4q25-q27, respectively. *Cytogenet Cell Genet* 1986;41:245-9.
- Krauter K, Montgomery K, Yoon SJ, et al. A second-generation YAC contig map of human chromosome 12. *Nature* 1995;337:321-33.
- Merimee TJ, Zapf J, Froesch ER. Dwarfism in the pygmy: an isolated deficiency of insulin-like growth factor I. *N Engl J Med* 1981;305:965-8.

J Med Genet 1999;36:941-943

Amelogenesis imperfecta, sensorineural hearing loss, and Beau's lines: a second case report of Heimler's syndrome

EDITOR—Hearing loss owing to genetic causes has a reported prevalence of 1 in 1000 births and among these 15-30% are associated with other abnormalities, although only a small number are associated with oral and dental disorders.¹ Heimler et al² reported two sibs with a combination of sensorineural hearing loss, amelogenesis imperfecta, and nail abnormalities (McKusick No 234580). We describe a further case here and extend the phenotypic spectrum of this syndrome.

A 12 year old girl presented with a combination of unilateral sensorineural deafness and amelogenesis imper-

fecta. She was born at term following a normal pregnancy and had a birth weight of 3200 g (50th centile). There was no consanguinity within the family; her mother was aged 25 and her father was aged 29 at the time of conception. She had no major illnesses in the first years of life and all her developmental milestones were achieved within normal limits. At the age of 7, it was discovered that she had unilateral hearing loss and subsequent investigation showed that she had profound sensorineural deafness on the left, hearing on the right being normal. At the time her mother felt that she may have had reduced hearing in the left ear for about two years before the diagnosis was made. At the age of 8 years, there was evidence of extensive enamel discoloration in her permanent dentition and amelogenesis imperfecta was diagnosed. Her primary dentition was reported as having erupted on time and the remaining primary teeth had a normal appearance. There was no history of intellectual impairment and she was doing well in main-